

Early result of hemiarthroplasty in elderly patients with fracture neck of femur

Mue Daniel, Saliu Mohammed¹, Awonusi Francis¹, Yongu William, Kortor Joseph, Elachi Cornilius

Department of Surgery, Benue State University, Makurdi, ¹Department of Clinical Services, National Orthopaedic Hospital Dala, Kano, Nigeria

ABSTRACT

Background: Fractured neck of femur is a frequent and severe injury in elderly patients with consequent high morbidity and mortality. Hemiarthroplasty is an established treatment modality for displaced intracapsular femoral neck fractures in elderly patients above 60 years. This study analysed the early functional outcome and complications of Austin Moore endoprosthesis in elderly patients above 60 years with fractured neck of femur. **Materials and Methods:** Retrospective data were obtained over a 5 year period from January 2007 to December 2012. Thirty-five elderly patients of 60 years and above with displaced intracapsular fracture neck of femur treated with hemiarthroplasty using Austin Moore endoprosthesis were included. Data were analysed using SPSS version 21. **Results:** A total of 35 patients were involved. The age-range was 60-90 years with mean age of 69.7 ± 7 years. The predominant mechanism of injury was trivial falls in 18 (66.7%) patients. The commonest complication was pressure sore in 2 (5.7%) patients, followed by surgical site infection in 1 (2.9%) patient and periprosthetic fracture in 1 (2.9%) patients. Early post-operative mortality was 2.9%. Post-operative hip functional status according to Postel and Merle d Aubigne revealed that majority (66.6%) of patients had satisfactory hip function. **Conclusion:** Functional outcome of Austin Moore in elderly patients above 60 years with fracture neck of femur was satisfactory in most of the cases with minimal morbidity. Careful patient selection for hemiarthroplasty is vital and may decrease the incidence of complications and ameliorate the outcomes in the treatment of intracapsular femoral neck fractures.

Key words: Austin Moore prosthesis, fracture neck femur, hemiarthroplasty

Address for correspondence:

Dr. Mue Daniel Demesugh,
Department of Surgery,
Benue State University
Teaching Hospital,
Makurdi, Nigeria.
E-mail: mue.daniel@yahoo.com

INTRODUCTION

Femoral neck fracture is a frequent and severe injury in the elderly with associated high mortality and morbidity. The incidence of these fractures has increased with improvement in life expectancy and is expected to double in the next 20 years and triple by 2050.¹ Mortality rate of 20-30% in the year following the fracture has been reported.¹ Management poses a challenge to the orthopaedic surgeon especially in the elderly patient with medical co-morbidities.

Although surgical treatment is the gold standard, the best surgical treatment option is still to be determined.² Hip replacement arthroplasty (partial or total) is emerging as the most viable treatment option and a broader consensus

has been reached as regards its benefits which allow immediate weight bearing, early restoration of pre-morbid activity and enhanced quality of life in elderly patients.³

Studies by Rogmark *et al.*,⁴ and Roden *et al.*,⁵ showed complications of non-union, avascular necrosis and a high rate (30-40%) of reoperation following internal fixation and superior function after primary hemiarthroplasty which eliminates these complications as the femoral head and neck is replaced by metallic implant.⁶ Although unipolar hemiarthroplasty with Austin Moore prosthesis is rarely employed in the developed countries, it is still commonly used in developing countries where it is reserved for elderly, very limited or non-ambulatory, low-demand patients with relatively shorter life expectancy.² Calder *et al.*,³ found no statistical difference in the complication rates following the use of unipolar and bipolar endoprosthesis in treating displaced hip fractures in octogenarians, and that the degree of return to the pre injury state was significantly greater when using the Austin Moore unipolar endoprosthesis. Frihagen *et al.*,⁷ in their study on the functional outcomes of Austin Moore endoprosthesis versus bipolar prosthesis have shown the end result to be the same.

Access this article online	
Quick Response Code:	Website: www.nigeriamedj.com
	DOI: 10.4103/0300-1652.149174

There is paucity of published literature on functional outcome of hemiarthroplasty among elderly patients in our environment. The objective of this study was to share our experience on the early functional outcome and complications of cementless unipolar hemiarthroplasty with Austin Moore endoprosthesis in elderly patients above 60 years with fractured neck of femur.

MATERIALS AND METHODS

This is a 5 year retrospective study from January 2007 to December 2012, conducted at Nongu u Krestu u i Ser u sha Tar (NKST) rehabilitation Hospital Mkar, North Central Nigeria. Thirty five elderly patients aged 60 years and above with displaced intracapsular fracture neck of femur were operated by 3 orthopaedic surgeons using Austin Moore endoprosthesis were included in the study. Patients having pre-existing symptomatic acetabular diseases (Rheumatoid arthritis, ankylosing spondylitis, tuberculosis, Paget’s disease), multiple fractures and any form of infection or a life threatening medical conditions were excluded from the study. The post-operative complications and hip functional status of patients was assessed according to the hip functional scale of Postel and merle d Aubigne (PMA) [Tables 1 and 2] after at least 4-6 months of follow-up.

The following variables were studied: Mechanism of injury, duration of fracture, associated systemic illness, complications and post-operative hip functional status.

The data was analysed for frequencies of various variables. Statistical programme for social science (SPSS) version 21 was used to analyse the data. Effect modifiers like age and gender were controlled through stratification.

RESULTS

The total number of patients was 35 with 23 males and 12 females. Male to female ratio was of 1.9:1 with a male gender prevailing by 65.7%. The age range was 60-90 years with mean age of 69.7 years.

The predominant mechanism of injury was trivial falls in 18 (66.7%) patients followed by motorcycle accident in 8 (29.6%) patients and vehicular accident in 1 (3.7%) patients. [Table 3] Majority of the women (88.9%) patients were involved in low energy injury trivial falls while more men (87.5% and 100%) patients were involved on high energy injury — motor cycle accident and vehicular accident respectively [Figure 1 and Table 3]. Only 4 (11.4%) patients presented within 48 hours of injury. Majority of the patients 71.4% presented between 3 week and 1 year of injury. Fifteen (42.9%) patients had one or more systemic co-morbidity such as hypertension (28.6%), Diabetes Mellitus (2.9%) and four (11.4%) patients had both diabetes mellitus and hypertension. Spinal anaesthesia was preferred in most (74.3%) patients as it is safer in these frail elderly patients with systemic comorbidity whose health status is further deranged by trauma, only 8 (29.1%) patients underwent surgery under general anaesthesia. One (3.7%) patients was started on spinal anaesthesia but later converted to general anaesthesia due to wearing out of the spinal anaesthesia from prolonged surgery.

The most frequently used surgical approach was anterolateral (48.5%) followed by direct lateral (28.6%) and posterior or

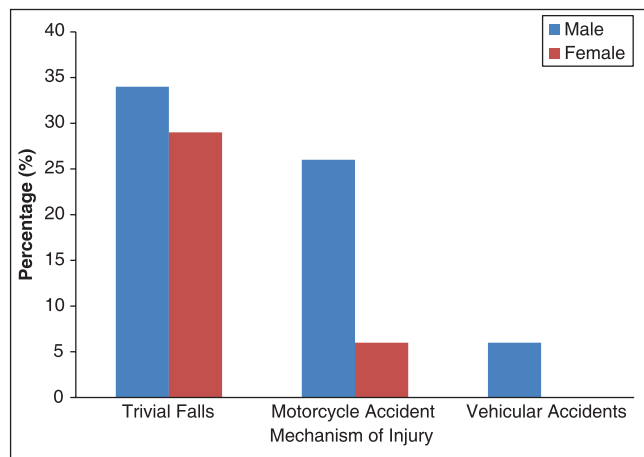


Figure 1: Gender versus Mechanism of Injury of fracture neck of femur in elderly patients

Table 1: Method of grading functional value of the hip (Postel and Merle D’ Aubigne)

Pain	Mobility	Ability to walk
No pain	Flexion of more than = 90°	Normal
Pain is mild and inconstant normal activity	Flexion between 80° and 90° Abduction at least 15°	Without cane but with slight limp
Pain is mild when walking. It disappears with rest	Flexion between 60° and 80°. Patient can reach his foot. Flexion between 40° and 60°	A long time with cane, short time without cane and with limp
Pain is tolerable with limited activity		With one cane, less than one hour; very difficult without a cane
Pain is severe when walking; prevents any activity	Flexion under 40°	Only with canes
Pain is severe even night	No movement; pain slight deformity	Only with canes
Pain is intense and permanent,	Ankylosis with bad position of the hip	None

No vicious attitude – Take in account only the bending attitude; Vicious attitude – Withdraw; Point for 20° + of bending or irreducible external rotation; points for 10° or + abduction; abduction; irreducible internal rotation

southern approach (22.9%). Size range of Austin Moore prosthesis used was 42-52 mm. The most frequently used sizes were 44-46 mm with 52.8% cumulative use. Majority (85.8%) patients of the smaller sized prosthesis (42-45 mm) were used by women while (80%) patients men used the larger sizes (46-52 mm) [Figure 2].

The mean duration of hospital stay was 16 (13-34) days. Mean duration of surgery was 113 (75-135) minutes and mean estimated blood loss was 330 mls. Fifty five percent of patients required at least one unit of blood transfusion. Majority of the patients (91.4%) walked with some form of external support during the hospitalisation period. Two patients (5.7%) had mental derangement and refused to co-operate with physiotherapy and one patient (2.9%) was discharged against medical advice.

The commonest complication was pressure sore in two patients (5.7%), followed by surgical site infection in one patient (2.9%) and periprosthetic fracture in 1 patient (2.9%). [Table 4] Early post-operative mortality was 2.9%.

Follow-up time of patients was poor as patients default frequently after a few visits. Five patients (14.2%) were lost to follow-up and were never seen after discharge in the surgical outpatient department. Only 21 patients (60%) were seen at 6 months follow-up, six patients (17.1%) at 1 year follow-up and only one patient (2.9%) was seen after 1 year.

Post-operative hip functional status done according to Postel and Merle d Aubigne scoring system [Tables 1 and 2] at 4-6 months post-operation revealed that majority of the surviving patients (69%) had satisfactory (Good, Very Good and Excellent) post-operative hip functional score [Figure 3].

DISCUSSION

Intracapsular fractures of the proximal femur form a major share of fractures in the elderly. Osteoporosis,

co-morbidities, increased incidence of trivial trauma increases the incidence and complicates the treatment of these fractures.

Table 2: Global assessment of hip function (by Merle D' Aubigne)

Pain	Mobility	Walking	Total	Appreciation
6	6	6	18	Excellent
6	5	6	17	Very good
6	6	5		
5	6	6		
6	5	5	16	Good
6	4	6		
5	6	5		
5	5	5	15	Fair
6	4	5		
5	4	6		
6	5	4		
4	6	5		
5	4	5	14	Poor
5	5	4		
4	5	5		
6	2	5	13	Arthrodesis (12,11,10)
4	4	4		
5	3	4		

Place here the post-surgery results if no clinical improvement or aggregation ≤9 Bad

Table 3: Age versus mechanism of injury of fracture neck of femur in elderly patients above 60 years

Age (years)	Trivial falls (%)	Motorcycle accident (%)	Vehicular accident (%)	Total (%)
60-70	11 (31.4)	8 (22.9)	1 (2.9)	20 (57.1)
71-80	11 (31.4)	2 (5.7)	—	13 (37.1)
81-90	2 (5.7)	—	—	2 (5.7)
Total	24 (68.6)	10 (28.6)	1 (2.9)	35 (100)

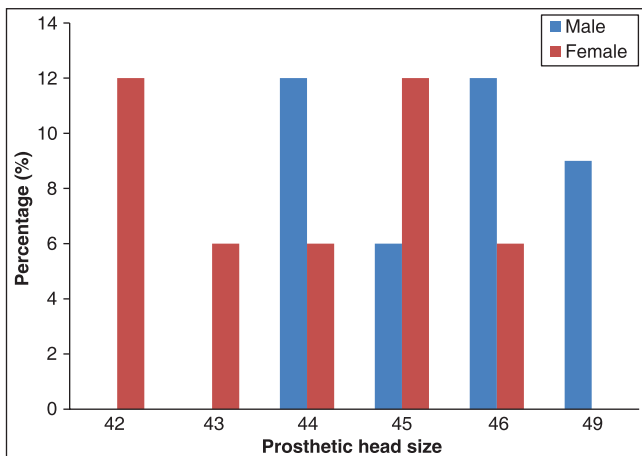


Figure 2: Gender versus prosthesis head size of elderly patients following hemiarthroplasty

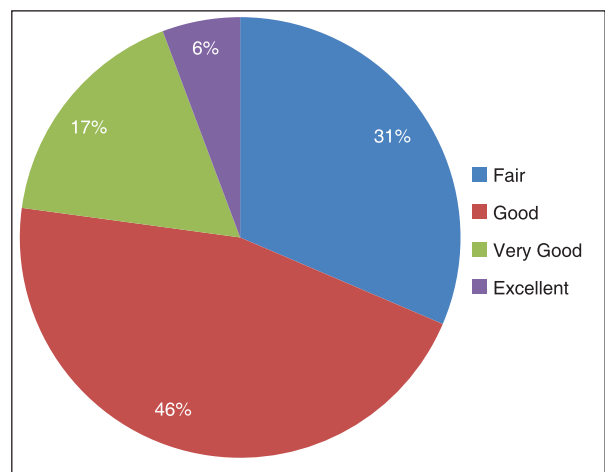


Figure 3: Post operative hip functional status of elderly patients above 60 years following hemiarthroplasty with Austin Moore endoprosthesis

Table 4: Age grade versus complications following hemiarthroplasty in elderly patients above 60 years

Age (years)	Periprosthetic fracture (%)	Surgical infection (%)	Pressure sore (%)	Total (%)
61-70	—	—	1 (2.8)	1 (2.8)
71-80	1 (2.8)	—	—	1 (2.8)
81-90	1 (2.8)	1 (2.8)	1 (2.8)	3 (8.6)
Total	2 (5.7)	1 (2.8)	2 (5.7)	5 (14.3)

There was a male preponderance observed in this study with a male female ratio was of 1.9:1. This gender variation is similar to results obtained in some loco regional studies by Onche *et al.*,⁸ Aristote *et al.*,⁹ but at variance with western studies by Dhar *et al.*,¹⁰ and Syed *et al.*,¹¹ where the female gender prevails in view of higher incidence of osteoporosis. Lauritzen *et al.*,¹² in their study observed that when comparing race, Caucasians are more likely to suffer hip fractures more than any other race and reported that African Americans and Hispanics are the least likely to suffer hip fractures, which is sought to be attributed to a higher bone density found in both of African Americans and Hispanics. The mean age of 69.7 ± 15 years obtained in this study is similar to 67.4 years by Onche *et al.*,⁸ and 65 years by Essoh *et al.*,¹³ but at variance with 72 years by Dhar *et al.*,¹⁰ and 83.5 years by Syed *et al.*,¹¹ which reflects the higher life expectancy of those countries.

The predominant mechanism of injury was trivial falls in 18 (66.7%) patients this is in keeping with previous studies.^{8,9} Eight (29.6%) patients were involved in motorcycle accident reflecting the recklessness of motorcyclist as a common etiology for trauma in developing countries.^{8,9} Majority of the women (88.9%) were involved in low-energy injury — trivial falls which reflects the higher incidence of osteoporosis in women⁸⁻¹² while more men (87.5% and 100%) were involved on high energy injury — motor cycle accident and vehicular accident respectively.

There was delay in presentation as majority 31(88.6%) of patients presented after 48 hours of injury of whom 71.4% presented between 3 week and 1 year of injury. This late presentation and probable worsening of fracture displacement from repeated manipulation by traditional bone setters may have caused additional trauma and potential vascular insult.¹³ This reflects the activities of these traditional healers and bone setters in developing countries who dabble into fracture management without regulation.^{8,9}

Cement less Austin Moore endoprosthesis was used in all cases. Bone cement has been shown to adversely affect pulmonary and cardiovascular function during the conduct of surgery and the immediate postoperative period which may be poorly tolerated in the elderly with pre-existing cardiopulmonary comorbidity. Pavarzi *et al.*,¹⁴

demonstrated the incidence of intraoperative death contributed by the use of acrylic bone cement during hip hemiarthroplasty to be less than 0.2%. Stavrakis *et al.*,¹⁵ in his study to assess the effectiveness of cement less Austin Moore and the cemented Thompson prostheses used in the treatment of displaced intracapsular fractures of the proximal femur, found that though advantages and disadvantages were identified in both groups, none of the techniques proved definitively superior to the other. The risk of intraoperative complications related to the use of cement may be reduced by venting the femur, avoiding excessive pressurization during insertion and adequate preoperative hydration.

Although Austin Moore's prosthesis eliminates the chances of non-union and avascular necrosis, other complications still occurred. The commonest complication encountered in this study was pressure sore in two patients (5.7%). This was Shea grade 1 which healed uneventfully following daily dressing and mobilisation of the patients. Early graded mobilisation is advocated in these patients to forestall this complication. Abduction pillow if used should be discontinued early after 4-5 days.

The infection rate in the present study was 2.9%. This was superficial surgical site infection and was treated by removal of alternate stitches, daily wound dressing and antibiotics therapy according to sensitivity pattern. Previous studies reported crude infection rate of 0% by Sicand *et al.*,¹⁶ 4.7% by D'Arcy *et al.*,¹⁷ and 20% by Onche *et al.*,⁸ Essoh *et al.*,¹³ reported deep surgical site infection necessitating removal of prosthesis and conversion to Girdlestone excision arthroplasty. The rate of infection was kept low by proper preoperative preparation, general measures for keeping operation room clean, use of impervious drapes by routine use of prophylactic antibiotic, and keeping such patients in the ward away from the infected patients. The infection rate has been reported to be higher when posterior approach is used for arthroplasty due to proximity of incision to the perineum. This was however not reported in this study.

Intraoperative periprosthetic fracture was encountered in 1 (2.9%) patient. This was Vancouver Type A2 fracture which was identified during the procedure and managed with cerclage wire, cementing the prosthesis was not required as fracture was considered stable. This is in similar to previous incidence of 6.8% by Fernandez *et al.*,¹⁸ 11.8-14.0% by Weinrauch *et al.*,¹⁹ Most fractures are often sustained during dislocation of head of femur from acetabulum, impaction of the prosthesis after broaching or during its reduction. Under broaching and relative oversizing of the stem with intent to provide interference fit of the prosthesis in osteoporotic bone may result in fracture during prosthesis insertion. Previous studies by Weinrauch *et al.*,¹⁹ and Parker *et al.*,⁶ have reported a statistically significant increased

incidence of periprosthetic fractures in uncemented Austin Moore prosthesis. Options available to minimize intraoperative periprosthetic fractures include; Proper patient positioning, adequate lateralization of the broach, adequate soft tissue release, routine use of narrow stem prosthesis or cementing the Austin Moore prosthesis.

Early post-operative mortality was 2.9%. Previous studies reported one year post-operative mortality rate of 8.3% by Essoh *et al.*,¹³ 15% by Syed *et al.*,¹¹ 11.1% by Aristotle *et al.*,⁹ and 38% by Sicand *et al.*,¹⁶ in elderly patients treated by Austin Moore prosthesis. The rate of mortality depends on age of the patients and systemic medical comorbidities^{12,16} which may be minimised by careful patient selection, proper pre-operative optimisation, adequate thrombo prophylaxis and early post-operative mobilisation.

Follow-up time of patients was poor as patients default frequently after a few visits. Five (14.2%) patients were lost to follow-up and never seen after discharge in the surgical outpatient department. Only 21 (60%) patients were seen at 6 months follow-up, 6 (17.1%) patients at 1 year follow-up and only one (2.9%) patient was seen after 1 year. This inconsistent follow-up and difficulty in contacting our patients made it challenging to accurately ascertain the post-operative mortality pattern as some deaths had probably occurred at home after the last consultation.

Post-operative hip functional status done according to Postel and Merle d Aubigne scoring system revealed that majority (69%) of patients had satisfactory hip function (Good, Very Good and excellent) post-operative hip functional score [Figure 3]. This is in keeping with previous studies which reported 76% satisfactory score by Ahmad *et al.*,²⁰ 59% by Syed *et al.*,¹² and 82% by D'Arcy *et al.*¹⁷

CONCLUSION

Functional outcome of Austin Moore in elderly patients with fracture neck of femur in terms of pain relief, mobility and restoration of function as near as possible to the pre-injury level was satisfactory in majority of cases with minimal morbidity. Careful patient selection for hemiarthroplasty is vital and may decrease the incidence of complications and ameliorate the outcomes in the treatment of displaced intracapsular femoral neck fractures. This study suggests primary hemiarthroplasty with Austin Moore endoprosthesis may be favoured in the treatment of displaced intracapsular fracture neck femur in elderly patients above 60 years.

REFERENCES

1. Schmidt AH, Swiontkowski MF. Femoral neck fractures. *Orthop Clin North Am* 2002;3:97-111.

2. Nather A, Seow CS, lau P, Chan A. Mortality and morbidity for elderly patients with fractured neck of femur treated by hemiarthroplasty. *Injury* 1995;26:187-90.

3. Calder SJ, Anderson GH, Jagger C, Harper WM, Gregg PJ. Unipolar or bipolar prosthesis in displaced intracapsular hip fractures in octogenarians: A randomised prospective study. *J Bone Joint Surg Br* 1996;78:391-4.

4. Rogmark C, Carlsson A, Johnell O, Sernbo I. Primary hemiarthroplasty in old patients with displaced femoral neck fracture: A 1-year follow-up of 103 patients aged 80 years or more. *Acta Orthop Scand* 2002;73:605-10.

5. Roden M, Schon M, Freden H. Treatment of displaced femoral neck fractures: A randomized minimum 5-year follow-up study of screws and bipolar hemiprosthesis in 100 patients. *Acta Orthop Scand* 2003;74:42-4.

6. Parker MJ, Khan RJ, Crawford J, Pryor GA. Hemiarthroplasty versus internal fixation for displaced intracapsular hip fractures in the elderly. A randomized trial of 455 patients. *J Bone Joint Surg Br* 2002;84:1150-5.

7. Frihagen F, Nordsletten L, Madsen JE. Hemiarthroplasty or internal fixation for displaced femoral neck fractures: Randomized controlled trial. *BMJ* 2007;335:1251-4.

8. Onche II, Yinusa W. Femoral neck fractures: A prospective assessment of the pattern, care and outcome in an orthopaedic centre. *Niger J Orthop Trauma* 2004;4:42-9.

9. Aristotle H, Moevi A, Michel L, Madougou S, Zannou R, Padonou J. Treatment of femoral fracture by moore prothesis in Cotonou. *Niger J Orthop Trauma* 2010;9:5-7.

10. Lauritzen JB. Hip fractures. Epidemiology, risk factors, falls, energy absorption, hip protectors, and prevention. *Dan Med Bull* 1997;44:155-68.

11. Dhar D. Early results of austin moore prosthesis in elderly patients with fracture neck femur. *J Orthop* 2007;4.

12. Syed SN, Niaz H, Imran J. Outcome of Austin-Moore hemiarthroplasty in elderly patients with fracture neck of Femur. *J Pak Orthop Assoc* 2010;8:14-9.

13. Essoh JB, Sie MD, Aka D, Kacou MD, Kodo MD, Iambin MD. Austin moore hemiarthroplasty for displaced fracture neck of fractures in patients aged 55years and above. An Ivorian experience. *Nigerian journal of trauma and Orthopaedics* 2006;5:18-24.

14. Parvizi J, Holiday AD, Ereth MH, Lewallen DG. The Frank Stinchfield Award. Sudden death during primary hip arthroplasty. *Clin Orthop Relat Res* 1999:39-48.

15. Stavrakis KJ,. Intracapsular fractures of the neck of the femur. *J Bone Joint Surg Br* 1970;52:514-7.

16. Sikand M, Wenn R, Moran CG. Mortality following surgery for undisplaced intracapsular hip fractures. *Injury* 2004;35:1015-9.

17. D'Arcy J, Devas M. Treatment of fractures of femoral neck by replacement with Thompson prosthesis. *J Bone Joint Surg Br* 1976;58:279-86.

18. Fernández-Valencia JA, Llobet F, Pons N, López-Zabala I, Borri JR. Intraoperative periprosthetic femoral fractures related to austin moore hemiarthroplasty-A retrospective review of 365 patients. *Open J Orthop* 2013;3:189-92.

19. Weinrauch P. Intra-operative error during Austin Moore hemiarthroplasty. *J Orthop Surg (Hong Kong)* 2006;14:249-52.

20. Ahmad I. Mortality and morbidity in elderly patients with fracture neck of femur treated by hemiarthroplasty. *J Coll Physicians Surg Pak* 2006;16:655-8.

How to cite this article: Daniel M, Mohammed S, Francis A, William Y, Joseph K, Cornilius E. Early result of hemiarthroplasty in elderly patients with fracture neck of femur. *Niger Med J* 2015;56:64-8.

Source of Support: Nil, **Conflict of Interest:** None declared.