

Available online at www.sciencedirect.com

ScienceDirect

journal homepage: www.elsevier.com/locate/radcr

Case Report

Bullet retrieval from the right hepatic vein using a controlled endovascular and transhepatic approach

Abouelmagd Makramalla, MD*, James Buchino, MD, Jay Johannigman, MD, Ross Ristagno, MD

University of Cincinnati, 234 Goodman St, Cincinnati, OH 45267-0761, USA

ARTICLE INFO

Article history:

Received 10 June 2018

Revised 22 June 2018

Accepted 23 June 2018

Available online 29 July 2018

Keywords:

bullet
 embolus
 snare
 endovascular
 balloon
 percutaneous

ABSTRACT

Venous bullet embolism is a rare complication of trauma. We describe a patient who sustained a gunshot wound. Computed tomography revealed antegrade embolization of the bullet to the right hepatic vein (RHV). The risk of not retrieving the bullet embolus and subsequent embolization to the pulmonary circulation includes pulmonary artery thrombosis, bleeding, or abscess formation. The bullet was retrieved through right internal jugular vein access; assisted by percutaneous transhepatic repositioning and endovascular balloon-immobilization of the bullet. The balloon served to "isolate" the bullet within the RHV to avoid the risk of endovascular migration to the pulmonary circulation. Transhepatic access allowed repositioning of the bullet within the RHV leading to successful snare retrieval. This technique demonstrates advantages of percutaneous and endovascular accesses, that repositioned and immobilized the bullet in the RHV to accomplish controlled endovascular retrieval.

© 2018 The Authors. Published by Elsevier Inc. on behalf of University of Washington.

This is an open access article under the CC BY-NC-ND license.

(<http://creativecommons.org/licenses/by-nc-nd/4.0/>)

Introduction

Although venous bullet emboli are rare [1,2] devastating complications often occur. A bullet can gain access to the venous circulation through penetrating wounds and embolize to any vascular bed. They may be asymptomatic or cause life-threatening complications, especially with migration [3,4].

The following case report describes bullet removal from the RHV in a postoperative patient who sustained a gunshot

wound to the right torso. Previous reports of bullet retrieval in the hepatic veins have been described [5–8] using a snare via a single venous access without endovascular balloon stabilization. Utilization of an endovascular balloon to stabilize a bullet during retrieval has been described in the retrieval of IVC [9] and the iliac vein [10] bullet emboli. In contrast to previous reports, the following employed techniques show the advantages of percutaneous transhepatic access and endovascular balloon immobilization to allow for controlled endovascular bullet retrieval from the RHV.

* Competing Interests: The authors have declared that no competing interests exist.

* Corresponding author.

E-mail addresses: mak@uc.edu (A. Makramalla), jjb004@gmail.com (J. Buchino), johannja@ucmail.uc.edu (J. Johannigman), ross.ristagno@uchealth.com (R. Ristagno).

<https://doi.org/10.1016/j.radcr.2018.06.014>

1930-0433/© 2018 The Authors. Published by Elsevier Inc. on behalf of University of Washington. This is an open access article under the CC BY-NC-ND license. (<http://creativecommons.org/licenses/by-nc-nd/4.0/>)

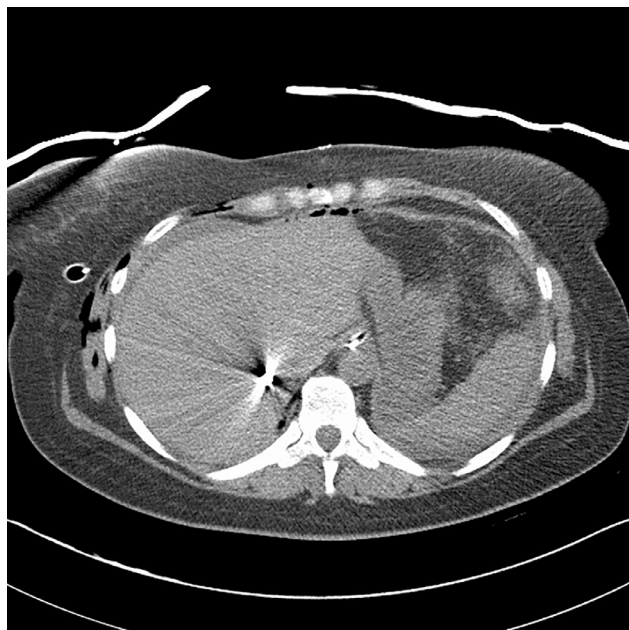


Fig. 1 – Noncontrast CT of the abdomen at the level of the hepatic veins showing bullet embolus in close proximity to the IVC.

Case

A 36-year-old female sustained a single gunshot wound to the right chest and abdomen. Emergent laparotomy repaired a through-and-through inferior vena cava (IVC) injury and bowel injuries. The bullet was not recovered. In addition, she required repair of a colon injury, small bowel resection and anastomosis, and placement of a right chest tube.

A postoperative computed tomography (CT) (Fig. 1) revealed the missing bullet had embolized to an unstable location within the RHV close to the IVC confluence.

Next, the patient underwent bullet retrieval in the interventional radiology suite under general anesthesia. A 65 cm, 20-F sheath (Cook Medical, Bloomington, IN) was selected for bullet retrieval and placed via the right internal jugular vein (IJV) with the tip positioned in the intrahepatic IVC. The size of the sheath was determined from CT measurements. A second sheath, 35 cm, 8-F Brite Tip (Cordis Corporation, Bridgewater, NJ), was inserted via the left IJV. Special care was taken in the positioning of guidewires and sheaths to avoid placement into the lower IVC where there had been a recent surgical repair. Through the left IJV sheath, a 65 cm, 5-F Soft-Vu MPA catheter (AngioDynamics, Inc. Queensbury, NY) was positioned into the RHV, caudal to the bullet, and a venogram (Fig. 2) demonstrated the relationship of the bullet to the RHV and no change in position compared to the CT.

An 18 mm × 4 cm Atlas balloon catheter (BARD Peripheral Vascular, Inc., Tempe, AZ) was placed through the left IJV sheath and inflated immediately cephalad to the bullet in the superior aspect of the RHV (Fig. 3). Slight movement of the bullet observed during balloon manipulation reaffirmed the precarious position of the bullet in the RHV. The balloon was

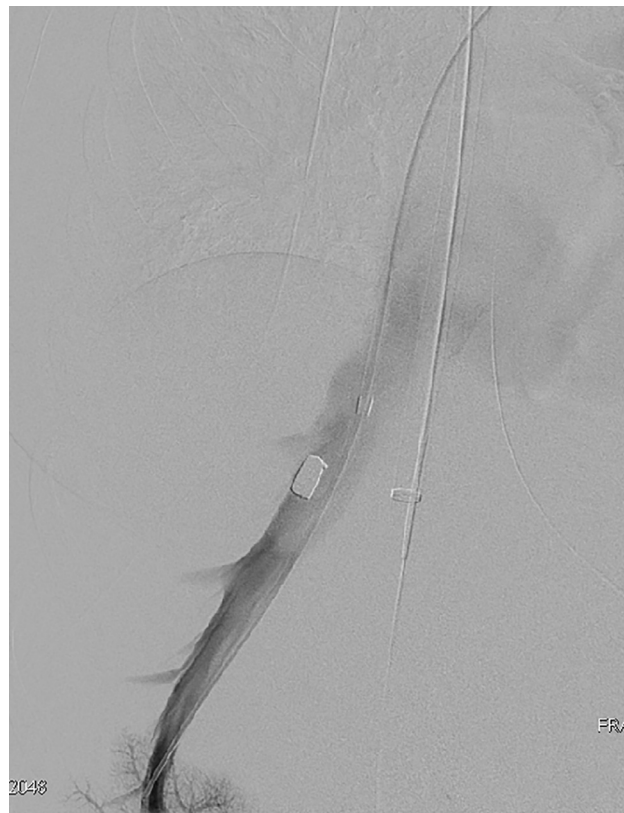

Fig. 2 – Selective right hepatic venogram showing bullet embolus within the right hepatic vein.

maintained in this position to secure the bullet in the RHV and prevent migration to the heart and lungs during retrieval attempts. Balloon inflation was titrated to allow sufficient RHV blood flow and avoid thrombosis.

Through the right IJV sheath, attempts to snare the bullet using different retrieval devices including a basket as well as a 20 mm Amplatz GooseNeck Snare (ev3 Endovascular, Inc., Plymouth, MN) were unsuccessful due to the unfavorable position of the bullet—too close to the balloon and lack of space in the RHV.

To facilitate the right IJV approach snare capture of the bullet, percutaneous, ultrasound- and fluoroscopic guided, transhepatic access to the RHV was obtained. A guidewire via the right IJV was placed within the peripheral posterior subsegmental branch of the RHV and used as a fluoroscopic target to guide the transhepatic access to the bullet. Through this transhepatic access, multiple attempts using different retrieval devices including a basket were unsuccessful. A 20 mm Amplatz GooseNeck Snare was then used to move the bullet away from the balloon and into a side branch of the RHV favorable for retrieval (Fig. 4). Through the right IJV 20-F sheath, a 12–20 mm Atrieve Vascular Snare (Angiotech Pharmaceuticals, Inc., Vancouver, BC) successfully captured the bullet (Fig. 5). Although a basket is a much better choice, however the Atrieve Vascular Snare was the only device that successfully captured the bullet.

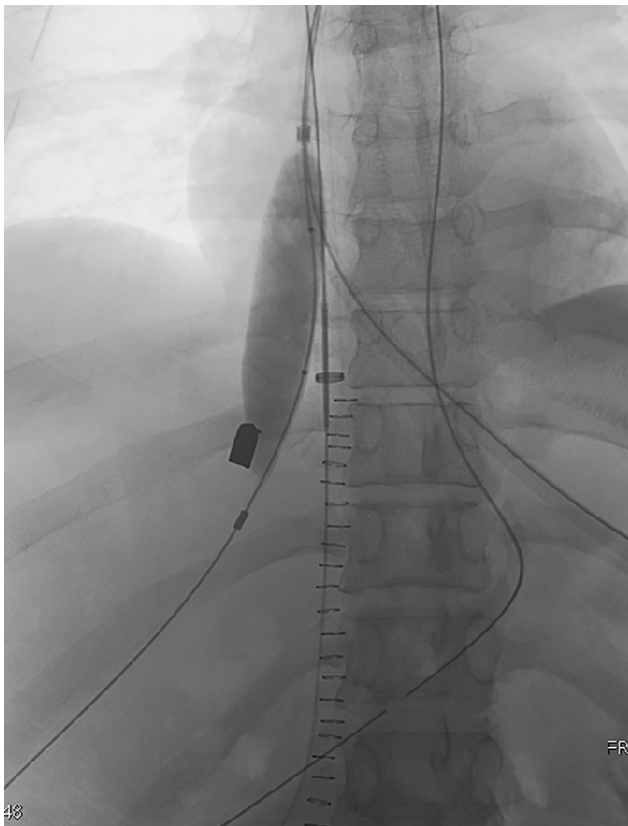


Fig. 3 An – 18 mm balloon inflated immediately cephalad to the bullet in the superior aspect of the right hepatic vein to isolate the bullet embolus.

At this point, the surgeon performed a right neck cut down with exposure of the right IJV and the 20-F sheath venotomy site. Surgical exposure of the right IJV was deemed necessary in case the snared bullet could not pass through the sheath and instead, removal of the sheath and/or snare and/or bullet combination would be required.

Next, the balloon was deflated and then the snare and bullet were retracted into the sheath as the sheath was gently advanced (Fig. 6). The snare was removed from the sheath and the bullet was delivered (Fig. 7). A final hepatic venogram (Fig. 8) demonstrated a patent RHV and upper IVC and no extravasation. The left IJV and transhepatic sheaths were removed followed by manual compression applied to each site. The 20-F right IJV sheath was removed followed by surgical closure of the venotomy site. The patient did well after the procedure and exhibited no postprocedural complications.

Discussion

Venous bullet emboli gain entry into the venous circulation from numerous points of entry and can travel anterograde or retrograde in the venous circulation, though more commonly move in the direction of blood flow [3,5,11], as in this case report. Venous bullet emboli may be asymptomatic or cause se-

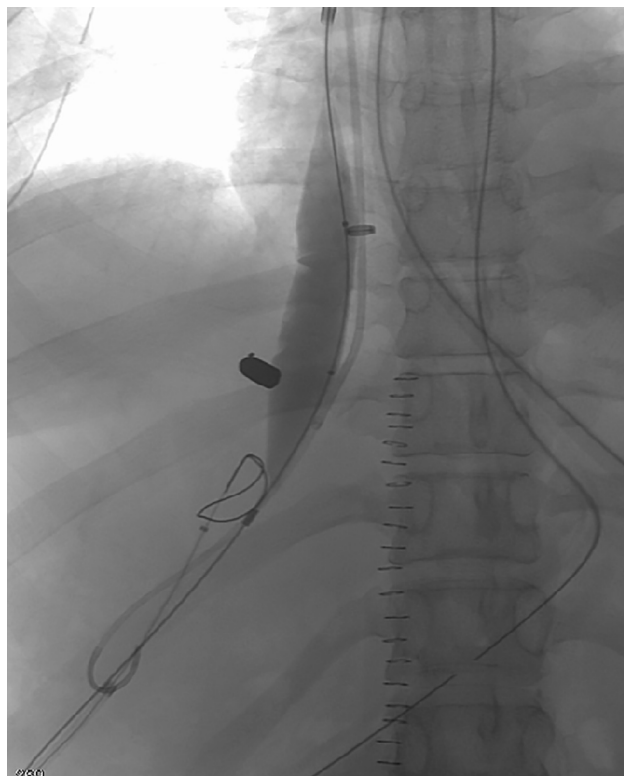


Fig. 4 – Amplatz GooseNeck Snare placed by a transhepatic access, used to move the bullet away from the balloon and into a side branch of the RHV favorable for retrieval.

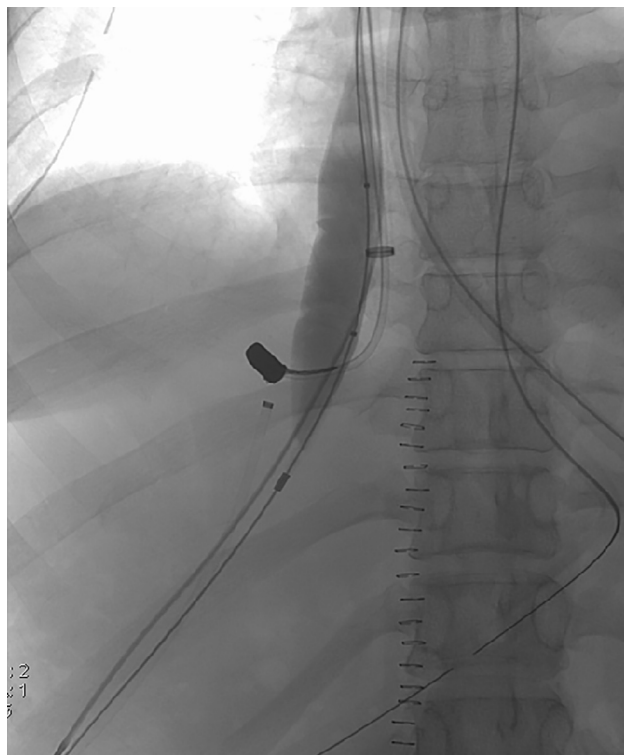


Fig. 5 – Successful capture of the bullet embolus through the right IJV 20-F sheath using an Atrieve Vascular Snare.

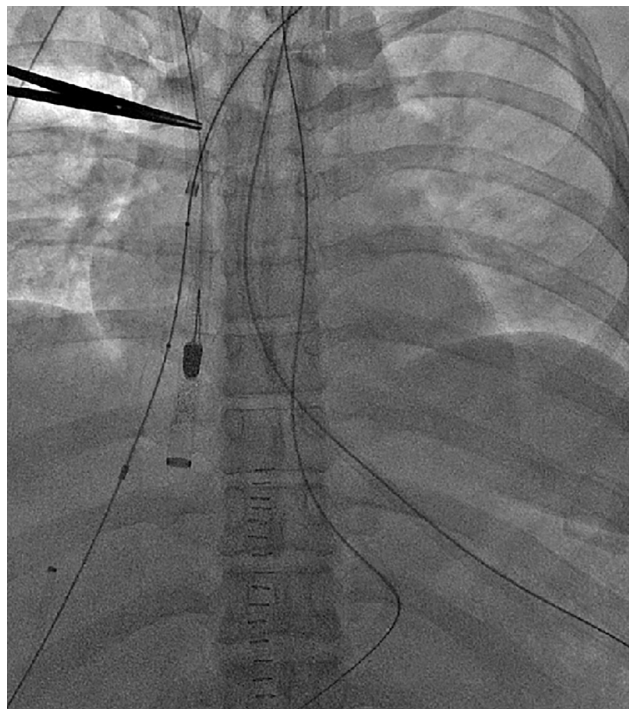


Fig. 6 – The snare-bullet combination retracted into the sheath.

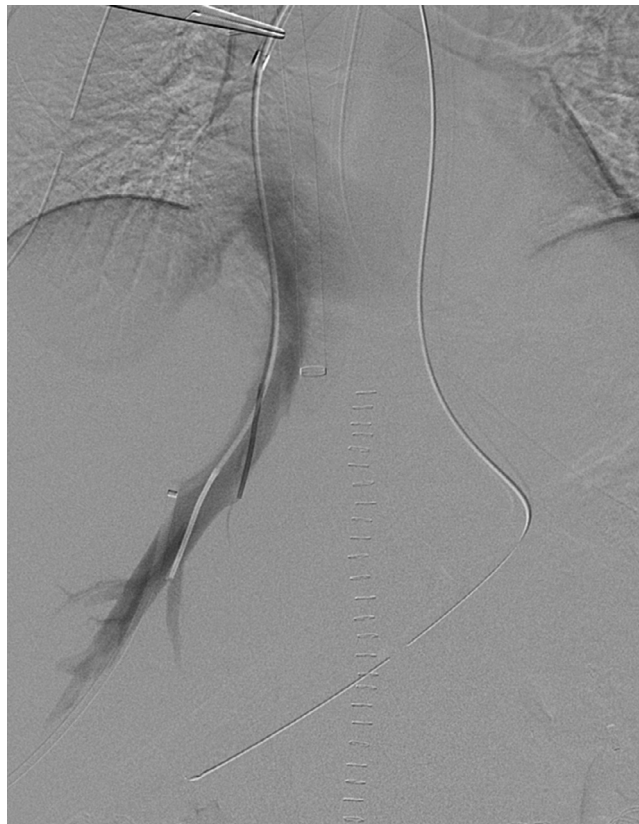

Fig. 8 – Final right hepatic venogram demonstrates a patent right hepatic vein with no extravasation.




Fig. 7 – The bullet embolus after successfully completed retrieval.

rious complications such as injury to cardiac valves, venous thrombosis and/or thrombophlebitis, sepsis, endocarditis, arrhythmias, and pulmonary artery occlusion [3,4]. Venous bullet migration may occur even years after injury and most eventually migrate to the right ventricle or pulmonary arterial tree [11-14].

Bullet retrieval may be accomplished through surgical or transvenous approaches. Successful endovascular snare retrieval of a hepatic venous bullet embolism has been described in very few previous case reports in the literature [5-8]. There has also been a report of an unsuccessful endovascular re-

trieval of a hepatic vein bullet embolus [15]. Bullet migration during an endovascular extraction attempt has been reported [11]. Although it may seem feasible to remove a bullet in the hepatic vein using a snare through a single venous sheath, careful planning prior to the procedure may avoid a migration complication during retrieval [11]. Risks of retrieving a bullet from the hepatic vein include unintentional migration of the bullet, embolization to the pulmonary circulation, hepatic vein thrombosis, and vascular injury.

This case report features a novel technique “assisted percutaneous transhepatic venous access to reposition the bullet embolus.” This allowed controlled venous bullet retrieval from the RHV using a snare, with balloon stabilization (on the cephalad side of the bullet), as well as moving the bullet (from the caudal side through transhepatic venous access) into a more accessible side branch of the RHV. The right IJV was selected over a femoral vein approach [6] for the retrieval access because the right IJV provided a straight path to the RHV. In this case report, not only was the bullet venous embolus in a very unstable location close to the IVC, but there was insufficient space in the RHV to snare it. Early in the procedure, a balloon was placed into the cephalad aspect of the RHV to “isolate” the bullet and avoid dislodgement and embolization to the heart or lungs. The balloon was inflated to the extent that the bullet was immobilized yet permitted sufficient blood flow in order to avoid RHV thrombosis. A percutaneous transhepatic approach was used to reposition the bullet away from the

balloon to a more proximal location within the right hepatic vein to allow for endovascular retrieval.

Removing the bullet through the large IJV sheath avoided possible hemorrhage that could be encountered if the bullet was directly extracted from the vein through a cut-down.

In summary, venous bullet embolus is a rare occurrence. Endovascular bullet retrieval is an excellent treatment modality to remove a venous bullet embolus lodged in the hepatic vein because of lower morbidity compared to an open surgical approach [1]. This case report describes a controlled endovascular snare technique for removal of a RHV bullet. As highlighted in this report, an endovascular balloon was used to stabilize the mobile bullet and percutaneous transhepatic manipulation of the bullet allowed for optimal presentation within the RHV for a successful endovascular snare retrieval of the bullet.

Supplementary materials

Supplementary material associated with this article can be found, in the online version, at [doi:10.1016/j.radcr.2018.06.014](https://doi.org/10.1016/j.radcr.2018.06.014).

REFERENCES

- [1] Schroeder ME, Pryor HI 2nd, Chun AK, Rahbar R, Arora S, Vaziri K. Retrograde migration and endovascular retrieval of a venous bullet embolus. *J Vasc Surg* 2011;53(April(4)):1113–15 PubMed PMID: 21215588.
- [2] Keele KL, Gilbert PM, Aquisto TM, Lichtenberg R, Field TC, Lee BK. Bullet embolus to the thoracic aorta with successful endovascular snare retrieval. *Journal of vascular and interventional radiology: JVIR*. 2010;21(1):157–8.
- [3] Miller KR, Benms MV, Sciarretta JD, Harbrecht BG, Ross CB, Franklin GA, et al. The evolving management of venous bullet emboli: a case series and literature review. *Injury* 2011;42(May(5)):441–6 PubMed PMID: 20828693.
- [4] Greaves N. Gunshot bullet embolus with pellet migration from the left brachiocephalic vein to the right ventricle: a case report. *Scand J Trauma Resusc Emerg Med* 2010;18:36 PubMed PMID: 20565913. Pubmed Central PMCID: 2898681.
- [5] Raikar SS, Jureidini SB, Balfour IC, Tinker K. The fantastic journey of a bullet: out with a snare. *Pediatric Cardiol* 2010;31(January(1)):108–10 PubMed PMID: 19795162.
- [6] Rehm C, Alspaugh JP, Sherman R. Bullet embolus to the right hepatic vein after a gunshot wound to the heart and its percutaneous retrieval. *J Trauma* 1988;28(May(5)):719–20 PubMed PMID: 3285019. Epub 1988/05/01. eng.
- [7] Bonk RT, Harrison SD, Meissner MH. Intravascular bullet localization by sonography. *AJR* 1996;167(July(1)):152 PubMed PMID: 8659361. Epub 1996/07/01. eng.
- [8] Shannon FL, McCroskey BL, Moore EE, Moore FA. Venous bullet embolism: rationale for mandatory extraction. *J Trauma* 1987;27(October(10)):1118–22 PubMed PMID: 3312620.
- [9] Ronsivalle J, Statler J, Venbrux AC, Arepally A. Intravascular bullet migration: a report of two cases. *Military Med* 2005;170(December(12)):1044–7 PubMed PMID: 16491945.
- [10] Sclafani SJ, Mitchell WG. Retrograde venous bullet embolism. *J Trauma* 1981;21(August(8)):656–7 PubMed PMID: 7021867.
- [11] Bertoldo U, Enrichens F, Comba A, Ghiselli G, Vaccarisi S, Ferraris M. Retrograde venous bullet embolism: a rare occurrence—case report and literature review. *J Trauma* 2004;57(1):187–92.
- [12] Wales L, Jenkins DP, Smith PL. Delayed presentation of right ventricular bullet embolus. *Ann Thorac Surg* 2001;72(2):619–20.
- [13] Wales L, Jenkins DP, Smith PL. Delayed presentation of right ventricular bullet embolus. *Ann Thorac Surg* 2001 20010822 DCOM- 20010906(0003-4975 (Print)). eng.
- [14] Bining HJ, Artho GP, Vuong PD, Evans DC, Powell T. Venous bullet embolism to the right ventricle. *Br J Radiol* 2007;80(December(960)):e296–8 PubMed PMID: 18065636.
- [15] Cavalcante LP, Bernardes MV, RD Rocha, Parisati MH, Souza JE, Araujo AOD, et al. Retrograde venous bullet embolism after thoracic gunshot. *J Vasc Brasileiro* 2013;12(4):324–8.