



# Wide-field endoscopic mucosal resection of laterally spreading rectal tumors using a multiband ligation endoscopic mucosal resection technique

Adam J. Kichler, DO, David L. Diehl, MD

## INTRODUCTION

Advanced tissue resection techniques such as EMR and endoscopic submucosal dissection (ESD) have been established as therapeutic options for the management of advanced mucosal neoplasia of the colon. EMR has been found to safely and effectively remove sessile or flat neoplasms confined to the superficial layers of the GI tract.<sup>1</sup>

Ligation EMR (L-EMR) is a well-established technique that is achieved through the creation of a pseudopolyp using a band ligator followed by electrocautery snare resection.<sup>2,3</sup> L-EMR is an integral component to the multimodal approach to Barrett's esophagus, and although it is not performed routinely for the management of colonic lesions, it has been shown to be effective in the resection of rectal carcinoid lesions.<sup>4,5</sup>

L-EMR can be safely performed in the rectum below the peritoneal reflection and may have a role in the management of large rectal lesions that are amenable to endoscopic resection. L-EMR can be easier than conventional piecemeal EMR or ESD for large lesions because tissue can be precisely targeted, particularly near the dentate line. Furthermore, band placement during the L-EMR technique promotes adequate depth of resection into the submucosa, allowing the deep margin to be clear of adenomatous tissue.

## INDICATIONS AND CONTRAINDICATIONS

L-EMR is an alternative for standard-snare EMR or ESD and is appropriate for the management of rectal lesions below the peritoneal reflection that have features amenable to endoscopic resection.<sup>6</sup> L-EMR is not appropriate for lesions proximal to the peritoneal reflection because the muscularis layer could be suctioned into the cap during pseudopolyp creation, potentially increasing the risk of a full-thickness resection. The muscularis propria layer is fixed below the peritoneal reflection, and there is a diminished risk of perforation.

Morphologic and mucosal surface assessment must be performed to determine whether the lesion harbors high-risk features for submucosal invasion. The Paris Classification system can be used to macroscopically assess

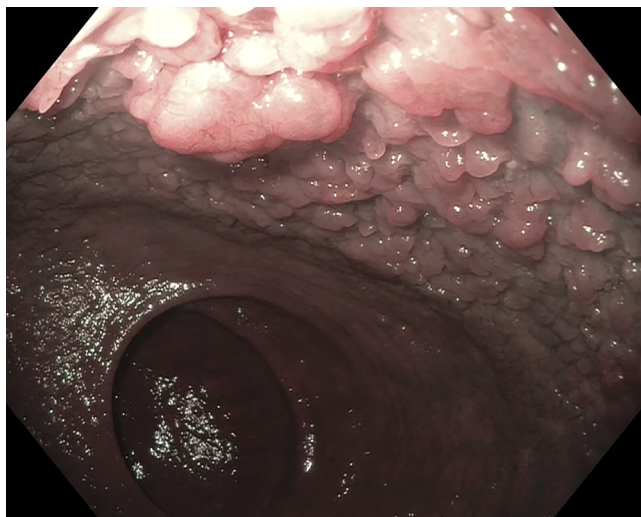
polyps, with increased risk for submucosal invasion being present in flat or depressed lesions (Paris IIb, IIc, IIa+IIc).<sup>7</sup> The lesion may also be assessed using narrow-band imaging (NBI) and characterized according to the NBI International Colorectal Endoscopic classification system. Increased risk of submucosal invasion should be suspected when NBI assessment demonstrates absent vessels or those in an amorphous or disrupted pattern (NBI International Colorectal Endoscopic Type 3).<sup>8</sup> L-EMR should not be performed for lesions that have high-risk features for submucosal invasion because these would confer increased risk of incomplete resection. L-EMR should also not be performed in clinical scenarios where en bloc resection is required.

## CASE

A healthy 51-year-old woman was referred for consideration of endoscopic versus surgical resection of a circumferential laterally spreading tumor (LST) of the rectum that was identified on her initial screening colonoscopy. Given her preference, young age, and excellent health status, the decision was made to proceed with endoscopic resection. Endoscopic evaluation revealed the presence of a near-circumferential granular Paris IIa LSTs of the rectum that extended from the dentate line proximally to the middle transverse rectal fold (Fig. 1). On endoscopic assessment, there were no high-risk features for deep invasion; therefore, it was believed to be appropriate for L-EMR.

## Procedural challenges

The endoscopic resection of giant granular LSTs of the rectum is a technically challenging and lengthy procedure. The daunting nature of these resections often leads to their referral to tertiary centers with endoscopists who have specialized training in the resection of advanced colonic neoplasia. L-EMR is a commonly used endoscopic technique and, when used in this scenario, may address a gap for many gastroenterology practices that have limited access to specialized centers.



**Figure 1.** Endoscopic lesion assessment.

## Equipment

The equipment required includes a standard gastro-scope with auxiliary water jet, carbon dioxide insufflation, spray catheter, mucosal contrast dye such as methylene blue or indigo carmine, an injection needle, thermal or argon cautery probe, multiband ligator or combined mucosectomy device, and an electrocautery snare.

## Procedure

Flexible sigmoidoscopy using a standard single-channel gastro-scope should first be performed to assess the lesion. Additional details of the lesion should be detected using electronic (eg, narrow-band imaging, i-scan, Fuji Intelligent Chromo Endoscopy [Fujifilm, Tokyo, Japan], or blue-light imaging) and/or dye (chromoendoscopy)-based image-enhanced endoscopy techniques to improve the optical diagnosis and lesion classification.<sup>9</sup> If spray chromoendoscopy is performed, a solution of dilute contrast (methylene blue or indigo carmine) should be prepared according to the SCENIC international consensus statement recommendations for lesion characterization and delineation of borders.<sup>10</sup> The spray catheter should be advanced through the working channel, and the dilute contrast solution should be applied to the entirety of the lesion and its adjacent mucosa for border delineation (Fig. 2).

For additional confirmation that giant LSTs of the rectum do not have submucosal invasion, an attempt should be made at lifting the lesion. With the use of an injection needle, dilute methylene blue in saline solution without epinephrine may be injected into the submucosal layer, and the entire lesion should be assessed for adequate lift before resection. Repeat submucosal lift injections can be performed throughout the procedure at the endoscopists' discretion. The borders of the lesion should

then be marked using a thermal cautery or argon plasma probe. This will help guide the resection and maintain orientation throughout the procedure (Fig. 3).

The endoscope is then equipped with a multiband ligating device with electrocautery snare or a combined ligation and mucosectomy device. Starting along the border, a target is identified, and the initial band should be positioned at the periphery of the lesion to include a rim of normal mucosa. The endoscope with distal cap and ligating device is advanced to this target, and the polypoid mucosa is aspirated into the ligating device.

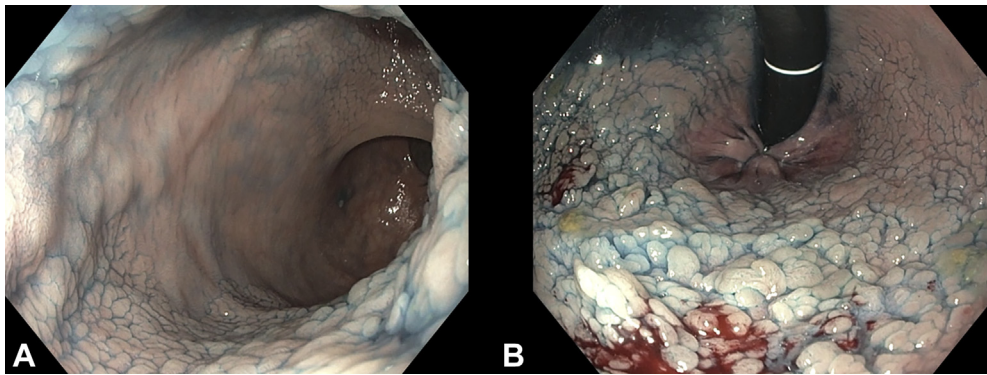
Once an adequate amount of tissue is within the ligation cap, an elastic band is deployed, thereby creating a pseudopolyp. An electrocautery snare is then passed through the working channel of the endoscope and situated at the base of the pseudopolyp below the elastic band to ensure adequate depth of resection before it is tightened. The pseudopolyp is resected using an electrocautery snare at a cutting current setting (Fig. 4). After successful resection, the pseudopolyp creation and snare resection process is repeated in sequential and contiguous fashion on immediately adjacent polypoid mucosa until the entire lesion has been resected (Fig. 5). The distal cap attachment of the ligation device allows for precise targeting of adenomatous tissue while minimizing unnecessary resection of neighboring healthy mucosa, thereby enhancing the ability to perform successful resections to the dentate line without significant postprocedural pain. This degree of precision is a distinct advantage of the L-EMR technique that may not be possible with a snare alone.

Upon resection of the entire lesion, snare-tip soft coagulation of the borders of the resection margin can be performed. Assessment of the resection bed should then be performed. Coagulation using coagulation graspers or the snare tip should be performed for protruding arterioles and veins to minimize risk of delayed postresection bleeding (Fig. 6). The resected tissue can be retrieved at any point throughout the resection process using a net or the suction channel.

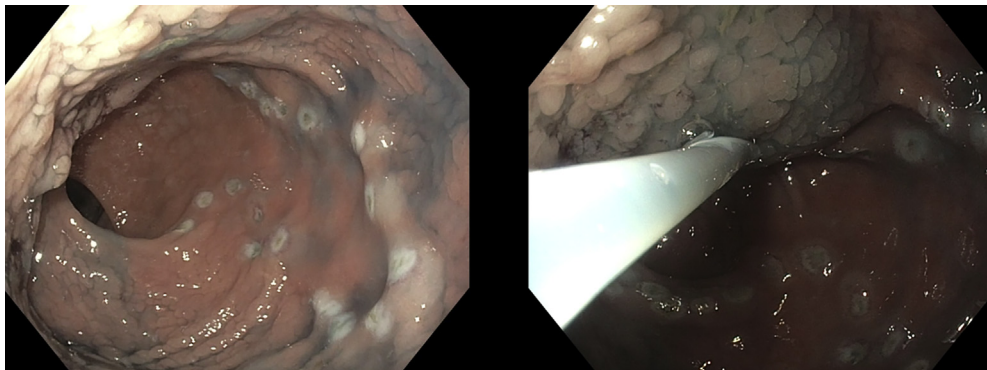
## Outcome

This video (Video 1, available online at [www.giejournal.org](http://www.giejournal.org)) demonstrates a multiband L-EMR of a giant LST requiring a total of 54 band ligations with a total procedure length of 137 minutes. Each pseudopolyp created was immediately resected with an electrocautery snare. Because of the anticipated length of the procedure, the decision was made to convert from monitored anesthesia care to general anesthesia after the initial lesion assessment.

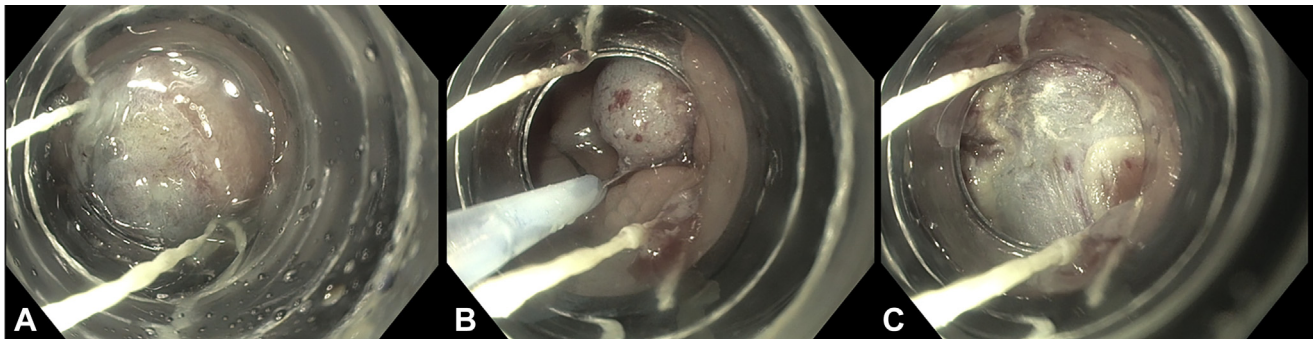
Pathology findings revealed fragments of adenomatous colonic mucosa with tubular, villous, and serrated features. The patient did not experience any postprocedural adverse events and was without any symptoms when she returned for a surveillance endoscopy 3 months later.



**Figure 2.** Assessment of lesion after spray chromoscopy in forward (A) and retroflexed (B) views.



**Figure 3.** The borders of the lesion are marked, and saline solution submucosal injection lift was performed.



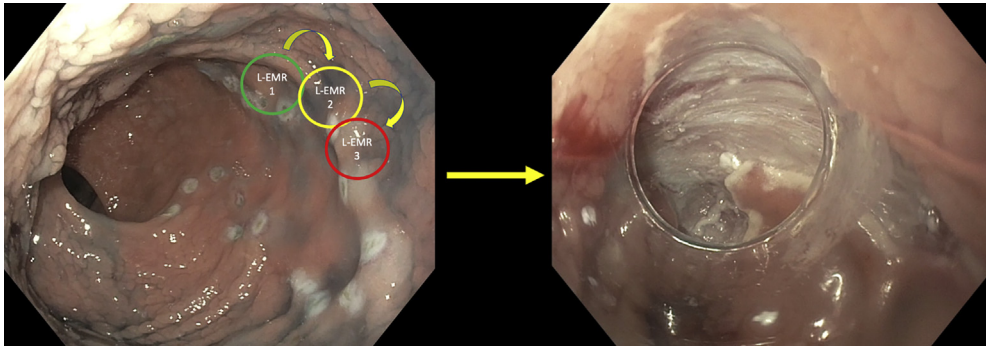
**Figure 4.** Sequential steps for the performance of ligation-assisted endoscopic mucosal resection. **A**, Lesion targeted for band ligation. **B**, Snare positioned and tightened below the band of pseudopolyp. **C**, Resection margin after ligation-assisted endoscopic mucosal resection.

On follow-up surveillance endoscopy, there was evidence of a healthy scar in the distal rectum with a 15-mm focus of residual polypoid tissue located along its proximal aspect (Fig. 7). This residual tissue was successfully resected by endoluminal surgical debriement using an endoscopic powered resection catheter that allows for tissue resection of nonlifting lesions or areas of significant scarring without having to remove muscle or perform full-thickness resection. Other

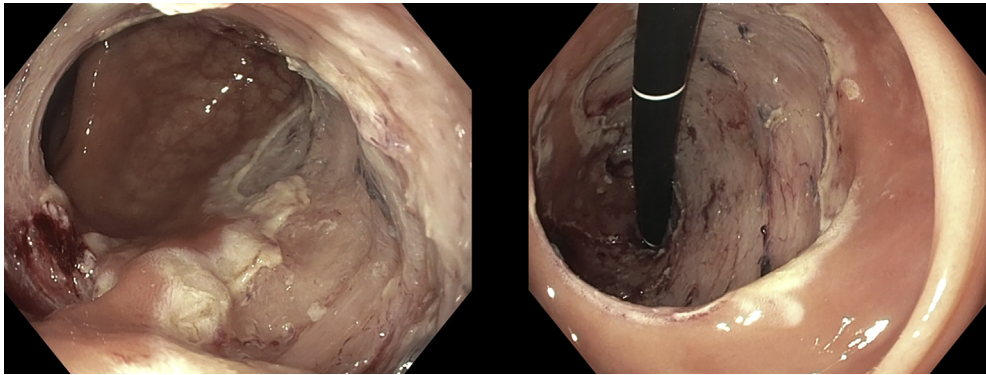
viable alternatives would be hot biopsy avulsion of the residual polypoid tissue.

The pathology findings of the remaining fragments were consistent with tubular adenoma with no evidence of high-grade dysplasia. Surveillance endoscopy performed 3 months later demonstrated no evidence of residual polypoid tissue. The patient remained asymptomatic with regard to the mild luminal narrowing resulting from post-resection scar formation.

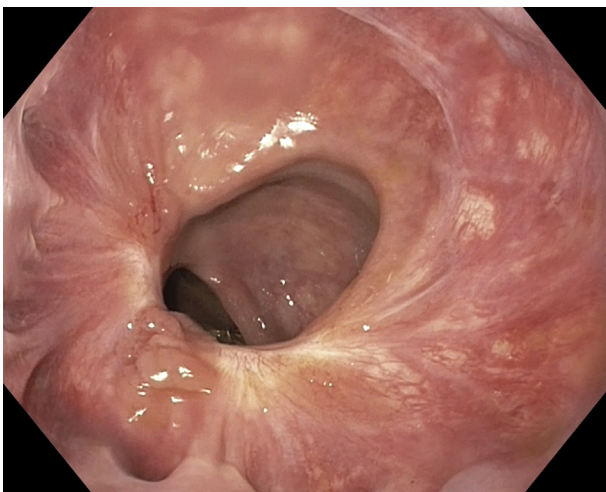




**Figure 5.** Schematic of multiband sequential ligation-assisted endoscopic mucosal resection of large rectal lesions.



**Figure 6.** Assessment of the resection margins after the 54-band L-wide field endoscopic mucosal resection.



**Figure 7.** Endoscopic appearance at the time of the 3-month follow-up endoscopy.

## CONCLUSIONS

Ligation EMR can be successfully and safely performed for the resection of large laterally spreading granular tumors of the rectum. This case has demonstrated that L-EMR can be effectively performed even on a nearly

circumferential lesion that extended distally to the dentate line. A limitation of L-EMR is the cost associated with multiple band ligation devices required, depending on the size of the lesion, but this expense is likely to be offset by a shorter overall procedure time compared with ESD or conventional piecemeal snare EMR.

L-EMR is very safe, but rare adverse effects such as intra-procedural bleeding (3.1%), delayed bleeding (0.6%), and perforation may occur; the main late adverse event of delayed structuring may be seen.<sup>5</sup> Although L-EMR is routinely performed in clinical gastroenterology practice, this report describes a novel application of L-EMR that can be added to the armamentarium of resection techniques for colonic neoplasia. L-EMR may be an alternative to technically challenging and lengthy ESD or traditional piecemeal snare EMR. L-EMR may also be uniquely positioned to provide successful tissue resection in regional practices that have limited access to tertiary referral centers capable of ESD techniques.

## DISCLOSURE

*Dr Diehl is a consultant for Boston Scientific, Olympus, Pentax, US Endoscopy/Steris, Creo Medical, Micro-Tek, and Merit/EndoTek and an educator for Boston*

*Scientific, Olympus, and Cook Medical. All other authors disclosed no financial relationships.*

*Abbreviations: ESD, endoscopic submucosal dissection; L-EMR, ligation-assisted endoscopic mucosal resection; LST, laterally spreading tumor; NBI, narrow-band imaging.*

## REFERENCES

- Hwang JH, Konda V, Abu Dayyeh BK, et al. Endoscopic mucosal resection. *Gastrointest Endosc* 2015;82:215-26.
- Chaves DM, Sakai P, Mester M, et al. A new endoscopic technique for the resection of flat polypoid lesions. *Gastrointest Endosc* 1994;40:224-6.
- Fleischer DE, Wang GQ, Dawsey S, et al. Tissue band ligation followed by snare resection (band and snare): a new technique for tissue acquisition in the esophagus. *Gastrointest Endosc* 1996;44:68-72.
- Pouw RE, van Vilsteren FG, Peters FP, et al. Randomized trial on endoscopic resection-cap versus multiband mucosectomy for piecemeal endoscopic resection of early Barrett's neoplasia. *Gastrointest Endosc* 2011;74:35-43.
- Lee J, Park YE, Choi JH, et al. Comparison between cap-assisted and ligation-assisted endoscopic mucosal resection for rectal neuroendocrine tumors. *Ann Gastroenterol* 2020;33:385-90.
- Berkelhammer C, Jasper I, Kirvaitis E, et al. "Band-snare" resection of small rectal carcinoid tumors. *Gastrointest Endosc* 1999;50:582-5.
- The Paris endoscopic classification of superficial neoplastic lesions: esophagus, stomach, and colon: November 30 to December 1, 2002. *Gastrointest Endosc* 2003;58:S3-43.
- Hewett DG, Kaltenbach T, Sano Y, et al. Validation of a simple classification system for endoscopic diagnosis of small colorectal polyps using narrow-band imaging. *Gastroenterology* 2012;143:599-607.e1.
- Kaltenbach T, Anderson JC, Burke CA, et al. Endoscopic removal of colorectal lesions: recommendations by the US multi-society task force on colorectal cancer. *Am J Gastroenterol* 2020;115:435-64.
- Laine L, Kaltenbach T, Barkun A, et al. SCENIC international consensus statement on surveillance and management of dysplasia in inflammatory bowel disease. *Gastrointest Endosc* 2015;81:489-501.e26.

Department of Gastroenterology, Hepatology, and Nutrition, Geisinger Medical Center, Danville, Pennsylvania.

If you would like to chat with an author of this article, you may contact Dr Kichler at [Kichler.Adam@gmail.com](mailto:Kichler.Adam@gmail.com).

Copyright © 2022 American Society for Gastrointestinal Endoscopy. Published by Elsevier Inc. This is an open access article under the CC BY-NC-ND license (<http://creativecommons.org/licenses/by-nc-nd/4.0/>).

<https://doi.org/10.1016/j.vgie.2021.10.010>

### Submit to *VideoGIE*

*VideoGIE* is now indexed in PubMed Central.

*VideoGIE* is an Open Access, online-only journal indexed in PubMed Central. Submit video cases of endoscopic procedures used in the study, diagnosis, and treatment of digestive diseases.

*VideoGIE* publishes the following article types:

- **Case Reports:** Reports of the diagnosis and management of digestive diseases using a single case.
- **Case Series:** Reports of the diagnosis and management of digestive diseases using 3 or more cases.
- **Tools and Techniques:** Educational videos demonstrating the use of a particular endoscopic tool or technique. The goal of this section is to help trainees, endoscopy nurses, and technicians learn how best to use the tools of endoscopy for high-quality care.

All manuscripts must be submitted online at <http://www.editorialmanager.com/vgie>