

## Early outcomes of 21-gauge needle-guided *ab interno* tube sulcus placement of a non-valved implant in pseudophakic eyes

Devendra Maheshwari, Sanjana Rao, Neelam Pawar<sup>1</sup>, Mohideen A Kadar, Rengappa Ramakrishnan

We report the early outcomes and describe an *ab interno* 21-G needle technique of sulcus placement of the Aurolab aqueous drainage implant (AADI) tube in nine pseudophakic eyes. IOP reduced from a preoperative mean (SD) of 28.33 (9.80) to 11.56 (2.65) mm Hg and the mean (SD) number of preoperative medications reduced from 3.0 (0.7) to 0.4 (0.9) at 3 months. There were no intraoperative complications noted. This technique of sulcus placement of the AADI tube is a precise technique of tube insertion. It may be an alternative to existing *ab externo* procedures of tube sulcus placement, limiting multiple blind entries.

**Key words:** AADI tube, *ab interno*, non-valve implant, pseudophakia, sulcus

Video Available on:  
www.ijo.in

Access this article online

Website:  
www.ijo.in

DOI:  
10.4103/ijo.IJO\_2303\_21

Quick Response Code:



Glaucoma drainage devices (GDD) have attained popularity as the procedure of choice in refractory glaucomas.<sup>[1]</sup> The Aurolab aqueous drainage device implant (AADI; Aurolab, Madurai, India) is a newer non-valved GDD derived from the Baerveldt prototype, which has demonstrated good long-term control of intraocular pressure (IOP).<sup>[1]</sup>

The most significant long-term complication of tube shunt insertion into the anterior chamber is corneal endothelial damage.<sup>[2,3]</sup> Tube insertion into the ciliary sulcus and vitreous cavity<sup>[2,3]</sup> have been increasingly performed to evade this complication.

Accurate placement of the tube in the sulcus is technically challenging, requiring multiple attempts to achieve precise tube location. To overcome the potential risks of damage to the iris, zonules, capsule, intraocular lens, and inadvertent insertion into the vitreous cavity,<sup>[4]</sup> *ab interno* methods of tube sulcus insertion have been described.<sup>[5-7]</sup> However, there is a paucity of information regarding the outcomes of this technique in Indian eyes and combined cataract surgery. Thus, we describe the initial outcomes of this technique in Indian eyes by using the AADI implant.

### Methods

This case series was conducted after getting approval from the institute's review board. The charts of patients more than 16 years of age undergoing AADI insertion in the posterior chamber sulcus by the new technique and with at least 3 months of follow-up between July 2019 and January 2020 were reviewed. All patients with pseudophakia or those who underwent cataract extraction and intraocular lens placement at the time of the AADI implantation were included in the study. Patients were selected for AADI surgery based on uncontrolled intraocular pressure (IOP) after maximally tolerated medical treatment. Informed consent was taken for all patients. Primary AADI implantation with or without combining phacoemulsification with intraocular lens implantation was carried out. A single experienced surgeon sitting superotemporally performed all the procedures.

### Surgical Technique

A 350 mm<sup>2</sup> Aurolab aqueous drainage implant (AADI; Aurolab, Madurai, India) was used for the procedure. Following peribulbar anesthesia, a fornix-based conjunctival peritomy was created in the superotemporal quadrant. Tenon's capsule

Departments of Glaucoma and <sup>1</sup>Paediatric Ophthalmology and Strabismus, Aravind Eye Hospital and Post-Graduate Institute of Ophthalmology, Tirunelveli, Tamil Nadu, India

**Correspondence to:** Dr. Devendra Maheshwari, Department of Glaucoma, Aravind Eye Hospital and Post-Graduate Institute of Ophthalmology, Tirunelveli - 627 001, Tamil Nadu, India. E-mail: drdevmaheshwari@gmail.com

Received: 08-Sep-2021

Revision: 24-Oct-2021

Accepted: 02-Nov-2021

Published: 25-Feb-2022

This is an open access journal, and articles are distributed under the terms of the Creative Commons Attribution-NonCommercial-ShareAlike 4.0 License, which allows others to remix, tweak, and build upon the work non-commercially, as long as appropriate credit is given and the new creations are licensed under the identical terms.

**For reprints contact:** WKHLRPMedknow\_reprints@wolterskluwer.com

**Cite this article as:** Maheshwari D, Rao S, Pawar N, Kadar MA, Ramakrishnan R. Early outcomes of 21-gauge needle-guided *ab interno* tube sulcus placement of a non-valved implant in pseudophakic eyes. Indian J Ophthalmol 2022;70:1051-3.

was dissected to expose the underlying sclera. The superior and lateral recti muscles were isolated, and the lateral expansions of the AADI device were placed beneath adjacent muscle bellies. The plate of the implant was then anchored to the sclera 9–10 mm posterior to the limbus by using two interrupted sutures of 8-0 nylon (monofilament polyamide black, Ethilon; Ethicon, Johnson & Johnson, India) through the fixation holes. The tube was then placed under the conjunctival flap. Phacoemulsification was carried out as indicated after securing the plate via a temporal clear corneal section. A foldable Posterior chamber intraocular lens (PCIOL) was implanted in the bag and the section was sutured with 10-0 nylon (monofilament polyamide black, Ethilon; Ethicon, Johnson & Johnson, India). The implant was primed using balanced salt solution, and the absence of flow through the tube was confirmed by irrigation of balanced salt solution into the tube via a 27-G cannula. The tube was then trimmed in a bevel-up fashion to have an intraocular segment of approximately 4 mm. It was then occluded tightly near tube plate junction by using two 6-0 vicryl sutures (Braided-coated polyglactin 910 violet, Ethicon, Johnson & Johnson, India). A rectangular scleral flap with dimensions 4 × 4 mm was made and raised. Based on the intended site of implantation, using an *ab interno* approach, a bent 21-G vein needle (Infusion set -Type 500, JMS Singapore Pte Ltd) was used to make an entry into the anterior chamber through the opposite limbus via an inferior paracentesis [Fig. 1 and Video 1]. The needle was directed to the sulcus by crossing the pupil entering the plane under the iris, remaining parallel to it, and emerging out through the bed of the scleral flap 2–2.5 mm from the limbus tunnel partially. The anterior chamber was well-formed using highly cohesive viscoelastic throughout the procedure. Through the exposed hollow end of the bevel of the needle (diameter: 800 microns), the tube (external diameter: 640 microns) was then inserted so as to be accommodated into the hollow bevel and was guided into the sulcus by withdrawing the needle along the direction of its insertion. The scleral flap was sutured with four 8-0 vicryl sutures (braided-coated polyglactin 910 violet, Ethicon, Johnson & Johnson, India). The conjunctiva was then closed with the same 8-0 vicryl suture (braided-coated polyglactin 910 violet, Ethicon, Johnson & Johnson, India) in a continuous fashion.

There was no intraoperative bleeding noted. There were also no complications encountered during the steps of AADI plate fixation, phacoemulsification or tube implantation.

**Results**

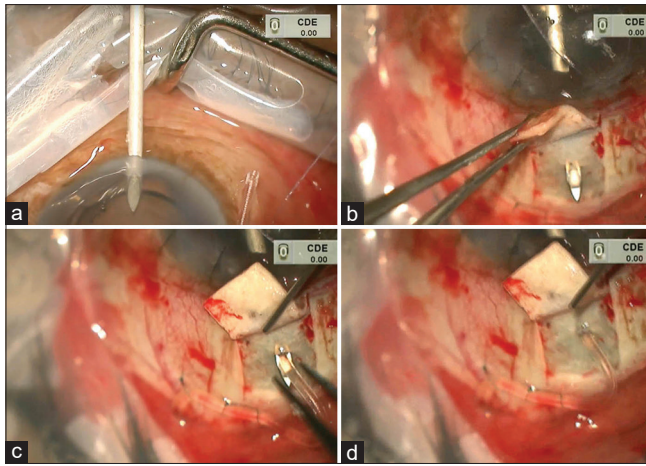
Nine eyes of nine patients of mean age 57.22 ± 7.85 years (range: 45–66) who underwent the new surgical procedure within the study period met the entry criteria and were included. The mean follow-up period was 3.90 ± 0.97 months (range: 3.07–6.17). Male: female ratio was 7:2. The Pre-operative and Post-operative parameters are as described in Table 1. The IOP reduced from a preoperative mean of 28.2 ± 9.80 mm Hg to a postoperative mean of 11.56 ± 2.65 mm Hg (*P* = 0.001). All the patients had IOP controlled successfully. The mean number of preoperative medications for IOP control reduced from 3.0 ± 0.7 to 0.4 ± 0.9 (*P* < 0.05) at the end of the follow-up period. There was an improvement in visual acuity noted from a median preoperative logMAR of 0.60 (IQR: 0.30–1.30) to a median logMAR of 0.48 (IQR: 0.30–1.00) at the last follow-up visit.

There were no intraoperative complications. Postoperatively, two patients (22%) had choroidal detachments at 2 weeks. Although patient 9 [Table 1] subsided with conservative

**Table 1: Preoperative and postoperative parameters of AADI tube sulcus patients**

Case number	Age (Years)	Gender	Glaucoma Diagnosis	Preoperative lens status	Preoperative IOP (mm Hg)	No: Preoperative AGM	Surgical procedure	Postoperative IOP at 3 months (mm Hg)	No: Post op AGM	Complication
1	60	M	NVG	Immature cataract	39	4	Phaco + IOL + AADI	11	nil	nil
2	50	M	ICE syndrome	Immature cataract	30	3	Phaco + IOL + AADI	6	nil	nil
3	48	M	Glaucoma post RD surgery	Pseudophakia	11	3	AADI implantation	12	nil	nil
4	65	F	PACG	Pseudophakia	37	2	AADI implantation	14	nil	nil
5	65	M	NVG	Immature cataract	26	3	Phaco + IOL + AADI	9	nil	Choroidal detachment + vitreous hemorrhage (post trauma)
6	58	F	POAG	Pseudophakia	19	4	AADI implantation	14	2	nil
7	58	M	NVG	Immature cataract	39	4	Phaco + IOL + AADI	18	nil	nil
8	66	M	PXFG	Pseudophakia	31	2	AADI implantation	12	nil	nil
9	45	M	PACG	Pseudophakia	40	3	AADI implantation	12	nil	Choroidal detachment

NVG: Neovascular glaucoma, PXFG: Pseudoexfoliation glaucoma AGM: Antiglaucoma medication, Phaco: Phacoemulsification, AADI: Aurolab aqueous drainage implant, RD: Retinal detachment, ICE: Iridocorneal endothelial syndrome, AGM: Antiglaucoma medication, nil: No complication



**Figure 1:** Intraoperative picture showing steps of the *ab interno* method of tube placement: (a) 21-G needle being inserted using an *ab interno* approach through a limbal paracentesis. (b) Needle exiting the scleral bed partially. (c) AADI tube inserted through the hollow end of a 21-G vein needle. (d) Needle the withdrawn to position tube into the sulcus

management, patient 5 required anterior chamber reformation with peripheral anterior synechiae release and tube repositioning owing to inadvertent blunt trauma.

## Discussion

Tube placement in the ciliary sulcus has been reported to be a safe and effective procedure offering adequate IOP reduction and reduced endothelial cell loss.<sup>[8,9]</sup>

The *ab externo* technique of tube sulcus implantation using a 23-G needle directed toward the ciliary sulcus 1.5–2 mm from the limbus has been commonly performed.<sup>[8,9]</sup>

Camejo *et al.*<sup>[5]</sup> first described an *ab interno* 23-G needle insertion followed by conventional *ab externo* tube insertion into the sulcus. Waldo *et al.*<sup>[6]</sup> in their case series demonstrated an *ab interno* technique similar to ours by using the hollow end of a 21-G needle as a guide for the tube. Compared to ours, their series<sup>[6]</sup> included a relatively younger age group with previous glaucoma surgical procedures. While Ahmed valve implantation was carried out in their study,<sup>[6]</sup> we used the AADI implant. While there were no significant postoperative complications reported in their series, we noted two postoperative choroidal detachments in, with one having an additional vitreous hemorrhage owing to blunt injury.

Moreno-Montañés *et al.*<sup>[7]</sup> also described a technique of tube sulcus placement by using a Prolene suture as a guide through the hollow end of a 23-G needle.

Owing to the large needle size, we anticipated potential iris incarceration and hypotony due to peritubal leakage. However, this was not seen in our series or by the other authors.<sup>[6]</sup> An adequate fill of the anterior chamber with a highly cohesive viscoelastic agent and making a partial rather than a complete exit of the needle could have prevented these. Moreover, we did not encounter any intraoperative bleeding by ensuring that the needle insertion site was not too posterior.

A longer tube length also may facilitate tube visualization through a small pupil following placement in the sulcus.

Our initial outcomes suggest reasonably good IOP control in Indian pseudophakic eyes, making it amenable for combining with phacoemulsification. This technique also ensures accurate

tube placement in the sulcus by controlled withdrawal of the needle, obviating the need for multiple entry attempts. The specific 21-G vein needle from the IV set differed from a regular 21-G needle by having a shorter, less sharp bevel thereby limiting damage to the tube. For needle-guided tube placement, we advocate a 21-G needle having a larger outer diameter (0.8 mm) rather than a 23-G needle as the outer diameter (0.64 mm) coincides with the outer diameter of the tube risking trauma to the same. A significant decrease in IOP and number of glaucoma medications was noted in our study comparable to others.<sup>[6]</sup>

This is by far the largest case series describing the initial outcomes of the 21-G needle method of *ab interno* tube sulcus insertion, adapting the technique described by Waldo *et al.*<sup>[6]</sup> in a non-valved (AADI) implant. We also report the outcomes of combining phacoemulsification with this method, which has not been previously described. Despite not having encountered iritis and postoperative hypotony in our series, these potential complications are to be anticipated owing to the larger needle size.

Limitations of this series include, its retrospective nature, small sample size, limited follow-up and lack of corneal endothelial counts prior to the procedure. The effectiveness of this implantation technique could also be better substantiated if compared with the conventional method.

## Conclusion

In conclusion, the *ab interno* technique of sulcus placement of the AADI tube is a precise technique of tube insertion. It may be an alternative to existing *ab externo* procedures of tube sulcus insertion, limiting multiple blind entries.

## Financial support and sponsorship

Nil.

## Conflicts of interest

There are no conflicts of interest.

## References

1. Puthuran GV, Palmberg PF, Wijesinghe HK, Pallamparthy S, Krishnadas SR, Robin AL. Intermediate-term outcomes of an affordable aqueous drainage implant in adults with refractory glaucoma. *Ophthalmol Glaucoma* 2019;2:258-66.
2. Gedde SJ, Schiffman JC, Feuer WJ, Herndon LW, Brandt JD, Budenz DL, *et al.* Three-year follow-up of the tube versus trabeculectomy study. *Am J Ophthalmol* 2009;148:670-84.
3. Sidoti PA, Mosny AY, Ritterband DC, Seedor JA. Pars plana tube insertion of glaucoma drainage implants and penetrating keratoplasty in patients with coexisting glaucoma and corneal disease. *Ophthalmology* 2001;108:1050-8.
4. Kasuga T, Asaoka S, Asada Y, Iwamoto S, Hirakata T, Honda R, *et al.* Prolene-assisted tube insertion through sulcus in Ahmed valve. *J Glaucoma* 2020;29:e106-7.
5. Camejo L, Noecker R. Ab interno sulcus placement of glaucoma tube implants. *Ophthalmic Surg Lasers Imaging* 2008;39:434-5.
6. Waldo LG, Vladimir MR, Vanessa IC, Vanessa VA, Rosa AV, Alejandro VD. Needle guided ab interno technique for tube insertion through the ciliary sulcus in uncontrolled glaucoma. *Eur J Ophthalmol* 2021;11206721211007093. doi: 10.1177/11206721211007093.
7. Moreno-Montañés J, Guirao-Navarro C, Argüeso F. Ab interno implantation of glaucoma drainage devices tubes in the posterior chamber. *BMC Ophthalmol* 20;2020:66.
8. Tello C, Espana EM, Mora R, Dorairaj S, Liebmann JM, Ritch R. Baerveldt glaucoma implant insertion in the posterior chamber sulcus. *Br J Ophthalmol* 2007;91:739-42.
9. Weiner A, Cohn AD, Balasubramaniam M, Weiner AJ. Glaucoma tube shunt implantation through the ciliary sulcus in pseudophakic eyes with high risk of corneal decompensation. *J Glaucoma* 2010;19:405-11.