

Fragmentation of central venous catheter - A rare but dreaded complication

Sir,

A rare but dreaded complication of central venous catheters (CVCs) is a retained fractured segment.^[1] The embolised fragment can lead to catheter malfunction, arrhythmia, pulmonary symptoms, thrombosis, vessel stenosis, infections and sepsis, but most of the cases remain asymptomatic.^[2]

A 38-year-old lady with new-onset diabetes mellitus and a history of recurrent oligo-astrocytoma was scheduled for an awake craniotomy and excision of the residual lesion. After pre-operative workup and adequate glycaemic control, she was taken up for the procedure.

Inside the operation theatre, after standard pre-induction monitors were attached, the left radial artery was cannulated and the right internal jugular vein was catheterised using a 7 French triple lumen CVC under ultrasound guidance and adequate local anaesthetic skin infiltration. After backflow of blood was confirmed in all three lumens, the catheter was secured to the skin with 3-0 non-absorbable monofilament nylon sutures. Throughout the surgery, the patient was haemodynamically stable with sinus rhythm.

Examination of the routine chest radiogram taken in the immediate postoperative period confirmed that the tip of the CVC was in the right atrium.

On the first post-operative day, the patient complained of irritation at the suture site of CVC. On removing the Tegaderm™ dressing for better inspection of the site, the catheter was found to be detached from the flanges but could not be located subcutaneously. During this

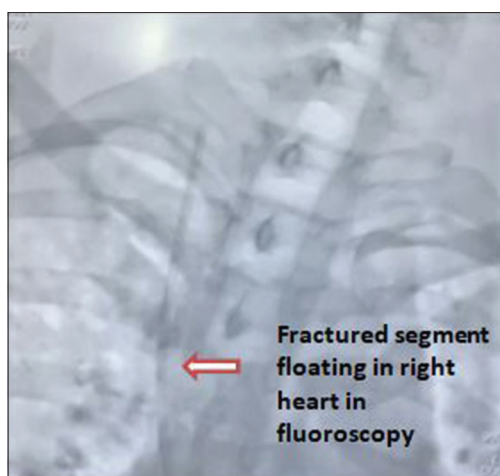


Figure 1: Fluoroscopy showing the fragmented catheter in the right heart

time also, the patient was haemodynamically stable, albeit anxious. A cardiology consultation was done, and a decision to retrieve the catheter tip through the right femoral vein was made. After taking informed consent, the patient was shifted to the Cath lab and fluoroscopy showed that the distal part of the catheter from the flanges was cut and dislodged into the right heart [Figure 1].

Under image intensifier guidance, a 15-mm Amplatz Goose Neck® snare was inserted through the right femoral vein and the fragment was removed from the right ventricle [Figure 2]. Post procedure, the patient was haemodynamically stable. She was observed in the intensive care unit for a day and shifted to the ward in a stable condition.

Central venous catheterisation, being an invasive procedure, is associated with several risks such as haematoma, pneumothorax, infections, arrhythmias, malposition, thrombosis and trauma to brachial plexus.^[3] Nevertheless, the coronavirus disease (COVID)-19 pandemic saw an increase in the number of central venous cannulations, especially in those with post-COVID-19 mucormycosis.^[4] Wearing personal protective equipment while doing central venous cannulation increases the chances of complications.^[5]

Fractured catheter is an infrequent but dangerous complication accounting for less than 0.1%. Fragmentation of the catheter may be caused either by mechanical shearing stress or the use of excessive force while inserting or removing the catheter. In this case, the fragmentation might have been due to

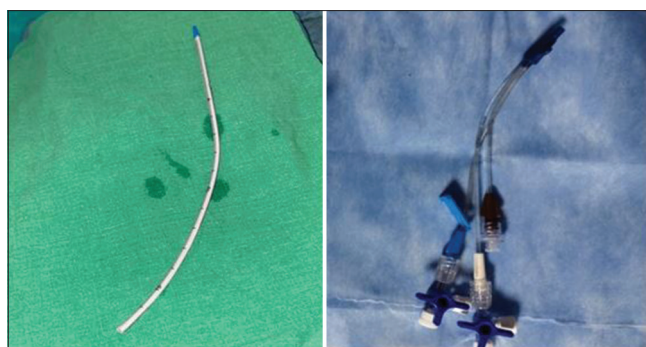


Figure 2: The retrieved catheter tip (left) and the fractured flanges (right)

a manufacturing defect. The fragmented catheter may migrate and lodge in the vena cavae, right atrium, right ventricle, pulmonary artery and the distal branches^[6] and lead to complications such as catheter occlusion, cardiovascular or pulmonary compromise, cardiac arrest or sudden death.^[1]

A fragmented intravascular device can be retrieved either through conventional open thoracotomy or minimally invasive percutaneous endovascular approach, the latter leading to a faster recovery and an overall reduction in morbidity and mortality.^[1] These techniques use various percutaneous equipment such as snares, tip deflecting wires and baskets for foreign body retrieval.^[7] The most popular among these is the snare, which kinks less owing to its elastic manufacturing. Rarely, thoracotomy is required when both ends of the catheter are either fixed or entrapped, which makes it impossible to grasp. Endovascular retrieval, although requiring adequate facility and expertise, is a safe and feasible option.

The manufacturer was informed about this complication, and all the remaining catheters were returned. They replied that they would analyse and rectify the defect.

Declaration of patient consent

The authors certify that they have obtained all appropriate patient consent forms. In the form, the patient has given her consent for her images and other clinical information to be reported in the journal. The patient understands that her name and initials will not be published and due efforts will be made to conceal identity, but anonymity cannot be guaranteed.

Financial support and sponsorship

Nil.

Conflicts of interest

There are no conflicts of interest.

**Gokuldas Menon, Riya Ann Jacob,
Devi Padmakumar, Mathew George**

Department of Anaesthesiology and Critical Care, Amrita Institute of Medical Sciences, Amrita Vishwa Vidyapeetham, Kochi, Kerala, India

Address for correspondence:

Dr. Gokuldas Menon,
Department of Anaesthesiology and Critical Care, Amrita Institute
of Medical Sciences, Amrita Vishwa Vidyapeetham, Kochi,
Kerala - 682 041, India.
E-mail: gokuldas75@hotmail.com

Submitted: 30-Apr-2021

Revised: 13-May-2021

Accepted: 31-Oct-2021

Published: 20-Apr-2022

REFERENCES

1. Surov A, Wienke A, Carter JM, Stoevesandt D, Behrmann C, Spielmann R-P, *et al.* Intravascular embolization of venous catheter -- Causes, clinical signs and management: A systematic review. *J Parenter Enteral Nutr* 2009;33:677-85.
2. Colón-Casasnovas N, Lugo-Vicente H. Distal fragmented port catheter: Case report and review of literature. *Bol Asoc Med P R* 2008;100:70-5.
3. Katiyar S, Jain RK. Entrapped central venous catheter guide wire. *Indian J Anaesth* 2010;54:354-5.
4. Gupta KK, Singh A, Kalia A, Kandhola R. Anaesthetic considerations for post-COVID-19 mucormycosis surgery- A case report and review of literature. *Indian J Anaesth* 2021;65:545-7.
5. Ahmad SR, Bellapukonda S, Mohanty CR, Tapuria P. External jugular vein cannulation – A double-edged sword. *Indian J Anaesth* 2021;65:173-4.
6. Dell'Amore A, Ammari C, Campisi A, D'Andrea R. Peripheral venous catheter fracture with embolism into the pulmonary artery. *J Thorac Dis* 2016;8:E1581-4.
7. Wadehra A, Ganjoo P, Tandon S. Guide wire loss during central venous cannulation. *Indian J Anaesth* 2010;54:587-8.

This is an open access journal, and articles are distributed under the terms of the Creative Commons Attribution-NonCommercial-ShareAlike 4.0 License, which allows others to remix, tweak, and build upon the work non-commercially, as long as appropriate credit is given and the new creations are licensed under the identical terms.

Access this article online	
Quick response code	Website: www.ijaweb.org
	DOI: 10.4103/ija.ija_379_21

How to cite this article: Menon G, Jacob RA, Padmakumar D, George M. Fragmentation of central venous catheter - A rare but dreaded complication. *Indian J Anaesth* 2022;66:309-11.

© 2022 Indian Journal of Anaesthesia | Published by Wolters Kluwer - Medknow