



Ulnar Collateral Ligament Repair With Suture Bridge Augmentation

Ekaterina Urch, M.D., Anthony DeGiacomo, M.D., Christos D. Photopoulos, M.D., Orr Limpisvasti, M.D., and Neal S. ElAttrache, M.D.

Abstract: The gold standard for management of elbow ulnar collateral ligament (UCL) injuries in elite athletes is reconstruction of the UCL with a tendon graft. Over the past several years, UCL repair for acute tears, as well as partial tears, in young athletes has gained increasing popularity, with studies reporting good outcomes and high rates of return to sports. Additionally, there is increased interest in ligament augmentation using the InternalBrace concept. A recent technique paper describes a direct repair of the UCL augmented with a spanning suture bridge. Although clinical outcomes for this method are promising, one possible concern when using this technique is bone loss at the ulnar origin of the UCL should revision reconstruction be required. We propose an alternative augmentation method that allows for stress shielding of the healing native ligament while minimizing bone compromise in the face of UCL reconstruction at a later time point.

Elbow ulnar collateral ligament reconstruction (UCLR), or the “Tommy John surgery,” was originally popularized by Dr. Frank Jobe in 1986.¹ Since then, UCLR with a tendon graft has remained the gold standard for managing these injuries.² Recently, studies have reported an increase in frequency of these injuries in athletes at all levels of competition, with as many as 25% of major league and 15% of minor league pitchers having the procedure.³⁻⁵ The reported average age range of patients undergoing this procedure has been found to be between 15 and 19 years, suggesting that younger athletes are at increasing risk.⁶ UCLR exposes these young pitchers to the risk of bone loss, fracture, or other complications requiring revision surgery. Indeed, recent literature has reported revision rates ranging

from 3.9% to as high as 15% in professional pitchers.^{7,8} Although primary UCLR can be expected to produce excellent results, the success of revision UCLR is significantly lower, with studies reporting return-to-sport rates ranging from only 33% to 65%.^{9,10}

Over the past years, UCL repair for acute as well as partial tears in young athletes has gained increasing popularity, with studies reporting good outcomes and return to sport rates in this patient cohort.^{11,12} With the introduction of the InternalBrace (Arthrex, Naples, FL) repair construct and its increasing popularity in the foot, ankle, and even anterior cruciate ligament literature, it was only a matter of time before this concept was applied to the elbow.^{13,14} A recent technique paper describes an “internal bracing” method that includes direct repair of the ligament augmented by a spanning suture tape fixated with 2 3.5-mm anchors at the proximal and distal insertion points.¹⁵ Although early clinical outcomes for this method are promising, one concern for this technique is the resultant bone loss that occurs at the center of the sublime tubercle when an anchor is placed centrally in the ulnar footprint. This may lead to a significant handicap should revision to the UCL be necessary in the future.

In this technique article, we present an alternative fixation construct that uses 2 smaller anchors to assist with ligament repair as the injured native ligament heals. We feel this modified construct will provide

From the Kerlan-Jobe Orthopaedic Clinic, Los Angeles, California, U.S.A. The authors report the following potential conflicts of interest or sources of funding: O.L. reports personal fees from Arthrex and personal fees from ConMed Linvatec outside the submitted work. Full ICMJE author disclosure forms are available for this article online, as [supplementary material](#).

Received August 14, 2017; accepted August 28, 2017.

Address correspondence to Ekaterina Urch, M.D., Kerlan-Jobe Orthopaedic Clinic, 6801 Park Terrace Drive, Los Angeles, CA 90045, U.S.A. E-mail: urchmd@gmail.com

© 2017 by the Arthroscopy Association of North America. Published by Elsevier. This is an open access article under the CC BY-NC-ND license (<http://creativecommons.org/licenses/by-nc-nd/4.0/>).

2212-6287/17982

<https://doi.org/10.1016/j.eats.2017.08.080>

Table 1. Pearls and Pitfalls for Ulnar Collateral Ligament (UCL) Repair With Internal Bracing

Key Points of the Surgical Technique
Use of sterile tourniquet to allow for optimal exposure of surgical site.
Identification and protection of the medial antebrachial cutaneous and ulnar nerves is paramount.
Releasing the medial intermuscular septum off of its attachment on the medial epicondyle to improve exposure.
Meticulous dissection of the UCL off of the ulnar footprint to preserve robust ligament tissue for repair.
Alternating drill trajectories for ulnar tunnels to ensure divergent anchor placement and preservation of bony bridge.
Identifying the center of humeral footprint and ensuring drill trajectory is collinear with epicondylar axis.
Performing the distal UCL repair after drilling humeral anchor site to facilitate visualization.
Docking the proximal anchor with the arm held in 60° of flexion and a gentle varus force applied.

stability to the elbow and shield the ligament from high stresses as it heals, while minimally impacting the osseous integrity of the sublime tubercle.

Surgical Technique

The key points of the technique are summarized in [Table 1](#), and the technique is demonstrated in [Video 1](#).

Patient Positioning and Setup

The patient is positioned supine with the operative extremity on a hand table attachment. General endotracheal anesthesia is used without regional blockade of the brachial plexus. This is done to allow for accurate postoperative evaluation of ulnar nerve function. After standard preparation and drape, the entire operative arm, up to but excluding the axilla, is draped into the surgical field. A sterile tourniquet can be used to allow maximum exposure of the surgical site. The operating surgeon sits on the ulnar side of the arm, with the first assistant sitting directly across from him or her. A second assist may be positioned at the end of the hand table.

Exposure of the UCL

A 10-cm curvilinear incision, centered over the medial epicondyle, is made spanning from the distal portion of the intramuscular septum to 2 cm distal to the sublime tubercle. Dissection is carried out through the subcutaneous tissue using Metzenbaum scissors. Care is taken to identify and preserve the branches of the medial antebrachial cutaneous nerve. The deep dissection is continued anteriorly and posteriorly over the medial epicondyle. The apex of the medial epicondyle is located, and electrocautery is used to mark the center of the insertion of the UCL. This is located roughly 3 mm anterior to the apex of the epicondyle. The sublime tubercle is palpated distally, and the fascia overlying the flexor pronator mass is incised

longitudinally in line with the identified 2 points. A small periosteal elevator is used to bluntly split the deep muscle fibers, exposing the underlying UCL. The ulnar nerve runs at the posterior border of the UCL in this location. Care is taken to dissect the nerve off of the UCL, freeing up its anterior edge. This allows safe retraction of the nerve when exposing the ligament's entire footprint on the sublime tubercle. The ulnar nerve is protected throughout the entire procedure. If there is clinical evidence of ulnar nerve compression, the nerve is circumferentially released and transposed.

Ligament Repair and Augmentation

The distal insertion of the UCL is identified at the sublime tubercle and sharply incised in line with its fibers directly over the center of the ligament footprint. The UCL is then elevated sharply off of the footprint, creating 2 separate flaps (anterior and posterior) of robust tissue to be used for later repair. The starting points for the anterior and posterior tunnels are identified 5 mm distal to the joint line, as originally described by Jobe, and marked with a marking pen.¹ Two divergent tunnels are drilled at the marked spots using a 2.9-mm drill and 12.5-mm drill sleeve ([Fig 1](#)). A 55° V-drill guide (Arthrex) is used to facilitate the identification of the starting point and to ensure a robust bone bridge between the anchors. Care is taken to avoid penetrating the articular surface of the ulna when drilling the tunnels. Two short 2.9 mm × 12.5 mm PushLock anchors (Arthrex) are used for the distal repair. The posterior anchor is loaded with 2 2-0 FiberWire sutures and one 1.3-mm




Fig 1. A sawbones model of the medial elbow (proximal is to the right of the image, anterior is at the top of the image). The image demonstrates the position of the 2 ulnar drill holes for the divergent anchor tunnels. The tunnels are drilled using a 2.9-mm drill. A drill guide with a 12.5-mm stop is used to ensure the tunnels are appropriate length. Most importantly, the drill holes are positioned in the same location as where tunnels would be drilled for a reconstruction.

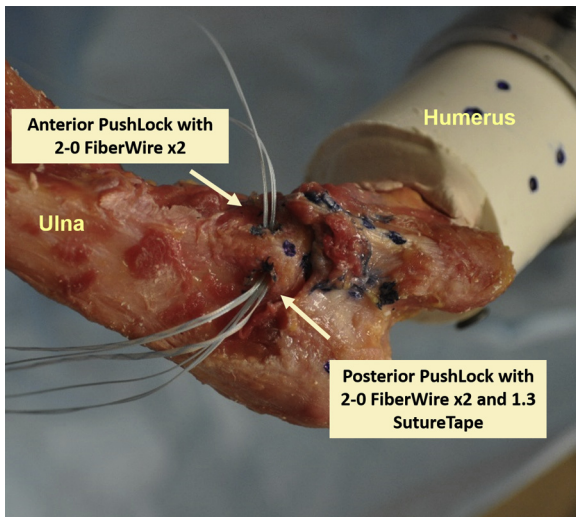


Fig 2. Cadaveric right elbow model demonstrating positioning of the 2 ulnar anchors. The anterior (top) anchor is loaded with 2 FiberWire sutures, while the posterior (bottom) anchor is loaded with 2 FiberWire sutures and a single SutureTape suture. Distal repair of the ulnar collateral ligament will be performed using the FiberWire sutures in the 2 anchors. The SutureTape will be used to bridge the ligament for augmentation.

SutureTape (Arthrex). The anterior anchor is loaded with 2 2-0 FiberWire sutures alone (Fig 2).

In preparation for the distal repair of the UCL, 2 limbs of FiberWire from each anchor are passed through the split edges of the UCL (e.g., FiberWires from the anterior anchor are passed through the anterior edge of the UCL, etc.). The remaining 4 FiberWire limbs are passed in a similar fashion but more peripherally from the central split in order to incorporate a more substantial

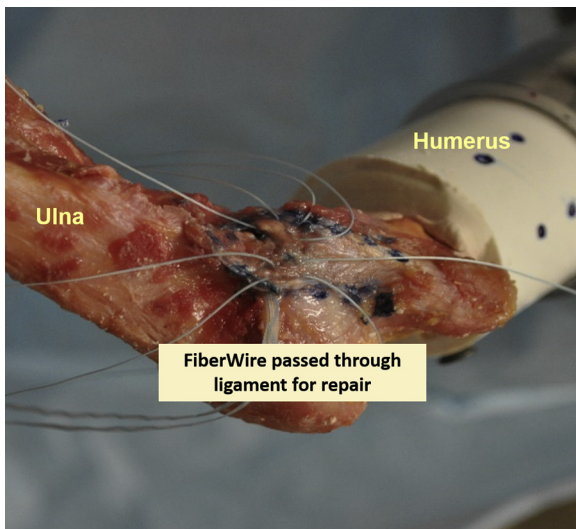


Fig 3. Cadaveric right elbow model demonstrating the distal ligament repair. The FiberWire sutures from each anchor are passed through the torn ligament in preparation for repair. The SutureTape (seen at the inferior border of the ligament) is left free for bridging of the entire ligament.

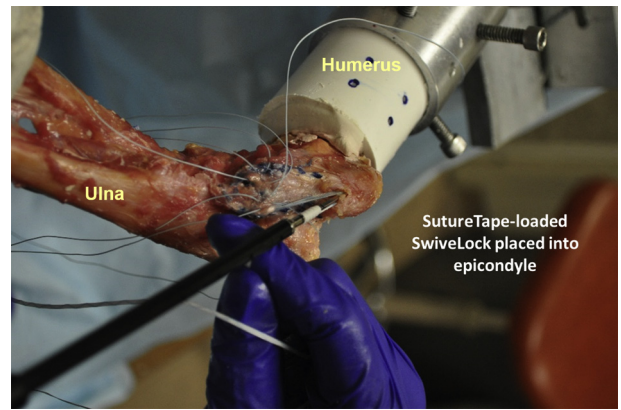


Fig 4. Cadaveric right elbow model demonstrating placement of the humeral anchor to complete the suture bridge augmentation. A SwiveLock anchor is loaded with the SutureTape from the posterior ulnar anchor and seated into the medial epicondyle to complete the ligament augmentation construct.

portion of the UCL. The final construct appears as a double-row suture construct on each side of the split ligament (Fig 3). The sutures are left untied to optimize visualization while preparing the humeral footprint.

The humeral footprint of the UCL is identified on the inferior surface of the medial epicondyle, and the center of the footprint is split with a scalpel to expose the underlying bone. Careful deliberation is used for positioning the anchor directly in the middle of the native footprint with a trajectory in line with the epicondylar axis. A 3.5-mm drill bit and corresponding drill guide are used to make a 16-mm tunnel in the medial epicondyle, taking care to avoid posterior cortical blowout. A 3.5 mm tap is used to prepare the tunnel for anchor insertion.

Attention is now turned back to the distal repair of the UCL. The elbow is held in 60° of flexion, and a

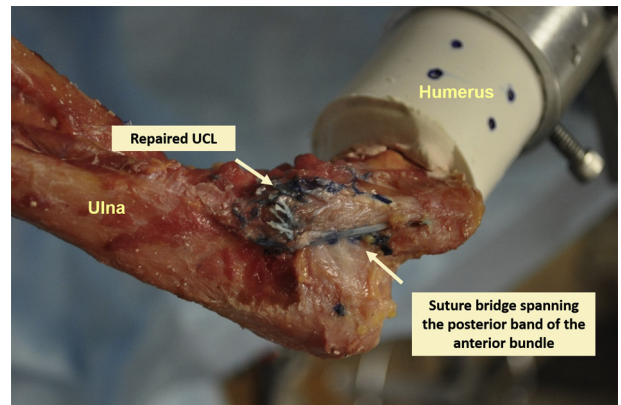


Fig 5. Cadaveric right elbow model demonstrating the final augmented repair. The FiberWire sutures have been tied down distally to repair the ligament. The SutureTape is seen spanning the posterior border of the anterior bundle of the ligament, running from the posterior ulnar anchor to the humeral medial epicondyle.

gentle varus force is applied to reduce the joint. The 2 peripheral FiberWire limbs are tied to each other in a simple fashion (e.g., anterior-proximal limb to anterior-distal limb, posterior-proximal limb to posterior-distal limb) to reduce the ligament down to the footprint. The 2 central rows of FiberWire sutures are then tied in a crossing pattern over the central split to repair the longitudinal split and reinforce the construct.

Finally, the 1.3-mm SutureTape from the posterior PushLock anchor is loaded into a 3.5 mm × 15.8 mm SwiveLock anchor (Arthrex). The ulnohumeral joint is held reduced in 60° of flexion with a gentle varus stress and, after confirming isometry of the construct, the anchor is seated into the humeral tunnel (Fig 4). The longitudinal split of the ligament is then repaired with simple stitches using 2-0 FiberWire suture (Fig 5). Following wound closure, the arm is placed in a well-padded posterior splint with the elbow held in 90° of flexion and neutral rotation.

Discussion

The UCL repair construct presented in this article carries the advantages of protecting the native UCL as it heals while preserving the bony integrity of the center of the sublime tubercle as this is often a later location for UCLR tunnels. This procedure is best applied to patients with acute avulsion injuries of the UCL from its distal insertion on the ulna. Our construct places emphasis on reinforcing the posterior band of the anterior oblique bundle with SutureTape because the posterior band is under highest tensile loads at increased angles of elbow flexion.^{16,17} High degrees of elbow flexion in overhead athletes correlate with the late cocking and early acceleration phases of throwing and consequently with the highest stresses experienced by the elbow during the movement.¹⁸ As such, the SutureTape construct provides a protective support for the UCL throughout rehabilitation as the ligament injury heals.

One limitation of this technique is it relies on the integrity of the UCL tissue following injury. In many cases, the ligament has sustained chronic injury over a prolonged period of time, leading to permanent injury and microtrauma throughout the entire ligament.^{1,19} This type of pathology is usually seen in professional and elite athletes after years of throwing.^{1,20} In these patients, primary repair is unlikely to be successful as the native tissue is insufficient to provide appropriate stability to the elbow; in such cases, ligament reconstruction is warranted.

More recently, however, there have been an increasing number of patients sustaining UCL injuries at younger ages, a phenomenon attributed to increasing pitch velocity and the increasing number of games played by these young athletes.^{21,22} UCL injuries in younger pitchers are more likely to be associated with

an acute injury isolated to the distal or proximal portion of the ligament.¹¹ In such cases, the integrity of the tissue remains intact and the ligament is thought to be amenable to primary repair.¹¹ The repair technique discussed in this paper is best applied to these types of injuries, where the ligament is likely to heal.

In conclusion, the modified UCL repair constructed presented in this paper, when applied to the appropriate patient, minimizes the morbidity of the procedure by eliminating the need for graft harvest, retains the bony integrity of the ulnar insertion, and adds internal stability to the ligament as it heals. Furthermore, the presence of the internal suture bridge may allow for faster rehabilitation and earlier return to sports.

References

1. Jobe FW, Stark H, Lombardo SJ. Reconstruction of the ulnar collateral ligament in athletes. *J Bone Joint Surg Am* 1986;68:1158-1163.
2. Chang ES, Dodson CC, Ciccotti MG. Comparison of surgical techniques for ulnar collateral ligament reconstruction in overhead athletes. *J Am Acad Orthop Surg* 2016;24:135-149.
3. Fleisig GS, Andrews JR. Prevention of elbow injuries in youth baseball pitchers. *Sports Health* 2012;4:419-424.
4. DeFroda SF, Kriz PK, Hall AM, Zurakowski D, Fadale PD. Risk stratification for ulnar collateral ligament injury in Major League Baseball players: a retrospective study from 2007 to 2014. *Orthop J Sports Med* 2016;4:2325967115627126.
5. Conte SA, Fleisig GS, Dines JS, et al. Prevalence of ulnar collateral ligament surgery in professional baseball players. *Am J Sports Med* 2015;43:1764-1769.
6. Erickson BJ, Nwachukwu BU, Rosas S, et al. Trends in medial ulnar collateral ligament reconstruction in the United States: a retrospective review of a large private-payer database from 2007 to 2011. *Am J Sports Med* 2015;43:1770-1774.
7. Erickson BJ, Gupta AK, Harris JD, et al. Rate of return to pitching and performance after Tommy John surgery in Major League Baseball pitchers. *Am J Sports Med* 2014;42:536-543.
8. Wilson AT, Pidgeon TS, Morrell NT, DaSilva MF. Trends in revision elbow ulnar collateral ligament reconstruction in professional baseball pitchers. *J Hand Surg Am* 2015;40:2249-2254.
9. Dines JS, Yocum LA, Frank JB, ElAttrache NS, Gambardella RA, Jobe FW. Revision surgery for failed elbow medial collateral ligament reconstruction. *Am J Sports Med* 2008;36:1061-1065.
10. Marshall NE, Keller RA, Lynch JR, Bey MJ, Moutzouros V. Pitching performance and longevity after revision ulnar collateral ligament reconstruction in Major League Baseball pitchers. *Am J Sports Med* 2015;43:1051-1056.
11. Savoie FH 3rd, Trenhaile SW, Roberts J, Field LD, Ramsey JR. Primary repair of ulnar collateral ligament injuries of the elbow in young athletes: a case series of

- injuries to the proximal and distal ends of the ligament. *Am J Sports Med* 2008;36:1066-1072.
12. Richard MJ, Aldridge JM 3rd, Wiesler ER, Ruch DS. Traumatic valgus instability of the elbow: pathoanatomy and results of direct repair. *J Bone Joint Surg Am* 2008;90:2416-2422.
 13. Mackay GM, Blyth MJ, Anthony I, Hopper GP, Ribbans WJ. A review of ligament augmentation with the InternalBrace: the surgical principle is described for the lateral ankle ligament and ACL repair in particular, and a comprehensive review of other surgical applications and techniques is presented. *Surg Technol Int* 2015;26:239-255.
 14. Dugas JR, Walters BL, Beason DP, Fleisig GS, Chronister JE. Biomechanical comparison of ulnar collateral ligament repair with internal bracing versus modified Jobe reconstruction. *Am J Sports Med* 2016;44:735-741.
 15. Dugas JR. Ulnar collateral ligament repair: an old idea with a new wrinkle. *Am J Orthop* 2016;45:124-127.
 16. Callaway GH, Field LD, Deng XH, et al. Biomechanical evaluation of the medial collateral ligament of the elbow. *J Bone Joint Surg Am* 1997;79:1223-1231.
 17. Cohen MS, Bruno RJ. The collateral ligaments of the elbow: anatomy and clinical correlation. *Clin Orthop Relat Res* 2001;383:123-130.
 18. Cain EL Jr, Dugas JR, Wolf RS, Andrews JR. Elbow injuries in throwing athletes: a current concepts review. *Am J Sports Med* 2003;31:621-635.
 19. Conway JE, Jobe FW, Glousman RE, Pink M. Medial instability of the elbow in throwing athletes: treatment by repair or reconstruction of the ulnar collateral ligament. *J Bone Joint Surg Am* 1992;74:67-83.
 20. Cain EL Jr, Andrews JR, Dugas JR, et al. Outcome of ulnar collateral ligament reconstruction of the elbow in 1281 athletes: Results in 743 athletes with minimum 2-year follow-up. *Am J Sports Med* 2010;38:2426-2434.
 21. Erickson BJ, Bach BR Jr, Cohen MS, et al. Ulnar collateral ligament reconstruction: the Rush experience. *Orthop J Sports Med* 2016;4:2325967115626876.
 22. Olsen SJ 2nd, Fleisig GS, Dun S, Loftice J, Andrews JR. Risk factors for shoulder and elbow injuries in adolescent baseball pitchers. *Am J Sports Med* 2006;34:905-912.