

Suture-Only Repair Versus Suture Anchor–Augmented Repair for Achilles Tendon Ruptures With a Short Distal Stump

A Biomechanical Comparison

Michael A. Boin,^{*†} MD, Matthew A. Dorweiler,[†] MD, Christopher J. McMellen,[†] BS, Gregory C. Gould,[†] BS, and Richard T. Laughlin,[†] MD

Investigation performed at the Department of Orthopaedic Surgery, Wright State University, Dayton, Ohio, USA

Background: Chronic noninsertional Achilles tendinosis can result in an acute Achilles tendon rupture with a short distal stump. In such tendon ruptures, there is a limited amount of adequate tissue that can hold suture, thus presenting a challenge for surgeons who elect to treat the rupture operatively.

Hypothesis: Adding suture anchors to the repair construct may result in biomechanically stronger repairs compared with a suture-only technique.

Study Design: Controlled laboratory study.

Methods: Nine paired Achilles-calcaneus complexes were harvested from cadavers. An artificial Achilles rupture was created 2 cm proximal to the insertion on the calcaneus. One specimen from each cadaver was assigned to a suture-only or a suture anchor–augmented repair. The contralateral specimen of the same cadaver received the opposing repair. Cyclic testing was then performed at 10 to 100 N for 2000 cycles, and load-to-failure testing was performed at 0.2 mm/s. This was followed by analysis of repair displacement, gapping at repair site, peak load to failure, and failure mode.

Results: The suture anchor–augmented repair exhibited a 116% lower displacement compared with the suture-only repair (mean \pm SD, 1.54 \pm 1.13 vs 3.33 \pm 1.47 mm, respectively; $P < .03$). The suture anchor–augmented repair also exhibited a 45% greater load to failure compared with the suture-only repair (303.50 \pm 102.81 vs 209.09 \pm 48.12 N, respectively; $P < .04$).

Conclusion: Suture anchor–augmented repairs performed on acute Achilles tendon ruptures with a short distal stump are biomechanically stronger than suture-only repairs.

Clinical Relevance: Our results support the use of suture anchor–augmented repairs for a biomechanically stronger construct in Achilles tendon ruptures with a short distal stump. Biomechanically stronger repairs may lead to less tendon repair gapping and failure, increasing the ability to start early active rehabilitation protocols and thus improving patient outcomes.

Keywords: Achilles rupture; repair; suture anchor; noninsertional Achilles tendinosis

*Address correspondence to Michael A. Boin, MD, 30 East Apple Street, Suite 2200, Dayton, OH 45409, USA (email: michaelboin@gmail.com).

[†]Department of Orthopaedic Surgery, Wright State University, Dayton, Ohio, USA.

One or more of the authors has declared the following potential conflict of interest or source of funding: Arthrex donated the repair materials through the Arthrex Research Grant, and the Miami Valley Hospital Biosciences Center donated the cadaver specimens.

Ethical approval was not sought for the present study.

The Orthopaedic Journal of Sports Medicine, 5(1), 2325967116678722

DOI: 10.1177/2325967116678722

© The Author(s) 2017

There is ample literature regarding acute midsubstance Achilles tendon rupture and the repair techniques. The current literature is lacking in studies that have investigated fixation techniques of Achilles tendon ruptures in patients with chronic noninsertional Achilles tendinosis. Chronic tendinosis can result in acute Achilles tendon rupture with a short distal stump. In such tendon ruptures, there is a limited amount of adequate tissue that can hold suture.

Ruptures can be treated operatively with surgical repair or nonoperatively with cast immobilization. Optimal treatment of Achilles tendon ruptures currently remains a topic of debate.^{10,13,22,23} Operative treatments have been advocated due to their relatively lower rate of rerupture and the

opportunity for early rehabilitation, which may lead to a better functional outcome, including reduced calf muscle atrophy and earlier return to normal activities.⁴

There is recent evidence that early active rehabilitation protocols are critical to minimize postoperative complications and to promote better outcomes.⁸ These programs have also been widely accepted as a means of reducing fatty atrophy of the gastrosoleus complex after Achilles rupture.⁵ However, early rehabilitation can also stress the repair construct and potentially result in gap formation at the repair site. The Achilles tendon has been shown to endure peak forces of greater than 2000 N during normal ambulation and forces of greater than 300 N during ambulation with the ankle immobilized in neutral dorsiflexion.^{7,23} With the increasing popularity of early rehabilitation protocol application, it is essential that repairs be biomechanically strong enough to withstand the gap-forming forces placed on them at earlier stages of healing.

Acute ruptures that leave a short distal stump may make it difficult to achieve secure tissue fixation using traditional end-to-end suture methods such as the Krackow technique. Patients with acute distal ruptures resulting from chronic tendinosis may require alternative fixation, where the proximal stump is attached directly to the calcaneus rather than to the damaged tissue of the short distal stump. It has been shown that suture anchor tenodesis is a viable repair technique for distal Achilles tendon ruptures.¹⁴ Implant systems such as the Achilles Midsubstance SpeedBridge (Arthrex) allows suture to pass from the proximal stump through the distal stump and to be anchored directly into the calcaneus. Clanton et al⁶ compared the relative strengths of a Midsubstance SpeedBridge repair and an open suture-only repair technique in midsubstance Achilles tendon ruptures and found no significant difference in ultimate strength of repair between the techniques.

There is currently no agreement on the best method to repair acute Achilles ruptures with a short distal stump, especially in cases of chronic tendinosis.²² The purpose of this study was to biomechanically compare a suture-only repair to a suture anchor-augmented repair in acute Achilles ruptures with a short distal stump. It was our hypothesis that we can construct biomechanically stronger repairs in these patients using the suture anchor-augmented repair compared with a suture-only repair.

METHODS

Nine paired Achilles-calcaneus complexes were harvested from fresh-frozen cadaveric donors. Cadavers were donated by our institution's biosciences center. Each specimen was obtained by transecting the Achilles tendon approximately 12 cm proximal to its insertion onto the calcaneus followed by disarticulation of the calcaneus.⁷ All specimens were inspected for any preexisting pathology and for gross abnormality. Additional soft tissue was resected until the specimen consisted of only the Achilles tendon and the calcaneus. The specimens were then soaked in sterile normal saline-soaked gauze and immediately frozen at -20°C .⁷ The

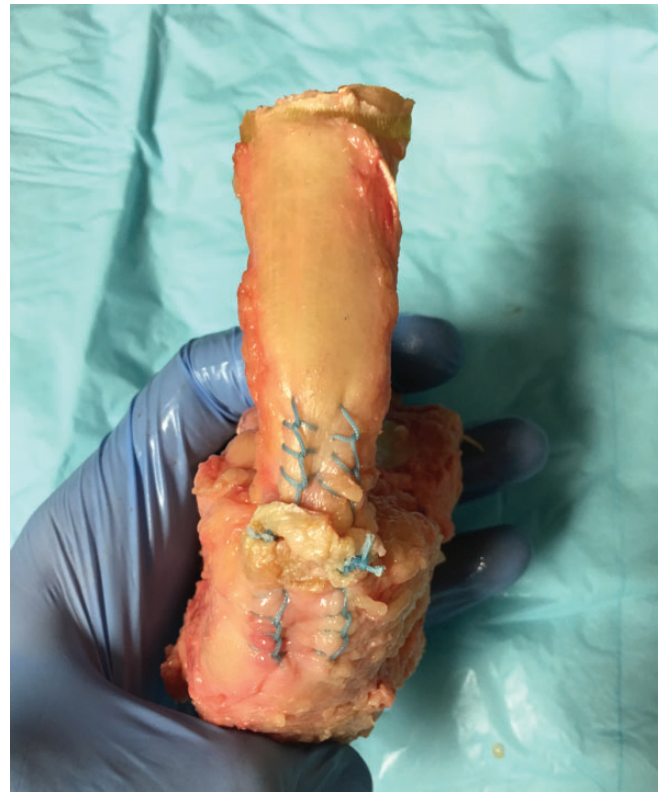

Figure 1. Suture-only repair.

specimens remained frozen until repair and biomechanical testing was performed. Twenty-four hours before repair and biomechanical testing, the individual specimens were placed in room temperature saline for thawing.^{7,9} Once thawed, one of a single donor's Achilles tendon complexes was randomly assigned to either a suture-only repair or a suture anchor-augmented repair. The contralateral side from the same donor was then assigned the opposing repair. The end result was 9 matched pairs of Achilles complexes. In all specimens, the Achilles tendon was sharply dissected at 2 cm proximal to the insertion. This was used to represent a common site for distal acute Achilles tendon ruptures in patients with chronic tendinosis. Chronic Achilles tendinosis has pathology around 2 to 3 cm proximal to the insertion; this is also the most distal portion of the tendon's watershed region.^{22,23}

The suture-only repair was performed with No. 2 FiberWire suture (Arthrex Inc). The sutures were placed in the proximal and distal segments of the Achilles tendon using a standard Krackow locking repair.²³ Each Krackow repair was standardized as being 2-stranded and included 4 throws per strand in each of the proximal and distal segments of tissue. There was approximately 5 mm of tissue between each throw. The sutures in both the proximal and distal segments were then tensioned and tied using a standard surgeon's knot (Figure 1).

The suture anchor-augmented repair was performed with No. 2 FiberWire suture and 4.75-mm Swivelock (Arthrex Inc) suture anchors. In the same way as the

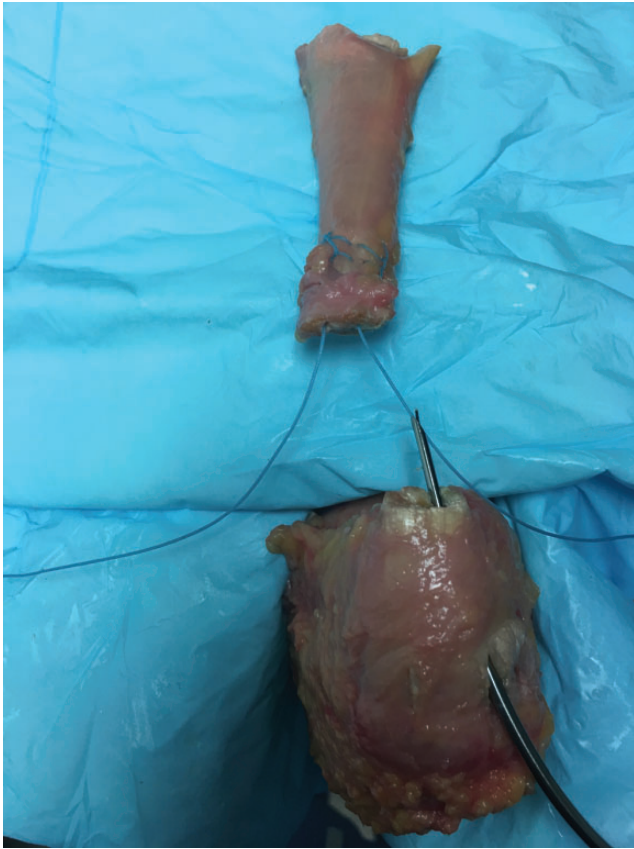


Figure 2. The use of a Banana Lasso to pass suture through the short distal stump during the suture anchor-augmented repair.

suture-only repair, the proximal segment of Achilles was repaired with No. 2 FiberWire suture in a 2-stranded Krackow repair. Again, each strand included 4 throws in the proximal stump. The distal stump of tissue was prepared as described in the Arthrex technique guide.¹ First, a Banana Suture Lasso (Arthrex Inc) was passed longitudinally through the entire length of the distal stump to retrieve the previously repaired suture in the proximal stump (Figure 2). After the suture had been retrieved and passed through the distal tendon stump, a 3.5-mm drill bit was used to create 2 holes in the most distal portion of the Achilles footprint on the calcaneal tubercle. These holes were then tapped, and a 4.75-mm Swivelock suture anchor that was loaded with the suture from the proximal stump was placed into each hole. The suture was tensioned appropriately so that the tendon edges came together flush. As the repair was tensioned, care was taken not to shorten the native length of the Achilles tendon. After insertion of the suture anchor, the excess suture was removed, and the final construct was a knotless Achilles tendon repair (Figure 3). All repairs were performed by a single surgeon.

The Achilles repair constructs were tested on a pneumatic material testing machine (EnduraTEC Systems Corp). The Achilles repair constructs were secured to the

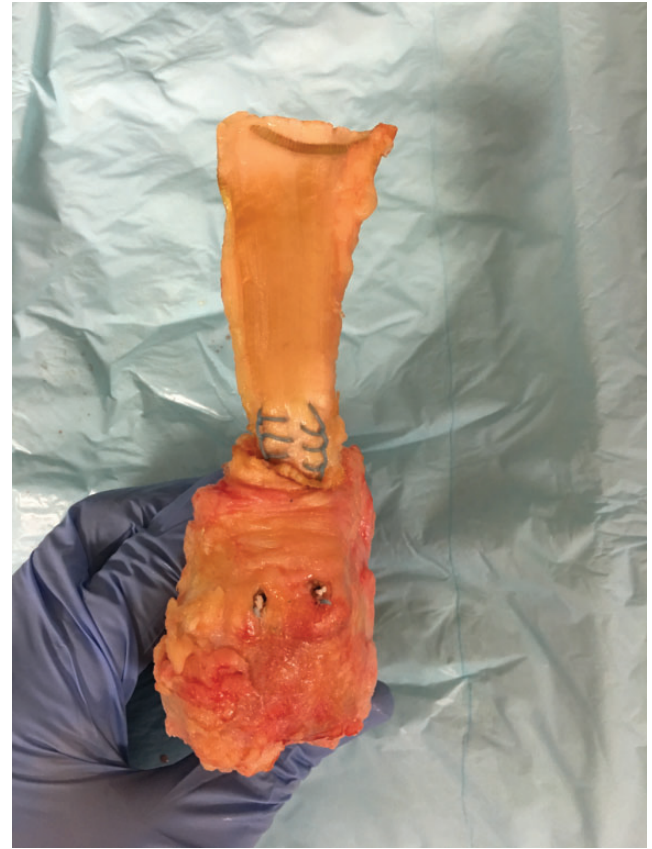

Figure 3. Suture anchor-augmented repair.

testing machine with two 5.0-mm Steinmann pins placed in the anterior and posterior portions of the calcaneus perpendicular to its long axis. The proximal most tendon was then secured in a specialized soft tissue grip (Bose Corp) which allowed for tendon fixation without slippage.⁷ The Achilles tendon was positioned at an angle of approximately 60° from the calcaneus (Figure 4); this angle was chosen to best simulate an ankle in neutral dorsiflexion and the stresses of early heel-rise.^{7,16}

All Achilles repair constructs then underwent the same testing protocol. Each repair complex was preconditioned at 100 N for 60 seconds. This allowed for conditioning elongation and accounts for the toe region on the stress-strain curve.^{7,10} After the Achilles repair construct was preloaded, the repair length was measured using manual calipers. The measurement was taken from the suture at the most proximal point to the most distal extent of the repair. The specific points used during measurements were marked for reproducibility. The repair was also examined for any gapping or other signs of construct failure. Once the repair was found to be free of gapping and failure, cyclic testing was begun. Each complex was dynamically loaded from 10 to 100 N at 2 Hz for 2000 cycles in a sinusoidal waveform.^{3,7}

After cyclic testing, the repair length was again measured using manual calipers, and the difference between the pre- and postcyclic load repair lengths was calculated.




Figure 4. Biomechanical testing apparatus used in all repairs.

The repair construct was examined for any postcyclic load gapping or failure, and any findings were recorded. Specimens then underwent load-to-failure testing, performed by mechanically displacing the tendon at a rate of 0.2 mm/s until the peak load was achieved.⁷ The ultimate failure point was determined by the load-displacement curve. The Achilles repair complex was then visually inspected to determine failure mode.

Statistical analysis was performed using a paired *t* test to analyze for differences in cyclic load repair displacement length and peak load to failure between the 2 repair types. Each specimen was matched to the contralateral specimen from the same cadaver in the statistical analysis. Statistical significance was set at $P < .05$.

RESULTS

The specimens included 4 males and 5 females, the average age of which was 72.4 years (range, 58-91 years). All specimens were found to be free of any preexisting pathology or gross abnormality. Because matched-pair testing was utilized, there was no difference between the 2 groups.

The amount of repair displacement after cyclic loading in the suture-only repair was a mean (\pm SD) of 3.33 ± 1.47 mm. The mean repair displacement in the suture anchor-augmented repairs was 1.54 ± 1.13 mm, which was

TABLE 1
Results of Biomechanical Testing^a

	Suture-Only Repair	Suture Anchor-Augmented Repair	<i>P</i> Value ^b
Repair site displacement, mm	3.33 ± 1.47	1.54 ± 1.13	$<.03$
Peak load to failure, N	209.09 ± 48.12	303.50 ± 102.81	$<.04$

^aValues are reported as mean \pm SD.

^bPaired *t* test.

116% less than the suture-only repair. This difference was found to be statistically significant ($P < .03$) (Table 1).

After cyclic testing, only 2 specimens exhibited any gapping at the repair site, both of which were suture-only repairs (Table 2). The amount of gapping at the repair sites in each specimen was 2.1 and 3.0 mm. This was considered less than clinical failure, which is described as greater than 5 mm of gapping.²⁰

The mean load to failure in the suture-only repairs was 209.1 ± 48.1 N. In the suture anchor-augmented repairs, the mean load to failure was 303.5 ± 102.8 N, which was an average of 45% greater load to failure than the suture-only repair. This was also found to be statistically significant ($P < .04$) (Table 1).

The clinical failure mode of all constructs during load-to-failure testing was by gapping greater than 5 mm. The reason for gapping differed between the 2 repair groups. The majority of suture-only repairs exhibited gapping due to suture breakage at the knot ($n = 5$). The remaining suture-only repairs exhibited gapping due to failure at the suture-tendon interface ($n = 4$). The suture anchor-augmented repairs had gapping due to failure at the suture-anchor interface in the majority of the repairs ($n = 8$); however, 1 specimen exhibited gapping due to suture breakage at the suture/anchor interface (Table 2).

DISCUSSION

Our study demonstrated that the suture anchor-augmented repair was biomechanically superior to the suture-only repair. The suture anchor-augmented repair could withstand a larger force before failure (303.5 ± 102.8 compared with 209.1 ± 48.1 N; $P < .04$). The augmented repair constructs also had less displacement across the repair (1.54 ± 1.13 compared with 3.33 ± 1.47 mm; $P < .03$). Considering that there are no previous studies comparing suture anchor versus suture-only repairs in Achilles tendon ruptures with a short distal stump, we cannot directly compare our results. However, a study conducted by Cox et al⁷ evaluated the biomechanical strength of knotless versus knotted insertional Achilles repairs using similar suture anchors to our study. These authors found that the load-to-failure force in the knotted repairs was 317.8 ± 93.6 N and was 196.1 ± 12.9 N in the knotless repairs. These load-to-failure forces are comparable with the results of our study.

TABLE 2
Failure Modes of Specimens

Specimen	Repair	Gapping After Cyclic Testing, mm	Ultimate Failure Mode ^a	Ultimate Failure Load, N
1	Suture-only	0	Suture breakage	163.31
	Suture anchor-augmented	0	Suture-anchor interface	252.50
2	Suture-only	0	Suture-tendon interface	209.20
	Suture anchor-augmented	0	Suture-anchor interface	243.54
3	Suture-only	0	Suture breakage	239.33
	Suture anchor-augmented	0	Suture-anchor interface	199.29
4	Suture-only	2.1	Suture-tendon interface	200.37
	Suture anchor-augmented	0	Suture breakage	215.30
5	Suture-only	0	Suture breakage	207.57
	Suture anchor-augmented	0	Suture-anchor interface	353.09
6	Suture-only	0	Suture-tendon interface	224.26
	Suture anchor-augmented	0	Suture-anchor interface	193.45
7	Suture-only	0	Suture breakage	310.33
	Suture anchor-augmented	0	Suture-anchor interface	423.14
8	Suture-only	0	Suture-tendon interface	184.22
	Suture anchor-augmented	0	Suture-anchor interface	402.92
9	Suture-only	3.1	Suture breakage	143.22
	Suture anchor-augmented	0	Suture-anchor interface	448.26

^aAll specimens initially failed clinically by gapping (>5 mm).

We believe that the suture anchor-augmented repairs were biomechanically stronger for a couple of reasons. First, the augmented repair bypasses the short distal stump of tissue and has primary fixation through the anchor in the calcaneus. This is likely even more important in patients with Achilles tendinosis, as the short distal stump of tissue is often degenerative and less capable of holding suture compared to our model with healthy Achilles tendons. A study by Kim et al¹⁵ examined the biomechanical significance of tendon purchase in flexor tendon repairs. They found that there was an increase in repair strength with increasing purchase length. Because of the short distal stump, there is a limited amount of tendon that suture can be passed through and therefore there is a shorter purchase length, thus a weaker construct.

Also, we believe that the lack of a knot improves biomechanical performance in suture anchor-augmented repairs. In the suture-only repair where knots were tied, over half of the specimens had failure through suture breakage at the knot. Conversely, in the augmented repairs, knots were not present and only 1 specimen failed due to suture breakage. In every other specimen, the repair failed at the suture/anchor interface. This leads us to believe that the knot is the most vulnerable point for failure of suture in Achilles tendon repairs.

In 2 of the matched pairs, the suture anchor-augmented repair failed at a lower ultimate load compared with the suture-only repair. The reason for the lower ultimate failure load cannot be known for certain; however, we hypothesize that the lower failure load is likely due to decreased bone mineralization. The suture anchors used in this study depend on friction between the suture and the surrounding bone for fixation. In patients with decreased bone mineralization, suture anchor fixation into the calcaneus could allow for slippage of the construct at the suture/bone interface and thus a lower point of failure.

Differences in the failure modes of the specimens also cannot be fully explained. In the suture-only repair group, 1 specimen failed due to suture breakage at only 143.22 N while another specimen failed at the suture/tendon interface at 224.26 N. The same repair and materials were used in both instances, however 1 suture failed with significantly less force than another suture of the same make was able to withstand. In general, we believe that the specimens with stronger Achilles tissue failed because of suture breakage, and specimens with weaker tendon failed at the suture/tendon interface.

The potential disadvantages to the use of suture anchor-augmented repair must also be evaluated. One disadvantage is the increased cost of a construct requiring suture anchors compared with one requiring only suture. In our experience, it is easier to shorten the Achilles tendon with the suture anchor construct, which could lead to functional limitations. Further investigation would also be warranted to determine differences in surgical time between the 2 techniques.

Noninsertional Achilles tendinosis is widely known to be a risk factor for chronic Achilles rupture, but it is also a risk factor for acute Achilles ruptures.^{2,22} It is our experience that in patients with underlying Achilles tendinosis who sustain an acute tendon rupture, often the rupture is located distal in the tendon leaving a short distal stump of tissue. The available biomechanical studies on Achilles tendon repairs were conducted using a simulated rupture at a location of 4 to 6 cm proximal to the insertion.^{6,11,12,17-19,21} To our knowledge, there is no literature on treatment of acute Achilles tendon ruptures with a short distal stump.

Our study is not without limitations. As with all biomechanical studies, true clinical relevance cannot be determined without larger clinical studies. The advanced average age of our cadavers (72.4 years; range, 58-91 years) can be seen as a weakness of the study, as the peak

incidence of Achilles ruptures are in younger patients. The cadaveric specimens were also free of any Achilles disease, which would likely be present in the clinical setting. We did not perform dual-energy x-ray absorptiometry (DEXA) scanning or any other bone mineral testing of the cadaveric specimens. However, we did use matched-pair testing to best match specimens for age, sex, tendon quality, and bone mineral density. Finally, our sample size is relatively small, including only 9 matched cadaveric pairs.

CONCLUSION

Our study demonstrates significant biomechanical superiority of the suture anchor–augmented repair compared to the suture-only repair in Achilles tendon ruptures with a short distal stump of tissue. Our results support the use of suture anchor–augmented repairs in similar Achilles ruptures for a biomechanically stronger construct. Biomechanically stronger repairs may lead to less tendon repair gapping and failure, increasing the ability to start early active rehabilitation protocols. Further investigation into the subject would be pertinent to identify true clinical significance.

REFERENCES

1. Arthrex Inc. Achilles midsubstance SpeedBridge surgical technique [pamphlet]. Naples, FL: Arthrex Inc; 2015.
2. Astrom M, Rausing A. Chronic Achilles tendinopathy. A survey of surgical and histopathologic findings. *Clin Orthop Relat Res*. 1995; 316:151-164.
3. Beitzel K, Mazzocca AD, Obopilwe E, et al. Biomechanical properties of double- and single-row suture anchor repair for surgical treatment of insertional Achilles tendinopathy. *Am J Sports Med*. 2013;41: 1642-1648.
4. Benthien RA, Aronow MS, Doran-Diaz V, Sullivan RJ, Naujoks R, Adams DJ. Cyclic loading of Achilles tendon repairs: a comparison of polyester and polyblend suture. *Foot Ankle Int*. 2006;27:512-518.
5. Booth BA, Mistovich RJ, Janout M, Stills HF, Laughlin RT. Fatty infiltration of the gastrocsoleus after tendo-Achilles lengthening and gastrocnemius recession in a rabbit model. *Foot Ankle Int*. 2009;30: 778-782.
6. Clanton TO, Haytmanek CT, Williams BT, et al. A biomechanical comparison of an open repair and 3 minimally invasive percutaneous Achilles tendon repair techniques during a simulated, progressive rehabilitation protocol. *Am J Sports Med*. 2015;43:1957-1964.
7. Cox JT, Shorten PL, Gould GC, Markert RJ, Barnett MD Jr, Laughlin RT. Knotted versus knotless suture bridge repair of the Achilles tendon insertion: a biomechanical study. *Am J Sports Med*. 2014; 42:2727-2733.
8. Fanter NJ, Davis EW, Baker CL Jr. Fixation of the Achilles tendon insertion using suture button technology. *Am J Sports Med*. 2012; 40:2085-2091.
9. Gardner MJ, Silva MJ, Krieg JC. Biomechanical testing of fracture fixation constructs: variability, validity, and clinical applicability. *J Am Acad Orthop Surg*. 2012;20:86-93.
10. Heckman DS, Gluck GS, Parekh SG. Tendon disorders of the foot and ankle, part 2: Achilles tendon disorders. *Am J Sports Med*. 2009;37: 1223-1234.
11. Huffard B, O'Loughlin PF, Wright T, Deland J, Kennedy JG. Achilles tendon repair: Achillon system vs. Krackow suture: an anatomic in vitro biomechanical study. *Clin Biomech (Bristol, Avon)*. 2008;23: 1158-1164.
12. Jaakkola JI, Hutton WC, Beskin JL, Lee GP. Achilles tendon rupture repair: biomechanical comparison of the triple bundle technique versus the Krakow locking loop technique. *Foot Ankle Int*. 2000;21:14-17.
13. Jones DC. Tendon disorders of the foot and ankle. *J Am Acad Orthop Surg*. 1993;1:87-94.
14. Kilicoglu O, Turker M, Yildiz F, Akalan E, Temelli Y. Suture anchor tenodesis in repair of distal Achilles tendon injuries. *Eur J Orthop Surg Traumatol*. 2014;24:117-122.
15. Kim JB, de Wit T, Hovius SE, McGrouther DA, Walbeehm ET. What is the significance of tendon suture purchase? *J Hand Surg Eur Vol*. 2009;34:497-502.
16. Labib S, Hage WD, Sutton KM, Hutton W. The effect of ankle position on the static tension in the Achilles tendon before and after operative repair: a biomechanical cadaver study. *Foot Ankle Int*. 2007;28: 478-481.
17. Labib SA, Rolf R, Dacus R, Hutton WC. The "giftbox" repair of the Achilles tendon: a modification of the Krackow technique. *Foot Ankle Int*. 2009;30:410-414.
18. Lee SJ, Goldsmith S, Nicholas SJ, McHugh M, Kremenic I, Ben-Avi S. Optimizing Achilles tendon repair: effect of epitendinous suture augmentation on the strength of Achilles tendon repairs. *Foot Ankle Int*. 2008;29:427-432.
19. Lee SJ, Sileo MJ, Kremenic IJ, et al. Cyclic loading of 3 Achilles tendon repairs simulating early postoperative forces. *Am J Sports Med*. 2009;37:786-790.
20. Maquirriain J. Achilles tendon rupture: avoiding tendon lengthening during surgical repair and rehabilitation. *Yale J Biol Med*. 2011;84: 289-300.
21. McCoy BW, Haddad SL. The strength of Achilles tendon repair: a comparison of three suture techniques in human cadaver tendons. *Foot Ankle Int*. 2010;31:701-705.
22. Reddy SS, Pedowitz DI, Parekh SG, Omar IM, Wapner KL. Surgical treatment for chronic disease and disorders of the Achilles tendon. *J Am Acad Orthop Surg*. 2009;17:3-14.
23. Thevendran G, Sarraf KM, Patel NK, Sadri A, Rosenfeld P. The ruptured Achilles tendon: a current overview from biology of rupture to treatment. *Musculoskelet Surg*. 2013;97:9-20.