



Since January 2020 Elsevier has created a COVID-19 resource centre with free information in English and Mandarin on the novel coronavirus COVID-19. The COVID-19 resource centre is hosted on Elsevier Connect, the company's public news and information website.

Elsevier hereby grants permission to make all its COVID-19-related research that is available on the COVID-19 resource centre - including this research content - immediately available in PubMed Central and other publicly funded repositories, such as the WHO COVID database with rights for unrestricted research re-use and analyses in any form or by any means with acknowledgement of the original source. These permissions are granted for free by Elsevier for as long as the COVID-19 resource centre remains active.



Available online at
ScienceDirect
www.sciencedirect.com

Elsevier Masson France
EM|consulte
www.em-consulte.com



Technical note

Bronchoscopy in times of COVID-19 pandemic: An interventional pulmonology unit experience



S. Levra^{a,*}, A. Veljkovic^b, M. Comune^b, V. Bernardi^b, A. Sandri^c, D. Indelicati^b

^a Department of Clinical and Biological Sciences, University of Torino, San Luigi University Hospital, Regione Gonzole 10, 10043 Orbassano, Turin, Italy

^b Department of Interventional Pulmonology, San Luigi Gonzaga University Hospital, Regione Gonzole 10, 10043 Orbassano, Turin, Italy

^c Division of Thoracic Surgery, San Luigi Gonzaga University Hospital, Regione Gonzole 10, 10043 Orbassano, Turin, Italy

ARTICLE INFO

Article history:

Received 12 April 2021

Accepted 19 May 2021

Available online 26 May 2021

ABSTRACT

Coronavirus disease 2019 (COVID-19) is an acute respiratory disease that has rapidly spread to become a global pandemic. Bronchoscopy is clearly a high-risk manoeuvre, so to continue endoscopic activity safely it was necessary to make many changes. We created different ways to access and exit the endoscopy theatre and reinforced our dressing/undressing regimens as well as equipment cleaning techniques. To prevent aerosol dispersion we used a bag valve mask with an antibacterial-antiviral filter, introducing the flexible bronchoscope orally rather than through the nose. For procedures with increased contagious risk a nasopharyngeal swab was required.

From the date of the first case of COVID-19 in our hospital to December 31 2020, we performed 1027 bronchoscopies, in both negative and positive patients. No outbreaks occurred within the staff and no patients are known to have developed COVID-19 after a procedure. Our experience underscores how it is possible to continue endoscopic activity safely.

1. Introduction

Severe acute respiratory syndrome coronavirus 2 (SARS-CoV-2) is a highly transmissible and pathogenic coronavirus that emerged in Wuhan, China, in late 2019 and rapidly spread to become a global pandemic of acute respiratory disease, named "Coronavirus disease 2019" (COVID-19) [1].

San Luigi Gonzaga Hospital, located in Orbassano in north-western Italy, has a long tradition in pulmonology and is a reference structure for the surrounding area. The interventional pulmonology centre inside it performs diagnostic and therapeutic bronchoscopies, in elective or emergency setting, 7 days a week, 24 hours a day. Certain medical procedures, just like bronchoscopy, result in close proximity with respiratory droplets and aerosol generation and are therefore considered at high-risk [2].

The first case of COVID-19 in our hospital was detected on March 3, 2020. The hospital set-up was changed and a COVID centre was established. The pandemic also had a great impact on the activity of our endoscopy centre by affecting the way we work. In order to continue our activity safely, it has been necessary to modify well-established habits and procedures, with few national [3] and international [4,5] recommendations available at the beginning of the pandemic. At the same time, the health emergency caused a

sudden reduction of staff, for infection and for support in newly adapted COVID-19 wards.

Two new critical issues have so emerged from the perspective of bronchial endoscopy: firstly, the safety of personnel performing procedures on patients with established or suspected SARS-CoV-2 infection and secondly, the continuation of activities without risk or delay in non-COVID-19 patients. Moreover, since the outbreak of the pandemic bronchoalveolar lavage analysis has been recognized as an additional method for virus detection [6], although characterized by a high infectious risk [7].

2. Our response to new challenges

To ensure individual protection, prior to procedures each staff member is equipped with safety protection devices (SPD), including a water-repellent gown, double gloves, shoe covers, a neck protection cap, a face shield and a surgical mask over a filter mask (FFP2/FFP3).

In order to avoid aerosol dispersion, a bag valve mask with a standard antibacterial-antiviral filter is used in combination with a Mainz-type adaptor (Fig. 1). Rather than through the nose, the flexible bronchoscope is introduced orally through a disposable mouthpiece. This reduces the curvature of the instrument and improves control and manoeuvrability.

Different ways to access and exit the endoscopy theatre were created, with separated green (low contagious risk) and red zones (high contagious risk) (Fig. 2). Similarly, separate rooms were set

* Corresponding author.

E-mail address: stefano.levra@unito.it (S. Levra).

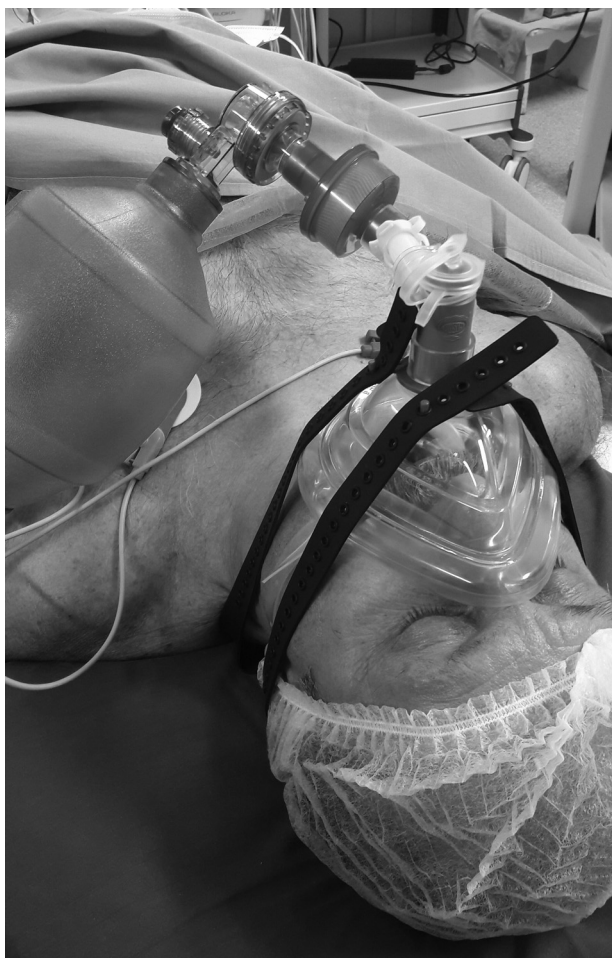

Fig. 1. New way to limit aerosol dispersion. The flexible instrument is introduced through a disposable mouthpiece, passing through a mask with bag valve in combination with a Mainz-type adapter. An antibacterial-antiviral filter link the adapter to the bag.

up for dressing and undressing. After the team entry, the doors of the theatre are closed to permit the action of the negative pressure. They are opened thirty minutes after the end of the procedure by the nurse who would then open the windows to promote the room's environmental ventilation. All the surfaces of the room, including the bed and the video stack are then sanitized with a dilution of 0.1% of sodium hypochlorite. The hospital cleaning service company would take care of the endoscopic centre hygiene

every evening at the end of the activities and every morning before the beginning.

The bronchoscope is reprocessed by usual specific steps but allowing a double washing program by decontamination trough a dilution of 50 ml enzymatic decontaminant in 5 L of water for 15 minutes.

In addition, for procedures with long duration (e.g. endobronchial ultrasound) or increased contagious risk (rigid bronchoscopy with open circuit) a nasopharyngeal molecular SARS-CoV-2 swab is always required, even in patients with a low clinical and radiological suspicion of infection.

Procedures in patients with confirmed infection or high suspicion were always done outside the endoscopy centre, in the inpatient department of origin or in a dedicated room in the emergency department. Each procedure performed outside the centre includes disposable instruments and handheld monitors (covered with cellophane and disinfected after use). SPDs are mandatory and similar to the ones described before.

3. Our numbers during the pandemic

From the first case recorded in this hospital to December 31 2020, a total of 1027 bronchoscopies have been performed in our centre. Their details are summarized in [Table 1](#).

We performed 118 bronchoscopies in patients with established or suspected COVID-19. In patients with proven infection, 59 procedures were performed: in 6 cases it was a diagnostic examination (e.g. over-infection), while in all the others the procedure had a therapeutic aim (e.g. haemoptysis, bronchial clearance). Similarly, 59 bronchoscopies were performed in patients with suspected infection, primarily to define clinical management. COVID-19 represented the first suspicion in 46 cases and all but 2 of these patients had already performed at least 1 molecular swab for SARS-CoV-2 that was deemed negative. COVID-19 was confirmed in 5 of 59 cases, whereas another pathogen was isolated in 31.

The staff reduction related to the in hospital re-employment in dedicated COVID-19 wards and the staff infection are two factors that could slow down the diagnostic pathway of diseases using bronchial endoscopy, especially the oncological ones. Our centre continued to perform diagnostic activities, for our and other hospitals as well as for outpatients. Specifically, during the period under review, 513 bronchoscopies were performed in oncological patients. In 303 cases the procedure had a diagnostic aim, while in 46 cases a preoperative bronchoscopy was performed. A total of 106 endobronchial ultrasound (EBUS) were performed for diagnosis and stadiation and 20 rigid bronchoscopies were performed with a therapeutic aim. Of all these procedures, 366 were performed after a negative SARS-CoV-2 molecular swab.

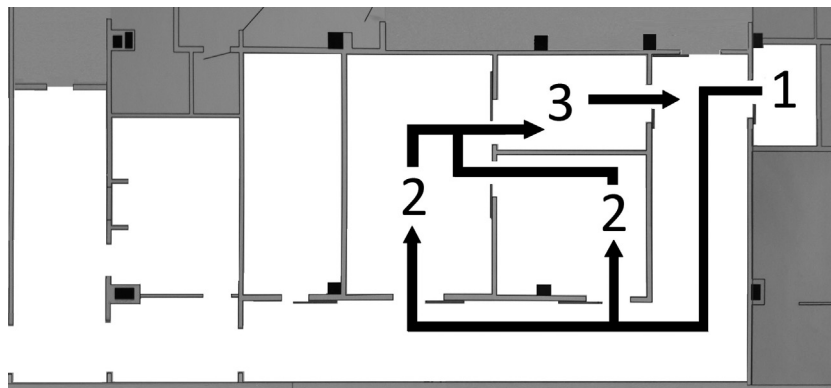


Fig. 2. Different ways to enter and exit the endoscopy theatre based on infectious risk. We get ready in the dressing room (1), keep the entrances and exits of the endoscopy theatre separated (2) and clean up in the undressing room (3).

Table 1
Endoscopic procedures from March 3 to December 31 2020.

	Endoscopy theatre	Inpatient department	Emergency department	Intensive care unite	Operating theatre	Total
COVID-19 confirmed	0	28	0	31	0	59
COVID-19 suspected	12	21	22	4	0	59
Not COVID-19	791	50	17	18	33	909
Total	803	99	39	53	33	1027

Endoscopic procedures based on site of performance and "coronavirus disease 2019" infection (COVID-19).

The remaining 396 procedures performed during the period under review were mainly of emergency in nature (e.g. haemoptysis, benign or malignant severe airway stenosis, endobronchial obstruction) or checks in patients with a tracheostomy cannula. Diagnostic bronchoscopies were performed in 104 cases, including 12 EBUS cases. The rigid bronchoscope was used in 10 cases. Of all these procedures, 193 were performed after a negative SARS-CoV-2 molecular swab.

Only 4 procedures in non-COVID-19 patients were delayed because of patient positivity on the pre-examination swab.

4. Discussion and conclusions

COVID-19 pandemic has changed the way bronchoscopy is performed in order to reduce the risk of transmission for both patients and operators [8]. Moreover, although characterized by a high risk, it has proven to be a useful diagnostic tool in selected cases [9].

In order to continue our work safely and without diagnostic delays in non-COVID-19 patients, it was necessary to strengthen our dressing/undressing regimens as well as equipment cleaning techniques. Some changes in operating procedures have also been necessary. From the point of view of the safety, the most important of these is the use of a bag valve mask along with a filter that provides excellent containment of droplets and aerosol. The use of the mask led to the oral access of the instrument, which is another important change. This access, also proposed by other Authors [10], may be more comfortable for the patient, although sometimes is made more difficult for the operator by tongue movements. Instrument is less stable than with the nasal route, but manoeuvrability is still effective. These changes in operating procedures, although they take operators time to adapt, are easily applied everywhere and so may be more handy than others described in literature [11–13].

In patients with established or suspected infection, bronchoscopy should be considered only for urgent/emergency reasons, especially for outpatients. For all other cases, the patient's risk should be always investigated and a nasopharyngeal swab should still be requested in case of a particularly long procedure or with a rigid instrument. For elective cancer diagnosis and staging cases we preferred to rely on clinical suspicion and possibly on the use of swabs rather than on a preventive isolation as suggested by other Authors [14].

Bronchioalveolar lavage can be an effective tool for the diagnosis of COVID-19, but it exposes the personnel to considerable infectious risk and is indicated only after a nasopharyngeal specimen [15]. In our view, in patients with significant clinical/radiological suspicion and a negative nasopharyngeal swab, the benefits of bronchioalveolar lavage may outweigh the risks only if performed in highly selected patients and by experienced operators with appropriate precautions.

In conclusion, these strategies ensured that the endoscopic activity of our centre proceeded without significant diagnostic delays and no outbreaks occurred within the staff. It includes 6 nurses, 4 physicians and 1 carer, some of whom also worked shifts within dedicated COVID-19 departments during the reporting period. Only 2 employees (1 physician and 1 nurse) contracted

COVID-19 within the year, but in neither case could a clear workplace episode be identified to explain the infection. No patients are known to have developed COVID-19 after a procedure. Our experience underscores that with some modifications it is possible to continue endoscopic activity safely, both for employees and patients. In addition, some of the changes adopted could also be used in the future, such as oral access that could be useful in patients at high infectious risk (e.g. tuberculosis) or with poor compliance.

Funding sources

This research did not receive any specific grant from funding agencies in the public, commercial, or not-for-profit sectors.

Disclosure of interest

The authors declare that they have no competing interest.

References

- [1] Wang C, Horby PW, Hayden FG, et al. A novel coronavirus outbreak of global health concern. *Lancet* 2020;395:470–3.
- [2] Krall J, Ali M, Maslonka M, et al. Bronchoscopy in the COVID-19 Era. *Clin Pulm Med* 2020;27:198–202.
- [3] Gasparini S. Ruolo e modalit?di esecuzione della broncoscopia nella pandemia da COVID-19. [AIPO-ITS Web site]; 2020. Available at: <http://www.aiponet.it>.
- [4] Pritchett MA, Oberg CL, Belanger A, et al. Society for advanced bronchoscopy consensus statement and guidelines for bronchoscopy and airway management amid the COVID-19 pandemic. *J Thorac Dis* 2020;12:1781–98.
- [5] Wahidi MM, Shojaaee S, Lamb CR, et al. The use of bronchoscopy during the Coronavirus Disease 2019 pandemic CHEST/AABIP guideline and expert panel report. *Thoracic Oncology: Guideline and Consensus Statement* 2020;158:1268–81.
- [6] Winichakoon P, Chaiwarith R, Liwsrisakun C, et al. Negative nasopharyngeal and oropharyngeal swabs do not rule out COVID-19. *J Clin Microbiol* 2020, <http://dx.doi.org/10.1128/JCM.00297-20>.
- [7] Wahidi MM, Lamb C, Murgu S, et al. American association for bronchology and interventional pulmonology (AABIP) statement on the use of bronchoscopy and respiratory specimen collection in patients with suspected or confirmed COVID-19 infection. *J Bronchol Interv Pulmonol* 2020, <http://dx.doi.org/10.1097/LBR.0000000000000681>.
- [8] Sampsonas F, Kakoullis L, Karampitsakos T, et al. Bronchoscopy during the COVID-19 pandemic: effect on current practices and strategies to reduce procedure-associated transmission. *Expert Rev Respir Med* 2021:1–7.
- [9] Barberi C, Castelnovo E, Dipasquale A, et al. Bronchioalveolar lavage in suspected COVID-19 cases with a negative nasopharyngeal swab: a retrospective cross-sectional study in a high-impact Northern Italy area. *Intern Emerg Med* 2021:1–8.
- [10] Uchimura K, Yamasaki K, Kawanami T, et al. Novel device to prevent droplets in bronchoscopy during the SARS-CoV-2 pandemic. *Thorac Cancer* 2021;12:137–9.
- [11] Francom CR, Javia LR, Wolter NE, et al. Pediatric laryngoscopy and bronchoscopy during the COVID-19 pandemic: a four-center collaborative protocol to improve safety with perioperative management strategies and creation of a surgical tent with disposable drapes. *Int J Pediatr Otorhinolaryngol* 2020;134:110059.
- [12] Andujar-Espinosa R, Ros-Lucas JA, Ruiz-Lopez FJ. Protective hood prototype for bronchoscopy during Covid-19. Prototipo de cubierta protectora para bronoscopias durante la infeccion COVID-19. *Med Clin (Barc)* 2021;156:46.
- [13] Yamamoto S, Nakayama M, Tsubochi H, et al. A novel protective barrier enclosure for performing bronchoscopy. *Respir Investig* 2021;59:260–2.
- [14] Ost D. Bronchoscopy in the age of COVID-19. *J Bronchology Interv Pulmonol* 2020;27:160–2.
- [15] Wahidi MM, Shojaaee S, Lamb CR, et al. The use of bronchoscopy during the Coronavirus Disease 2019 pandemic: CHEST/AABIP guideline and expert panel report. *Chest* 2020;158:1268–81.