

Anterior Release and Anterior Reconstruction for a Neglected Osteoporotic Odontoid Fracture

Abstract

A 70 years old lady presented to us with history of a fall 3 months prior. She had suffered a type 2 odontoid fracture with atlantoaxial dislocation, that was not reducible by traction. She had symptoms of neck pain with inability to hold the neck upright. The patient was subsequently planned for anterior release and reduction of odontoid fracture dislocation with posterior stabilization in the same sitting. The patient was treated with cervical skeletal traction and immobilized. However, she developed occipital sore during the period and was mobilized with brace after which she developed myelopathic symptoms and gait disturbance due to the collapse of fracture segment. The patient was planned for anterior release and fixation with contoured reconstruction plate fixing C1 lateral mass to the lateral mass on the right side and C1 lateral mass to C2 body on the left side primarily with distraction of the C1–C2 joint by autologous tricortical iliac bone graft. The posterior stabilization was planned after healing of the sore, and the patient was counseled for the same. However, the patient was lost on follow-up and returned at 3-month postoperative period with collapse of the graft, resubluxation of C1–C2 segment, and failure of anterior fixation. The standard modality of treatment for such cases includes an anterior release of contracted soft tissues and ligaments and posterior stabilization with fusion in a single setting. However, it is the posterior fixation that stabilizes the fracture and prevents it from redislocation. Anterior fixation as a stand-alone treatment in osteoporotic bone has high risks of failure due to severe posterior tensile stresses. This article describes the importance of posterior fixation in osteoporotic bone based on our experience.

Keywords: Anterior release and reconstruction, irreducible atlantoaxial dislocation, posterior fixation, retropharyngeal approach, type 2 odontoid fracture

Introduction

Irreducible atlantoaxial dislocation (AAD) most commonly results from traumatic and congenital abnormalities, rarely inflammatory conditions. Such dislocations result in stenosis of foramen magnum, basilar invagination, and compression of the cord with myelopathy if chronic resulting in various signs and symptoms. It results in chronic disability due to chronic neck pain and lack of normal head movements. Treatment of such neglected spinal injuries and irreducible dislocations is challenging as it requires extensive dissection of vital organs both anteriorly and posteriorly.

Case Report

A 70-year-old female, came to the outpatient department, 3 months after a history of fall from height and injury to the neck, which was initially treated with a hard cervical

collar and analgesics elsewhere. The patient had symptoms of neck pain and inability to hold her neck upright without support. On examination, the patient had no neural deficits. X-ray showed an odontoid type 2 fracture with AAD [Figures 1-4]. She was treated with cervical traction, but she developed an occipital pressure sore [Figure 5]. The traction was removed and the patient was mobilized with a brace. Two-week postremoval of traction, she developed gait disturbances and Grade 1 myelopathy. Her X-ray showed worsening of AAD [Figures 6-9].

Investigations

Computed tomography and magnetic resonance imaging-angio scans were done. It showed malunion of the odontoid fracture type 2 with fracture of the left superior articular process of C2 [Figure 10]. There was high-riding vertebral artery on one side with cord compression due to malunion of the odontoid.

How to cite this article: Sonone S, Dahapute AA, Balasubramanian SG, Gala R, Marathe N, Pinto DA. Anterior release and anterior reconstruction for a neglected osteoporotic odontoid fracture. Asian J Neurosurg 2019;14:525-31.

**Sandeep Sonone,
Aditya Anand
Dahapute,
Sai Gautham
Balasubramanian¹,
Rohan Gala,
Nandan Marathe,
Deepika Albert
Pinto²**

Department of Orthopaedics, KEM Hospital, ¹Department of Orthopaedics, Siddhartha Hospital, ²Department of Orthopaedics, Dr. BDBA Hospital, Kandivali West, Mumbai, Maharashtra, India

Address for correspondence:

*Dr. Sai Gautham
Balasubramanian,
Department of Orthopaedics,
Siddhartha Hospital,
Goregaon, Mumbai - 400 063,
Maharashtra, India.
E-mail: saigautham90@gmail.
com*

Access this article online

Website: www.asianjns.org

DOI: 10.4103/ajns.AJNS_42_18

Quick Response Code:



This is an open access journal, and articles are distributed under the terms of the Creative Commons Attribution-NonCommercial-ShareAlike 4.0 License, which allows others to remix, tweak, and build upon the work non-commercially, as long as appropriate credit is given and the new creations are licensed under the identical terms.

For reprints contact: reprints@medknow.com

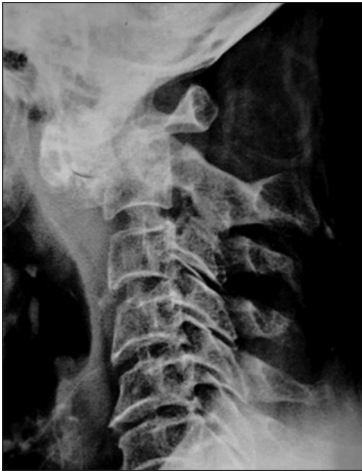

Figure 1: X-ray cervical spine – Lateral showing type 2 odontoid fracture with atlantoaxial dislocation

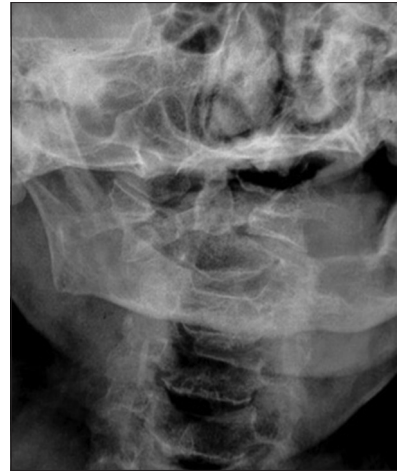

Figure 2: X-ray cervical spine – Anteroposterior view

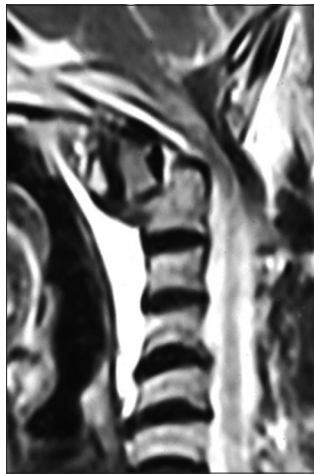

Figure 3: Magnetic resonance imaging – Sagittal view showing atlantoaxial dislocation with cord compression

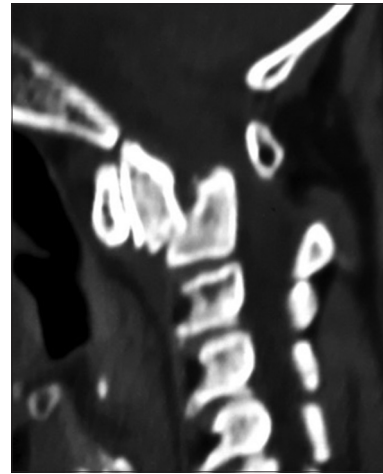


Figure 4: Computed tomography – Sagittal cuts showing complete anterior translation of dens with irreducible atlantoaxial dislocation

Challenges in further treatment

- Challenge in approach – The presence of occipital pressure sore makes posterior surgical approach prone to surgical wound-related complications
- Challenge in reduction – Fixed malunion needs anterior release to align the fragments and reduce the compression on the cord. After reducing, maintaining the reduction postoperative till the patient undergoes posterior fixation predisposes the patient from iatrogenic cord compression since the C1/C2 complex is hypermobile
- Challenge in fixation – Posterior fixation in the form of transarticular screw was highly risky considering the high-riding vertebral artery. Stabilization anteriorly was challenging due to low bone mass available for fixation anteriorly
- Further challenges – Risk of pharyngeal erosion and implant exposure. Risk of development of myelopathy symptoms.

Treatment options

- a. Anterior transoral approach for release and reduction + posterior approach for stabilization and fusion
- b. Anterior retropharyngeal approach for release and reduction + posterior approach for stabilization and fusion
- c. All anterior – reduction, grafting, and stabilization.

Treatment performed

Rationale – An anterior approach was chosen for release, reduction, grafting, and fixation. A posterior C1/C2 fixation was planned at the second stage since the patient had occipital sore and worsening neurology.

Anterior retropharyngeal approach was used to release the proximal fragment, excision of superior tip of the distal fragment, alignment, and distraction of C1–C2 joint [Figures 11-13] with insertion of tricortical bone grafts [Figure 14] to aid fusion was performed. Stabilization was done by contoured reconstruction

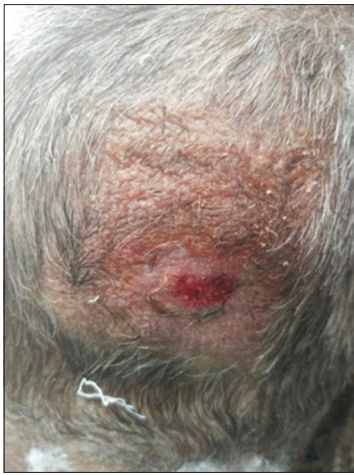

Figure 5: Occipital sore after 2 weeks of traction

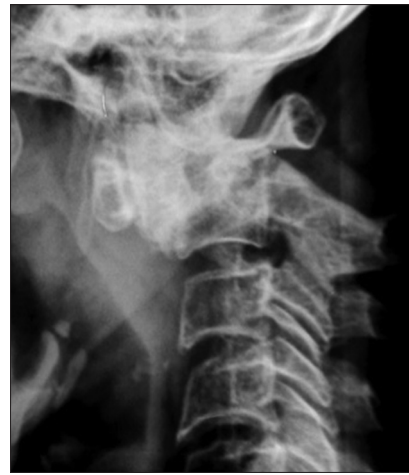

Figure 6: X-ray cervical spine lateral showing worsening of atlantoaxial dislocation – 2 weeks' posttraction

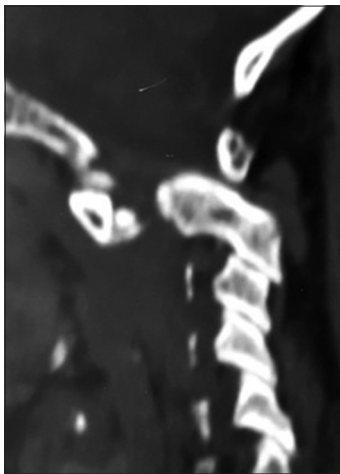


Figure 7: Computed tomography – Sagittal view showing complete displacement of C1-C2 segment

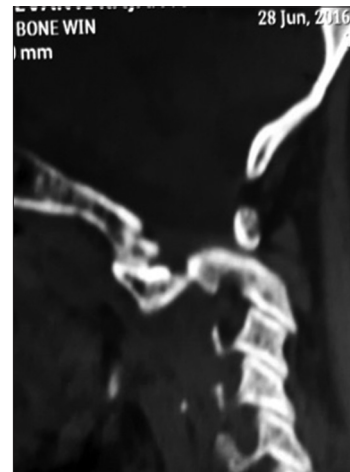


Figure 8: Computed tomography – Sagittal view

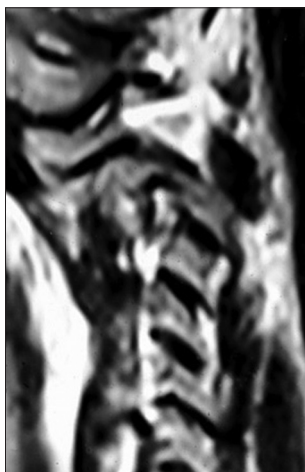

Figure 9: Magnetic resonance imaging – Sagittal view showing mild myelopathic changes

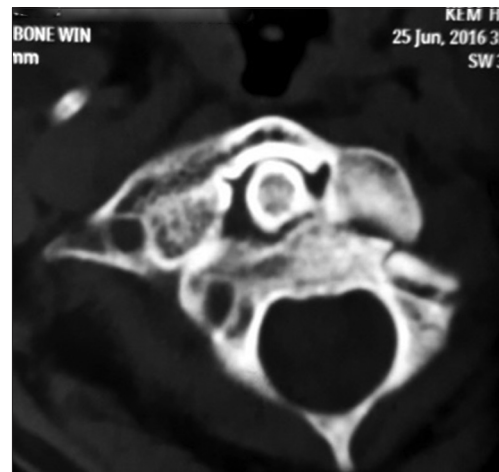


Figure 10: Computed tomography – Axial view showing left C2 superior articular process fracture with C1-C2 segment rotation

plate fixing C1 lateral mass to the lateral mass on the right side and C1 lateral mass to C2 body on the left side since there was a fracture of C2 superior lateral

mass on the left side [Figures 15-18]. The patient had an improvement in gait and posterior stabilization was planned after 2-3 weeks on healing of occipital

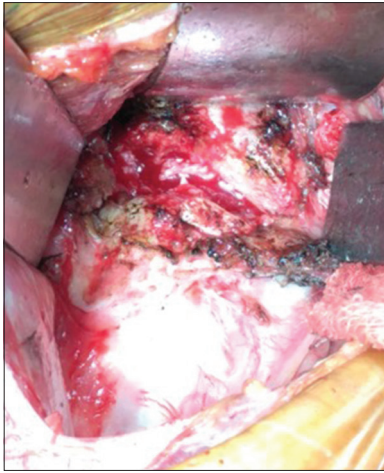

Figure 11: Anterior release through retropharyngeal approach

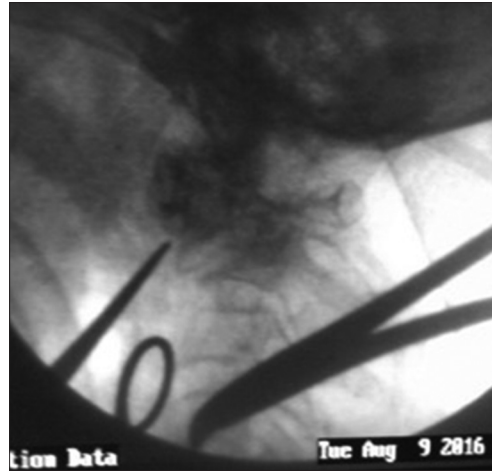


Figure 12: Intraoperative image showing complete reduction of odontoid fracture post anterior release

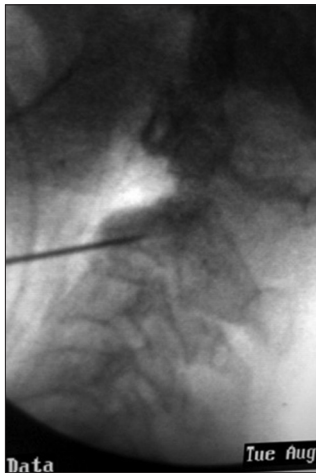

Figure 13: Excising superior tip of distal fragment

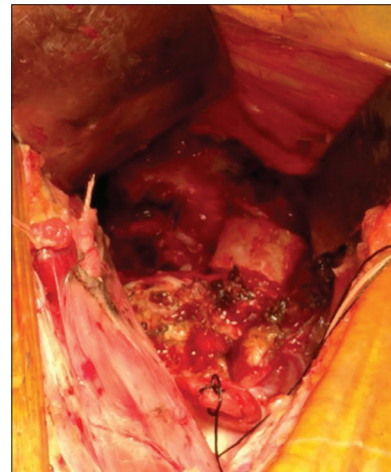


Figure 14: C1-C2 joint distraction with tricortical iliac graft

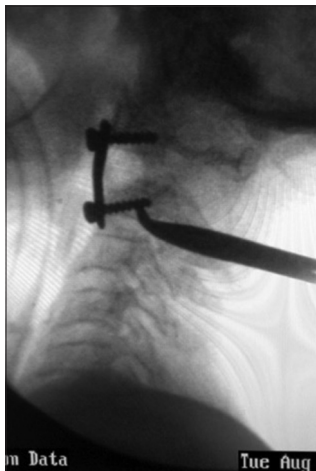


Figure 15: Anterior stabilization

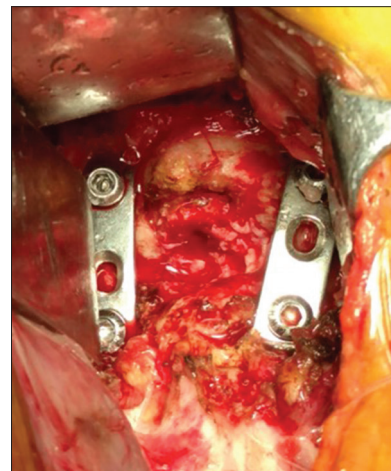


Figure 16: Left C1 lateral mass to C2 body contoured recon plate

sore. However, the patient was lost on follow-up and subsequently returned after 3-month postoperatively with collapse of the fracture fragment and graft with implant failure anteriorly and worsening of AAD when compared preoperatively. However, the patient had no myelopathic

symptoms or gait disturbances with reduction of neck pain [Figures 19 and 20]. However, the patient was unable to hold her neck upright with severe restriction in daily activities leading to chronic disability.

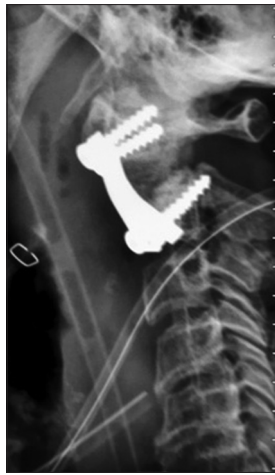

Figure 17: Immediate postoperative X-ray – well-reduced atlantoaxial dislocation with anterior stabilization

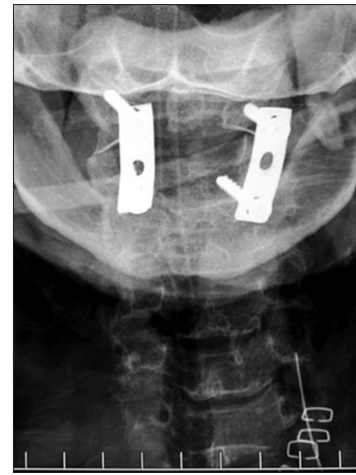

Figure 18: Immediate postoperative – Anteroposterior view

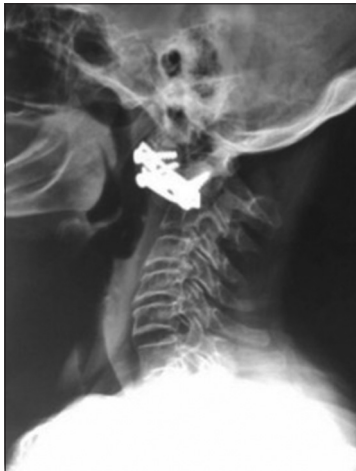

Figure 19: 3-month postoperative X-ray showing complete collapse with resubluxation of C1–C2 segment

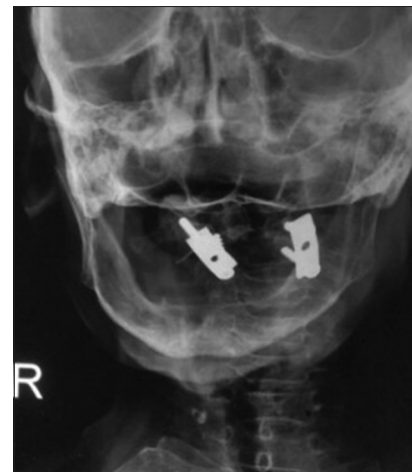


Figure 20: Anteroposterior view – 3-month postoperative

Discussion

Odontoid type 2 fractures are more prone to nonunion due to the poor vascularity and instability caused by fracture. It may lead to irreducible AAD due to contraction of the soft tissues and ligaments in the concavity of the deformity (anterior).^[1] This leads to severe posterior angulation of dens resulting in severe cord compression as noted by Grabb *et al.*^[2] The longus colli, longus capitis, anterior joint capsule, and the anterior longitudinal ligaments are all in the concavity of the deformity and undergo contracture preventing complete reduction resulting in C1–C2 kyphosis.^[3] Furthermore, the bony changes in the form of arthritis of C1–C2 joint, osteophytes, and intra-articular adhesions may prevent the reduction. Rarely, new bone formation or malunion of odontoid may result in irreducible dislocation.

The AAD has been treated traditionally by the release of contracted and shortened anterior structures and reduction of odontoid through anterior approach with posterior fixation

by transarticular screws or occipitocervical plating and fusion with bone grafting of C1–C2 joint. Rarely, release of atlantoaxial joint with distraction of facets as described by Goel^[4] posteriorly is used for less severe cases. However, the pathological tethered structures are not released by this approach and the reduction achieved is almost always incomplete with residual posterior angulation of dens resulting in incomplete decompression of the cord. This procedure also causes inherent instability to the C1–C2 joint and carries the risk of perforating vertebral artery in case of misplacement of the transarticular screws or hemorrhage from venous plexuses with high morbidity and mortality. Furthermore, there is a chance of injury of C2 root ganglion.

Another approach is the transoral odontoidectomy, followed by posterior fixation and fusion. This procedure allows adequate exposure of C1 and C2 levels and release of osteophytes, ligaments, and capsule. However, the excessive kyphosis or rotational malalignment cannot be corrected by this procedure. This procedure also carries the risk of dural injuries which might lead to meningitis and the mucosa-related problems with poor healing potential.

The all-anterior approach, as described by Schmelzle *et al.*,^[5] approaches C1–C2 segment transorally followed by stabilization and fixation with grafting. Harms' anterior atlantoaxial fixation device was able to impart acute mechanical stability in some patients, but it was a neutralization device. It was not capable of effecting reduction like the transoral atlantoaxial reduction plate (TARP).^[6] Furthermore, as the device lacked a screw locking mechanism, as presently described Harms' procedure must include a supplementary posterior fusion to get enough stability.

The anterior release of contracted structures can also be done through anterior retropharyngeal approach. This procedure has the advantages of performing release of the pathological structures under vision, reduction of C1–C2 joint with correction of rotational malalignment, and adequate decompression of the cord while negating the complications of transoral approach. Although it has a tangential view of the pathological site rather than direct view of transoral approach, it has the familiarity of the approach by the surgeons.

In our case, the patient had come to our clinic after 3 months of initial injury with severe irreducible AAD. The skeletal traction was followed with up to one-tenth of body weight to stretch the contracted anterior structures and prevent iatrogenic traction injury to the cord intraoperatively. However, the patient developed occipital sore which narrowed down our treatment possibilities to all anterior release, realignment, and fixation with reconstruction plates. This fixation is deemed to be biomechanically inferior as it is on the anterior compressive forces rather than posterior tensile forces. This might lead to recollapse of atlantoaxial joint anteriorly resulting in craniovertebral junctional kyphosis with severe compression on the cord. Hence, the posterior fixation with transarticular screws or occipitocervical fusion at a second stage after improvement of skin condition was planned.

However, the patient was lost to follow-up and was reviewed 3 months after the first-stage surgery with resubluxation of C1–C2 segment with collapse of the tricortical bone graft and implant failure. The patient was asymptomatic and is being presently observed and counseled for further management.

The multitude of treatment options for the reduction and stabilization of AAD make the choice of surgery selected according to the patient's type of fracture and dislocation pattern. Transoral approach becomes the only treatment of choice in extreme vertical migration of dens following odontoid fractures, whereas in patients with limited mouth opening, retropharyngeal approach becomes the only approach.

Conventionally, irreducible AAD had been treated surgically by transoral odontoidectomy, followed by posterior fusion.^[7,8] Wang *et al.*^[11] showed that

anterior transoral release of irreducible AAD without odontoidectomy, followed by posterior instrumented fusion can achieve excellent alignment even in severe dislocations. Several authors have reported successful application of this technique to treat irreducible dislocations through retropharyngeal approach.^[9,10] Release of anterior structures rather than odontoidectomy has several advantages, in that, the postoperative torticollis and swan neck deformity can be avoided. Furthermore, the risk of dural injuries and postoperative meningitis can be minimized.

Srivastava *et al.*^[11] noted that results obtained for the anterior release of structures from both transoral and retropharyngeal approaches have no difference and that it depends on surgeon's familiarity contracted structures for the reduction of AAD. Most surgeons prefer posterior fixation following anterior release. Wu *et al.*^[12] described a technique of microendoscopic anterior release and anterior transarticular screw fixation for patients with irreducible AAD without posterior fixation. An all-posterior approach has also been described by Goel *et al.* for less severe dislocations by atlantoaxial joint release and distraction. However, it is more prone to recurrence and cannot fully correct the deformity.

Transarticular screws can be used for posterior fixation for posterior C1–C2 fusion. An alternative technique is to use the Goel–Harms C1 lateral mass and C2 pedicle screw fixation. There are definite advantages of the latter technique over transarticular screws, as this method does not require anatomical reduction of C1–C2 joint before fixation. Rotational malalignment is also easier to correct with this technique. Furthermore, this technique has a stable and rigid fixation construct, resulting in solid fusion of C1–C2 joint than the transarticular screws fixation.

Patkar^[13] introduced a new technique of anterior retropharyngeal plate with bilateral transarticular screw fixation anteriorly for type 2 odontoid fractures without the risks of posterior exposure. His results showed that this anterior approach combines the best aspects of anterior screw fixation (Bohler) and posterior C1–C2 fixation (Goel–Harms) along with the release of anterior contracted structures for the reduction of AAD.

Ai *et al.*^[14] used a TARP fixation system, which had the additional feature of being able to actively facilitate the reduction while imparting sufficient internal stability to avoid a posterior fusion procedure. Combined with atlantoaxial reduction instrumentation, the TARP can affect the reduction of the atlantoaxial joints after the C1/C2 joint release. But according to Kandizora *et al.*,^[15] isolated anterior atlantoaxial plating was less stable than the combined reconstruction procedures in the experimental biomechanical analysis of transoral plates. Transoral plate fixation according to Harms in combination with posterior wire fixation according to Brooks provided a failure load and stiffness equal to transarticular screw fixation according to Magerl.

Hence, according to the current literature review and the results, irreducible AAD should be treated with release of anterior structures and concurrent stable posterior fixation in a single setting to prevent the recurrence of the deformity, especially in osteoporotic fractures.

Conclusion

Anterior retropharyngeal approach is a viable option for release, realignment, and fixation for irreducible AAD, but as a stand-alone treatment has risk of failing, especially in osteoporotic bone. As the anterior fixation has the disadvantage of biomechanically inferior due to compressive forces, it should be supplemented by posterior fixation to restore the posterior tension band neutralizing the posterior tensile forces.

Declaration of patient consent

The authors certify that they have obtained all appropriate patient consent forms. In the form the patient(s) has/have given his/her/their consent for his/her/their images and other clinical information to be reported in the journal. The patients understand that their names and initials will not be published and due efforts will be made to conceal their identity, but anonymity cannot be guaranteed.

Financial support and sponsorship

Nil.

Conflicts of interest

There are no conflicts of interest.

References

- Wang C, Yan M, Zhou HT, Wang SL, Dang GT. Open reduction of irreducible atlantoaxial dislocation by transoral anterior atlantoaxial release and posterior internal fixation. *Spine (Phila Pa 1976)* 2006;31:E306-13.
- Grabb PA, Mapstone TB, Oakes WJ. Ventral brain stem compression in pediatric and young adult patients with chiari I malformations. *Neurosurgery* 1999;44:520-7.
- Aggarwal RA, Rathod AK, Chaudhary KS. Irreducible atlanto-axial dislocation in neglected odontoid fracture treated with single stage anterior release and posterior instrumented fusion. *Asian Spine J* 2016;10:349-54.
- Goel A. Treatment of basilar invagination by atlanto-axial joint distraction and direct lateral mass fixation. *J Neurosurg Spine* 2004;1:281-6.
- Schmelzle R, Harms J, Stoltze D. Osteosynthesis in Occipito-Cervical Dislocation via Transoral Access. In: XVII SICOT World Congress Abstracts. Munich: Demeter-Verlag; 1987. p. 27-8.
- Yin QS, Ai FZ, Zhang K, Mai XH, Xia H, Wu ZH, *et al.* Transoral atlantoaxial reduction plate internal fixation for the treatment of irreducible atlantoaxial dislocation: A 2- to 4-year follow-up. *Orthop Surg* 2010;2:149-55.
- Jain VK. Atlantoaxial dislocation. *Neurol India* 2012;60:9-17.
- Jain VK, Behari S, Banerji D, Bhargava V, Chhabra DK. Transoral decompression for craniocervical osseous anomalies: Perioperative management dilemmas. *Neurol India* 1999;47:188-95.
- Hao D, He B, Zheng Y, Zhang Z. Single stage anterior release and sequential posterior fusion for irreducible atlantoaxial dislocation. *Spinal Disord Tech* 2013.
- Hao DJ, He BR, Wu QN. One-stage anterior release and reduction with posterior fusion for treatment of irreducible atlantoaxial dislocation. *Orthop Surg* 2009;1:305-10.
- Srivastava SK, Aggarwal RA, Nemade PS, Bhosale SK. Single-stage anterior release and posterior instrumented fusion for irreducible atlantoaxial dislocation with basilar invagination. *Spine J* 2016;16:1-9.
- Wu YS, Chi YL, Wang XY, Xu HZ, Lin Y, Mao FM, *et al.* Microendoscopic anterior approach for irreducible atlantoaxial dislocation: Surgical techniques and preliminary results. *J Spinal Disord Tech* 2010;23:113-20.
- Patkar S. Anterior retropharyngeal plate screw fixation with bilateral anterior transarticular screws for odontoid fractures. A new comprehensive technique. *Neurol Res* 2017;39:581-6.
- Ai FZ, Yin QS, Xu DC, Xia H, Wu ZH, Mai XH, *et al.* Transoral atlantoaxial reduction plate internal fixation with transoral transpedicular or articular mass screw of c2 for the treatment of irreducible atlantoaxial dislocation: Two case reports. *Spine (Phila Pa 1976)* 2011;36:E556-62.
- Kandziora F, Kerschbaumer F, Starker M, Mittlmeier T. Biomechanical assessment of transoral plate fixation for atlantoaxial instability. *Spine (Phila Pa 1976)* 2000;25:1555-61.