



# Doing more with less: multiple uses of a single slide in veterinary cytology. A practical approach

Carla Marrinhas<sup>1,2</sup> · Fernanda Malhão<sup>2</sup> · Célia Lopes<sup>2</sup> · Filipe Sampaio<sup>2,3</sup> · Raquel Moreira<sup>2,4</sup> · Mario Caniatti<sup>5</sup> · Marta Santos<sup>2</sup> · Ricardo Marcos<sup>2</sup>

Received: 21 January 2022 / Accepted: 7 June 2022 / Published online: 18 June 2022  
© The Author(s), under exclusive licence to Springer Nature B.V. 2022

## Abstract

Veterinary cytology faced a remarkable evolution in the last 15 years, in part due to increase recognition of the advantages of the cytology by veterinary clinicians. Simultaneously, there has been a growing awareness by the owners about the importance of a complete diagnostic workup aimed at defining a proper treatment protocol. With the extended use of cytology, challenging diagnostic cases are more frequent, and more clinically useful answers are requested. In this scenario, the use of cytology specimens to perform ancillary techniques is a valid approach. Rather than being simply archived, cytology slides can be a valuable source and a good platform to carry out cytochemistry, immunocytochemistry, and molecular techniques. Therefore, several diagnostic techniques can be applied in tiny samples, thus following the “doing more with less” principle. The aim of this approach is to refine the cytologic diagnosis and provide additional prognostic and therapeutic information. Herein, we detailed this principle in veterinary cytology and reviewed the use of cytology specimens for ancillary techniques as a single procedure, i.e., using the whole slide, or multiple procedures, i.e., multiple procedures applied in the same slide.

**Keywords** Cytology · Diagnosis · Immunocytochemistry · Molecular biology · Dog · Cat

## Introduction

The microscopic evaluation of cells for diagnostic purposes is an old procedure, almost as old as the microscope itself. In human medicine, neoplastic cells were reported in the *sputa* of patients in the middle of the XIX century, but it was only after the mid-XX century that the use of cytology for diagnostic purposes became widespread (Naylor 2000). The history of veterinary cytology is shorter, but has

spread widely in recent decades, boosted by prompt results, and particularly for the importance of making a definitive diagnosis avoiding the use of more invasive and expensive surgical biopsies for histological examination. Still, two significant differences exist between veterinary and human cytology. The acquisition of material and general interpretation of cytology samples are skills of general practice veterinarians and are not restricted to pathologists or specialized technicians as occurs in human medicine (Sharkey et al, 2014). Moreover, samples in veterinary cytology are almost exclusively air-dried and stained with an aqueous based Romanowsky stain, rapid [e.g. Diff-Quik™ (RAL Diagnostics, Martillac, France), Hemacolor™ (Merck KGaA, Darmstadt, Germany)] or methanolic Romanowsky stains (e.g., Wright-Giemsa, May-Grünwald Giemsa), while in human pathology alcohol-fixed specimens and stained with Papanicolaou are largely used (Sharkey et al. 2014).

After staining with a Romanowsky stain and making a morphologic diagnosis at the microscope, the diagnostic value of a cytology slide is far from being over. The specimen can be sent back to a laboratory to be reused. The smear can be either fully restained or be scraped for molecular biology techniques in a single procedure. Alternatively, it can have

✉ Ricardo Marcos  
rmarcos@icbas.up.pt

<sup>1</sup> Hospital Do Baixo Vouga, OneVet Group, Águeda, Portugal

<sup>2</sup> Cytology and Hematology Diagnostic Services, Laboratory of Histology and Embryology, Institute of Biomedical Sciences Abel Salazar, ICBAS - School of Medicine and Biomedical Sciences, Rua de Jorge Viterbo Ferreira, 228, 4050-313 Porto, Portugal

<sup>3</sup> Laboratório INNO, Braga, Portugal

<sup>4</sup> UPVET, ICBAS – School of Medicine and Biomedical Sciences, Porto, Portugal

<sup>5</sup> Dipartimento Di Medicina Veterinaria E Scienze Animali (DIVAS), Università Degli Studi Di Milano, Milano, Italy

multiple applications using parts of the smear for different purposes. These multiple procedures involve some laboratory workup, since parts of the smear can be covered, split into several slides or used for immunostaining with a panel of markers (Fig. 1).

This review intends to highlight these procedures and provide some applications. The final aim of these methods is to refine the cytologic diagnosis and provide additional clinical or prognostic information, thus following the “doing more with less” principle. Moreover, a comparison with the standard practice in human pathology is included. In this area and in the era of personalized medicine, this principle has been followed for many years (Gonzalez et al. 2017). For the sake of clarification, we divided this review into two approaches as follows. Single procedure: all the smear in a slide is retained or used for molecular biology. Multiple procedures: part of the Romanowsky-stained smear is preserved.

### Initial step: removing the coverslip

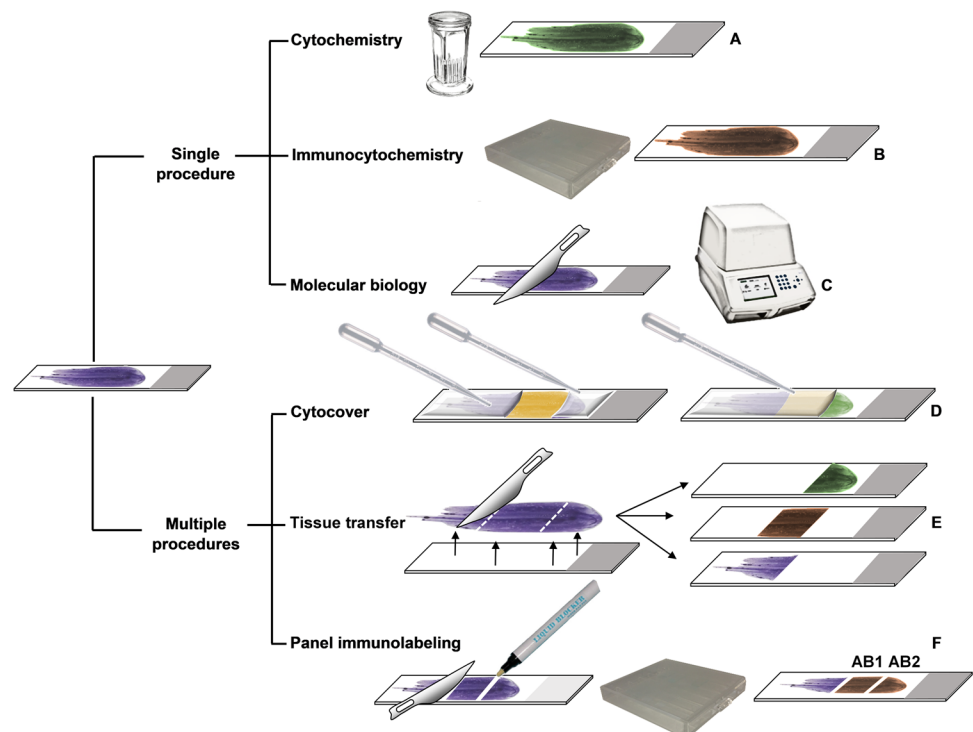
Removing the coverslip may not be needed as many veterinary practitioners do not coverslip their cytologic preparations. Still, if slides were mounted [with Entellan™ (Merck), Cover-Quik™ (VWR Chemicals, Fontenay-sous-bois, France) or any other commercial media] the coverslip can be removed by immersing the slide in xylene (or xylene alternatives), a solvent of all routinely used synthetic mounting media. This step can be time-consuming in archival slides, since 4 days may be needed for slides mounted for 6 months

or more (Zhou et al. 2017). Various alternative methods can be used to speed up the coverslip removal, differing only in the time needed. Slides may be put at  $-20^{\circ}\text{C}$  for a couple of minutes (Cunha Santos et al. 2013) or in liquid nitrogen for 30 s (Zhou et al. 2017). Then, the coverslip is removed with a scalpel blade (Cunha Santos et al. 2013; Zhou et al. 2017). Alternatively, the slides can be immersed in hot ( $56^{\circ}\text{C}$ ) xylene and the coverslip can be removed in a few hours (Karigoudar et al. 2019).

### Single procedure

This section reviews applications involving the entire cytological preparation. In such cases, the original Romanowsky-stained slides are lost or completely modified. This may have legal implications. For instance in human medicine, the College of American Pathologists (CAP) and Clinical Laboratory Improvement Amendments (CLIA) defined that fine needle aspirate (FNA) slides have to be retained for at least 10 years after the date of examination for positive cases and 5 years for negative cases or suspicious ones (CLIA 2020). According to CAP, digital images used for primary diagnosis also have to be retained for 10 years. This time frame is similar among veterinary pathologists (MacMillan and La Regione 2020). Therefore, if Romanowsky-stained cytologic features need to be preserved, multiple procedure strategies can be followed (described in the next section of this review). Alternatively, if digital whole slide scanning resources compliant to Good Laboratory Practices are

**Fig. 1** Schematic overview of the multiple uses of a cytologic smear. Single procedure refers to the full use of the smear (meaning that no Romanowsky-stain is retained) for special cytochemical staining (A), immunocytochemistry (B) or for molecular biology (C). In contrast, multiple procedures refer to the simultaneous application of different techniques, while retaining Romanowsky-stained material in part of the slide, which can be covered (D) or split and transferred to other slides (E). Multiple uses can also be achieved in manual immunocytochemistry (F), by applying several antibodies (AB1 and AB2) on the same slide, retaining the Romanowsky-stained area



available, slides may be scanned and stored or digital images can be taken of several areas of the slides.

## Cytochemical stains

Cytochemistry is generally fast and straightforward being extensively validated for cytological specimens in human (Sachdeva and Kline 1981) and veterinary medicine (Marcos et al. 2009). Cytochemistry may be used to demonstrate a variety of substances or pigments (e.g., Prussian blue for iron, Rhodanine for copper, Hall's for bilirubin), granules (e.g., Toluidine blue for mast cells), to highlight the presence of microorganisms (e.g., Gram for bacteria, Ziehl–Neelsen for acid-fast bacteria) or to determine cellular lineages (e.g., Davis et al. 2018). Cytochemical stains have been applied to Romanowsky-stained smears in a variety of conditions. To name a few examples, bacterial infections, including mycobacteria (Marcos et al. 2009; Stone and Gan 2014) have been highlighted; canine melanomas, myxosarcomas and osteosarcomas (Marcos et al. 2009; Ryseff and Bohn 2012) have been diagnosed; Copper and amyloid associated hepatopathies (Moore et al 2016; Stone and Gan 2014), and calcium related tissue deposits (Marcos et al. 2006; Ryseff et al. 2014) have been demonstrated (Table 1).

Cytochemistry can be applied to Romanowsky-stained smears with several advantages. The major one is that suspicious structures or findings can be compared to the previously-stained smear, which circumvents the variability in cellularity and representativeness between different smears (Marcos et al. 2009). For instance, slides left unstained may lack adequate material for evaluation resulting in false negative diagnosis. Cytochemical stains can even be used sequentially and this may be relevant for assessing fungal elements, especially when they are rare in the specimen. In that case, the use of periodic acid-Schiff (PAS) alone may miss them, but they can be highlighted by a second restaining with Grocott-Gomori methenamine silver (GMS) (Marcos et al. 2016). One study has reported 30% more hyphae and 35% more yeast-like organisms identified in PAS compared to Romanowsky-stained slides (Sampaio et al. 2017). Sequential staining with GMS amplified these figures especially for hyphae, allowing an easy differential diagnosis between hyphae and pseudohyphae (Sampaio et al. 2017) (Fig. 2). Besides fungal detection, cytochemical stains can be also used to determine if a pigment is iron, melanin or lipofuscin.

Usually, cytochemistry reacts with large chemical groups, present in different substances or organisms (e.g., Schiff reagent from PAS reacts with monosaccharide units, either present in glycogen, mucus or fungal walls). Therefore, these stains are less specific than immunocytochemistry (ICC) or molecular biology methods (Ramos-Vara et al. 2016). Overall, cytochemical stains can be applied either directly to Romanowsky-stained smears or following a destaining

step in an alcohol-acid solution (Marcos et al. 2009). Nevertheless, destaining may not be necessary if the restaining protocol includes immersion in acidic solutions (e.g., PAS or Masson-Fontana) (Marcos et al. 2009). It should be stressed that contrary to ICC and molecular biology techniques, the longtime storage of slides has no influence on cytochemical reactions (Marcos et al. 2009).

## Immunocytochemistry

Classic human pathology studies have demonstrated that immunostaining in both histologic and cytologic samples provide identical results in 90% of cases, and yields additional or essential information in 50% of cytology cases (Flens et al. 1990). With the advent of monoclonal antibodies and technical improvements in polymer detecting systems, these percentages have increased and the diagnostic value of ICC in human pathology, as well as in veterinary pathology, is nowadays undisputed (Fischer et al. 2014; Kirbis et al. 2020; Priest et al. 2017). Comparing to immunohistochemistry (IHC), ICC shares the same advantages of cytology itself: it has low invasiveness and short turn-around time, especially if rapid protocols are used (Sawa et al. 2017; Sawa et al. 2018); therefore, it is particularly valuable for rapid clinical decisions, when surgery or chemotherapy are going to be planned (Priest et al. 2017). Several fixatives and protocols have been proposed for ICC in cytopathology (Suthipintawong et al. 1996). Consequently, marked variability in protocols still prevails among diagnostic laboratories of human and veterinary pathology (Fischer et al. 2014; Kirbis et al. 2020; Raskin et al. 2019; Valli et al. 2009).

To perform ICC of solid lesions, a recent consensus among veterinarians recommended the submission of 3 unfixed and unstained, freshly prepared FNA smears: one for assessing cell morphology, one for the primary antibody, and one as a negative control (Priest et al. 2017). However, this number of slides may not be available, mainly because ICC is often not anticipated when submitting samples. Moreover, cellularity and cell preservation often vary between smears, and the inability to assess the quality of the smear prior to ICC may be a considerable limitation, leading to low diagnostic yield (Priest et al. 2017). This can be prevented by using previously stained slides (Raskin et al. 2019). With microscopic screening, only slides with representative or good quality material will be used for ICC (i.e., adequate cellularity, and without high hemodilution or ruptured cells that will produce heavy background). In fact, the first study in human pathology evaluating ICC in diagnostic cytology already reported that it could be performed in previously Papanicolaou-stained preparations (Nadji 1980). Likewise, one of the first reports of ICC in the veterinary field used a Romanowsky-stained smear, which was stained with a broad-spectrum cytokeratin antibody, since only one slide

**Table 1** Diagnostic techniques already performed on previously Romanowsky-stained slides (only a few examples are provided for illustrative purposes)

Method	Technique/Reagent	Diagnostic use/cells	References
Single Procedure			
Cytochemical stains	Ziehl–Neelsen	Mycobacteria	Marcos et al. 2009 Stone and Gan 2014
	PAS	Fungus	Marcos et al. 2016 Sampaio et al. 2017
	GMS	Fungus	Marcos et al. 2016 Sampaio et al. 2017
	Alcian-blue	Myxosarcoma	Marcos et al. 2009
	Masson-Fontana	Melanoma	Marcos et al. 2009
	Alkaline-Phosphatase	Osteosarcoma	Ryseff and Bohn 2012
	Rhodanine	Copper	Stone and Gan 2014
	Congo Red	Amyloid	Moore et al. 2016
	Von Kossa	Calcium	Marcos et al. 2006 Ryseff et al. 2014
Immunocytochemistry	Cytokeratin	Epithelial cells	Raskin et al. 2019 Sprague and Thrall 2001
	Vimentin	Mesenchymal cells and others*	Raskin et al. 2019
	CD3, CD20, PAX5, MUM1	Lymphoid cells	Dörfelt et al. 2019 Raskin et al. 2019 Stone and Gan 2014
	HLA-DR, Lysozyme	Macrophages	Raskin et al. 2019
	Melan-A	Melanoma	Raskin et al. 2019
	NeuN, GFAP	Neural cells	Dörfelt et al. 2019
	WT1	Mesothelial cells and others**	Marrinhas et al. 2022
	Molecular Biology	PCR	Fungus
Dirofilaria			Szatmári et al. 2020
Lymphoma			Burnett et al. 2003
Transmissible Venereal Tumor			Castro et al. 2017
Mast cell tumors			Downing et al. 2002
Urothelial/prostatic carcinoma			Decker et al. 2015
Multiple Procedures			
Cytocover	Cytochemical stains (Hall's and Perl's)	Billirubin	Present review
Tissue transfer	Cytochemical stains		Stone and Gan 2014
	Immunocytochemistry		Stone and Gan 2014
	PCR		Stone and Gan 2014
Panel immunolabeling	Immunocytochemistry (CD3, CD20)	Lymphoid cells	Raskin et al. 2019
	Immunocytochemistry (CD3, PAX5)	Lymphoid cells	Sampaio et al. 2021

\* including endothelial cells, renal tubular cells, macrophages, as well as fibroblasts, and leukocytes

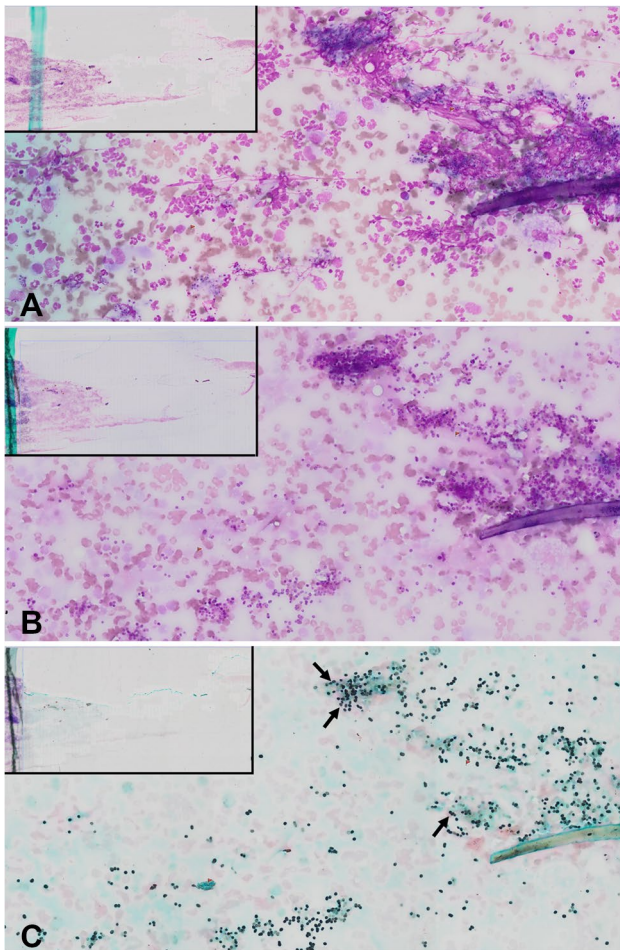
\*\* including glomerular podocytes, Sertoli cells (testis), stromal cells, surface epithelium and granulosa cells (ovary)

Periodic acid-Schiff (PAS), Grocott-Gomori methenamine silver (GMS), Multiple Myeloma 1 (MUM-1), Human Leukocyte Antigen (HLA-DR), Neuronal nuclear antigen (NeuN), Glial fibrillary acidic protein (GFAP), Wilms-tumor 1 (WT1)

had been submitted for diagnosis (Sprague and Thrall 2001) (Table 1).

Protocols usually include heat-induced antigen recovery, which is applied in IHC for formalin-fixed material. There is no need to previously destain the slides since all the Romanowsky-stain disappears during the heat-induced antigen recovery (Marcos et al. 2009). Still, adjusting the buffer's pH of antigen retrieval solutions may be necessary since

some leukocyte markers will call for high pH. Optimized protocols for ICC on Romanowsky-stained slides have been recently published (Raskin et al. 2019). Nowadays, all major cytologic categories of neoplasia (i.e., epithelial, mesenchymal and round cell) can be distinguished using ICC (Raskin et al. 2019) (Table 1). Protocols for ICC against cytokeratins, vimentin, Melan-A, Multiple Myeloma 1 (MUM-1), Human Leukocyte Antigen (HLA-DR) and Lysozyme, as well as



**Fig. 2** Pyogranulomatous inflammation in the skin of a dog. Various fungal organisms (later diagnosed as *Microsporium* spp.) can be seen among neutrophils and macrophages in aqueous Romanowsky (Hemacolor, Merck) (A). After restaining with periodic-acid Schiff (PAS) more organisms could be detected (B); a second restaining with Grocott–Gomori methenamine silver stain (applied over the PAS) highlighted more fungal organisms, especially when cells and debris overlapped (arrows) (C). After each staining procedure, the slides were scanned using the Olympus VS110 Virtual Slide Scanning System (Olympus, Japan) and the same areas of slide were compared

neuronal nuclear antigen and glial fibrillary acidic protein (GFAP) have been defined in veterinary medicine (Dörfelt et al. 2019; Raskin et al. 2019). Still, it should be kept in mind that several preprocessing factors may influence the immunostaining, such as the absence of coverslipping, the lag between Romanowsky staining and the immunoprocurement (Dörfelt et al. 2019), and the loss of material during ICC. Antigenicity has been reported to decrease after 4 weeks without previous staining (Aoki et al. 1991) or after 5 months from Romanowsky staining (Raskin et al. 2019). Therefore, if more time before ICC is expected, it is recommended to store slides at  $-70^{\circ}\text{C}$  (Skoog and Tani 2011). It is

noteworthy that despite all advances in ICC in recent years, there are still antigens (e.g., Feline Coronavirus) that cannot be highlighted by ICC in previously Romanowsky-stained slides (Dörfelt et al. 2019).

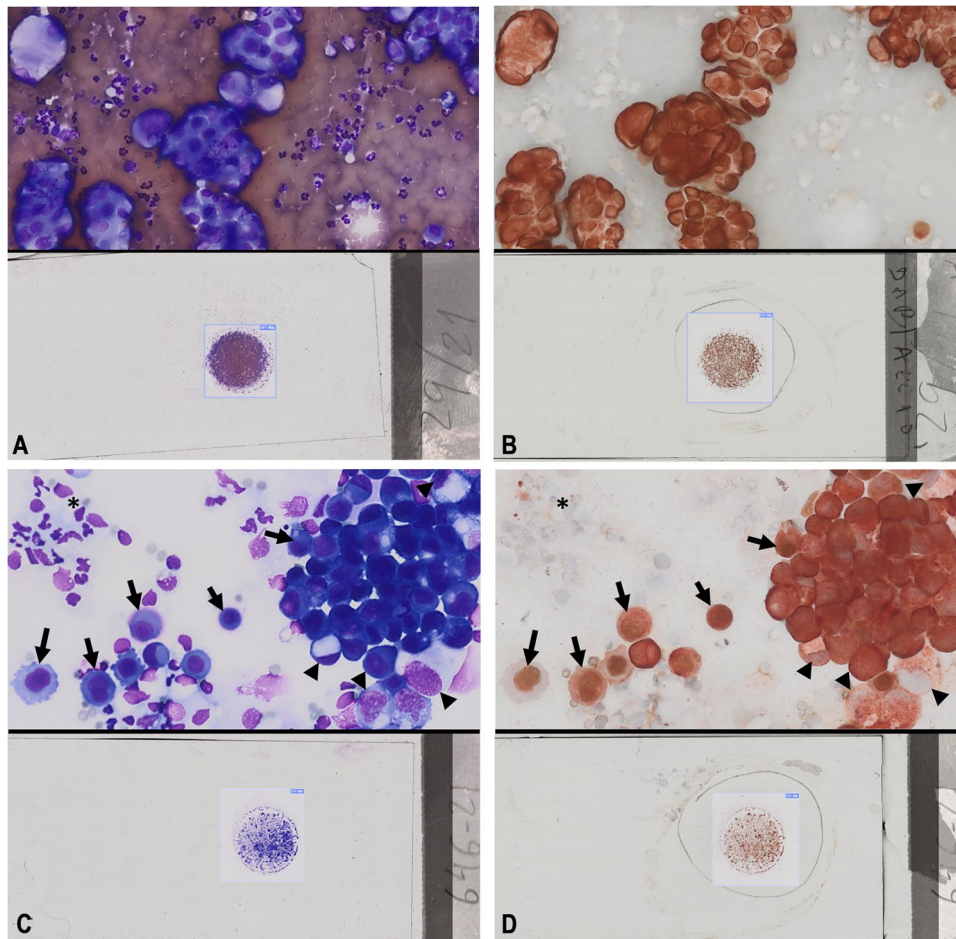
Both single ICC and double immunostaining can be performed in cytologic smears. For example, dual-color double ICC has been used to distinguish mesothelial cells from carcinoma cells in cavitory effusions, in both human and veterinary medicine (Conner et al. 2014; Marcos et al. 2019; Marrinhas et al. 2022), when limited slides are available (Fig. 3).

## Molecular biology

Routine cytology slides are a good source for molecular studies. According to some authors (Killian et al. 2010), preprocessing factors have a lower influence on molecular biology techniques, since the DNA is readily extractable and stable for up to five years or more (Killian et al. 2010). In human medicine it has been shown that the DNA quality in air-dried cytology slides is superior to formalin-fixed specimens (Huang and Wei 2020) and the assessments in the veterinary field point towards the same direction (Ehrhart et al. 2019). This quality is generally assessed by the DNA integrity number (DIN), which varies from 1 (highly degraded DNA) to 10 (mostly intact DNA). The crosslinking effects of formalin cause DNA fragmentation and oxidation that are dependent on formalin concentration, buffer and fixation time, thus decreasing DIN values. These effects may lead to false-negative or false-positive results (Einaga et al. 2017).

Cell collection from slides is usually attained by scraping the smear with a scalpel blade (Fig. 4), but cell lifting or cell transfer (see below) may also be used (Stone and Gan 2014). According to human pathology guidelines, a minimum of 50–100 cells or 200 cells are needed for mutation analysis, depending on the methodology (next-generation sequencing or traditional Sanger sequencing, respectively), and represent around 1.2 ng of DNA ( $\approx 6$  pg per cell) (Zhang and Yang 2016). Apart from these figures, a minimum proportion of tumor cells is mandatory and this might be readily evaluated in smears. As a rule of thumb, a minimum of 20% of tumor cells is needed. This allows the PCR amplification steps to favor the mutant template over the wild type (Zhang and Yang 2016).

There are multiple applications of molecular biology techniques in cytology samples in human medicine, aiming to diagnose from infectious to neoplastic diseases. The traditional way to diagnose pathogenic bacteria or viruses requires the specific collection of samples in conditions that favor their isolation followed by culture and confirmatory tests. In the case of slow-growing agents, it may take 7–10 days to identify some viruses, and this delay is extended up to 6–12 weeks for *Mycobacteria* (Canberck et al. 2016). In the particular case of *M. tuberculosis* in



**Fig. 3** Pleural effusions from one dog with a benign effusion (**A**, **B**) and a second dog with a malignant effusion (**C**, **D**) stained with a double immunocytochemistry protocol against pan-cytokeratins (AE1/AE3) and Wilms-tumor 1 (WT1), as a screening test for carcinomatous cells. (**A**) Top panel shows a cytocentrifuged preparation with isolated cells or small clusters Hemacolor stained (aqueous Romanowsky). (**B**) After the double immunocytochemistry, all cells have a strong brown nuclear positivity (WT1 antibody, Diaminobenzidine chromogen) and weak cytoplasmic red staining (AE1/AE3 antibody, Aminoethylcarbazole chromogen), which is consistent with mesothelial cells and a benign effusion; this was later confirmed by cell block immunohistochemistry and follow-up. (**C**) Bottom panel shows macrophages (asterisks), cell clusters of mesothelial cells

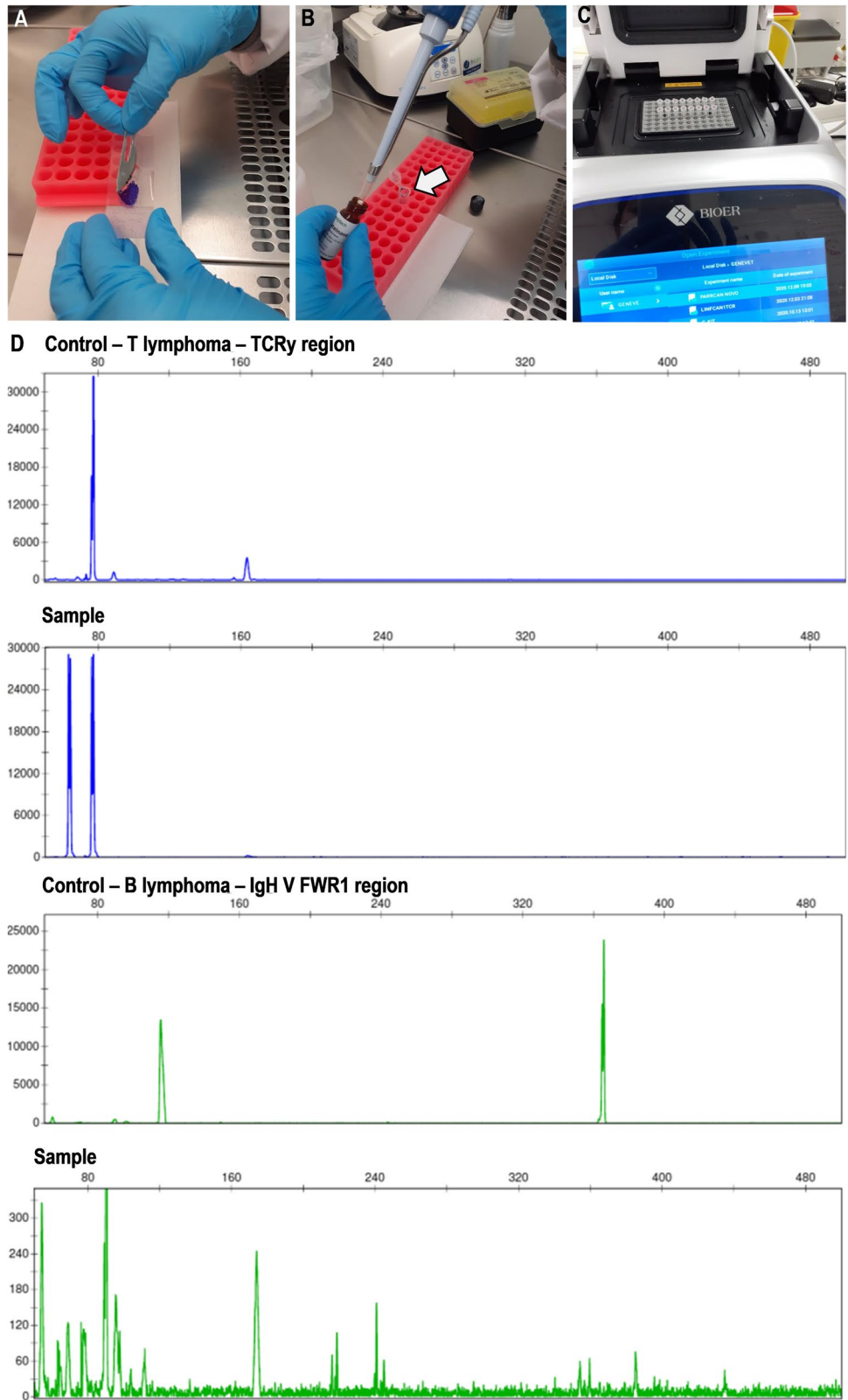
(arrows), intermingled with neoplastic carcinomatous cells (arrowheads) Hemacolor stained. (**D**) After the double immunocytochemistry, macrophages appear negative for both markers (asterisks), mesothelial cells have double positivity (arrows) (i.e., nuclear positivity with WT1 antibody, Diaminobenzidine chromogen, and cytoplasmic staining with AE1/AE3 antibody, Aminoethylcarbazole chromogen), whereas neoplastic carcinomatous cells have single positivity (arrowheads) (i.e., red cytoplasmic staining with AE1/AE3 antibody, Aminoethylcarbazole chromogen). In this double immunocytochemistry protocol, slides were first incubated with WT1, followed by an acidic glycine buffer rinse to elute these antibodies, and then incubated with pan-cytokeratin antibody

human samples, it has been shown that PCR provides high sensitivity and specificity, detecting more cases than culture or Ziehl–Neelsen stain (85% and 15%, respectively) (Purohit et al. 2008). Moreover, PCR has the advantage of determining the specific type of *Mycobacterium*, and does not require biosafety level facilities. This contrasts with the manipulation of sputum or unstained (and unfixed) smears that may still have viable bacilli.

Molecular biology methods have developed tremendously in veterinary medicine in recent years (Guillen et al. 2021). These methods are mainly used in infectious and neoplastic

diseases (Table 1). For instance, regarding *Mycobacteria*, it has been shown that PCR detects more cases than culture in experimentally infected dogs (Bonovska et al. 2005). Furthermore, the specific type of *Mycobacterium* can be highlighted. This is particularly important in cats that can be affected by *M. bovis*, *M. tuberculosis*, *M. avium*, *M. lepraemurium* and many other atypical ones (Lloret et al. 2013). PCR methods may also distinguish between pathogenic and less pathogenic organisms (e.g., *Dirofilaria immitis* microfilaria can be differentiated from the less pathogenic *D. repens* or *Acanthocheilonema dranculoides*) (Szatmári et al. 2020).

**Fig. 4** Fine needle aspiration of an enlarged lymph node submitted for molecular testing (PCR for antigen receptor rearrangement, PARR). After removing the coverslip, the smear was scraped (**A**) into a vial (arrow in **B**). After Proteinase K digestion (**B**), the DNA is extracted using commercial kits. After ensuring that sufficient DNA of good quality is present, PCR can be performed (**C**). The DNA products can be either sequenced or sorted in agarose gels or by capillary electrophoresis (**D**), in which the peaks of the sample are compared with control samples of T and B lymphomas. In this case, the sample was consistent with a T-cell lymphoma



Fungal infections can also be diagnosed by PCR using pan-fungal assays against the fungi’s ribosomal DNA gene cluster (Lau et al. 2007).

Another primary application is related to the diagnosis and management of neoplastic diseases (Guillen et al. 2021). Molecular biology tests are currently available in veterinary

medicine for lymphoma, chronic myeloid leukemia, urothelial/prostatic carcinoma, transmissible venereal tumor and mast cell tumors (Burnett et al. 2003; Castro et al. 2017; Cruz Cardona et al. 2011; Decker et al. 2015; Downing et al. 2002; Mochizuki et al. 2015). Among these, the PCR for antigen receptor rearrangement (PARR) is, by far, the most commonly used (Guillen et al. 2021). It has been reported that FNA of lymphomatous lymph nodes yield 7760 ng of DNA per slide with 4.8 DIN, on average, which is enough for PARR in most occasions (Ehrhart et al. 2019). This technique, besides the most common use of differentiating reactive from neoplastic lymphoid populations in lymph nodes (Fig. 4) (Burnett et al. 2003), may also help to differentiate between chronic enteropathy and lymphoma (Ohmura et al. 2017), thymoma and mediastinal lymphoma (Vessieres et al. 2018). The DNA product assessed by capillary electrophoresis can display a single length (monoclonal peak), thus corresponding to a monoclonal neoplastic proliferation, or display multiple lengths (polyclonal expansions), as expected in inflammatory conditions (Guillen et al. 2021). Several primers are used for the complementary region 3 of T cell receptor and immunoglobulin heavy chain genes (e.g., Melendez-Lazo et al. 2019; Waugh et al. 2016). Recent studies have reported high sensitivity with figures over 80% for different types of lymphomas (Goto-Koshino et al. 2015; Vessieres et al. 2018; Waugh et al. 2016). Specificity is usually high but can be negatively affected by infectious diseases such as ehrlichiosis or leishmaniasis (Burnett et al. 2003; Melendez-Lazo et al. 2019). In the latter, 10% of animals may present monoclonal or biclonal patterns, leading to false diagnosis. Other tumors like histiocytomas may also have a monoclonal or oligoclonal peak which, associated with a lymphocytic response at cytology, may also confound results (Keller et al. 2016). Traditionally, DNA fragments are assessed using polyacrylamide gel electrophoresis, but technical developments such as Sanger sequencing of DNA products or the capillary gel electrophoresis (Fig. 4) may enhance the precision of the PARR method (Guillen et al. 2021).

In cats, the PARR method has lower sensitivity compared to the dog. For T-cell lymphoma sensitivity  $\geq 79\%$  have been reported. Lower records (34 to 89%) have been reported for B-cell lymphoma (Rout et al. 2019). Still, the level of sensitivity may attain that of dogs, by assessing incomplete recombination of IgH loci and adding primers to additional regions of the B-cell receptor (Rout et al. 2019).

More recent technical developments in **molecular biology**, such as next generation sequencing, are already being applied in the veterinary field (Lee et al. 2021). These advances may increase the precision of existing molecular based methods, such as PARR, or may allow the development of novel diagnostic procedures, like microRNAs collected by FNA. These have already proved to be a valuable tool for classifying thyroid samples with indeterminate

cytology in human medicine (Lithwick-Yanai et al. 2017). Other techniques, such as Fluorescence in situ hybridization (FISH) may also be applied in previously stained samples (Richmond et al. 2006) and this method may help in the diagnosis of hematological malignancies (Cruz Cardona et al. 2011), as long as probes for fusion genes become available in veterinary medicine (Guillen et al. 2021).

### Multiple procedures on one slide

Cytologists often face single-slide scenarios due to a single slide submitted for diagnosis, or due to a single slide with representative material because the remaining slides have poorly preserved material or heavy blood contamination. Sometimes it seems that the number of available slides is inversely proportional to the difficulty of a case (Miller 2019). A recent human pathology survey identified low number of slides as the most frequent problem reported for ICC in smears (Kirbis et al. 2020). In those cases, sequential procedures can be carried out in the same slide. This section will focus on technical adjustments and diagnostic techniques which preserve part of the original Romanowsky-type stained material.

### Cell protection/cytocover

Tissue protection was originally described for small biopsies of human prostatic lesions. The technique is particularly useful when the paraffin block has limited material or further sections for IHC are not possible (Kubier and Miller 2002). Moreover, in prostatic biopsies suspicious lesions are sometimes restricted to a single section previously stained with Hematoxylin–Eosin (HE). To perform IHC on this section while preserving adjacent HE stained area, the latter is protected with mounting medium prior to the IHC procedure (Kubier and Miller 2002). The procedure was originally designed for sections on adhesive slides in which tissue transfer (addressed below) is not recommended (Miller 2019). The tissue protection technique has been also applied in human cytology (Miller and Kubier 2002), but never detailed in the veterinary field, to the best of our knowledge. We termed the cytologic version of tissue protection as “cytocover”. Cytocover consists of covering parts of the slide with mounting medium in order to preserve Romanowsky-stained regions while performing additional procedures on adjacent uncovered parts of the same slide, where suspicious cells or agents may be present. Several mounting media such as Entellan™ (Merck), Coverquick™™ (VWR), DPX™ (Merck) or ClearVue™™ (Thermo Scientific, Kalamazoo, MI, USA) are used (Miller and Kubier 2002 and Miller 2019).

After removing the coverslip (if present) and dipping the slide in xylene, mounting medium is added to cover the part



of the slide that will not be restained, leaving the part with the suspicious cells or agents completely uncovered. On the latter, several techniques may be applied depending on the cells or agents' nature, such as PAS, Mucicarmine and GMS to highlight the presence of *Cryptococcus* in a cytocentrifuged preparation (Marcos et al. 2016). Other cytochemical procedures may be used to highlight other fungi, bacteria or pigments in traditional FNA slides, such as the Hall's and Perl's Prussian Blue (Fig. 5). At the end of the procedure, the slide will have a Romanowsky-stained area (the cell cover area) and another restained one.

Care should be taken when choosing the restaining protocol in order to avoid acetone or other components that may dissolve the cell cover mounting medium (e.g., with Luxol fast blue stain for myelin, the mounting medium dissolves totally). The cytocover technique can also be used for ICC (Miller and Kubier 2002). In that case, no destaining step is needed for the uncovered area if heat-induced antigen

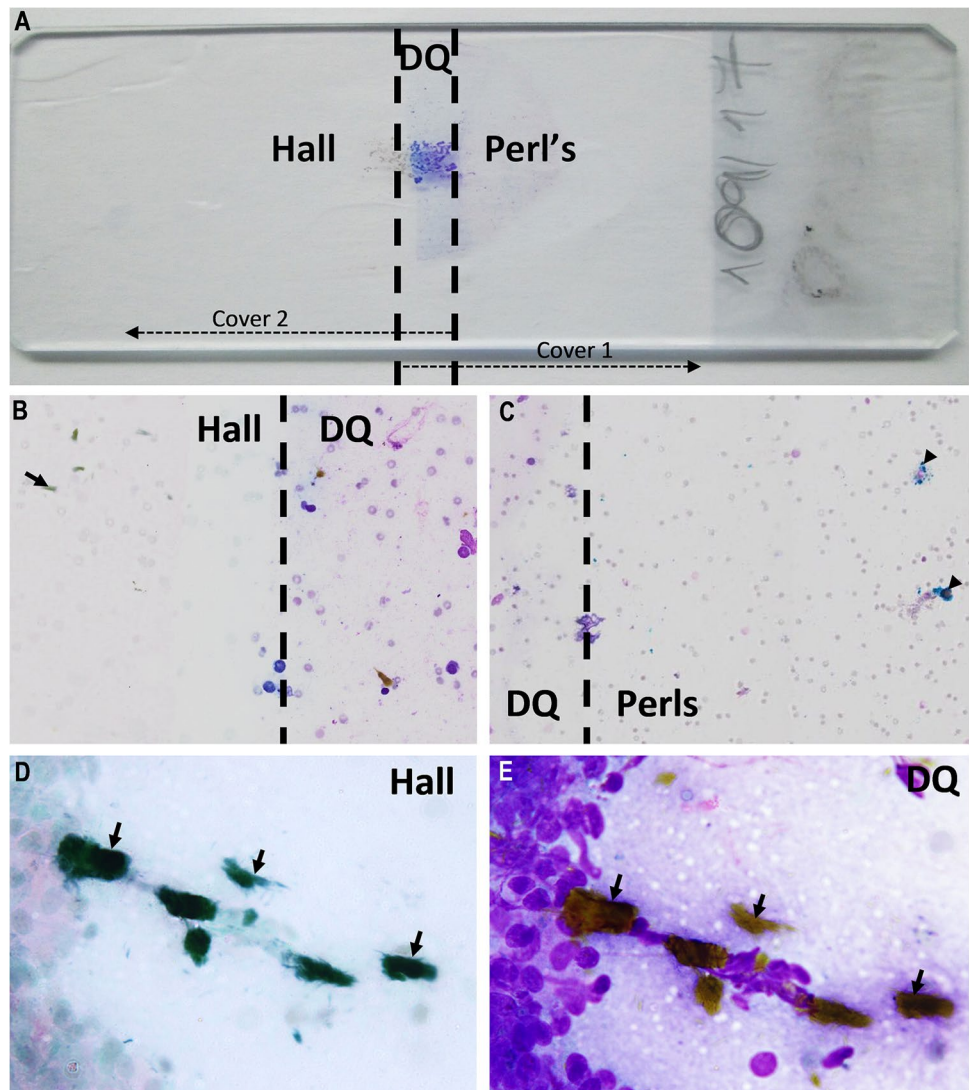
retrieval is included, as is usually done. The results are generally correlated with those of immunohistochemistry in the same tissues (Kubier and Miller 2002).

As a final remark, staining reagents should only be applied after the mounting medium has hardened (usually after 1 h). Cytocover may be challenging when the uncovered area is too small, because the mounting medium easily leaks to the uncovered area. In those cases, a thicker mounting medium should be applied with a small brush.

### Tissue transfer

Tissue transfer is an older technique that continues to be updated (Jimenez-Joseph and Gangi 1986; Morito et al. 2021; Sherman et al. 1994). The technique was initially developed for non-adhesive slides, allowing the generation of multiple slides from a single one. The main purpose was to solve the frequent dilemma of not having

**Fig. 5** Ascitic fluid of a dog, in which brown to greenish extracellular material was observed in Romanowsky staining (detailed in **E**). In order to elucidate the identity of this material, the right part of the slide was covered with mounting medium (cover 1 in **A**) and the Hall's staining was applied in the uncovered area (**B, D**). After immersing in xylene to remove the previous cover, a second application followed. The left part of the slide was now covered with mounting medium (cover 2 in **A**) and the Perl's Prussian Blue applied over the uncovered area (**C**). Note that besides biliary material (arrows in **B, D** and **E**, the latter two correspond to the same area), there were also hemosiderin that appeared blue in Perl's Prussian Blue (arrowheads in **C**). In this case, the sample was consistent with biliary peritonitis

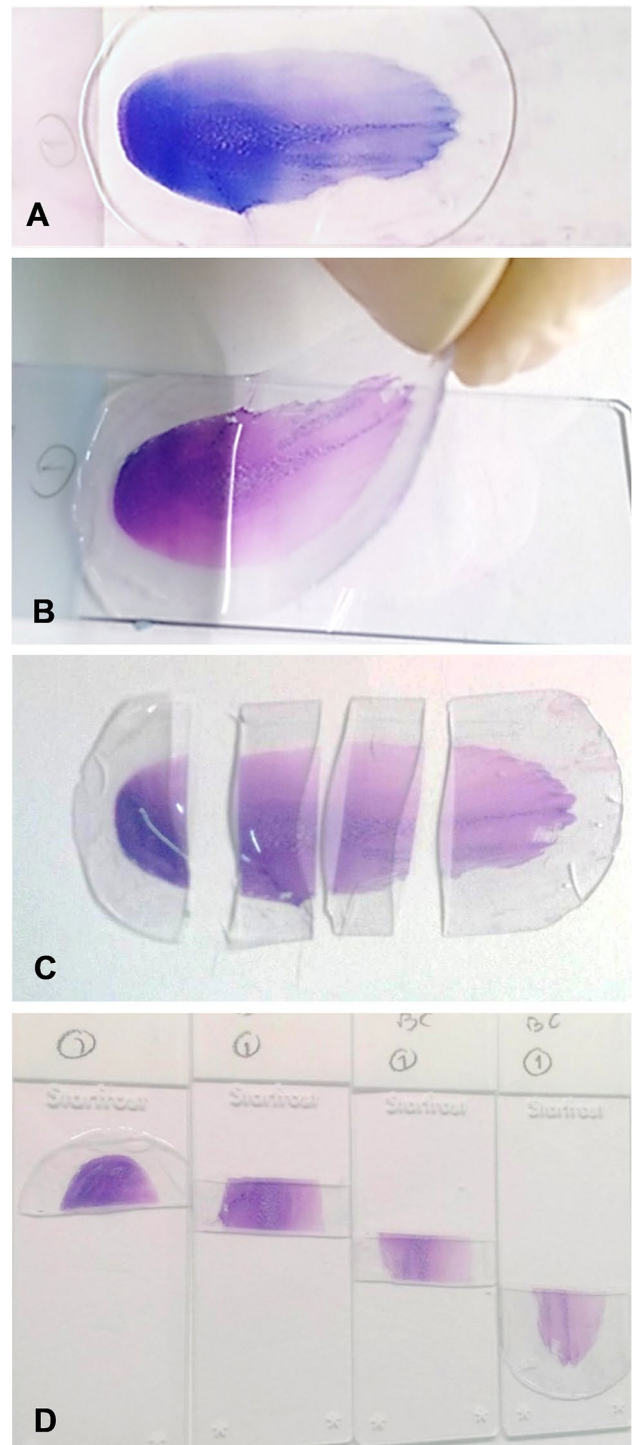


enough slides available for ICC (Kirbis et al. 2020). After removing the coverslip from the original slide, a thick layer of the mounting medium is added, and the slide is left in a laboratory drying oven at 60°C to let the mounting medium harden. The slide is then placed in a water bath at 60°C to soften the mounting medium, which is then peeled from the slide (with the material attached) and divided for several uses (Fig. 6). The original descriptions recommended a specific mounting medium (Mount Quick, Daido Sangyo, Tokyo, Japan), but several other media such as Pertex® (CellPath Ltd, Newtown, Powys, UK), Depex® (Serva Electrophoresis GmbH, Heidelberg, Germany) or Entellan® (Merck) have been successfully used (Stone and Gan 2014).

In human pathology, commonly used antibodies for ICC have been validated in cell-transferred material (Gong et al. 2005). In the veterinary field, the technique has been shown to be of value for cytochemical stains (Gram, PAS, Congo Red and Ziehl–Neelsen), ICC (immunophenotyping using CD3 and PAX5 for T and B-lymphocytes) and for molecular biology (PCR analysis) (Stone and Gan 2014) (Table 1). The method is useful when different heat-induced antigen retrieval protocols, for example low and high buffer pH, are required for various antibodies. When the same antigen retrieval protocol fits two antibodies, an immunolabeling panel can be applied on a slide, as described ahead.

In our hands, tissue transfer has been difficult to perform in old, archived slides, as well as in cases where cells are strongly attached to the slides (for example cyto-centrifuged preparations). In those cases, cells may be stretched or torn when peeled off from the slides, and may result in incomplete transfers.

Taking 3 to 40 h, the technique can be time-consuming, thus adding a day of turn-around time for the diagnosis (Marshall et al. 2014). Alternatively, the use of a nylon mesh may provide reliable transfers in only 30 min (Morito et al. 2021). This method is reported to be faster and safer since no scalpel blade is required. It is also very reliable because the transferred material is less prone to stretch or tear due to the mechanical support of the nylon mesh (Morito et al. 2021). It must be stressed that tissue transfer is a complementary technique that is usually only performed in selected cases. A retrospective study over a three-year period in a human medical laboratory (Marshall et al. 2014), reported that tissue transfer was used in only 1% of cases (152 out of 11,259). In those, ICC either confirmed or refined the cytological diagnosis, determined the origin of the neoplasia or provided information on estrogen/progesterone receptors in breast carcinomas, giving valuable prognostic and therapeutic information (Marshall et al. 2014).



**Fig. 6** Fine needle aspiration of a dog with enlarged lymph nodes submitted for tissue transfer (A). After heating the mounting medium (in a water bath at 60°C for 1 h), the medium is lifted from the slide (B), then clipped in pieces (C) and transferred to new slides (D). The receptor slides should be moistened and firm pressure should be applied after the transfer (for instance, the slides can be left overnight with even pressure applied under a heavy book)

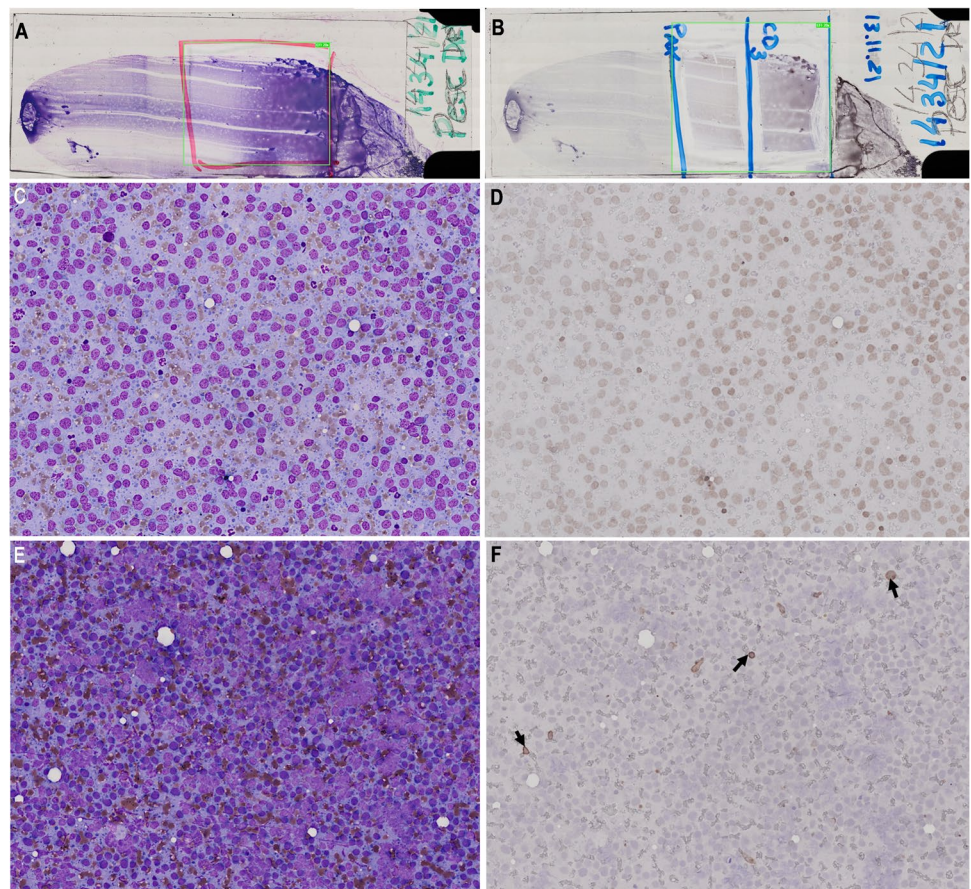
### Panel immunolabeling on the same slide

The use of two or more antibodies on the same slide is commonly used for immunophenotyping lymphomas in veterinary medicine (Raskin et al. 2019; Valli et al. 2009) (Table 1). For example, an antibody against CD3 is applied for T-lymphocytes over an area of the slide, while another area is covered with an antibody against B-lymphocytes (PAX5 or CD20), keeping the third area as a negative control (i.e., without primary antibodies) (Raskin et al. 2019). The technique relies on a slide of adequate cellularity and cell preservation, and the different ICC procedures should undergo the same antigen retrieval method (Raskin et al. 2019). Otherwise, multiple slides (if available) or a tissue transfer technique can be used.

Major pitfalls of panel immunolabeling include smear size, area separation and loss of material. Concerning the size, large smears should be used (Fig. 7). Smaller smears as it is the case of cytocentrifuged preparations, do not easily accommodate multiple separate areas. Area separation is another critical issue. Scraping out a borderline with a scalpel followed by application of a barrier

hydrophobic pen is recommended to avoid accidental diffusion of reagents (Raskin et al. 2019) (Fig. 1). The loss of material during ICC is a controversial pitfall. While some authors report this problem (Valli et al. 2009) and recommend the use of positive-charged slides for ICC (Ramos-Vara et al. 2016; Valli et al. 2009) as it is also recommended in human medicine (Dupré and Courtade-Saidi 2012; Fowler and Lachar 2008), others disregard this issue (Raskin et al. 2019). The use of positive-charged slides is far from being common in veterinary cytology because it is impractical and costly to have two sets of slides at the clinic (one for routine cytology and another for ICC). Substantial cell loss (6% to 13% of cases) occurs particularly when non-coverslipped and/or old archived slides are used for ICC (Sampaio et al. 2021). Loss of material can be readily identified when digitally Romanowsky-stained slides are directly compared with the immunostained slides (Sampaio et al. 2021). Obviously, tissue loss is more problematic in panel immunolabeling when a single slide is available. If several slides exist, the lost material can be replaced by using another smear for ICC, delaying the final diagnosis.

**Fig. 7** Fine needle aspiration of an enlarged lymph node submitted for panel immunocytochemistry against CD3, a marker of T lymphocytes and PAX5, a marker of B lymphocytes. The Romanowsky-stained slides were previously scanned using the Olympus VS110 Virtual Slide Scanning System and the same areas were compared before (A) and after the immunostaining (B). By comparing the same regions (C, D and E, F pairs) it is possible to disclose a positive nuclear immunoreactivity to PAX5 (D) meaning that a proliferation of neoplastic B lymphocytes was present, whereas only few scattered lymphocytes were positive for CD3 (arrows) (F)



## Conclusion

Cytology plays a key role in veterinary clinical practice. However, the diagnostic value of cytology specimens should not end on their observation at the microscope. The slides can be used for cytochemical, immunocytochemical and molecular biology techniques. These complementary techniques can confirm and refine the cytologic diagnosis or provide additional clinical or prognostic information. In the era of personalized veterinary medicine, the “doing more with less” principle should be considered when additional diagnostic or prognostic data is needed for tailoring the clinical management of a veterinary patient. Following this approach can avoid, at least in selected cases, the collection of additional samples, which could delay the diagnosis or contribute to morbidity through more invasive tests.

**Authors' contributions** Conceptualization: C. Marrinhas, R. Marcos. Methodology: C. Marrinhas, F. Malhão, C. Lopes. Formal Analysis and Investigation: C. Marrinhas, F. Sampaio, R. Moreira. Writing-original draft preparation: C. Marrinhas. Writing-review and editing: C. Marrinhas, F. Malhão, C. Lopes, F. Sampaio, R. Moreira, M. Santos, R. Marcos, M. Caniatti. Funding Acquisition: N/A. Resources: N/A. Supervision: M. Caniatti, M. Santos, R. Marcos.

**Data availability** The datasets included in this study are available from the corresponding author on a reasonable request.

## Declarations

**Ethical Approval** This study involved material submitted for diagnostic purposes and material included in research projects; ethical approval for these was granted by the ICBAS University Ethics Committee (P237/2017/ORBEA and P340/2019/ORBEA).

**Consent to participate** All listed authors have approved to participate in the manuscript.

**Conflict of interest** No conflict of interest has been declared.

## References

- Aoki J, Sasaki N, Hino N, Nanba K (1991) A study on the appropriate fixation for the procedures for the better preservation of cellular antigenicity and morphology of the blood smear in immunocytochemistry: an improvement of the immunostain technique using alkaline-phosphatase (ALP) as a labeling enzyme. *Rinsho Ketsusueki* 32:11–18
- Bonovska M, Tzvetkov Y, Najdenski H, Bachvarova Y (2005) PCR for detection of *Mycobacterium tuberculosis* in experimentally infected dogs. *J Vet Med B Infect Dis Vet Public Health* 52:165–170
- Burnett RC, Vernau W, Modiano J, Olver C, Moore P, Avery A (2003) Diagnosis of canine lymphoid neoplasia using clonal rearrangements of antigen receptor genes. *Vet Pathol* 40:32–41
- Canberk S, Longatto-Filho A, Schmitt F (2016) Molecular diagnosis of infectious diseases using cytological specimens. *Diagnostic Cytopathol* 44:156–164
- Castro KF, Strakova A, Tinucci-Costa M, Murchison EP (2017) Evaluation of a genetic assay for canine transmissible venereal tumour diagnosis in Brazil. *Vet Comp Oncol* 15:615–618
- CLIA (2020). College of American Pathologists and Clinical Laboratory Improvement Amendments CLIA, Regulations Record Retention. <https://elss.cap.org/elss/ShowProperty?nodePath=/UCMCON/Contribution%20Folders/WebApplications/pdf/retention-laboratory-records-and-materials.pdf> accessed 3–12–2021.
- Conner J, Cibas ES, Hornick J, Qian X (2014) Wilms tumor 1/ cytokeratin dual-color immunostaining reveals distinctive staining patterns in metastatic melanoma, metastatic carcinoma, and mesothelial cells in pleural fluids: An effective first-line test for the workup of malignant effusions. *Cancer Cytopathol* 122:586–595
- Cruz Cardona JA, Milner R, Alleman R, Williams C, Vernau W, Breen M, Tompkins M (2011) BCR-ABL translocation in a dog with chronic monocytic leukemia. *Vet Clin Pathol* 40:40–47
- Cunha Santos G, Schroeder M, Zhu JB, Saieg MA, Geddie WR, Boerner SL, McDonald S (2013) Minimizing delays in DNA retrieval: The “freezer method” for glass coverslip removal. *Cancer Cytopathol* 121:533
- Davis L, Hume K, Stokol T (2018) A retrospective review of acute myeloid leukaemia in 35 dogs diagnosed by a combination of morphologic findings, flow cytometric immunophenotyping and cytochemical staining results (2007–2015). *Vet Comp Oncol* 16:268–275
- Decker B, Parker HG, Dhawan D, Kwon EM, Karlins E, Davis B, Ramos-Vara JA, Bonney P, McNeil E, Knapp DW, Ostrander EA (2015) Homologous mutation to Human BRAF V600E is common in naturally occurring canine bladder cancer - Evidence for a relevant model system and urine-based diagnostic test. *Mol Cancer Res* 13:993–1002
- Dörfelt S, Matiasek L, Felten S, Sangl L, Hartmann K, Matiasek K (2019) Antigens under cover - The preservation and demasking of selected antigens for successful poststaining immunocytochemistry of effusion, brain smears, and lymph node aspirates. *Vet Clin Pathol* 48:98–107
- Downing S, Chien MB, Kass P, Moore P, London C (2002) Prevalence and importance of internal tandem duplications in exons 11 and 12 of c-kit in mast cell tumors of dogs. *Am J Vet Res* 63:1718–1723
- Dupré MC, Courtade-Saidi M (2012) Immunocytochemistry as an adjunct to diagnostic cytology. *Ann Pathol* 32:e47–e51
- Ehrhart EJ, Wong S, Richter K, Zismann V, Grimes C, Hendricks W, Khanna C (2019) Polymerase chain reaction for antigen receptor rearrangement: Benchmarking performance of a lymphoid clonality assay in diverse canine sample types. *J Vet Intern Med* 33:1392–1402
- Einaga N, Yoshida A, Noda H, Suemitsu M, Nakayama Y, Sakurada A, Kawaji Y, Yamaguchi H, Sasaki Y, Tokino T, Esumi M (2017) Assessment of the quality of DNA from various formalin-fixed paraffin-embedded (FFPE) tissues and the use of this DNA for next-generation sequencing (NGS) with no artifactual mutation. *PLoS ONE* 12:e0176280
- Fischer A, Schwartz M, Moriarty A, Wilbuer D, Souers R, Fatheree L, Booth C, Clayton A, Kurtz D, Padmanabhan V, Crothers B (2014) Immunohistochemistry practices of cytopathology laboratories: A survey of participants in the College of American Pathologists Nongynecologic Cytopathology Education Program. *Arch Pathol Lab Med* 138:1167–1172
- Flens MJ, Vand Der Valk P, Tadema T, Huysmans A, Risse E, Van Tol G, Meijer C (1990) The contribution of immunocytochemistry in diagnostic cytology. *Comp Eval Immunohistol Cancer* 65:2704–2711

- Fowler LJ, Lachar WA (2008) Application of immunohistochemistry to cytology. *Arch Pathol Lab Med* 132:373–383
- Gong Y, Joseph T, Sneige N (2005) Rapid Cell Transfer by Means of Nylon Mesh to Improve Cellular Diagnosis: The Role of Immunocytochemistry. *Cancer Cytopathol* 105:158–164
- Gonzalez M, Akhtar I, Manucha V (2017) Changing trends and practices in cytopathology. *Acta Cytol* 61:91–95
- Goto-Koshino Y, Mochizuki H, Sato M, Nakashima K, Hiyoshi S, Fujiwara-Igarashi A, Maeda S, Nakamura K, Uchida K, Fujino Y, Ohno K, Tsujimoto H (2015) Construction of a multicolor GeneScan analytical system to detect clonal rearrangements of immunoglobulin and T cell receptor genes in canine lymphoid tumors. *Vet Immunol Immunopathol* 165:81–87
- Guillen A, Smallwood K, Killick DR (2021) Molecular pathology in the cancer clinic – where are we now and where are we headed? *J Small Anim Pract* 62:507–520
- Huang M, Wei S (2020) Overview of molecular testing of cytology specimens. *Acta Cytol* 64:136–146
- Jimenez-Joseph D, Gangi MD (1986) Application of Diatex compound in cytology: use in preparing multiple slides from a single routine smear. *Acta Cytol* 30:446–447
- Karigoudar M, Kapse S, Shankar D, Sharma S, Yerraguntla D (2019) Alternative rapid methods for coverslip removal: a comparative study. *J Clin Diagn Res* 13:1–2
- Killian J, Walker R, Suuriniemi M, Jones L, Scurci S, Singh P, Cornelison R, Harmon S, Boisvert N, Zhu J, Wang Y, Bilke S, Davis S, Giaccone G, Smith W Jr, Meltzer P (2010) Archival fine-needle aspiration cytopathology (FNAC) samples: untapped resource for clinical molecular profiling. *J Mol Diagn* 12:739–745
- Kirbis IS, Roque R, Bongiovanni M, Flezar M, Cochand-Priollet B (2020) Immunocytochemistry practices in European cytopathology laboratories—review of European Federation of Cytology Societies (EFCS) online survey results with best practices recommendations. *Cancer Cytopathol* 128:757–766
- Kubier P, Miller RT (2002) Tissue protection immunohistochemistry: a useful adjunct in the interpretation of prostate biopsy specimens and other selected cases in which immunostains are needed on minute lesions. *Am J Clin Pathol* 117:194–198
- Lau A, Chen S, Sorrell T, Carter D, Malik R, Martin P, Halliday C (2007) Development and clinical application of a panfungal PCR assay to detect and identify fungal DNA in tissue specimens. *J Clin Microbiol* 45:380–385
- Lee G, Bienzle D, Keller S, Hwang M-H, Darzentas N, Chang H, Rätsep E, Egan R, Beeler-Marsifi J (2021) Use of immune repertoire sequencing to resolve discordant microscopic and immunochemical findings in a case of T cell-rich large B cell lymphoma in a young dog. *BMC Vet Res* 17:85
- Lithwick-Yanai G, Dromi N, Shtabsky A, Morgenstern S, Strenov Y, Feinmesser M et al (2017) Multicentre validation of a microRNA-based assay for diagnosing indeterminate thyroid nodules utilising fine needle aspirate smears. *J Clin Pathol* 70:500–507
- Lloret A, Hartmann K, Pennisi G-J, Addie D, Belák S et al (2013) Mycobacterioses in cats. ABCD guidelines on prevention and management. *J Fel Med Surg* 15:591–597
- MacMillan A, La Regione R (2020) Best practice recommendations. Storage and retention of animal tissues and records. The Royal College of Pathologists. G184-BPR-Storage-retention-animal-tissues-records.pdf (rcpath.org) Accessed on March 2022.
- Marcos R, Santos M, Santos N, Malhão F, Ferreira F, Monteiro RAF, Rocha E (2009) Use of destained cytology slides for the application of routine special stains. *Vet Clin Pathol* 38:94–102
- Marcos R, Malhão F, Santos J, Marques S, Thompson G, Santos M (2016) The cryptic *Cryptococcus*. *Vet Clin Pathol* 45:532–533
- Marcos R, Marrinhas C, Malhão F, Canadas A, Santos M, Caniatti M (2019) The cell tube block technique and an immunohistochemistry panel including Wilms tumor 1 to assist in diagnosing cavity effusions in dogs and cats. *Vet Clin Pathol* 48:50–60
- Marrinhas C, Lopes C, Santos M, Marcos R (2022) Mesothelial cells: The messed-up cells that make a confusion out of an effusion. *Vet Clin Pathol* 51:194–195
- Marshall A, Cramer H, Wu H (2014) The usefulness of the cell transfer technique for immunocytochemistry of fine-needle aspirates. *Cancer Cytopathol* 122:898–902
- Melendez-Lazo A, Jasensky AK, Jolly-Frahija I, Kehl A, Müller E, Mesa-Sánchez I (2019) Clonality testing in the lymph nodes from dogs with lymphadenomegaly due to *Leishmania infantum* infection. *PLoS ONE* 14:e0226336
- Miller RT (2019) Avoiding pitfalls in diagnostic immunohistochemistry—important technical aspects that every pathologist should know. *Sem Diagn Pathol* 36:312–335
- Miller RT, Kubier P (2002) Immunohistochemistry on cytologic specimens and previously stained slides (When no paraffin block is available). *J Histotechnol* 25:251–257
- Mochizuki H, Shapiro SG, Breen M (2015) Detection of BRAF mutation in urine DNA as a molecular diagnostic for canine urothelial and prostatic carcinoma. *PLoS ONE* 10:e0144170
- Moore AR, Coffey E, Hamar D (2016) Diagnostic accuracy of Wright-Giemsa and rhodanine stain protocols for detection and semi-quantitative grading of copper in canine liver aspirates. *Vet Clin Pathol* 45:689–697
- Morito S, Nitanda T, Tsukamoto R, Kamoshida S, Yasui H, Itoh T, Ohsaki H (2021) Rapid Cell Transfer by Means of Nylon Mesh to Improve Cellular Diagnosis: The Role of Immunocytochemistry. *Acta Cytol* 65:424–429
- Nadji M (1980) The potential value of immunoperoxidase techniques in diagnostic cytology. *Acta Cytol* 24:442–447
- Naylor B (2000) The century for cytopathology. *Acta Cytol* 44:709–725
- Ohmura S, Leipzig M, Schöpfer I, Hergt F, Weber K, Rütgen BC, Tsujimoto H, Hermanns W, Hirschberger J (2017) Detection of monoclonality in intestinal lymphoma with polymerase chain reaction for antigen receptor gene rearrangement analysis to differentiate from enteritis in dogs. *Vet Comp Oncol* 15:194–207
- Priest HL, Hume KR, Killick D, Kozicki A, Rizzo VL, Seelig D, Snyder LA, Springer NL, Wright ZM, Robat C (2017) The use, publication and future directions of immunocytochemistry in veterinary medicine: a consensus of the Oncology-Pathology Working Group. *Vet Comp Oncol* 15:868–880
- Purohit M, Mustafa T, Sviland L (2008) Detection of *Mycobacterium tuberculosis* by polymerase chain reaction with DNA eluted from aspirate smears of tuberculous lymphadenitis. *Diagn Mol Pathol* 17:174–178
- Ramos-Vara JA, Avery P, Avery A (2016) Advanced diagnostic techniques. In: Raskin RE, Meyer DJ (eds) *Canine and feline cytology. A color Atlas and Interpretation Guide*, 3<sup>rd</sup> edition, Elsevier, St Louis, pp. 453–494
- Raskin R, Vickers J, Ward J, Toland A, Torrance A (2019) Optimized immunocytochemistry using leukocyte and tissue markers on Romanowsky-stained slides from dogs and cats. *Vet Clin Pathol* 48:88–97
- Richmond J, Bryant R, Trotman W, Beatty B, Lunde J (2006) FISH detection of t(14;18) in follicular lymphoma on Papanicolaou-stained archival cytology slides. *Cancer Cytopathol* 108:198–204
- Rout ED, Burnett R, Yoshimoto J, Avery P, Avery A (2019) Assessment of immunoglobulin heavy chain, immunoglobulin light chain, and T-cell receptor clonality testing in the diagnosis of feline lymphoid neoplasia. *Vet Clin Pathol* 48:45–58
- Ryseff J, Bohn A (2012) Detection of alkaline phosphatase in canine cells previously stained with Wright-Giemsa and its utility in differentiating osteosarcoma from other mesenchymal tumors. *Vet Clin Pathol* 41:391–395

- Ryseff J, Duncan C, Sfiligoi G, Avery P (2014) Gamna-Gandy bodies: a case of mistaken identity in the spleen of a cat. *Vet Clin Pathol* 43:94–100
- Sachdeva R, Kline T (1981) Aspiration biopsy cytology and special stains. *Acta Cytol* 25:678–683
- Sampaio F, Lopes C, Malhão F, Correia-Gomes C, Caniatti M, Marcos R, Santos M (2017) Sequential use of special stains for the cytological diagnosis of fungal infections. in: Book of Abstracts of the XXII Meeting of the Portuguese Society of Animal Pathology, 2017 May 17–18, Porto, Portugal, p. 53
- Sampaio F, Marrinhas C, Oliveira L, Malhão F, Lopes C, Gregório H, Correia-Gomes C, Marcos R, Santos M (2021) Immunophenotyping in stained cytology smears and matched cell blocks of canine and feline lymphoid samples. In: Book of Abstracts of the 2021 European Society of Veterinary Clinical Pathology – European Colleague of Veterinary Clinical Pathology Meeting, 2021 October 13–16, pp. 43
- Sawa M, Inoue M, Yabuki A, Kohyama M, Miyoshi N, Setoguchi A, Yamato O (2017) Rapid immunocytochemistry for the detection of cytokeratin and vimentin: assessment of its diagnostic value in neoplastic diseases of dogs. *Vet Clin Pathol* 46:172–178
- Sawa M, Yabuki A, Kohyama M, Miyoshi N, Yamato O (2018) Rapid multiple immunofluorescent staining for the simultaneous detection of cytokeratin and vimentin in the cytology of canine tumors. *Vet Clin Pathol* 47:326–332
- Sharkey L, Seelig D, Overmann J (2014) All lesions great and small, part I: Diagnostic cytology in veterinary medicine. *Diagn Cytopathol* 42:535–543
- Sherman ME, Jimenez-Joseph D, Gangi MD, Rojas-Corona RR (1994) Immunostaining of small cytologic specimens. Facilitation with Cell Transfer. *Acta Cytol* 38:18–22
- Skog L, Tani E (2011) Immunocytochemistry: an indispensable technique in routine cytology. *Cytopathology* 22:215–229
- Sprague W, Thrall MA (2001) Recurrent skin mass from the digit of a dog. *Vet Clin Pathol* 30:189–192
- Stone B, Gan D (2014) Application of the tissue transfer technique in veterinary cytopathology. *Vet Clin Pathol* 43:295–302
- Suthipintawong C, Leong AS, Vinyuvat S (1996) Immunostaining of cell preparations: a comparative evaluation of common fixatives and protocols. *Diagn Cytopathol* 15:167–174
- Szatmári V, Leeuwen M, Piek C, Venco L (2020) False positive antigen test for *Dirofilaria immitis* after heat treatment of the blood sample in a microfilaremic dog infected with *Acanthocheilonema dracunculoides*. *Parasit Vectors* 13:501
- Valli V, Peters E, Williams C, Shipp L, Barger A, Chladny J, Hoffmann W (2009) Optimizing methods in immunocytochemistry: one laboratory's experience. *Vet Clin Pathol* 38:261–269
- Vessieres F, Rasotto R, Peters I, Villiers E, Berlato D, Cian F (2018) Assessment of lymphoid molecular clonality in canine thymoma. *J Comp Pathol* 158:66–70
- Waugh E, Gallagher A, Haining H, Johnston P, Marchesi F, Jarrett R, Morris J (2016) Optimisation and validation of a PCR for antigen receptor rearrangement (PARR) assay to detect clonality in canine lymphoid malignancies. *Vet Immunol Immunopathol* 182:115–124
- Zhang S, Yang B (2016) Development and validation of molecular testing on cytologic specimens. In: Yang B, Rao J (eds) *Molecular cytopathology, essentials in cytopathology* 26. Springer International, Bern, pp. 1–16
- Zhou W, Geiersbach K, Chadwick B (2017) Rapid removal of cytology slide coverslips for DNA and RNA isolation. *J Am Soc Cytopathol* 6:24–27

**Publisher's Note** Springer Nature remains neutral with regard to jurisdictional claims in published maps and institutional affiliations.