

HOSTED BY



ELSEVIER

Contents lists available at ScienceDirect

# Chinese Journal of Traumatology

journal homepage: <http://www.elsevier.com/locate/CJTEE>

## Case report

# Reconstruction and rehabilitation of short-range gunshot injury to lower part of face: A systematic approach of three cases

Ashutosh Vatsyayan\*, Apurba Kumar Adhyapok, Subhas Chandra Debnath, Kapil Malik

Department of Oral and Maxillofacial Surgery, Regional Dental College and Hospital, Bhangagarh, Guwahati 781032, Assam, India

## ARTICLE INFO

### Article history:

Received 12 February 2015

Received in revised form

7 January 2016

Accepted 13 January 2016

Available online 29 April 2016

### Keywords:

Maxillofacial injuries

Wounds

Gunshot

Firearms

## ABSTRACT

Gunshot injuries are always known to cause severe morbidity and mortality when head and neck are involved. They vary in morbidity, which can occur in civilian surroundings. The wound largely depends on the type of weapon, mass and velocity of the bullet, and the distance from where it has been shot. Close-range gunshot wounds in the head and neck region can result in devastating aesthetic and functional impairment. The complexity in facial skeletal anatomy cause multiple medical and surgical challenges to an operating surgeon, demanding elaborate soft and hard tissue reconstruction. Here we presented the successful management of three patients shot by short-range pistol with basic life support measures, wound management, reconstruction and rehabilitation.

© 2016 Daping Hospital and the Research Institute of Surgery of the Third Military Medical University.

Production and hosting by Elsevier B.V. This is an open access article under the CC BY-NC-ND license

(<http://creativecommons.org/licenses/by-nc-nd/4.0/>).

## Introduction

Gunshot wounds to the face present serious challenges to the oral and maxillofacial surgeons. These injuries result from assaults, accidents or suicide attempts. In contrast to blunt facial trauma, ballistic injuries result in significant bone and soft tissue loss, whose severity is not always apparent at initial presentation. Reconstruction of these defects is often complicated by tissue ischaemia, necrosis and infection.<sup>1,2</sup>

Ballistic injuries can be classified as low-velocity or high-velocity. Generally, low-velocity injuries are from projectiles travelling at less than 1200 feet/s. High-velocity missiles are those travelling at greater than 1200 feet/s. The degree of surrounding tissue injury from a gunshot wound is related to the mass of the projectile and the square of its velocity (kinetic energy =  $1/2 mv^2$ ).<sup>3</sup> Low-velocity injuries cause limited damage along the missile path and result in little bone and soft tissue loss. These are generally treated similarly to blunt facial trauma, with limited debridement, immediate bony reconstruction and primary soft tissue closure.<sup>4</sup>

High-velocity weapons, including rifles or close-range shotgun blasts, inflict considerably significant damage. In addition to the initial cavity created by the bullet path, an evolving pattern of tissue loss is observed, with resultant bone and soft tissue loss for several days or weeks.

Wounds are frequently contaminated with oral secretions and foreign materials, resulting in a complication rate as high as 39%.<sup>5</sup> Close-range gunshot wounds have a reported infection rate of 100%.<sup>6</sup> Traditional treatment of these injuries involves initial wound debridement and soft tissue closure without replacement of lost bone.<sup>1,7</sup>

Soft tissue injury, which could not be closed primarily, is allowed to be healed by secondary intention. Bony reconstruction is addressed secondarily, which often results in significant scar contracture and suboptimal cosmetic and functional outcome.

The past 10 years have seen a shift away from delayed treatment of these injuries towards immediate definitive reconstruction. This has been largely due to the increased use of free tissue transfer which allows importation of well vascularized bone and soft tissue into the wound.<sup>7</sup> Early transfer of vascularized tissue helps restore the bony and soft tissue framework while minimizing scar contracture.<sup>8,9</sup> Reconstruction of facial gunshot wound should proceed in a staged fashion to optimize form and function.<sup>10</sup> Our algorithm involves two phases, each with specific goals (Table 1). The two phases are the initial encounter and the definitive reconstruction.

\* Corresponding author. Tel.: +91 9878933112.

E-mail address: [dental@live.in](mailto:dental@live.in) (A. Vatsyayan).

Peer review under responsibility of Daping Hospital and the Research Institute of Surgery of the Third Military Medical University.

**Table 1**Algorithm of reconstruction after gunshot wounds or severe avulsive trauma to the face.<sup>10</sup>**Phase I: the initial encounter**

CABs of trauma management per ATLS protocols  
 Identification of life or limb-threatening injuries and stabilization of patient  
 Imaging once patient stabilized  
 CT scan head region to rule out head injury  
 Initial operating room management  
 Management of intracranial, ocular, and other life or limb-threatening injuries  
 Establishment of occlusal relationships  
 Debridement of foreign material and obviously nonviable tissue  
 ORIF of midface/mandibular fractures when adequate bone stock available

**Phase II: the definitive reconstruction**

Planning of definitive bony and soft tissue reconstruction  
 Importation of adequate soft tissue to allow cosmetic contouring  
 Reconstruction of major mandibular and maxillary defects  
 Free bone graft reconstruction of midface, upper face, nasal profile and peri-orbital area.  
 Adequate soft tissue coverage of underlying bone, internal and external defects

Note: ATLS: advanced trauma life support; ORIF: open reduction and internal fixation.

**Case report****Case 1**

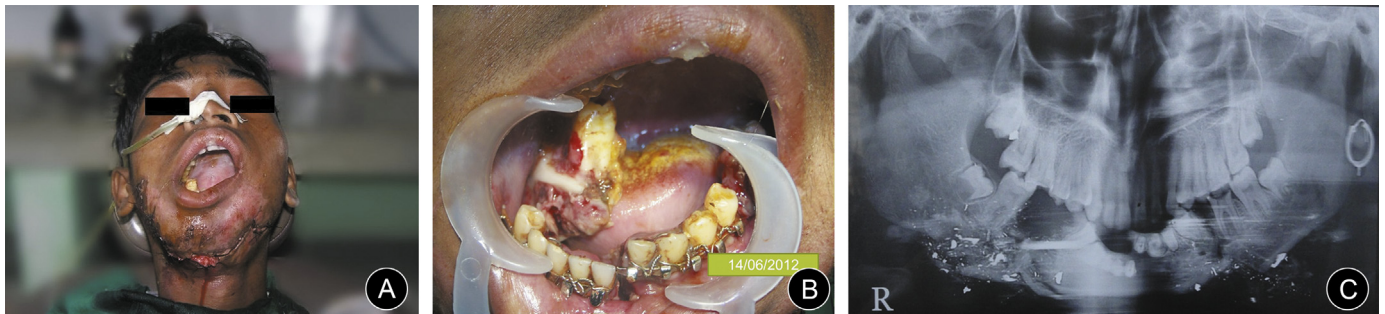
An 18-year-old male reported to the casualty department of Guwahati Medical College & Hospital at 6:00 p.m. on December 6, 2012, referred from Bongaigaon Civil Hospital, Assam, approximately 4 h after sustaining a bullet injury on the face. The patient was shot with the hand gun at a very short distance. The bullet entrance wound was in right submandibular region. Possible exit

wound for the bullet could be identified on left submandibular region. The patient was fully conscious, well oriented to time, place and person. His vital signs were within normal limits. On inspection, there were submandibular lacerating injury marks on both sides of mandible, multiple fractured segments visible in mandible on both sides. The patient was unable to close and open the mouth (Fig. 1A and B).

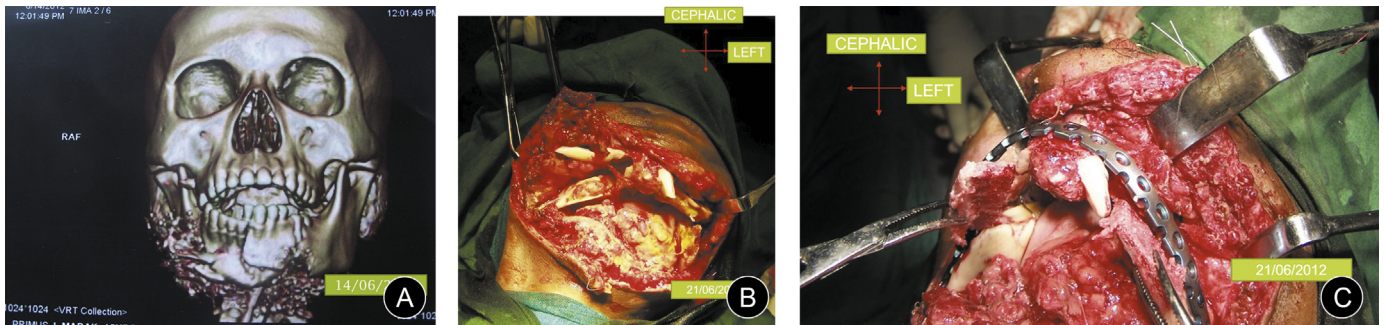
Provisional diagnosis was displaced right and left mandibular body fracture and middle symphysis fracture. Initial debridement of the lacerated non-vital soft tissue wound was done under local anaesthesia and soft tissue closure was done primarily where it was possible and within limits. The patient was then admitted in our ward and planned for operation under general anaesthesia and all the necessary routine investigations were advised along with orthopantomogram (OPG) (Fig. 1C), paranasal sinus X-ray (PNS) and CT scan (Fig. 2A).

In the operation room, surgical site was prepared and sub-mandibular incisions were given bilaterally along the already lacerated wound which was connected in the midline (Fig. 2B). Facial artery and vein were identified and ligated. Fracture site was exposed and after careful exploration, bullet fragments/pellets were removed. A 4.0 cm × 1.6 cm × 1.5 cm anterior iliac crest graft was harvested and then divided into two halves, which were placed at the avulsed site on both sides of body of mandible: the left graft was stabilized with 2-hole miniplate with gap and 2 mm × 6 mm screws along with a reconstruction plate and the right graft was stabilized with reconstruction plate alone (Fig. 2C).

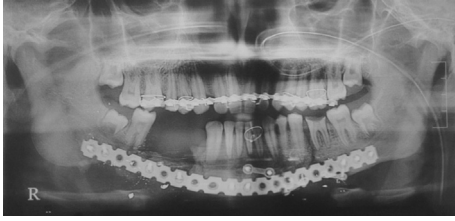One week after operation, the patient had infection in surgical wound on right body region of mandible, which was managed with intravenous antibiotics for 1 week. The healing was uneventful and good bone formation was apparent radiographically 2 months later (Fig. 3).



**Fig. 1.** A: Preoperative photograph of the patient with lacerating injury marks in the lower part of the chin. B: Multiple fractured segments visible in mandibles on both sides. C: Preoperative orthopantomogram view showing bilateral mandibular body fracture with middle symphysis fracture. Multiple radioopaque loose bony fragments and foreign pellets are seen around right side entry and left side exit wound region.



**Fig. 2.** A: CT scan in faciomaxillary region with three-dimensional reconstruction. B: Intraoperative exposure of the fractured mandible due to gunshot wound. C: Reconstruction plate placed from body to body of mandible.



**Fig. 3.** Orthopantomogram at postoperative 2 months with iliac crest bone graft stabilized with reconstruction plate on right side and 2.0 mm miniplates on left side. Multiple radioopaque foreign pellets are seen in bilateral mandibular body region.

**Case 2**

A 12-year-old male patient was admitted the casualty department of Guwahati Medical College and Hospital, Guwahati, approximately 8 h after sustaining a bullet injury on the face.

Entry wound was in the anterior mandibular alveolar region. During history taking, the patient revealed that the bullet fell outside the mandible after the impact through an exit wound present intraorally in the anterior mandibular region. After necessary CT/OPG (Fig. 4A) and general anaesthetic investigations, the patient was scheduled for surgical stabilization of mandible fracture under general anaesthesia. After fixation of arch bar, although the occlusion was not deranged, maxillomandibular fixation was performed. Comminuted fracture was fixed using a 2.0 mm continuous plate (Fig. 4B and C).

**Case 3**

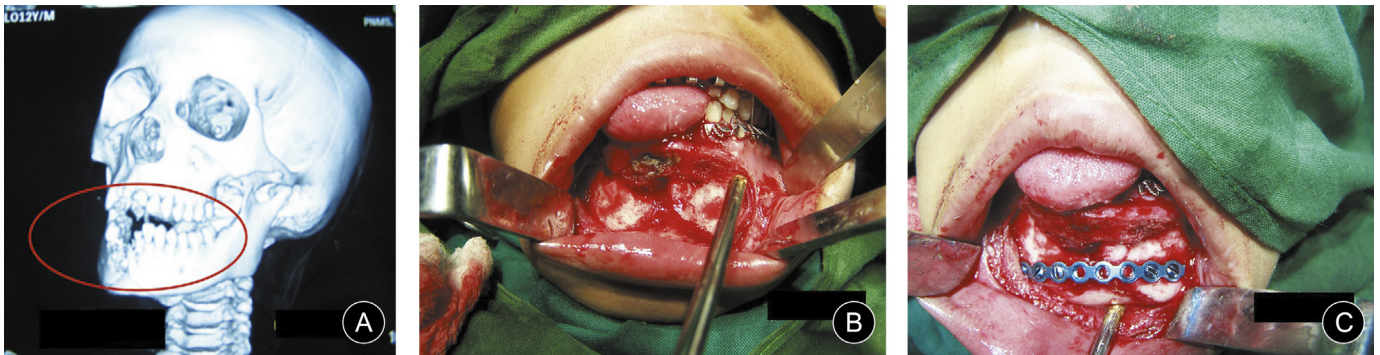
A 30-year-old male reported to the casualty department of Guwahati Medical College and Hospital, Guwahati, approximately 2 h after sustaining a bullet injury on the face.

The patient was shot with an indigenous made hand gun held from a short distance. The bullet entrance/exit wound was in left mandibular parasymphysis region (Fig. 5A and B). There was no derangement in occlusion. After necessary investigation, surgical exposure of fracture site was performed under general anaesthesia, and fixed using 2.0 mm continuous plate and lag screws (Figs. 5C and 6).

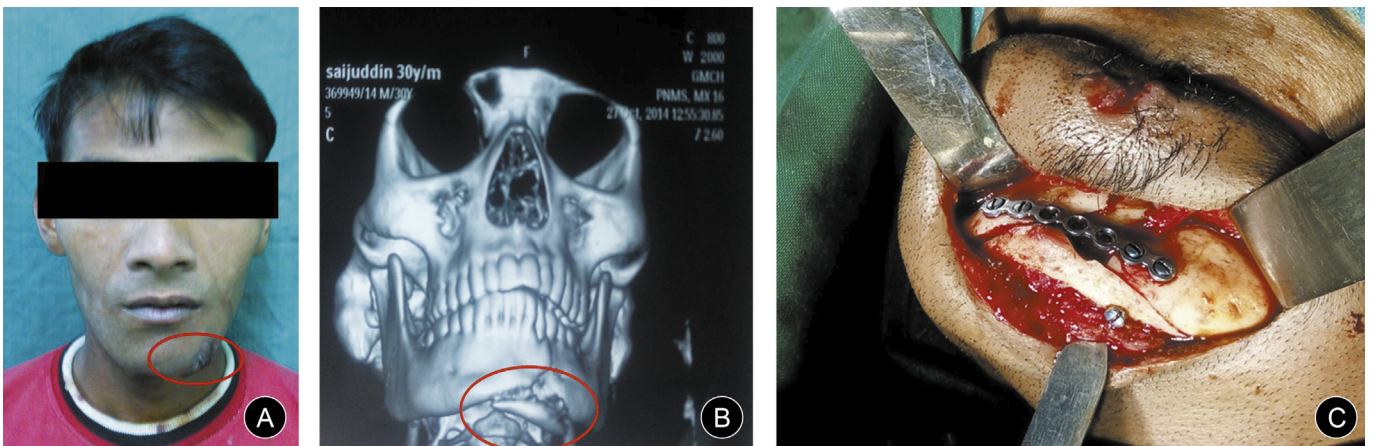
Table 2 summarizes the main information of the above-mentioned three cases of gunshot injuries.

**Discussion**

Bullets crushes structures along its track, causing temporary cavitation, shearing and compression, sometimes tears the structures (as with solid abdominal viscera) or stretching inelastic tissue (the brain). As tissues recoil and hot gases dissipate, soft tissue collapses inwards, and hence, a permanent cavity is formed. Additionally, kinetic energy transfer occurs during retardation of the bullet and this may cause damage outside the tract. Factors influencing the efficiency of kinetic energy transfer include the kinetic energy of a body, proportional to mass and velocity, projectile's deformation and fragmentation, entrance profile and path travelled through the body and biological characteristics of the tissues.<sup>11</sup>



**Fig. 4.** A: CT scan of the patient showing comminuted fracture of mandible. B: Surgical exposure of fracture segments. C: Fixation of fractured segment with 2 mm continuous plate.



**Fig. 5.** A: Extraoral view of the patient with gunshot injury. B: Three-dimensional reconstruction of CT faciomaxillary region. C: Adequate reduction of bone segments and fixation of fractured segments with 2 mm continuous plates and a lag screw.

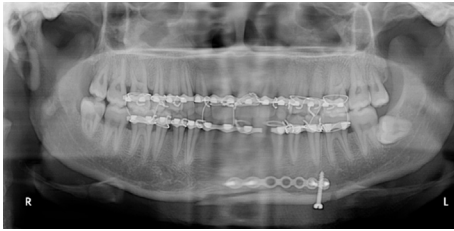


Fig. 6. Postoperative orthopantomogram after 1 week.

The maxillo-facial gunshot injuries are associated with a high mortality rate. The severity of these injuries varies depending on the calibre of the weapon used, distance, the mass and velocity of bullet (low velocity, less than 1000 feet/s and high velocity, more than 2000 feet/s). High-velocity injuries have traditionally been assumed to cause more damage than low-velocity ones have, an assumption that is still under dispute. A close-range, high-velocity gunshot wound can result in devastating facial disfigurement and disability in those who survive.

Airway management is a major concern in patients with maxillofacial ballistic injuries because a compromised airway can lead to death. Although there are many options to secure airway, each has specific indications, and the choice ultimately depends on the patient's situation and the expertise of the trauma team.<sup>12,13</sup>

In general, endotracheal intubation is usually not a viable option in cases of profuse bleeding from oronasal cavity. Cricothyroidotomy, tracheostomy or percutaneous needle tracheostomy are preferred to secure airway in emergencies. Other procedures for consideration are the submental or submandibular intubation techniques, which can provide a clear field for facial surgeries. Hollier et al<sup>13</sup> had shown that 21% of patients requiring tracheostomy had lower third facial injury.<sup>14</sup> This can be due to intraoral bleeding which prevents endotracheal intubation, distortion of oropharyngeal anatomy, and the fear of oedema compromising airway. All three cases were intubated nasotracheally because all cases involved trauma to mandible only. Tracheostomy was not required in all the three cases.

An early and comprehensive surgical management of soft tissue at the first stage with less aggressive debridement can decrease morbidity. A primary closure or local flaps are preferred over secondary healing as it may cause excessive scarring. Fractured bone pieces should be aligned if attached to muscle and periosteum, and the plate fixation should be done according to the AO/ASIF principles of rigid fixation. Immediate bone grafting should be considered provided soft tissue is adequate to achieve a watertight closure.<sup>15,16</sup>

In our cases, the patients were treated in two stages. First, we accomplished wound debridement by removing nonviable tissue, loose bone fragments, loose and irrevocable teeth, and retrieval of superficial pellets under local anaesthesia followed by primary wound closure. Arch bars were placed and surgical reconstruction was done under general anaesthesia.

In gunshot wound injury, restoration of continuity of mandible is the most frequent requirement. Defects of mandible occur rarely after civilian trauma or road traffic accident, and bone graft is required only for malunion/non-union. Injury to lower 1/3rd of face as demonstrated in this case results in avulsion of mandible and associated soft tissue loss. Sometimes extent of soft tissue injury is much that available soft tissue bed for future bone graft is unfavourable in terms of bulk and vascularity, which is different from the cases which needed bone graft after resection of part of jaw for benign neoplasm.

It has been demonstrated that early surgical debridement plays an important role in minimizing the ultimate loss of tissue.<sup>17</sup> Entry and exit wounds can be closed primarily following careful debridement and extensive irrigation. Owing to the excellent blood supply in the head and neck, primary closure is the treatment of choice.<sup>18</sup> Only obviously nonviable tissue should be removed along with debris. Fractured un-restored teeth with pulp exposure, which are of no use in immobilization of the fracture, may be extracted provided that the removal causes no loss of alveolar bone. If retention of such teeth is necessary, endodontic therapy or extraction should be considered 4–6 weeks after bone consolidation.

At the second stage in case 1, mandibular defect was reconstructed using the iliac crest graft through an extraoral approach. Free microvascular tissue grafts are also preferred for implant placement several months later to reduce graft bone resorption.<sup>16</sup>

Literature showed that retrieval of metal debris is important because the lead is soluble in serum and systemic lead toxicity has been reported as early as 2 d after injury.<sup>19</sup> However, some authors also pointed out that if the bullet/fragments are lodged deep within the soft tissue with no functional deficit or major aesthetic defect, it could be left in place. If the wound becomes grossly infected or causes significant discomfort, surgical intervention is initiated with removal of the bullet and debridement of the wound if required.

Antibiotics play a major role in preventing infections in both hard and soft tissues after primary closure of class IV wounds. Appropriate wound debridement, immobilization and fixation, detailed wound closure, drainage and maintenance of clean dressings, nutrition and circulating fluid volume are equally important. The haemodynamics of the patient should be addressed as the oxygen-carrying capacity influences both wound healing and prevention of infection.<sup>17,18</sup> The penetrating injuries to the face can cause minor or major devastating consequences. The general condition of the patient, timing and treatment sequencing, extent of damage, proper reconstruction method and rehabilitation are helpful for the final functional and aesthetic outcome.<sup>16</sup>

Even with a comprehensive primary management approach, penetrating maxillofacial injuries are associated with a significant number of residual problems. The majority of these, however, can be addressed as an outpatient basis.<sup>20</sup> Treatment options necessitate clinical judgement and no strict protocol can be uniformly applied to all patients. With the antibiotics and surgical hardware at hand, the majority of maxillofacial penetrating injuries can be treated definitively at the time of debridement when the general

Table 2  
Summary of the three cases.

Case No.	Age	Injury	Treatment	Follow-up
1	18	Avulsed right and left body segment of mandible	Debridement of wound, followed by reconstruction with iliac crest bone graft and reconstruction plate	3 mon
2	12	Middle-symphysis fracture	Open reduction and fixation using a 2.0 mm continuous plate	2 mon
3	20	Left parasymphysis fracture	Open reduction and fixation using a 2.0 mm continuous plate and lag screws	2 mon

Note: Case 1 had postoperative complication of surgical wound infection.

status of the patient permits and when this is in the best interest of the patient.

Immediate basic life support, fluid resuscitation and appropriate management of soft and hard tissue damage can stabilize the patient's condition. Early operative repair of facial fractures resulting from blunt trauma and reconstitution of soft tissue is critical for obtaining an optimal result, which could be done with rigid fixation techniques. Fixation failure may result in bone displacement, scarring of soft tissue, even bone defect. If hard tissues are found to be scattered and displaced rather than be avulsed, the location and stabilization is better than aggressive debridement, which devitalizes and strips the fragments from their attachments in fear of sequestration. Thus proper timing and staging of operations, minimizing secondary revisions and prevention of revision operation are of utmost importance in this respect.<sup>17</sup>

## References

1. Thorne CH. Gunshot wounds to the face. Current concepts. *Clin Plast Surg.* 1992;19:233–244.
2. Clark N, Birely B, Manson PN, et al. High energy ballistic and avulsive facial injuries: classification, patterns, and an algorithm for primary reconstruction. *Plast Reconstr Surg.* 1996;98:583–601.
3. DeMuth Jr WE. The mechanism of shotgun wounds. *J Trauma.* 1971;11:219–229.
4. Vayvada H, Menderes A, Yilmaz M, et al. Management of close-range, high energy shotgun and rifle wounds to the face. *J Craniofac Surg.* 2005;16:794–804.
5. Kihitir T, Ivatury RR, Simon RJ, et al. Early management of civilian gunshot wounds to the face. *J Trauma.* 1993;35:569–575.
6. Suominen E, Tukiainen E. Close range shotgun and rifle injuries to the face. *Clin Plast Surg.* 2001;28:323–337.
7. Gruss JS, Antonyshyn O, Phillips JH. Early definitive bone and soft-tissue reconstruction of major gunshot wounds of the face. *Plast Reconstr Surg.* 1991;87:436–450.
8. Olding M, Winski FV, Aulisi E. Emergency free flap reconstruction of a facial gunshot wound. *Ann Plast Surg.* 1993;31:82–86.
9. Vitkus K, Vitkus M. Microsurgical reconstruction of shotgun-blast wounds to the face. *J Reconstr Microsurg.* 1990;6:279–286.
10. Futran ND, Farwell DG, Smith RB, et al. Definitive management of severe facial trauma utilizing free tissue transfer. *Otolaryngol Head Neck Surg.* 2005;132:75–85.
11. Newgard K. The physiological effects of handgun bullets: the mechanisms of wounding and incapacitation. *Wound Ballist Rev.* 1992;1:7–12.
12. Lindsey D. The idolatry of velocity, or lies, damn lies, and ballistics. *J Trauma.* 1980;20:1068–1069.
13. Hollier L, Grantcharova EP, Kattash M. Facial gunshot wounds: a 4-year experience. *J Oral Maxillofac Surg.* 2001;59:277–282.
14. Mohan R, Iyer R, Thaller S. Airway management in patients with facial trauma. *J Craniofac Surg.* 2009;20:21–23. <http://dx.doi.org/10.1097/SCS.0b013e318190327a>.
15. Baig MA. Current trends in the management of maxillofacial trauma. *Ann R Australas Coll Dent Surg.* 2002;16:123–127.
16. Motamedi MH. Primary treatment of penetrating injuries to the face. *J Oral Maxillofac Surg.* 2007;65:1215–1218.
17. Osborne TE, Bays RA. Pathophysiology and management of gunshot wounds to the face. In: Fonseca RJ, Walker RV, eds. *Oral and Maxillofacial Trauma.* vol. 2. Philadelphia, PA: Saunders; 1991:672–679.
18. Shelton DW. Gunshot wounds. In: Peterson LJ, Indresano AT, Marciani RD, eds. *Principles of Oral and Maxillofacial Surgery.* vol. 2. Philadelphia, PA: JB Lippincott; 1992:596–614.
19. Bartlett CS, Helfet DL, Hausman MR, et al. Ballistics and gunshot wounds: effects on musculoskeletal tissues. *J Am Acad Orthop Surg.* 2000;8:21–36.
20. Ordog GJ, Wasserberger J, Balasubramaniam S, et al. Civilian gunshot wounds-outpatient management. *J Trauma.* 1994;36:106–111.