

# Effects of Hemosiderosis on Epilepsy Following Subarachnoid Hemorrhage

Tsukasa HIRANO,<sup>1</sup> Rei ENATSU,<sup>1</sup> Satoshi IIHOSHI,<sup>1</sup> Takeshi MIKAMI,<sup>1</sup>  
Toshimi HONMA,<sup>2</sup> Hirofumi OHNISHI,<sup>3</sup> and Nobuhiro MIKUNI<sup>1</sup>

<sup>1</sup>Department of Neurosurgery, Sapporo Medical University, Sapporo, Hokkaido, Japan;

<sup>2</sup>Department of Neurosurgery, Oji General Hospital, Tomakomai, Hokkaido, Japan

<sup>3</sup>Department of Public Health, Sapporo Medical University, Sapporo, Hokkaido, Japan;

## Abstract

Epilepsy after aneurysmal subarachnoid hemorrhage (post-SAH epilepsy) is a critical complication that influences clinical and social prognoses. However, the underlying mechanisms remain unclear. We investigated the relationship between hemosiderosis and the incidence of post-SAH epilepsy. About 50 patients with aneurysmal SAH who were admitted to Sapporo Medical University and Oji General Hospital between April 2010 and June 2016 were enrolled in this retrospective study. Hemosiderosis detected by T2\*-weighted magnetic resonance imaging (MRI) and the incidence of post-SAH epilepsy were retrospectively analyzed. Post-SAH epilepsy was defined as an unprovoked seizure occurring more than 1 week after the onset of SAH. Six patients (12%) developed post-SAH epilepsy. In all patients, hemosiderosis in the cortex or cerebral parenchyma was detected by T2\*-weighted MRI. Statistical analyses revealed that hemosiderosis and the co-existence of intracerebral hemorrhage (ICH) related with post-SAH epilepsy (Fisher's exact test, univariate exact logistic regression analysis:  $P < 0.05$ ). Post-SAH epilepsy was predicted by hemosiderosis and the co-existence of ICH. The present results suggest that hemosiderin is the principal cause of post-SAH epilepsy and may be a predictor of this critical complication.

Key words: hemosiderosis, subarachnoid hemorrhage, epilepsy, seizure

## Introduction

Subarachnoid hemorrhage (SAH) accounts for only 5% of all strokes, whereas it is a fatal disease and occurs at a younger age than intracerebral hemorrhage or cerebral infarction.<sup>1)</sup> Although advances in the medical and surgical management of SAH have decreased mortality rates, approximately 50% of SAH survivors are severely disabled, and the quality of life of most of these patients is negatively affected.<sup>2,3)</sup> The diagnosis and management of SAH remains challenging.

Epilepsy is one of several complications following SAH. Previous studies reported that the incidence of SAH-related epilepsy is between 7 and 12%.<sup>4-6)</sup> Independent risk factors for epilepsy include a young age, ischemia and post-operative vasospasms, a poor neurological grade, aneurysms located in the anterior circulation, hypertension, intracerebral

hemorrhage, large cisternal hemorrhage, acute seizure, rebleeding, and hydrocephalus.<sup>4-9)</sup> Since epilepsy is associated with a poor functional status and emotional health,<sup>10)</sup> it is important to elucidate the underlying mechanisms of and risk factors for epilepsy following SAH.

In the present study, we retrospectively evaluated the relationship between hemosiderosis detected by magnetic resonance imaging (MRI) and epilepsy following SAH.

## Materials and Methods

### Patients

Patients with SAH admitted to Sapporo Medical University Hospital and Oji General Hospital between April 2010 and June 2016 were enrolled in this retrospective study. SAH was diagnosed based on admission CT or MRI. All patients were treated with microsurgical clipping or endovascular therapy. Inclusion criteria were as follows: (1) Patients diagnosed with SAH due to the rupture of saccular or dissecting aneurysms; (2) patients who underwent T2\*-weighted imaging (T2\*WI) more than 30 days

Received June 5, 2018; Accepted November 8, 2018

Copyright© 2019 by The Japan Neurosurgical Society  
This work is licensed under a Creative Commons Attribution-NonCommercial-NoDerivatives International License.

after admission. Exclusion criteria included: (1) SAH by causes other than the rupture of aneurysms (e.g., traumatic SAH, arteriovenous malformation, and hypertensive intracerebral hemorrhage); (2) a previous medical history of epilepsy before SAH. This retrospective study was approved by the Institutional Review Board Committee of Sapporo Medical University (IRB #282-112).

### Definition of SAH-related epilepsy

In the present study, the diagnosis of epilepsy followed the definition of International League Against Epilepsy:<sup>11)</sup> (1) At least two unprovoked seizures occurring >24 hours apart, or (2) one unprovoked seizure with a high probability of further seizures e.g., seizures due to brain infarction, ICH, or status epilepticus. Post-SAH epilepsy was defined as epilepsy diagnosed at least 1 week after SAH. Acute seizures within 1 week of the onset of SAH were not regarded as unprovoked seizures.

### Assessment of hemosiderosis

Hemosiderosis was assessed by T2\*WI. T2\*WI was performed using the 3-T MR scanner (Signa HDxt 3.0T version16, GE Healthcare, Fairfield, CT, USA) in Sapporo Medical University Hospital and the 1.5-T MR scanner (Ingenia 1.5T, Philips healthcare, Amsterdam, The Netherlands) in Oji General Hospital. The scanning parameters for T2\*WI were as follows: TR: 550–560 ms, TE: 15–25 ms, flip angle: 25°, and slice thickness: 4–6 mm. Although signal loss in T2\*WI may represent hemosiderin, physiological ferritin, calcification, air, melanoma, and some paramagnetic contrast agents, T2\*WI is a sensitive method for detecting the deposition of hemosiderin<sup>12)</sup> (Fig. 1). Two neurosurgeons (RE and TH) blinded to clinical information independently evaluated the T2\*WI of each patient to detect the

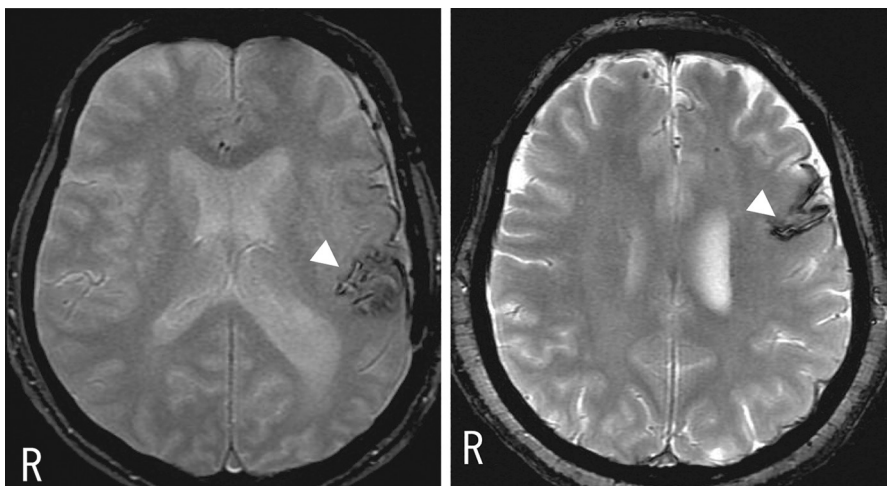
presence or absence of hemosiderosis. Hemosiderosis was established by consensus between the two reviewers.

### Statistical analysis

Groups were compared using Fisher's exact test with IBM SPSS Statistics version 22 (IBM Corp., Armonk, NY, USA). The odds ratio (OR) of each risk factor was then calculated with a univariate exact logistic regression using Stata Statistical Software: Release 15 (StataCorp LLC, College Station, TX, USA). A probability (*P*) value of  $\leq 0.05$  was regarded as significant.

## Results

About 50 patients were enrolled in this study (29 patients in Sapporo Medical University Hospital and 21 patients in Oji General Hospital). Patient characteristics are shown in Table 1. The mean age of patients was 62 years; 74% were women; 22% were WFNS-grade 1; 34% were grade 2; 2% were grade 3; 18% were grade 4, and 24% were grade 5 on admission. The most frequent locations of ruptured aneurysms in these patients were the internal carotid artery (32%) and anterior communicating artery (30%). Hemosiderosis and intracerebral hemorrhage (>15 cm<sup>3</sup>) were detected in 25 (50%) and six patients (6%), respectively. Twenty-three patients (46%) received prophylactic antiepileptic drugs (AED). Twenty-six patients (52%) achieved good outcomes [modified Rankin scale (mRS) 0 in 12 (24%), mRS 1 in 10 (20%), and mRS 2 in four patients (8%)], while 24 patients (48%) had poor outcomes [mRS 3 in seven (14%), mRS 4 in nine (18%), and mRS 5 in eight patients (16%)]. Microsurgical clipping was performed on 19 patients, endovascular coiling on 30, and medical treatment for one.



**Fig. 1** MRI of patients with hemosiderosis. T2\*-weighted images showing hypointensity rims around subarachnoid spaces and intraparenchyma (arrowhead), consistent with the deposition of hemosiderin.

**Table 1 Patient profiles**

Characteristics	Total no. (%)	Sz group no. (%)	Non-Sz group no. (%)	P-value	
Male	13 (26.0)	3 (50.0)	10 (22.7)	0.173	
Female	37 (74.0)	3 (50.0)	34 (77.3)		
Aneurysm location					
Anterior circulation	43 (86.0)	6 (100.0)	37 (84.0)	0.384	
IC	16 (32.0)	2 (33.3)	14 (31.8)		
Acom	15 (30.0)	1 (16.7)	14 (31.8)		
ACA	1 (2.0)	1 (16.7)	0 (0)		
MCA	11 (22.0)	2 (33.3)	9 (20.5)		
Posterior circulation	7 (14.0)	0 (0)	7 (15.9)		
BA	2 (4.0)	0 (0)	2 (4.5)		
VA	5 (10.0)	0 (0)	5 (11.4)		
WFNS grade					
Low WFNS grade	29 (58.0)	2 (33.3)	27 (61.4)		0.193
I	11 (22.0)	0 (0)	11 (25.0)		
II	17 (34.0)	2 (33.3)	15 (34.1)		
III	1 (2.0)	0 (0)	1 (2.3)		
High WFNS grade	21 (42.0)	4 (66.7)	17 (38.6)		
IV	9 (18.0)	1 (16.7)	8 (18.2)		
V	12 (24.0)	3 (50.0)	9 (20.5)		
Hemosiderosis					
Positive	25 (50.0)	6 (100.0)	19 (43.2)	0.011	
Negative	25 (50.0)	0 (0)	25 (56.8)		
ICH					
Positive	3 (6.0)	3 (50.0)	0 (0)	0.004	
Negative	47 (94.0)	3 (50.0)	100 (100)		
Prophylactic AED					
Positive	23 (46.0)	6 (100)	17 (38.6)	0.006	
Negative	27 (54.0)	0 (0)	27 (61.4)		
Cerebral infarction					
Positive	6 (12.0)	1 (16.7)	5 (11.4)	0.556	
Negative	44 (88.0)	5 (83.3)	39 (88.6)		
mRS					
Good outcome	26 (52.0)	1 (16.7)	25 (56.8)	0.078	
0	12 (24.0)	0	12 (27.3)		
1	10 (20.0)	0	10 (22.7)		
2	4 (8.0)	1 (16.7)	3 (6.8)		
Poor outcome	24 (48.0)	5 (83.3)	19 (43.2)		
3	7 (14.0)	1 (16.7)	6 (13.6)		
4	9 (18.0)	0	9 (20.5)		
5	8 (16.0)	4 (66.7)	4 (9.1)		
Treatment					
Clipping	20 (40)	4 (66.7)	16 (36.4)		0.164
Coiling	30 (60)	2 (33.3)	28 (63.6)		

ACA: anterior cerebral artery, Acom: anterior communicating artery, AED: antiepileptic drug, BA: basilar artery, IC: internal carotid artery, ICH: intracerebral hemorrhage, MCA: middle cerebral artery, Sz: seizure, VA: vertebral artery, WFNS: World Federation of Neurosurgical Society.

Six out of 50 patients (12%) developed post-SAH epilepsy. The characteristics of the six patients are shown in Table 2. Seizure types were classified into focal to bilateral tonic-clonic (FBTC) seizure in four patients and focal impaired awareness seizures in two [autonomic seizure (tachycardia) in one patient and cognitive seizure (aphasia) in the other] according to the 2017 ILAE seizure classification.<sup>13)</sup> Patients had their first seizures 2–65 weeks after SAH.

Hemosiderosis was observed in all six patients with post-SAH epilepsy. MRI detected hemosiderosis in all of these patients at the time of seizure occurrence. Hemosiderosis was not detected in 25 patients (50%), in whom seizures were not observed. Statistical analyses revealed a relationship between hemosiderosis and post-SAH epilepsy [Fisher's exact test;  $P = 0.011$ , univariate exact logistic regression analysis;  $P = 0.022$ , OR; 9.97, 95% confidence interval (CI); 1.33-inf] (Tables 1 and 3).

Computed tomography revealed intracerebral hemorrhages (>15 cm<sup>3</sup>) in three out of the six patients with post-SAH epilepsy, while 44 patients without epilepsy did not have intracerebral hemorrhage. A relationship was also found between intracerebral hemorrhage and post-SAH epilepsy (Fisher's exact test;  $P = 0.004$ , univariate exact logistic regression analysis;  $P = 0.002$ , OR; 40.43, 95% CI; 3.87-inf) (Tables 1 and 3).

All six patients with post-SAH epilepsy received prophylactic AED. A significant relationship was detected between prophylactic AED and post-SAH epilepsy (Fisher's exact test;  $P = 0.006$ , univariate exact logistic regression analysis;  $P = 0.0127$ , OR; 11.96, 95% CI; 1.6-inf) (Tables 1 and 3).

Six patients developed brain infarction due to cerebral vasospasms after SAH. One out of six patients developed post-SAH epilepsy. There was no significant relationship between brain infarction

due to vasospasms and post-SAH epilepsy (Fisher's exact test,  $P = 0.556$ ).

There was no significant difference in percentages of locations of ruptured aneurysms, severities of SAH (i.e. WFNS grade), and outcomes (i.e. mRS) between epilepsy group and non-epilepsy group (Fisher's exact test,  $P = 0.384$ , 0.193, and 0.078, respectively).

Among the six patients with post-SAH epilepsy, four underwent microsurgical clipping and two underwent endovascular coiling. There was no significant difference in percentages of treatment modalities for ruptured aneurysms, direct surgery vs endovascular therapy, between epilepsy group and non-epilepsy group (Fisher's exact test,  $P = 0.164$ ).

## Discussion

A previous study reported that the risk factors for epilepsy after aneurysmal SAH included the rupture of aneurysms in the anterior circulation, a young age, intracerebral hemorrhage, and a poor neurological outcome.<sup>14)</sup> In the present study, intracerebral hemorrhage and hemosiderosis correlated with post-SAH epilepsy, whereas the location of aneurysms, a poor WFNS grade and mRS were not associated with epilepsy.

Six patients (12%) developed epilepsy after SAH in the present study. This incidence was consistent with previous findings.<sup>4–6)</sup> However, a previous study reported that continuous EEG monitoring detected non-convulsive seizures (NCSz) and non-convulsive status epilepticus (NCSE) in approximately 10% of patients after aneurysmal SAH.<sup>15)</sup> Many patients in the present study were classified as having a poor WFNS grade and did not undergo continuous EEG monitoring; therefore, NCSz may have been overlooked. Continuous EEG monitoring may provide a more accurate incidence of post-SAH epilepsy.

**Table 2 Characteristics of patients with post-SAH epilepsy**

Patient	Age/Sex	WFNS grade	Aneurysm location	Location of hemosiderosis	ICH > 15 cm <sup>3</sup>	Modality	DCI	Onset after SAH (week)	Sz classification
1	54 F	II	Acom	Lateral frontal	–	Catheter	–	2	FBTC
2	66 M	IV	Lt. MCA	Temporal	–	Surgery	–	30	FIAS (cognitive)
3	66 M	V	Rt. MCA	Temporal	+	Surgery	–	2	FBTC
4	79 F	V	Rt. ACA	Medial frontal	+	Surgery	+	3	FIAS (autonomic)
5	78 F	V	Lt. IC	Temporal	–	Catheter	–	8	FBTC
6	73 M	II	Lt. IC	Temporal	+	Surgery	–	65	FBTCS

DCI: delayed cerebral ischemia, F: female, FBTC: focal to bilateral tonic-clonic, FIAS: focal impaired awareness seizure, Lt: left, M: male, Rt: Right, SAH: subarachnoid hemorrhage.

**Table 3 Risk factors for epilepsy (Univariate exact logistic regression analysis)**

Variable	P-value	OR (95% CI)
Hemosiderosis	0.022	9.97 (1.33-inf)
ICH	0.002	40.43 (3.87-inf)
Prophylactic AED	0.013	11.96 (1.6-inf)

Six patients developed post-SAH epilepsy, and hemosiderosis was observed in all of these patients. A relationship was noted between hemosiderosis and post-SAH epilepsy. T2\*WI is a sensitive tool for the detection of hemosiderin deposits,<sup>12)</sup> and thus may provide useful information for predicting post-SAH epilepsy. To the best of our knowledge, few studies have investigated the pathogenesis of post-SAH epilepsy, and the relationship between hemosiderosis and post-SAH epilepsy remains unclear. On the other hand, the effects of hemosiderin on epileptogenesis have been examined in patients with cerebral cavernous malformations (CCMs). The epileptogenesis of CCMs is mainly responsible for pathological changes in the adjacent brain tissue resulting from repeated microhemorrhage.<sup>16)</sup> Repeated microhemorrhage in brain tissue leads to the deposition of hemosiderin, which is a degradation product of ferritin. Hemosiderin acts as an electron donor in the production of free radicals and lipid peroxidases.<sup>17,18)</sup> Several intracellular reactions induced by radicals and free iron induce epileptogenic changes in brain tissues adjacent to CCMs.<sup>18)</sup> Furthermore, hemosiderin-induced neuronal cell injury may cause epileptogenic synaptic reorganization. We hypothesize that these mechanisms of hemosiderin-related epileptogenesis are also involved in post-SAH epilepsy. Structural focal epilepsy, such as post-SAH epilepsy, is induced by brain tissue injury, namely, neural cell injury. It currently remains unclear whether neural cell injuries in post-SAH epilepsy are caused by the abrupt destruction of brain tissue or induced by gradual processes associated with free iron and radicals in hemosiderosis.

In the present study, we found a significant relationship between intracerebral hemorrhage and post-SAH epilepsy, as previously described,<sup>14)</sup> whereas three patients without intracerebral hematoma developed late-onset epilepsy. In these patients, neural cell injury may have been induced by the latter process. The accumulation of more cases is needed to elucidate the mechanisms underlying epileptogenesis and neural cell injury in post-SAH epilepsy.

In this study, the odds ratio of prophylactic AED for post-SAH epilepsy was 11.96 by using a univariate

exact logistic regression analysis. This result suggests that prophylactic AED does not reduce the incidence of post-SAH seizures. Although we need to consider impact of several confounding factors, we could not use multivariate analysis because of small sample size. Further large-scale studies are needed to clarify the effect of prophylactic AED on post-SAH epilepsy.

Regarding treatment modalities, namely, direct surgery vs endovascular treatment, no relationships were observed with post-SAH epilepsy. The prospective International Subarachnoid Aneurysm Trial reported that the cumulative rates of epilepsy at 5 years were 6.4 and 9.6% after endovascular treatment and surgical clipping, respectively, and craniotomy was identified as an independent risk factor for epilepsy with HR 1.7.<sup>19)</sup> Since the sample size in the present study was limited, we were unable to reach any concrete conclusions about the relationship between treatment modalities and post-SAH epilepsy.

Several limitations of the present study need to be acknowledged. The study population was relatively small and the study design was retrospective. Thus, the applicable statistical analysis was limited and confounding factors may have affected the results obtained. The inclusion of a larger study population and appropriate statistical analyses (e.g. a multivariate analysis) will provide more precise information on the relationship between hemosiderosis and post-SAH epilepsy. Furthermore, continuous EEG monitoring was not performed in the present study. Hence, we may have overlooked NCSz or NCSE, and underestimated the incidence of epilepsy after SAH. Additionally, various AED were prophylactically prescribed to 17 patients at hospitalization or after surgery without a specific diagnosis of epilepsy. The prophylactic prescription of AED may have hampered evaluations of the incidence of epilepsy.

Despite these limitations, the present study demonstrated that hemosiderosis is closely related to epilepsy after aneurysmal SAH. Hemosiderosis detected by T2\*WI may predict epilepsy after SAH.

### Conflicts of Interest Disclosure

The authors have no personal financial or institutional interests in any of the drugs, materials, or devices described in this manuscript.

### References

- 1) van Gijn J, Kerr RS, Rinkel GJ: Subarachnoid haemorrhage. *Lancet* 369: 306–318, 2007

- 2) Longstreth WT, Nelson LM, Koepsell TD, van Belle G: Clinical course of spontaneous subarachnoid hemorrhage: a population-based study in King County, Washington. *Neurology* 43: 712–718, 1993
- 3) Hop JW, Rinkel GJ, Algra A, van Gijn J: Quality of life in patients and partners after aneurysmal subarachnoid hemorrhage. *Stroke* 29: 798–804, 1998
- 4) Ukkola V, Heikkinen ER: Epilepsy after operative treatment of ruptured cerebral aneurysms. *Acta Neurochir (Wien)* 106: 115–118, 1990
- 5) Keränen T, Tapaninaho A, Hernesniemi J, Vapalahti M: Late epilepsy after aneurysm operations. *Neurosurgery* 17: 897–900, 1985
- 6) Bidziński J, Marchel A, Sherif A: Risk of epilepsy after aneurysm operations. *Acta Neurochir (Wien)* 119: 49–52, 1992
- 7) Lin YJ, Chang WN, Chang HW, et al.: Risk factors and outcome of seizures after spontaneous aneurysmal subarachnoid hemorrhage. *Eur J Neurol* 15: 451–457, 2008
- 8) Claassen J, Peery S, Kreiter KT, et al.: Predictors and clinical impact of epilepsy after subarachnoid hemorrhage. *Neurology* 60: 208–214, 2003
- 9) Byrne JV, Boardman P, Ioannidis I, Adcock J, Traill Z: Seizures after aneurysmal subarachnoid hemorrhage treated with coil embolization. *Neurosurgery* 52: 545–552, 2003
- 10) Leidy NK, Elixhauser A, Vickrey B, Means E, Willian MK: Seizure frequency and the health-related quality of life of adults with epilepsy. *Neurology* 53: 162–166, 1999
- 11) Fisher RS, Acevedo C, Arzimanoglou A, et al.: ILAE official report: a practical clinical definition of epilepsy. *Epilepsia* 55: 475–482, 2014
- 12) Imaizumi T, Chiba M, Honma T, Niwa J: Detection of hemosiderin deposition by T2\*-weighted MRI after subarachnoid hemorrhage. *Stroke* 34: 1693–1698, 2003
- 13) Fisher RS, Cross JH, French JA, et al.: Operational classification of seizure types by the International League Against Epilepsy: position paper of the ILAE commission for classification and terminology. *Epilepsia* 58: 522–530, 2017
- 14) Huttunen J, Kurki MI, von Und Zu Fraunberg M, et al.: Epilepsy after aneurysmal subarachnoid hemorrhage: a population-based, long-term follow-up study. *Neurology* 84: 2229–2237, 2015
- 15) Kondziella D, Friberg CK, Wellwood I, Reiffurth C, Fabricius M, Dreier JP: Continuous EEG monitoring in aneurysmal subarachnoid hemorrhage: a systematic review. *Neurocrit Care* 22: 450–461, 2015
- 16) Awad IA, Robinson JR Jr, Mohanty S, Estes ML: Mixed vascular malformations of the brain: clinical and pathogenetic considerations. *Neurosurgery* 33: 179–188, 1993
- 17) Kraemer DL, Awad IA: Vascular malformations and epilepsy: clinical considerations and basic mechanisms. *Epilepsia* 35 Suppl 6: S30–S43, 1994
- 18) Baumann CR, Schuknecht B, Lo Russo G, et al.: Seizure outcome after resection of cavernous malformations is better when surrounding hemosiderin-stained brain also is removed. *Epilepsia* 47: 563–566, 2006
- 19) Molyneux AJ, Kerr RS, Yu LM, et al., International Subarachnoid Aneurysm Trial (ISAT) Collaborative Group: International subarachnoid aneurysm trial (ISAT) of neurosurgical clipping versus endovascular coiling in 2143 patients with ruptured intracranial aneurysms: a randomised comparison of effects on survival, dependency, seizures, rebleeding, subgroups, and aneurysm occlusion. *Lancet* 366: 809–817, 2005

---

*Address reprint requests to:* Nobuhiro Mikuni, MD, PhD, Department of Neurosurgery, Sapporo Medical University, South 1, West 16, Chuo-ku, Sapporo, Hokkaido 060-8543, Japan.  
*e-mail:* mikunin@sapmed.ac.jp