



# Bilateral fibrodysplasia ossificans affecting the masticatory muscles and causing irreversible trismus in a domestic shorthair cat

*Journal of Feline Medicine and Surgery Open Reports*  
1–8

© The Author(s) 2019

Article reuse guidelines:

sagepub.com/journals-permissions

DOI: 10.1177/2055116919839857

journals.sagepub.com/home/jfmsopenreports

This paper was handled and processed by the European Editorial Office (ISFM) for publication in *JFMS Open Reports*



Michel Guzu<sup>1</sup>, Hugues A Gaillot<sup>1</sup>, Marco Rosati<sup>2</sup>,  
Alexandra Nicolier<sup>3</sup> and Philippe R Hennet<sup>1</sup>

## Abstract

**Case summary** An 8-year-old spayed female domestic shorthair cat was referred for trismus of progressive onset, which had started at least 1 month previously. The patient presented with weakness, anorexia, chronic bilateral purulent nasal discharge and concurrent reduced nasal airflow. Upon physical examination, painful mouth opening, bilateral swelling of the temporal areas, with an inability to open and close the mouth completely, were apparent. A vertical mandibular range of motion (vmROM) of 22 mm was noted. Complete blood count, biochemistry, electrolytes and various serology tests were unremarkable. CT revealed multiple mineralised lesions within the masticatory muscles. Histopathological features were consistent with those seen in the human disease fibrodysplasia ossificans progressiva (FOP). Supportive treatment did not improve the vmROM, eventually resulting in a 13 mm open bite, and total inability to close and open the mouth. Cardiac arrest occurred at the induction of an anaesthesia procedure aiming to perform tracheostomy and nasal lavage. Despite emergency tracheotomy and cardiac resuscitation, humane euthanasia was elected by the owners. Post-mortem molecular investigations highlighted a heterozygous deletion, compatible with a splicing site mutation in *ACVR1*, which is also associated with FOP in humans.

**Relevance and novel information** This is the first report in the veterinary literature of FOP-like disease selectively affecting the masticatory muscles. This condition is associated with a poor prognosis, as no medical or surgical treatment has currently proven to be of any prophylactic or curative benefit. Although rare, FOP-like disease should be included in the differential diagnosis of trismus in the cat. Any further muscle injury should be avoided.

**Keywords:** Fibrodysplasia ossificans progressiva; trismus; BMP; *ACVR1*; masticatory muscles

**Accepted:** 5 March 2019

## Introduction

Fibrodysplasia ossificans progressiva (FOP), also known as myositis ossificans progressiva, Münchmeyer's disease and 'stone man syndrome', is an extremely rare autosomal dominant genetic disease involving *ACVR1*, which codes for the activin receptor-like kinase 2 receptor (ALK2) in people.<sup>1,2</sup> It results in dysregulation of the bone morphogenetic protein (BMP) pathways within the connective tissues.<sup>1,2</sup> Pathophysiology of the disease starts with minor soft-tissue injuries that trigger an inflammatory response leading to muscle injury and

<sup>1</sup>ADVETIA Specialists Referral Hospital, Vélizy-Villacoublay, France

<sup>2</sup>Section of Clinical and Comparative Neuropathology, Centre for Clinical Veterinary Medicine, Ludwig-Maximilians-Universität, Munich, Germany

<sup>3</sup>Vet Diagnostics, Lyon, France

### Corresponding author:

Michel Guzu DVM, Dentistry and Oromaxillofacial Surgery, ADVETIA Specialists Referral Hospital, 9 Avenue Louis Bréguet, 78140 Vélizy-Villacoublay, France  
Email: guzu@advetia.fr



Creative Commons Non Commercial CC BY-NC: This article is distributed under the terms of the Creative Commons

Attribution-NonCommercial 4.0 License (<http://www.creativecommons.org/licenses/by-nc/4.0/>) which permits non-commercial use, reproduction and distribution of the work without further permission provided the original work is attributed as specified on the SAGE and Open Access pages (<https://us.sagepub.com/en-us/nam/open-access-at-sage>).

necrosis, and subsequent fibroproliferation, maturing to endochondral bone formation. Regional swelling and great toe malformation of (bilateral hallux valgus) are also usually present in people.<sup>1,2</sup> Maxillofacial presentations affecting the masticatory muscles alone or together with extra-skeletal lesions elsewhere in the patient, resulting in unresolving trismus, have been reported in humans.<sup>3-7</sup> No medical or surgical treatment has yet been proven to give any prophylactic or curative effect. Corticosteroids, non-steroidal anti-inflammatory drugs, retinoids and bisphosphonates have been used for treatment but seem to be of limited efficacy.<sup>1</sup> FOP carries a poor prognosis.<sup>1,2</sup>

FOP-like conditions affecting various areas of the spine, trunk and legs have been previously reported in 11 cats.<sup>8-16</sup> Terms such as generalised myositis ossificans, fibrodysplasia ossificans, progressive ossifying myositis, FOP and FOP-like disease have been used as alternatives to describe the disease. However, in only one reported feline case has similar genetic abnormality to that described in humans been identified.<sup>14</sup> The term FOP should be reserved for those cases where the genetic abnormality has been identified; otherwise, the term 'FOP-like' should be used. The term 'myositis' should be restricted to non-hereditary forms of heterotopic ossification such as myositis ossificans circumscripta.<sup>16</sup> To our knowledge, this clinical case is the first report in the veterinary literature of a FOP-like condition involving the masticatory muscles.

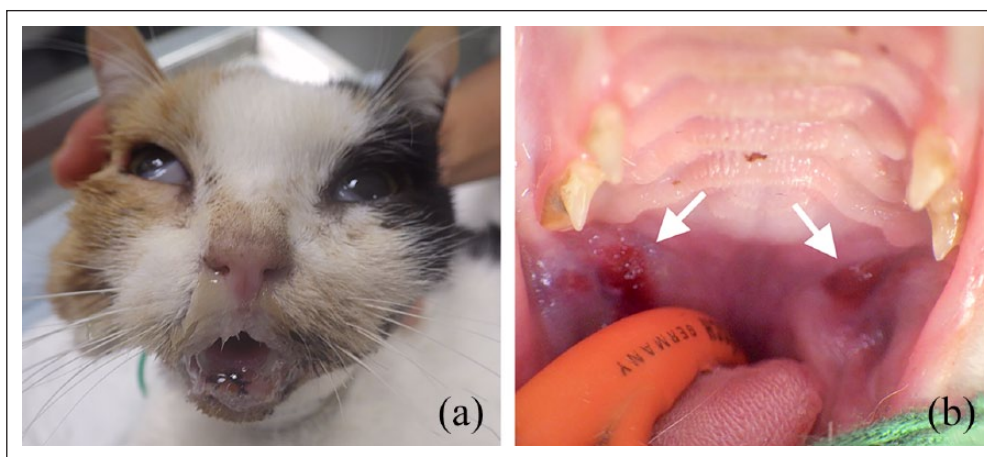
### Case description

An 8-year-old tortoiseshell spayed female domestic shorthair cat was referred for anorexia, weight loss and progressive trismus of at least 1 month duration. A history of chronic rhinitis since the age of 4 months was reported. A PCR test for calicivirus was negative. Previous

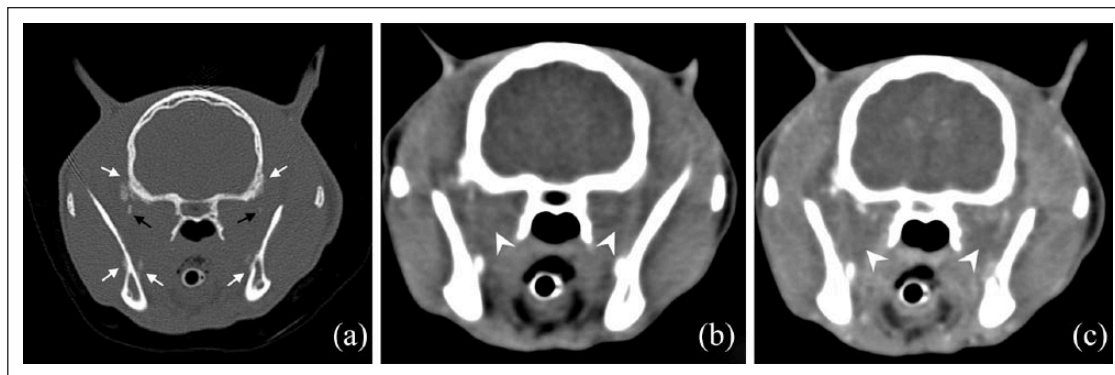
antibiotic therapies (doxycycline 10 mg/kg PO q24h for 10 days; benzylpenicillin procaine 7 mg/kg [dihydrostreptomycin 10 mg/kg long-acting formulation] IM; and clindamycin hydrochloride 11 mg/kg PO q24h for 10 days) did not result in any clinical improvement. The cat was exclusively fed veterinary dry food and no history of trauma was reported.

Upon presentation, the cat had generalised weakness, bilateral purulent nasal discharge, with concurrent reduced nasal airflow, right epiphora with chemosis and third eyelid protrusion, and concurrent mild bilateral mandibular lymph node enlargement. Body condition score was 3/9 (weight 2.9 kg [6.4 lb]). Neurological examination revealed decreased bilateral palpebral reflexes on the ophthalmic branch territories of the trigeminal nerves, and an absence of pupillary light reflexes. Vision testing revealed complete visual deficits, previously unnoticed by the owners, absent menace response in both eyes, and the patient bumping into objects. Spinal reflexes were normal and no gait abnormality was present. Oral examination showed painful mouth opening with a restricted vertical mandibular range of motion (vmROM), and an inability to close the mouth (Figure 1). The rest of the physical examination was within normal limits.

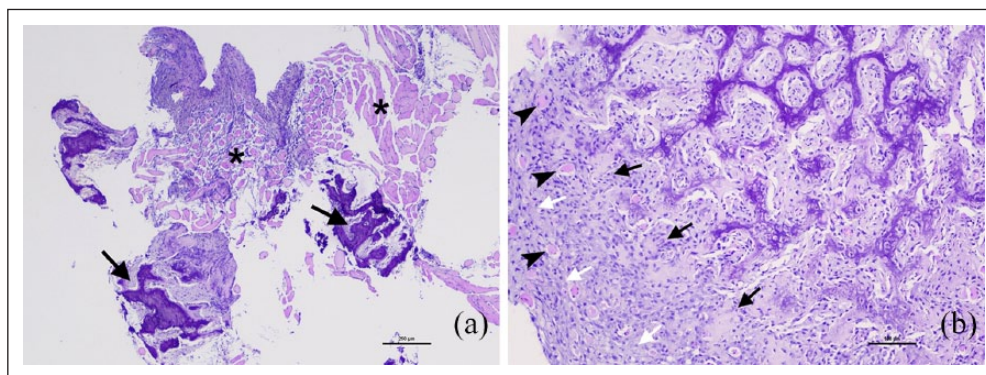
Serum biochemistry and electrolytes were unremarkable. Serological screening for infectious agents (*Toxoplasma* species, *Ehrlichia* species, *Cryptococcus* species, *Anaplasma* species) was negative. A complete blood count and blood smear examination revealed a mild microcytic non-regenerative normochromic anaemia with concurrent moderate neutrophilia and monocytosis. Antinuclear antibody testing was negative, and creatine kinase activity, activated partial thromboplastin time, activated clotting time, thrombin clotting times and D-dimers were within the normal limits. The restriction of vmROM



**Figure 1** (a) Image of an 8-year-old tortoiseshell spayed female domestic shorthair cat on initial presentation with open bite. (b) Rostral aspect of the oral cavity under general anaesthesia. Note the bilateral submucosal haematomas involving the retromolar areas (white arrows). The vertical mandibular range of motion (vmROM) was 22 mm



**Figure 2** CT of the head. Transverse reconstructions at the level of both rami. (a) Irregular periosteal new bone on both mandibulae and parietal bones (white arrows); dystrophic mineralisation in temporalis/pterygoid muscles (black arrows). (b,c) Bilateral, non-enhancing, ill-defined hypodense areas in temporalis and medial pterygoid muscles (white arrowheads)



**Figure 3** Photomicrograph of a section of the needle-core biopsy of the right temporalis muscle. (a) Extensive replacement of the muscle (asterisks) by a dense mesenchymal tissue exhibiting progressive ossification (arrows). Haematoxylin and eosin, bar = 250  $\mu$ m. (b) Proliferation of fibroblasts (white arrows) and osteoblasts (black arrow) gradually forming trabeculae of mineralised lamellar bone. Note residual atrophic muscle fibres embedded in the lesion (black arrowheads). Haematoxylin and eosin, bar = 100  $\mu$ m

persisted under general anaesthesia (22 mm). Intra-oral examination and dental charting revealed oropharyngeal swelling, with haematomas involving the retromolar areas, ulceration of the dorsal aspect of the tongue and mild generalised periodontitis.

In order to explore the cause of reduced mouth opening, CT of the head was performed. Selected reconstructed images are provided (Figure 2). CT images showed bilateral, asymmetrical, non-enhancing (49 Hounsfield units in the pre- and post-contrast images), ill-defined hypodense areas within the masticatory muscles, mostly the temporalis and masseter muscles. Irregular periosteal reaction was noted on the ramus of the mandible and on the parietal and temporal bones bilaterally. Some new bone foci extended into the temporalis and medial pterygoid muscles away from the bone surfaces, indicating an ectopic mineralisation disorder. CT findings suggested bilateral chronic masticatory myositis.

Six ultrasound-guided needle-core biopsies from the right and left masticatory muscles were collected and submitted to two different laboratories for comparative anatomopathological analysis. Biopsied material was submitted fresh and fixed in 10% neutral buffered formalin and decalcified as required. Fresh biopsies were isopentane pre-cooled in liquid nitrogen for cryohistology. Cryosections were stained with haematoxylin and eosin, Engel's modified Gömöri trichrome stain, oil red O and periodic acid-Schiff reaction. Fixed biopsies were embedded in paraffin, sectioned at 3–5  $\mu$ m thickness, mounted on glass slides and stained with haematoxylin and eosin before light microscopy evaluation. The samples showed extensive replacement of the myofibers with a dense vascularised mesenchymal tissue exhibiting progressive ossification. The mesenchymal tissue was composed of peripheral fascicles of activated fibroblasts and intermediate osteoblasts depositing woven bone and gradually forming trabeculae of lamellar bone (Figure 3).

Rare atypia and mitoses were present in the fibroblastic population. Residual muscle fibres embedded in the lesions were atrophic and degenerated. Some samples revealed striated muscle containing occasional inflammatory infiltrates. No infectious agent was observed within the samples. A FOP-like disease was considered the most likely diagnosis by both laboratories.

Supportive treatment during hospitalisation consisted of fluid therapy (3 ml/kg/h), nutrition through an oesophagostomy tube, antibiotic therapy (clindamycin hydrochloride 11 mg/kg PO q24h for 7 days, then doxycycline 10 mg/kg PO q24h), pain management (buprenorphine 20 µg/kg IV q6h), a muscle relaxant (dantrolene-sulfate 1 mg/kg PO q8h) and immunosuppressive doses of methylprednisolone (3.3 mg/kg PO q24h) in case of an immune-mediated process. The latter was subsequently replaced with robenacoxib (1 mg/kg PO q24h) 4 weeks after initial presentation.

Despite weight stabilisation, and improved willingness to move, allowing transient home care, the cat failed to recover the ability to eat spontaneously. A full-body CT scan was eventually performed 4 weeks after initial presentation and excluded additional areas of soft tissue calcification, pulmonary lesions and lymph node enlargement. Five weeks after initial presentation there had been a rapid decrease of vmROM leading to a total inability to open and close the mouth (13 mm open bite). A persistent bilateral purulent nasal discharge with almost total blockage of the nares led to the decision to perform a tracheostomy and nasal cavity lavage under general anaesthesia. During induction of anaesthesia, an emergency endotracheal intubation by tracheotomy, followed by cardiac resuscitation, had to be carried out. Because of the worsening prognosis, the owners elected humane euthanasia and rejected post-mortem investigations.

Two remaining samples of fresh biopsied material, kept at  $-80^{\circ}\text{C}$ , were ultimately sent in dry-ice medium to a specialised laboratory for molecular analysis. Genomic DNA was extracted from the muscle samples, using sodium dodecyl sulfate/proteinase K lysis followed by purification on silica columns. The primers were synthesised at a 25 nmol scale, desalted and designed on the reference sequence of Genbank NC\_018730, with the use of a software. After PCR amplification and product purification Sanger sequencing was performed for the whole nine coding exons of *Felis catus ACVR1* (total linear DNA length 222,790,142 bp), located on the C1 chromosome, and purified. DNA sequencing products were analysed on a 96 capillary DNA analyser. Two deletions were highlighted in the exon 8 and exon 9 PCR products, and were further amplified and sequenced. Both of them were characterised in intron 8, upstream of the last coding exon 9 of *ACVR1*. Four bases (TTGA) were deleted around  $-123$  bases of the exon 9 start (position 139,512 of the total gene sequence), and five bases (CCCAT) were

deleted around  $-225$  bases upstream of the exon 9 start (position 139,410 of the total gene sequence).

## Discussion

This is the first case report of FOP in a cat, which selectively involved the masticatory muscles with sparing of other muscle groups. A review of previous descriptions in this species are summarised in Table 1.

Compared with previously reported cases aged from 16 weeks to 6 years, this patient was older (8 years). Additionally, the clinical presentation of our cat was unusual as it included decreased vmROM, signs of rhinitis/pharyngitis, multiple cranial nerve deficits, and lacked locomotory and other neuromuscular abnormalities. Nerve deficits were reported in one other cat,<sup>12</sup> and chronic neurological presentations have been documented in 51% of people with FOP.<sup>17</sup> Progression of the lesions commonly follows a cranial-to-caudal and axial-to-appendicular direction in people, sparing the diaphragm, tongue, extra-ocular, smooth and cardiac muscles.<sup>2</sup> However, retrograde involvement, from hindlimbs to forelimbs, has been described in cats.<sup>8,10,11,14</sup>

Previous feline cases of FOP-like disease have shown a poor prognosis owing to rapid progression of the disease, generally leading to a decision of euthanasia a few weeks or months after initial presentation.<sup>8-16</sup> Cardiorespiratory failure, secondary to increased pulmonary vascular resistance, is the most common cause of death in human patients,<sup>18</sup> usually occurring during the second to fifth decades of life.<sup>12</sup> Involvement of the oromaxillofacial region is an additional concern, as it may compromise vital primary requirements, such as air and food intake.

Differential diagnosis for restricted mouth opening in dogs and cats includes temporomandibular joint disease (fracture/luxation, dysplasia, osteoarthritis, neoplasia), any painful condition related to the masticatory region (eg, retrobulbar abscess, severe middle-ear disease) and systemic diseases such as tetanus.<sup>19</sup> Masticatory myositis, a well-known autoimmune condition in dogs, was also recently described in a cat and is mainly characterised by its chronic presentation of bilateral symmetrical masticatory muscle atrophy.<sup>20</sup> Normal vmROM has been recently established in cats at a mean  $\pm$  SD of  $62 \pm 8$  mm (median 63 mm, range 41–84 mm);<sup>21</sup> our cat had a vmROM of 22 mm when first presented.

In humans, the most important imaging feature of FOP is the late ectopic ossification of soft tissue that is easily seen with CT.<sup>2,22,23</sup> Non-mineralised early-to-intermediate - stage FOP lesions are oedematous, markedly inflammatory and progressively fibroproliferative. With CT, such lesions may appear as swelling of the facial plane around muscles that is isodense to hypodense with a variable enhancement pattern, depending on the balance between inflammation and neovascularity.

**Table 1** Summary of the clinical features in 11 cats diagnosed with a fibrodysplasia ossificans progressiva-like condition

Reference	Breed	Age at presentation (years)	Sex	History	Clinical findings	Regions involved	Diagnostic modalities	Outcome
Klang et al <sup>16</sup>	DLH	1	FN	Altered gait, stiffness affecting all limbs, non-pruritic extensive alopecia	Restricted ROM (shoulder, elbow, hip, stifle joints); marked diffuse hardening of back and limb muscles	Skeletal muscles (paravertebral, upper forelimbs and hindlimbs), tongue, upper lip	Plain radiographs, CT scan, histology, necropsy	Euthanasia (4 months after presentation)
Crivellenti et al <sup>15</sup>	DSH	2.5	M	Progressive lameness, pain upon manipulation, ongoing inability to extend the hindlimbs	Pain upon manipulation, inability to extend hindlimbs	Skeletal muscles (hindlimbs)	Plain radiographs, histology	Euthanasia (timing not specified)
Berkowitz et al <sup>14</sup>	DSH	1.5	M	Stiffness since 4 months of age (unusually long third digit on both hindlimbs), muscle atrophy, inability to ambulate and groom itself	Decreased ROM on multiple joints, progression from hindlimbs to forelimbs	Skeletal muscles (forelimbs and hindlimbs)	Plain radiographs, CT scan, histology, necropsy, ACVR1 genetic testing	Euthanasia (timing not specified)
Yabuzoe et al <sup>13</sup>	Maine Coon	1.5	F	Extensive alopecia with concurrent dermatitis	Awkward gait without pain, popliteal lymphadenopathy, paravertebral induration	Skeletal muscles (paravertebral)	Plain radiographs, CT scan, histology, necropsy	Died 6 months after presentation (pulmonary oedema and congestion)
Asano et al <sup>12</sup>	Japanese Bobtail	1.25	MN	Hindlimbs stiffness, pain upon manipulation	Fever, muscle atrophy of the hindlimbs, loss of postural reactions and decreased neurological reflexes	Skeletal muscles (hindlimbs)	Plain radiographs, CT scan, histology	Alive at least 144 days after presentation
Valentine et al <sup>11</sup>	DLH	5	MN	Lethargy	Fever, periodontitis, popliteal lymphadenopathy, hindlimbs firm enlargement, decreased ROM (hip and stifle joints)	Skeletal muscles (forelimbs and hindlimbs)	Plain radiographs, histology, necropsy	Euthanasia (1 month after presentation)
Waldron et al <sup>10</sup>	American Shorthair	2	F	Pruritus with cervical alopecia, forelimb stiffness	Decreased ROM (shoulder joints), with progressive extension to pelvic musculature and muscles of both hindlimbs	Skeletal muscles (cervical, thoracic, forelimbs and hindlimbs)	Plain radiographs, histology necropsy	Euthanasia (1 month after presentation)
Warren and Carpenter <sup>9</sup>	DLH	1	M	Progressive altered gait, difficulty in rising	Pain upon manipulation, stiff and awkward limb movements, decreased ROM (forelimbs and hindlimbs)	Skeletal muscles (forelimbs and hindlimbs), groin	Plain radiographs, histology necropsy	Euthanasia (timing not specified)

(continued)

Table 1 (Continued)

Reference	Breed	Age at presentation (years)	Sex	History	Clinical findings	Regions involved	Diagnostic modalities	Outcome
Warren and Carpenter <sup>9</sup>	DLH	1	M	Progressive altered gait, difficulty in rising	Pain upon manipulation, stiff and awkward limb movements, decreased ROM (forelimbs and hindlimbs)	Skeletal muscles (forelimbs, hindlimbs, and thorax)	Plain radiographs, histology, necropsy	Euthanasia (timing not specified)
Warren and Carpenter <sup>9</sup>	DSH	0.5	FN	Progressive altered gait, difficulty in rising	Pain upon manipulation, stiff and awkward limb movements, decreased ROM (forelimbs and hindlimbs)	Skeletal muscles (paravertebral, forelimbs and hindlimbs), visceral pleura, groin	Plain radiographs, histology, necropsy	Euthanasia (timing not specified)
Norris et al <sup>8</sup>	DLH	0.8	FN	Stiffness, paresis, multiple nodules on forelimbs and hindlimbs, inability to jump and climb	Mild stiffness and weakness, decreased ROM with spasticity (forelimbs and hindlimbs), popliteal lymphadenopathy	Skeletal muscles (forelimbs, hindlimbs, abdomen, back)	Plain radiographs, histology, necropsy	Euthanasia (1 month after presentation)

DSH = domestic shorthair; DLH = domestic longhair; M = male; MN = male neutered; F = female; FN = female neutered; ROM = range of motion

In our case, the hypodense areas within the masticatory muscles most likely represented areas of oedema and inflammation. The lack of enhancement after intravenous injection of iodinated contrast medium may indicate the absence of significant neovascularisation.

In the previous cases of feline FOP-like disease, CT was helpful for the characterisation, localisation and histopathological sampling of the soft tissue calcifications.<sup>13,16</sup> The degree of soft tissue calcification in our case, as assessed with CT, was considered low when compared with previously published CT images of cats. Considering the location of the lesions and their relative low degree of calcification it is likely that these lesions would have been missed on plain radiographs. Heterotopic new bone formation in human FOP and feline FOP-like disease involves various connective tissues, such as the muscles, tendons, ligaments, aponeuroses, fasciae and joint capsules.<sup>1,2,16</sup> In people, MRI and (fluorodeoxyglucose)-positron emission tomography are more sensitive than CT in the early diagnosis of FOP and in recognising 'flare ups'.<sup>2,22,23</sup>

Mandibular periostitis ossificans is a condition that has been described in young people and dogs, characterised by periosteal new bone formation, without any intramuscular heterotopic lesions, and mostly related to mandibular maturation.<sup>24</sup> Lesions are mainly distributed along the caudal ventral border of the body of the mandible, and are suspected to be associated with dental disease in young patients.<sup>24</sup>

Periosteal bone proliferation in the present case follows the muscle attachments along the temporal and parietal bones and the ramus while sparing the caudal ventral border of the body of the mandible. Similar descriptions involving various locations, including the masticatory muscle attachments, are well described in humans with FOP.<sup>2,25</sup> Such lesions were not specifically reported in cats with FOP-like disease,<sup>8-16</sup> but most likely correspond to early manifestations of the extra-skeletal bridging ossification process in our case.

Low-grade extra-skeletal osteo-/chondrosarcoma share some histological features with FOP that may lead to a challenging histopathological differentiation of these two conditions.<sup>26</sup> In our case, a malignant bone tumour could have been considered based on ectopic bone formation within skeletal muscle, cellular atypia and proliferation. However, the bilateral distribution, low mitotic index and concentric organisation with very well-differentiated bone spicules led to us ruling out malignancy.

Periosteal new bone formation was described in human and canine myositis ossificans circumscripta.<sup>22-29</sup> The lack of consistent inflammatory features on biopsied material and the bilateral multifocal asymmetric distribution of lesions are not compatible with myositis ossificans circumscripta.<sup>22,27-29</sup>

The exclusive involvement of masticatory muscles might have suggested a specific inflammatory response against type 2M myofibres. This entity was ruled out owing to the absence of characteristic histological features. Although masticatory muscle myositis might be associated with dystrophic mineralisation in necrotic myofibres, it is not associated with heterotopic new bone formation among myofibres.<sup>20</sup> However, the 2M antibody test may be useful, as a possible non-invasive diagnostic test to differentiate masticatory muscle myositis from FOP-like disease.

The cause of the multiple cranial nerve deficits in our case remains undetermined. As previously described in human FOP, and cats with FOP-like disease, some of these deficits may have been due to the entrapment of vessels and nerves by the lesions, lymphedema, demyelisation or venous thromboembolism.<sup>2,9,16</sup> Additionally, prolonged trismus and muscle swelling may have impaired the blood supply of the maxillary arteries to the retinae and brain.<sup>30–32</sup>

In people, FOP lesions may arise after a regional inflammatory process such as a viral infection, fatigue, or muscle trauma and strain.<sup>1</sup> No history of trauma was reported in our case. The chronic rhinitis/pharyngitis may have been an inflammatory trigger leading to metaplastic changes within the masticatory muscles. Experimental evidence in mice and primates suggests there is an upregulation of BMP-1 receptors secondary to respiratory epithelium inflammation.<sup>33,34</sup> Through their chemotactic activity, BMPs are not only responsible for bone deposition,<sup>35</sup> but could also play a key role in the respiratory inflammatory process.<sup>33,34</sup> Upper airway respiratory disease in our patient may have triggered or been a consequence of BMP overexpression.

Mutation of *ACVR1/ALK2* has been shown to trigger BMP-1 receptor constitutive activation, resulting in osteoblast differentiation and bone formation in most human cases of FOP and in one cat with the disease.<sup>14,35</sup> However, a detailed genetic background, as well as the material and methods used for the genetic characterisation of the disease, have, to date, not been reported in cats. Using sequence alignment, a comparison between the well-documented *Homo sapiens* and *Felis catus* non-documented *ACVR1* showed that they were quite different in their exonic structure and sequence. Thus, it was not possible to use *H sapiens ACVR1* to design primers for *F catus ACVR1* gene analysis. Sequencing the whole *ACVR1* gene in our case permitted the characterisation of two deletions in intron 8, upstream of the last coding DNA sequence, constituting exon 9.

Probably the most interesting mutation corresponded to a four-base TTGA deletion, from a motif very similar to the 'branching site necessary for intron splicing' or 'splice-site mutation' that is (C/T)TNA(C/T) or YTNAY in humans.<sup>36</sup> The latter are located at the very termini of introns and drive exon recognition. Such genetic

mutations occur in the very specific site at which splicing takes place during the processing of a precursor mRNA into a mature mRNA. The deletion of the splicing site may result in remaining mature mRNAs that may lead to the production of abnormal proteins. Genotype variations from classic FOP have also been described in humans.<sup>37</sup>

Despite the fact that no direct link can be established between the mutation observed and FOP, it is possible that the splice site mutation of *ACVR1* observed in our case could be responsible for the disease. Full confirmation would require functional analysis of the variant or, failing that, bioinformatic predictive algorithms.<sup>36</sup> This condition was considered very likely in regard to the clinical presentation, and complementary results, similar to some oromaxillofacial descriptions of FOP in humans.<sup>3–7</sup>

## Conclusions

Although uncommon, heterotopic ossification-related diseases such as FOP should be included in the differential diagnosis of restricted-mouth-opening disorders in cats. Suspicion should be raised following clinical and diagnostic imaging findings. Any additional trauma, such as muscular biopsies or surgical procedures, should be minimised as they may activate bone deposition and worsen muscular lesions. Studies are needed in order to further characterise the genetic background of the disease, promote the development of a commercially available test and offer a non-invasive diagnostic tool.

**Acknowledgements** The authors are grateful to Dr Stella Papageorgiou (DMV, Dipl ECVN) for her support related to the neurological interpretation; Dr Farida Mebarki (DM, Biofidal laboratory, Vaulx-en-Velin, France) for the genetic analysis and interpretation; and to Dr Suzy Valentin (DMV, MS, Dipl ACVIM, Dipl ECVIM-CA) for editing the manuscript.

**Conflict of interest** The authors declared no potential conflicts of interest with respect to the research, authorship, and/or publication of this article.

**Funding** The authors received no financial support for the research, authorship, and/or publication of this article.

## References

- 1 Qi Z, Luan J, Zhou X, et al. **Fibrodysplasia ossificans progressiva: basic understanding and experimental models.** *Intractable Rare Dis Res* 2017; 6: 242–248.
- 2 Bauer AH, Bonham J, Gutierrez L, et al. **Fibrodysplasia ossificans progressiva: a current review of imaging findings.** *Skeletal Radiol* 2018; 47: 1043–1050.
- 3 Luchetti W, Cohen RB, Hahn GV, et al. **Severe restriction in jaw movement after routine injection of local anesthetic in patients who have fibrodysplasia ossificans progressiva.** *Oral Surg Oral Med Oral Pathol Oral Radiol Endod* 1996; 81: 21–25.

- 4 Herford AS and Boyne PJ. **Ankylosis of the jaw in a patient with fibrodysplasia ossificans progressiva.** *Oral Surg Oral Med Oral Pathol Oral Radiol Endod* 2003; 96: 680–684.
- 5 Kriegbaum RK and Hillerup S. **Fibrodysplasia ossificans progressiva (FOP): report of a case with extra-articular ankylosis of the mandible.** *J Craniomaxillofac Surg* 2013; 41: 856–860.
- 6 Rajanikanth BR, Prasad K, Vineeth K, et al. **Unresolving trismus following third molar surgery: report of a case of fibrodysplasia ossificans progressiva with review of literature.** *Cranio* 2018; 36: 341–349.
- 7 Okuno T, Suzuki H, Inoue A, et al. **Restricted mandibular movement attributed to ossification of mandibular depressors and medial pterygoid muscles in patients with fibrodysplasia ossificans progressiva: a report of 3 cases.** *J Oral Maxillofac Surg* 2017; 75: 1891–1898.
- 8 Norris AM, Pallett L and Wilcock B. **Generalised myositis ossificans in a cat.** *J Am Anim Hosp Assoc* 1980; 16: 659–663.
- 9 Warren HB and Carpenter JL. **Fibrodysplasia ossificans in three cats.** *Vet Pathol* 1982; 21: 495–499.
- 10 Waldron D, Pettigrew V, Turk M, et al. **Progressive ossifying myositis in a cat.** *J Am Vet Med Assoc* 1985; 187: 64–65.
- 11 Valentine B, George C, Randolph JF, et al. **Fibrodysplasia ossificans progressiva in the cat. A case report.** *J Vet Intern Med* 1992; 6: 335–340.
- 12 Asano K, Sakata A, Shibuya H, et al. **Fibrodysplasia ossificans progressiva-like condition in a cat.** *J Vet Med Sci* 2006; 68: 1003–1006.
- 13 Yabuzoe A, Yokoi S, Sekiguchi M, et al. **Fibrodysplasia ossificans progressiva in a Maine Coon cat with prominent ossification in dorsal muscle.** *J Vet Med Sci* 2009; 71: 1649–1652.
- 14 Berkowitz A, Engiles JB, Shore EM, et al. **Detailed analyses of feline fibrodysplasia ossificans progressiva [abstract].** *Vet Pathol* 2010; 47 Suppl: 52.
- 15 Crivelenti LZ, Borin S, Brum AM, et al. **Fibrodysplasia ossificans progressiva-like in a cat.** *Arq Bras Med Vet Zootec* 2012; 64: 359–362.
- 16 Klang A, Kneissl S, Glänzel R, et al. **Imaging diagnosis: fibrodysplasia ossificans progressiva in a cat.** *Vet Radiol Ultrasound* 2013; 54: 532–535.
- 17 Kitterman JA, Strober JB, Kan L, et al. **Neurological symptoms in individuals with fibrodysplasia ossificans progressiva.** *J Neurol* 2012; 259: 2636–2643.
- 18 Kaplan FS, Zasloff MA, Kitterman JA, et al. **Early mortality and cardiorespiratory failure in patients with fibrodysplasia ossificans progressiva.** *J Bone Joint Surg Am* 2010; 92: 686–691.
- 19 Gatineau M, El-Warrak AO, Marretta SM, et al. **Locked jaw syndrome in dogs and cats: 37 cases (1998–2005).** *J Vet Dent* 2008; 25: 16–22.
- 20 Blazejewski SW and Shelton GD. **Trismus, masticatory myositis and antibodies against type 2M fibers in a mixed breed cat.** *J Feline Med Surg Open Reports* 2018; 4: DOI: 10.1177/2055116917746786.
- 21 Gracis M and Zini E. **Vertical mandibular range of motion in anesthetized dogs and cats.** *Front Vet Sci* 2016; 3: 1–8.
- 22 McCarthy EF and Sundaram M. **Heterotopic ossification: a review.** *Skeletal Radiol* 2005; 34: 609–619.
- 23 Tyler P and Saifuddin A. **The imaging of myositis ossificans.** *Semin Musculoskelet Radiol* 2010; 14: 201–216.
- 24 Blazejewski SW, Lewis JR, Gracis M, et al. **Mandibular periostitis ossificans in immature large breed dogs: 5 cases (1999–2006).** *J Vet Dent* 2010; 27: 148–159.
- 25 Carter LC. **Soft tissue calcifications and ossifications.** In: White SC and Pharoah MJ (eds). *Oral radiology: principles and interpretation.* 7th ed. St Louis, MO: Mosby/Elsevier, 2014, pp 524–541.
- 26 Yoshida A, Ushiku T, Motoi T, et al. **Immunohistochemical analysis of MDM2 and CDK4 distinguishes low-grade osteosarcoma from benign mimics.** *Mod Pathol* 2010; 23: 1279–1288.
- 27 Lewis DD. **Fibrotic myopathy of the semitendinosus muscle in the cat.** *J Am Vet Med Assoc* 1988; 193: 240–241.
- 28 Tyler P and Saifuddin A. **The imaging of myositis ossificans.** *Semin Musculoskelet Radiol* 2010; 14: 201–216.
- 29 Tambella AM, Palumbo Piccionello A, Dini F, et al. **Myositis ossificans circumscripta of the triceps muscle in a Rottweiler dog.** *Vet Comp Orthop Traumatol* 2013; 26: 154–159.
- 30 Barton-Lamb AL, Martin-Flores M, Scrivani PV, et al. **Evaluation of maxillary arterial blood flow in anesthetized cats with the mouth closed and open.** *Vet J* 2013; 196: 325–331.
- 31 Martin-Flores M, Scrivani PV, Loew E, et al. **Maximal and submaximal mouth opening with mouth gags in cats: implications for maxillary artery blood flow.** *Vet J* 2014; 200: 60–64.
- 32 Scrivani PV, Martin-Flores M, van Hatten R, et al. **Structural and functional changes relevant to maxillary arterial flow observed during computed tomography and nonselective digital subtraction angiography in cats with the mouth closed and opened.** *Vet Radiol Ultrasound* 2014; 55: 263–271.
- 33 Rosendahl A, Pardali E, Speletas M, et al. **Activation of bone morphogenetic protein/Smad signaling in bronchial epithelial cells during airway inflammation.** *Am J Respir Cell Mol Biol* 2002; 27: 160–169.
- 34 Lynn TL, Molly AL, Masterson JC, et al. **SMAD signaling in the airways of healthy rhesus macaques versus rhesus macaques with asthma highlights a relationship between inflammation and bone morphogenetic proteins.** *Am J Respir Cell Mol Biol* 2016; 54: 562–573.
- 35 van Dinther MV, Visser N, de Gorter DJ, et al. **ALK2 R206H mutation linked to fibrodysplasia ossificans progressiva confers constitutive activity to the BMP type I receptor and sensitizes mesenchymal cells to BMP-induced osteoblast differentiation and bone formation.** *J Bone Miner Res* 2010; 25: 1208–1215.
- 36 Anna A and Monika G. **Splicing mutations in human genetic disorders: examples, detection, and confirmation.** *J Appl Genet* 2018; 59: 253–268.
- 37 Kaplan FS, Xu M, Seeman P, et al. **Classic and atypical FOP phenotypes are caused by mutations in the BMP type I receptor ACVR1.** *Hum Mutat* 2009; 30: 379–390.