

Magnetic Resonance Imaging of the Hips of Runners Before and After Their First Marathon Run

Effect of Training for and Completing a Marathon

Laura M. Horga,^{*†} PhD, Johann Henckel,[†] MD, Anastasia Fotiadou,[†] MD, PhD, Anna Di Laura,[†] PhD, Anna C. Hirschmann,[‡] MD, and Alister J. Hart,[†] MA, MD, FRCS(Orth)

Investigation performed at Institute of Orthopaedics and Musculoskeletal Science, University College London, Royal National Orthopaedic Hospital, Middlesex, UK

Background: No studies have focused on magnetic resonance imaging (MRI) of the hips of marathoners, despite the popularity and injury risks of marathon running.

Purpose: To understand the effect of preparing for and completing a marathon run (42 km) on runners' hip joints by comparing MRI findings before and after their first marathon.

Study Design: Case-control study; Level of evidence, 3.

Methods: A total of 28 healthy adults (14 males, 14 females; mean age, 32.4 years) were recruited after registering for their first marathon. They underwent 3-T MRI of both hips at 16 weeks before (time point 1) and 2 weeks after the marathon (time point 2). After the first MRI, 21 runners completed the standardized, 4 month-long training program and the marathon; 7 runners did not complete the training or the marathon. Specialist musculoskeletal radiologists reported and graded the hip joint structures using validated scoring systems. Participants completed the Hip disability and Osteoarthritis Outcome Score (HOOS) at both imaging time points.

Results: At time point 1, MRI abnormalities of the hip joint were seen in 90% of participants and were located in at least 1 of these areas: labrum (29%), articular cartilage (7%), subchondral bone marrow (14%), tendons (17%), ligaments (14%), and muscles (31% had moderate muscle atrophy). At time point 2, only 2 of the 42 hips showed new findings: a small area of mild bone marrow edema appearance (nonweightbearing area of the hip and not attributable to running). There was no significant difference in HOOS between the 2 time points. Only 1 participant did not finish the training because of hip symptoms and thus did not run the marathon; however, symptoms resolved before the MRI at time point 2. Six other participants discontinued their training because of non-hip related issues: a knee injury, skin disease, a family bereavement, Achilles tendon injury, illness unrelated to training, and a foot injury unrelated to training.

Conclusion: Runners who completed a 4-month beginner training program before their first marathon run, plus the race itself, showed no hip damage on 3-T MRI scans.

Keywords: long-distance running; hip joint; muscles; MRI

Long-distance running is very popular, with >30 million people annually participating in marathons across the globe and many of them being novice marathon runners.⁶ The repetitive loading during running is thought to place a high amount of stress on musculoskeletal joint structures, particularly on the articular cartilage and subchondral bone. The vertical forces exerted by running can reach up

to 8 times the body weight at the knee joint and 5 times the body weight at the hip joints.^{22,32} A high dose of running, as in a marathon (42 km), has anecdotally been associated with an increased risk of osteoarthritis, although evidence is inconclusive.^{13,16-18,21,26-29,31} On the contrary, a large recent survey-based study demonstrated that the prevalence of arthritis in active marathoners was less than that in the general nonrunning population.²⁵

Magnetic resonance imaging (MRI) is the most effective noninvasive tool to assess structural and functional joint changes. Previous studies have used MRI to focus on the

The Orthopaedic Journal of Sports Medicine, 9(7), 23259671211010405
DOI: 10.1177/23259671211010405
© The Author(s) 2021

This open-access article is published and distributed under the Creative Commons Attribution - NonCommercial - No Derivatives License (<https://creativecommons.org/licenses/by-nc-nd/4.0/>), which permits the noncommercial use, distribution, and reproduction of the article in any medium, provided the original author and source are credited. You may not alter, transform, or build upon this article without the permission of the Author(s). For article reuse guidelines, please visit SAGE's website at <http://www.sagepub.com/journals-permissions>.

effect of marathon running on knee joints and found that the high-impact forces are actually well tolerated in runners with no preexisting injuries because no significant pathological alterations were reported after the run.^{13-15,20,29,30} However, limited research has been done on hips. Only 1 previous study used MRI of the hip joints 24 to 48 hours before and after a marathon, and it found no running-related abnormalities.¹³ However, the limitations of this study include small sample size (8 participants), only experienced long-distance runners achieving 60 to 150 km/wk, and unilateral hip and low-resolution MRI. To better understand running-related changes, high-resolution 3-T MRI needs to be employed for greater diagnostic accuracy and effective detection of early signs of lesions.^{1,9}

The objective of this study was to better understand the effects of a 4-month beginner training program for a marathon run, plus the race itself, on the hip joints and muscles of 28 first-time marathon runners using high-resolution 3-T MRI before and after marathon running. This will help to inform whether a marathon run and its preceding training may harm runners' hips and how to prevent or minimize the risk of sustaining running-related injuries. The hypothesis was that beginner long-distance runners would show no pathological findings on their MRI scans after their first marathon run and therefore marathon running would not be detrimental to their hips.

METHODS

Participants

This was a prospective, longitudinal cohort study with participants of the Richmond Marathon 2019. The study was approved by our ethics committee, and all volunteers gave written informed consent before participation. The main inclusion criteria were as follows: no previous marathon runs, no present or previous history of hip injury or surgery, asymptomatic hip joints, and no contraindications to MRI. Exclusion criteria included pregnancy, active breastfeeding, age <18 years, claustrophobia, history of anxiety, panic attacks, or known hip problems.

We recruited 28 volunteers who had registered to run their first marathon, the Richmond Marathon 2019 (14 male, 14 female; mean age, 32.4 years; age range, 18-58 years). All participants had similar running experience before joining the study: they previously had participated in at least one 10-km race (5 people had run a maximum 10-km distance, the majority [23/28] had run a maximum 21-km distance [half-marathon], and there were no other

TABLE 1
Baseline Characteristics of Study Participants (N = 28)^a

Variable	Value
Age, y	32.4 ± 8.6
Sex, male:female	14:14
Weight, kg	70.4 ± 9.6
Height, cm	174 ± 10.2
BMI	23.2 ± 2.3

^aValues are reported as mean ± SD or No. BMI, body mass index.

values between these) and were running recreationally at least 2 times per week (mean, 3.4 ± 0.8 times per week; range, 2-5 times per week) for a total of 3 to 4 h per week of running (all sessions per week), with distances varying between 10 and 21 km per week (16.5 ± 2.6 km per week). All undertook a standardized marathon training program supplied by the race organizers. Participant characteristics are summarized in Table 1.

All participants underwent bilateral hip MRI before starting their formal training (time point 1), a standardized 4-month beginner training program for the marathon (with gradual increase in mileage per week, available online on the Richmond Runfest Marathon website). Two weeks after the marathon, the participants were recalled for a bilateral hip MRI (time point 2).

Participant Self-Assessment Questionnaire

The Hip disability and Osteoarthritis Outcome Score (HOOS) was used as a self-reported questionnaire of the hip condition and associated injuries that can result in osteoarthritis.²³ The HOOS questionnaire was completed by participants at both time point 1 and time point 2. The assessment is divided into 5 categories: pain, other symptoms, function in daily living, hip-related quality of life, and function in sport and recreation. Participants were asked to complete the questionnaire to assess their perceived hip joint health. Each question has 5 potential answers and is marked from 0 to 4. The sum of the scores from each category was converted into a scale ranging from 0 to 100, with 0 indicating extreme hip problems and 100 indicating no hip problems.

All training nonfinishers (those who stopped during training and did not run on the marathon day) were asked details about their reasons for training discontinuation and completed HOOS questionnaires at time point 2.

*Address correspondence to Laura M. Horga, PhD, Institute of Orthopaedics and Musculoskeletal Science, University College London, Royal National Orthopaedic Hospital, Brockley Hill, Stanmore, London HA7 4LP, UK (email: laura.horga.17@ucl.ac.uk) (Twitter: @HorgaLaura; @Running4Science).

[†]Institute of Orthopaedics and Musculoskeletal Science, University College London and the Royal National Orthopaedic Hospital, Stanmore, London, UK

[‡]Department of Radiology and Nuclear Medicine, University Hospital Basel, Basel, Switzerland

Final revision submitted December 18, 2020; accepted February 9, 2021.

The authors declared that there are no conflicts of interest in the authorship and publication of this contribution. This research study was funded by patient donations and supported by researchers at the National Institute for Health Research University College London Hospitals Biomedical Research Centre. Support was also received from The London Clinic, The Maurice Hatter Foundation, The RNOH Charity, The Rosetrees Trust, and The Stonegate Trust. AOSSM checks author disclosures against the Open Payments Database (OPD). AOSSM has not conducted an independent investigation on the OPD and disclaims any liability or responsibility relating thereto.

Ethical approval for this study was obtained from the University College London Research Ethics Committee (ref 13823/001).

All participants were also contacted via email 6 months later to verify if they had any hip problems over this period.

MRI Protocol

The participants underwent bilateral hip 3-T MRI (Magnetom VidaHealthineers; Siemens), using a dedicated 18-channel ultraflex coil, 16 weeks before and 2 weeks after the marathon. The imaging protocol included proton density-weighted fat-suppressed turbo spin-echo (PD FS TSE) sequences in the coronal (repetition time/echo time [TR/TE], 4190/44 milliseconds; image size/acquisition matrix, 512 × 512 pixels) and sagittal bilateral planes (TR/TE, 4420/35 milliseconds; image size/acquisition matrix, 320 × 320 pixels); axial T1 TSE (TR/TE, 27/10 milliseconds); coronal PD TSE (TR/TE, 3290/39 milliseconds); axial PD FS TSE (TR/TE, 4400/36 milliseconds; image size/acquisition matrix, 384 × 384 pixels); axial Dixon (4 phases: in-phase, out-of-phase, water only, fat only) (TR/TE, 4220/45 milliseconds); and T1 volumetric interpolated breath-hold examination 3-dimensional coronal (TR/TE, 0.1/4.92 milliseconds). All slices were 3 mm thick. The total acquisition time per bilateral scan was 30 minutes.

Imaging Analysis

All MRI scans were reviewed and reported using a picture archiving and communications system workstation by a senior musculoskeletal radiologist (A.F.) with 10 years of experience at the consultant level. To assess the reproducibility of the readings, the MRI scans of a subset of 20% of the cohort were randomly selected for an additional independent evaluation by a second senior musculoskeletal radiologist (A.C.H.) with 9 years of experience at the consultant level. Previous imaging studies have used a subset of 10% of the total number of participants for double reporting⁵; to increase reliability, we doubled this to a subset of 20%. In cases of disagreement between the radiologists' reports, the final score was achieved via consensus reading in a second MRI reporting session.

MRI findings of the hip joint were analyzed using validated scoring systems for the presence of any signal changes or lesions of varying severity for the following structures: labrum, articular cartilage, bone marrow, tendons, ligaments, and muscles (Table 2).^{2,11,12,19} Other findings were also specified, including trochanteric bursitis and hip joint effusion. The labrum was divided in 4 subregions: anterior, posterior, anterosuperior, and superior. The articular cartilage and bone marrow were each assessed in both the acetabular region (4 subregions: anterior, posterior, superolateral, and superomedial) and the femoral region (6 subregions: anterior, posterior, lateral, superolateral, superomedial, and inferior).

Statistical Analysis

Normal distribution was assessed using the following statistical tests: Shapiro-Wilk, D'Agostino-Pearson, and Kolmogorov-Smirnov. Characteristics of marathon finishers and training nonfinishers were compared.

TABLE 2
Grading Systems Used for All Assessed Internal Hip Features^a

Hip Feature and Grading System	
Labrum (SHOMRI ¹⁹)	Tendons (Chi et al ²)
0: Normal variant such as aplasia or hypoplasia	0: Normal
1: Abnormal signal and/or fraying	1: Tendinosis (intermediate signal, not fluid)
2: Simple tear	2: Low-grade partial-thickness tear (<50% tendon fluid signal)
3: Labrocarrilage separation	3: High-grade partial-thickness tear (≥50% tendon fluid signal)
4: Complex tear	4: Full-thickness tear (complete fluid signal)
5: Maceration	
Articular cartilage (SHOMRI ¹⁹)	Ligaments (SHOMRI ¹⁹)
0: No loss	0: Normal
1: Partial thickness loss	1: Signal abnormalities or fraying
2: Full-thickness loss	2: Partial tear
Bone marrow (SHOMRI ¹⁹)	3: Complete tear
Edema	Muscles (Fuchs et al ¹¹ and Goutallier et al ¹²)
0: No lesion	0: Normal muscle (no fat)
1: ≤0.5 cm	1: Some fatty streaks (for minimal atrophy)
2: >0.5 and ≤1.5 cm	2: <50% fatty muscle atrophy (for mild atrophy: fat infiltration less than muscle)
3: >1.5 cm	3: 50% fatty muscle atrophy (for moderate atrophy: fat infiltration equal to muscle)
Cysts	4: >50% fatty muscle atrophy (for marked atrophy: fat infiltration greater than muscle)
0: No lesion	Other findings (binary; eg, present/absent)
1: ≤0.5 cm	
2: >0.5 cm	

^aSHOMRI, Scoring Hip Osteoarthritis with MRI.

Statistical tests were performed for age, height, body mass index (BMI), prestudy running experience (unpaired *t* test), and sex (χ^2 test). The paired *t* test was used to analyze changes in BMI values between time point 1 and time point 2 in each group of participants, respectively. The Wilcoxon signed-rank test was used for time point 1 and time point 2 scores/grades for each hip structure as well as HOOS results for each questionnaire item. Hips of the same participant were treated independently in the statistical analysis. The unpaired *t* test was used to assess significant differences between the prestudy running experience of participants presenting with MRI abnormalities and the running experience of those without MRI abnormalities.

Differences between the marathon finishing times of participants who ran up to 10-km race distances before the study and those with half-marathon running experience were compared for significance using the unpaired *t* test. In addition, the marathon finishing times of participants

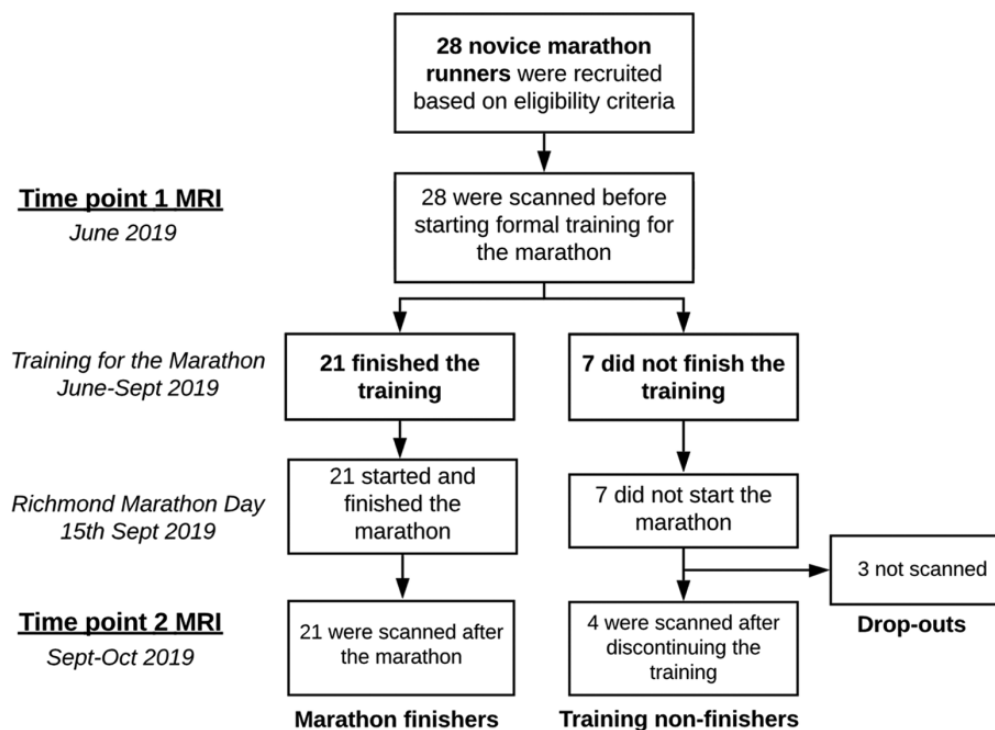


Figure 1. Flowchart of study design. MRI, magnetic resonance imaging.

who had a specific type of premarathon abnormality were compared with the marathon finishing times of participants who did not have that same abnormality using the unpaired *t* test. Interrater agreement for the subset of MRI scans reviewed by 2 authors (A.F. and A.C.H.) was evaluated using κ statistics. Statistical significance was defined as $P < .05$ (Prism Version 6.0 c; GraphPad).

Analysis of MRI findings was performed for all hips of study participants to provide an overall picture of the effect of marathon running on hips. Further details are available as Supplemental Material.

RESULTS

The status of the hips of all 28 participants was known at the end of the study. Some participants did not complete the training or the marathon, so we present a comparison of these groups. There was excellent interrater agreement between the scores reported by the 2 musculoskeletal radiologists for each hip structure on MRI scans ($\kappa = 1.000$). Abnormalities on MRI scans at time point 1 were found in 25/28 (90%) participants, and there were only 2 new abnormalities on the MRI scans at time point 2, which were not associated with symptoms or reduced hip function at time point 2 and 6-month follow-up. Only 1 participant did not finish the training (and therefore did not undertake the marathon) because of hip symptoms; this participant had no abnormality on MRI scans at time point 2, and the symptoms rapidly resolved. The differences in pretraining running experience among participants did not affect MRI findings or running performance.

Participant Completion of the Study

Of 28 participants, 21 participants finished both the training for the marathon and the marathon itself (marathon finishers), while 7 participants were considered training non-finishers. After the marathon, all marathon finishers and 4 of 7 training nonfinishers returned for their second MRI, thus completing the study. The 3 other training nonfinishers were not able to attend because of personal issues or availability, so these did not complete the study (see Figure 1 for study design).

The 4 training nonfinishers who completed the study discontinued their training for the following reasons: (1) minor hip injury, (2) Achilles tendon injury, (3) illness unrelated to training, and (4) foot injury unrelated to training. The remaining 3 participants who did not complete the study stopped their training because of the following: (1) knee injury, (2) skin disease unrelated to training, and (3) family bereavement (see Supplemental Tables S1 and S2 for further details, available online).

MRI Findings at Time Point 1

Abnormalities on MRI scans at time point 1 were found in 90% of the total cohort. For most participants, these were seen in both hips (71%) and were found in the labrum, articular cartilage, bone marrow, tendons, ligaments, and muscles in the study cohort (Figure 2). The differences in prestudy running experience among participants were not significant between those participants with MRI abnormalities and those without abnormalities ($P = .569$).

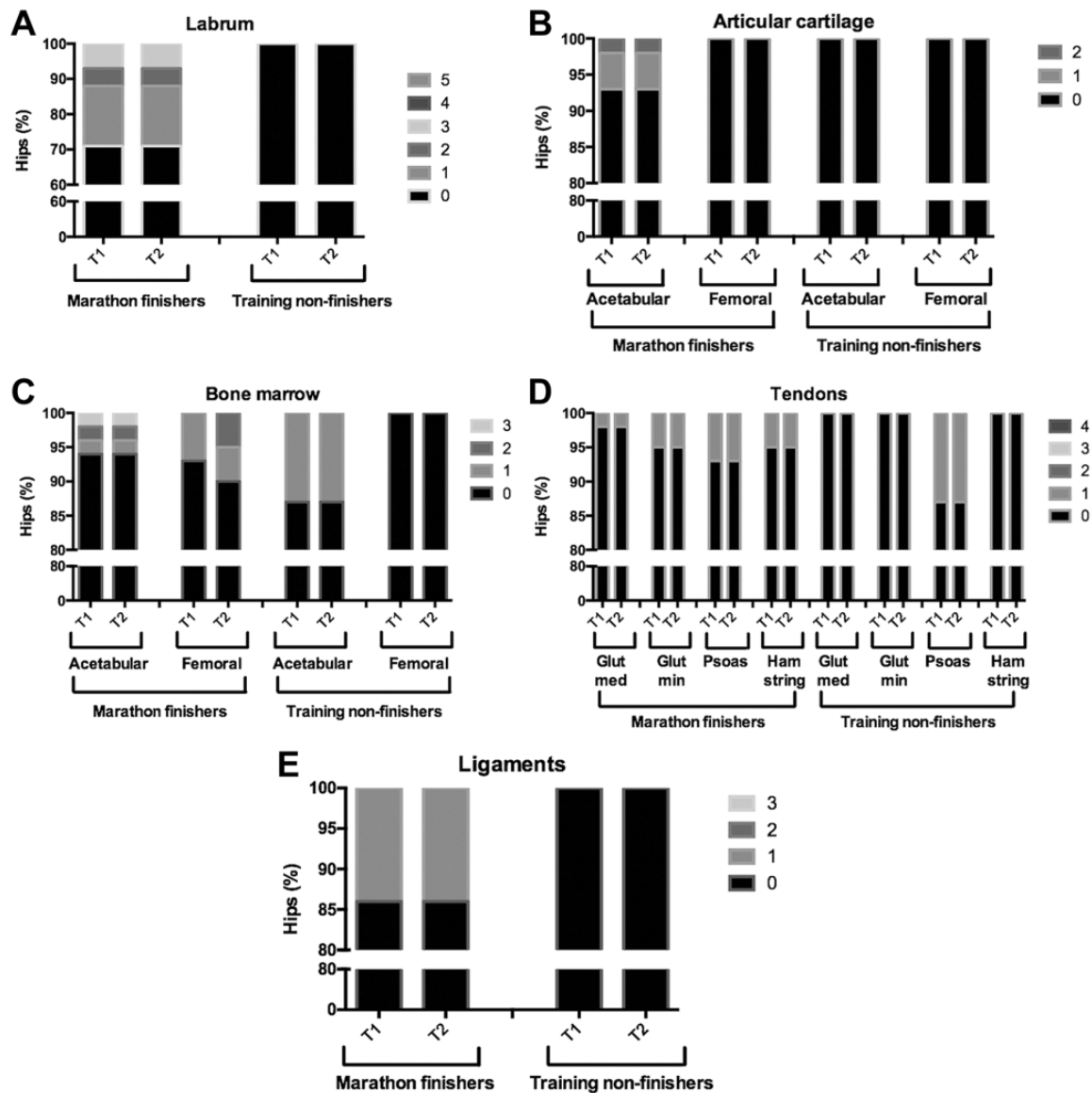


Figure 2. 3-T Magnetic resonance imaging findings in the key hip joint structures including (A) labrum, (B) articular cartilage, (C) bone marrow, (D) tendons, and (E) ligaments at time point 1 (T1) and time point 2 (T2) in the hips of both marathon finishers and training nonfinishers. Glut, gluteus; med, medius; min, minimus.

In the case of marathon finishers, time point 1 scans revealed labral abnormalities in 12 hips (29%). Out of these 12 hips, 7 had grade 1 (abnormal signal), 2 had grade 2 (simple tear), and 3 had grade 3 abnormalities (labrocartilage separation) (Figures 2 and 3C). Four hips (10%) had paralabral cysts. Cartilage abnormalities were identified in 3 hips (7%) in the acetabular region: 2 with grade 1 (partial-thickness defect) and 1 with grade 2 (full-thickness cartilage loss) (Figure 3A). Bone marrow edema was present in 6 hips (14%) in either the acetabular or femoral region: 4 had grade 1 (≤ 0.5 cm) (Figure 4C), 1 had grade 2 (>0.5 cm but ≤ 1.5 cm), and 1 had grade 3 (>1.5 cm). Grade 1 tendon abnormalities (tendinosis) were found in 7 hips (17%). Grade 1 ligament abnormalities (abnormal ligament signal) were

found in 6 hips (14%). The tendons showing abnormal signal were the gluteus, psoas, and hamstring (Figure 5, A and C). Moderate muscle atrophy was present in 13 hips (31%), specifically in the gluteal muscles (Figure 6A), tensor fascia latae muscles, or both. Joint effusion was found in 2 hips (5%). Trochanteric bursitis was present in 3 hips (7%), and psoas bursitis was present in 2 hips (5%).

Regarding training nonfinishers, time point 1 results showed 1 hip (13%) with subchondral bone marrow edema of up to 0.5 cm in size and 2 hips (25%) with subchondral cysts. Psoas tendinosis was found in 1 hip (13%), and moderate atrophy was found in 4 hips (50%) in the gluteal muscles, tensor fascia latae muscles, or both. Trochanteric bursitis was present in 3 hips (38%).

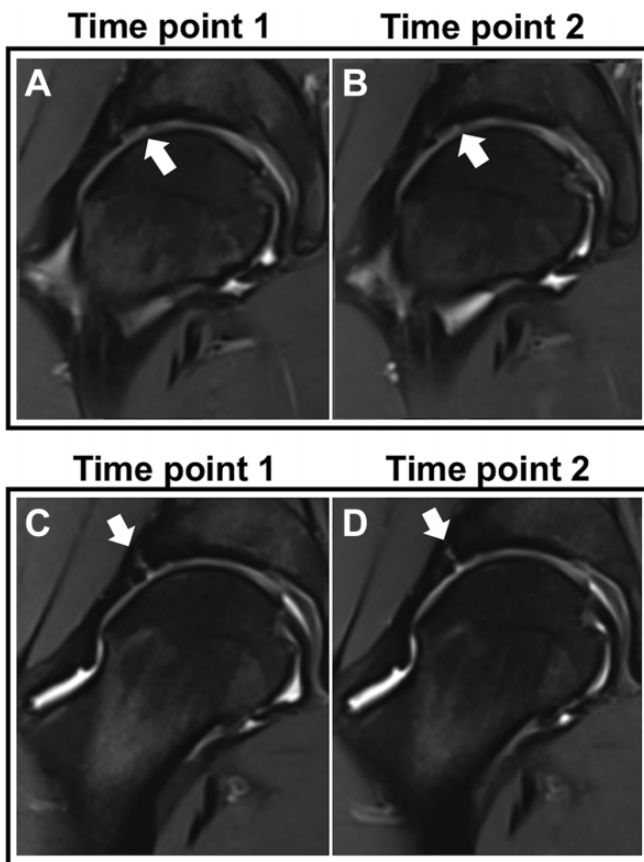


Figure 3. Coronal Dixon magnetic resonance imaging scans of 2 participants showing damage at time point 1 and no worsening at time point 2. (A, B) Participant 1 had a full-thickness acetabular cartilage defect (arrows). (C, D) Participant 2 had a labrocartilage separation (arrows).

Marathon Finishing Times

The mean \pm standard deviation marathon finishing time was 4 hours 23 minutes \pm 42 minutes. Variation between individual prestudy running experience among participants did not affect either marathon finishing times ($P = .686$) or other postmarathon results. HOOS was similar for both time points and for individual sections: other symptoms ($P = .780$), pain ($P = .445$), function in daily living ($P = .227$), function in sport and recreation ($P = .992$), and hip-related quality of life ($P = .565$).

The presence of labral tears or labrocartilage separation on the time point 1 MRI scan did not affect marathon finishing times when compared with no labral lesion ($P = .310$) (Figure 7). The presence of other time point 1 MRI abnormalities also did not affect finishing times, specifically for cartilage abnormalities ($P = .214$), bone marrow edema ($P = .975$), abnormal ligament signal ($P = .433$), tendinosis ($P = .802$), effusion/bursitis ($P = .378$), and moderate muscle atrophy ($P = .992$). The differences in pretraining running experience among participants did not affect marathon finishing times ($P = .872$).

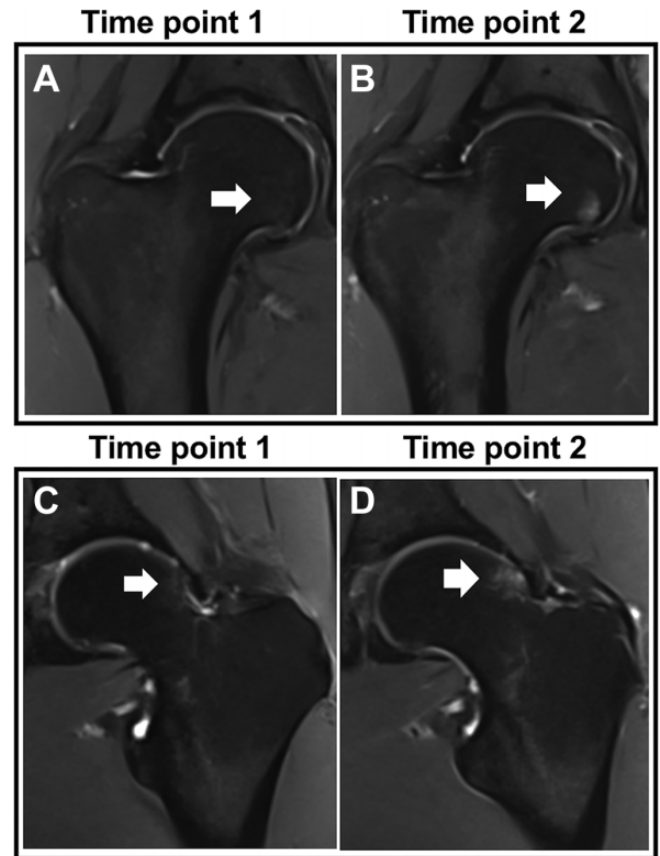


Figure 4. Coronal Dixon magnetic resonance imaging scans of 2 participants showing all subchondral bone marrow edema changes after the marathon. (A, B) Participant 1 had no edema before the marathon (A; arrow) and mild edema appeared after the marathon (B; grade 2, 0.5-1.5 cm; arrows). (C, D) Participant 2 had little edema before the marathon (C; grade 1, ≤ 0.5 cm; arrow), but the edema slightly extended after the marathon (D; grade 2, >0.5 - ≤ 1.5 cm; arrows). In both cases, edema changes were seen in the nonweightbearing area and likely due to impingement and not running.

Comparison of MRI From Time Points 1 and 2 in Marathon Finishers

There were very few changes in the MRI scans from time point 2 when compared with time point 1 (Figures 2–6). There were 2 cases with a small area of bone marrow edema appearance in the femoral heads: 1 progressed from a grade of 0 to 2, and the other progressed from a grade of 1 to 2 (Figure 4). Both of these abnormalities were in the nonweightbearing area of the hip joint and were not associated with symptoms or a change in HOOS (may have been due to impingement and not running). In the first case, the participant had a concomitant partial-thickness cartilage defect (which was present on the time point 1 MRI scan and did not progress on the time point 2 MRI scan) in the same hip on the acetabular side. In the second case, the

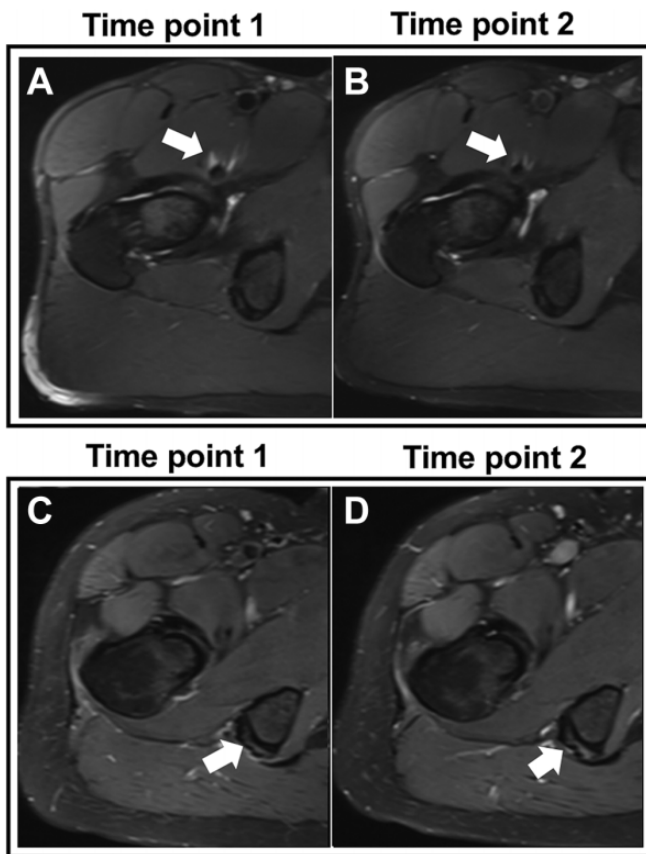


Figure 5. Axial Dixon magnetic resonance imaging scans of 2 participants showing tendinosis at time point 1 and no worsening at time point 2. (A, B) Participant 1 had psoas tendinosis (arrows). (C, D) Participant 2 had hamstring tendinosis (arrows).

participant had an enlarged preexisting psoas bursa in the same hip, which slightly decreased in size at time point 2. Another participant with a small premarathon psoas bursa showed a slight increase in size after the marathon.

There was no significant difference between the running experience of these few participants with minor postmarathon abnormalities and the running experience of the rest of participants with no pre- to postmarathon changes ($P = .333$). All 3 participants were contacted 6 months later and asked about their perceived hip condition: no hip problems were reported, and they continued training for other running events.

Comparison Between Marathon Finishers and Training Nonfinishers

There was no significant difference between marathon finishers and training nonfinishers in terms of baseline characteristics: age ($P = .413$), sex ($P = .238$), BMI ($P = .255$), and prestudy running experience ($P = .157$). There was no significant change in BMI between the 2 time points for both marathon finishers ($P = .641$) and training nonfinishers ($P = .391$).

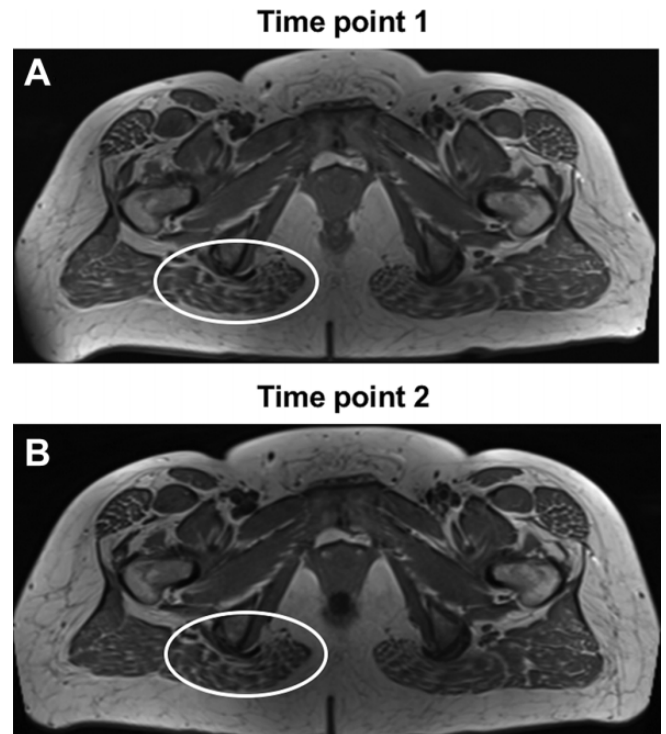


Figure 6. Axial Dixon magnetic resonance imaging scans of 1 participant showing (A) moderate atrophy of the gluteus maximus muscle (circles) at time point 1 and (B) no worsening at time point 2.

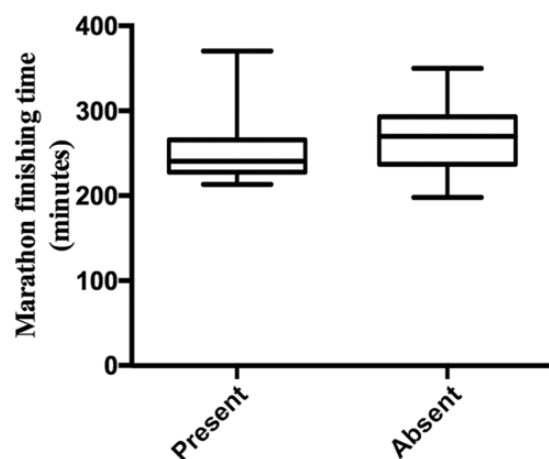


Figure 7. Marathon finishing times of participants, divided into 2 groups, based on presence or absence of labral tears or labrocartilage separation on time point 1 magnetic resonance imaging scans; 21 participants entered and finished the marathon, with labral abnormalities ($n = 8$) or normal labrum ($n = 13$).

MRI findings in training nonfinishers were similar to those of the marathon finishers in terms of level of damage at time point 1 and comparison between the 2 time points (Figure 2).

Only 1 participant did not finish the training because of right hip pain. A small area of acetabular bone marrow edema was the only abnormality seen on the time point 1 MRI scan of the contralateral (left) hip. No changes were seen on the time point 2 MRI scan. The right hip was normal on MRI scans at both time points, and there was no difference in HOOS between the 2 time points because the pain had already resolved by time point 2. This participant had torn a ligament in the right ankle 6 years previously and had recovered after having done strengthening work with a physical therapist; this previous injury may have indirectly affected the right hip. All other training nonfinishers completed the HOOS questionnaire at time point 2 and confirmed that the reason for stopping their training was not related to their hip condition (see details in Supplemental Table S1, available online). Six months after time point 2, they also reported no hip problems.

Study Noncompletion

Regarding training nonfinishers who did not complete the study and only attended time point 1 scans (3 participants), no MRI abnormalities were identified. All participants completed the HOOS questionnaire after not completing the study and confirmed that the reason for stopping their training was not related to their hip condition (see details in Supplemental Table S2, available online). Six months later, no hip problems were reported.

DISCUSSION

Preexisting abnormalities were common (90%) in asymptomatic runners on 3-T MRI scans before starting their training for their first marathon. No hip damage was reported on the MRI scans of the participants after completing a 4-month beginner training program and the marathon itself. In addition, those preexisting abnormalities did not disadvantage a runner when compared with someone without damage in terms of running performance.

At time point 2, 2 of 42 hips (21 runners) had MRI findings of bone edema in a small area of the nonweightbearing area of the hip that may have been attributable to impingement rather than running and were asymptomatic. All runners who completed the standardized training started and finished the marathon. The number of training nonfinishers in our study was 25%, which was lower than the expected 30% to 50%.^{3,4,10} Importantly, only 1 participant stopped training because of hip problems, and these problems had resolved, as confirmed in the self-reported questionnaire completed at time point 2 as well as 6 months after the marathon.

To our knowledge, this is the only study that has used high-resolution 3-T MRI to assess the effect of marathon running on hips in a large cohort of novice marathon runners. Given the increasing participation in marathons and ultramarathons among recreational runners, the controversially associated risks of injury, and the paucity of scientific evidence on this topic, we believe that this research is an important step in understanding the effect of high

doses of running on the hip joints. There are several strengths of our study design and ability to carry out the study. First, we recruited novice marathon runners who undertook a standardized, 4-month training program to minimize the effect of previous running experience. Second, we optimized MRI using high-resolution (3-T) scanning of both hips and scored by 2 musculoskeletal radiologists, with strong agreement, using validated scoring systems. Third, by the end of the study we knew the status of the hips of all 28 participants. As expected, but to a lesser level than that predicted based on other marathons, some participants did not complete the training and the marathon, so we presented a comparison of this group with those who finished the marathon.

We acknowledge some limitations. First, radiological assessment of the hip scans may involve a certain level of bias. In order to reduce bias, 2 radiologists reported the study results—that is, 1 radiologist reported all scans, a subset of them was co-reported by a second radiologist, and perfect interrater agreement was found. Second, 3 training nonfinishers could not attend the second MRI scan after discontinuing the marathon training because of reasons of availability, so we could not compare between the pre- and posttraining MRI findings. However, only 1 participant had knee pain during training, while the other 2 did not stop running because of training-related reasons. Third, only morphologic 3-T MRI assessments were conducted, and no biochemical analyses were included in this study. Considering that the cartilage is a complex structure to study, further compositional analysis studies using specific quantitative MRI sequences may be required to properly understand the effect of marathon running on the cartilage. Nevertheless, this study was not specifically focused on cartilage analysis but evaluated all internal structures of the hip joint. Fourth, a longer-term follow-up study is needed to assess whether the 2 bone marrow edema changes reverse over time. Fifth, immediate premarathon MRI scans (ie, posttraining) were not conducted. This could have provided useful information on the effect of training alone on the hip joints; however, the aim of our study was to assess the effect of a marathon run (including the preparation for it, altogether) on the hip joints of runners.

Existing literature on the effect of marathon running on hip joints using MRI is very limited. Previously, only 1 research group¹³ conducted such a hip MRI study with 8 marathon runners, specifically 6 recreational and 2 semi-professional runners. Unilateral hip MRI scans were collected 24 to 48 hours before and after running a marathon, and they did not reveal any pre- or postmarathon bone marrow edema, cartilage lesions, or other abnormalities. On the contrary, in our study, we found a number of asymptomatic hips with premarathon joint abnormalities of the labrum (29%), articular cartilage (7%), bone marrow (14%), tendons (17%), and ligaments (14%). However, our study included a larger sample size; first-time marathon runners instead of experienced long-distance runners with running distances of 60 to 150 km per week as in the previous study; and high-resolution MRI instead of low-resolution MRI, which may detect even subtle early signs of lesions. In addition, bilateral MRI scans instead of unilateral ones were

collected. Regarding the postmarathon scans, similar to the other study, the MRI scans did not demonstrate any significant changes after the run. All other marathon studies to date have focused on the effect of running on knees instead of hips, showing no permanent major changes after the marathon.^{13,16,20,29,30}

Our results suggest that marathon running does not induce any acute changes between the pre- and postmarathon hip MRI scans of first-time marathon runners with no previous hip problems or known injuries. We showed that running a single marathon is not associated with damage seen on MRI scans. This is of great importance given the rising concerns relating running with hip injuries and arthritis.^{21,28,31}

Our study supports the current evidence showing lack of hip arthritis in marathon runners, although we acknowledge that the absence of evidence is not evidence of absence. Some studies actually have shown an improved knee joint condition after marathon running.^{14,15} In fact, other studies have shown that an increased number of marathons may be associated with decreased joint pain.²⁵ This may be because of muscle strengthening during training, which can potentially reduce the load effect on the joints and thus decrease the risk of injury; also, the joints themselves may gradually develop adaptation mechanisms over time, i.e. joints of runners may be able to adapt to tolerate the high-impact forces exerted during running, as a result of training on a regular basis.^{14,15} In addition, a number of confounding factors need to be considered, for example running style, running surface, running shoes, health status of other joints, individual unreported changes to the standardized marathon training plan, leg alignment, and biomechanics, which may play major roles in decreasing the stress on the cartilage and subchondral bone. Adaptation mechanisms may limit overloading and thus lower the risk of joint degeneration.^{7,8,14,15,24}

CONCLUSION

The study findings demonstrated no acute changes after marathon running on 3-T hip MRI scans. Future research should focus on the long-term effects of marathon running over a longer period of time to better understand the implications of marathon running on the hip joints.

Supplemental material for this article is available at <http://journals.sagepub.com/doi/suppl/10.1177/232596712111010405>.

REFERENCES

- Barr C, Bauer JS, Malfair D, et al. MR imaging of the ankle at 3 Tesla and 1.5 Tesla: protocol optimization and application to cartilage, ligament and tendon pathology in cadaver specimens. *Eur Radiol.* 2007; 17(6):1518-1528.
- Chi AS, Long SS, Zoga AC, et al. Prevalence and pattern of gluteus medius and minimus tendon pathology and muscle atrophy in older individuals using MRI. *Skeletal Radiol.* 2015; 44(12):1727-1733.
- Clough PJ, Dutch S, Maughan RJ, Shepherd J. Pre-race drop-out in marathon runners: reasons for withdrawal and future plans. *Br J Sports Med.* 1987;21(4):148-149.
- Clough PJ, Shepherd J, Maughan RJ. Marathon finishers and pre-race drop-outs. *Br J Sports Med.* 1989;23(2):97-101.
- Cuzick J, Warwick J, Pinney E, Warren RML, Duffy SW. Tamoxifen and breast density in women at increased risk of breast cancer. *J Natl Cancer Inst.* 2004;96(8):621-628.
- Derrick TR. The effects of knee contact angle on impact forces and accelerations. *Med Sci Sports Exerc.* 2004;36(5):832-837.
- Dixon SJ, Collop AC, Batt ME. Surface effects on ground reaction forces and lower extremity kinematics in running. *Med Sci Sports Exerc.* 2000;32(11):1919-1926.
- Eckstein F, Tieschky M, Faber S, Englmeier KH, Reiser M. Functional analysis of articular cartilage deformation, recovery, and fluid flow following dynamic exercise in vivo. *Anat Embryol (Berl).* 1999;200(4): 419-424.
- Fischbach F, Bruhn H, Unterhauser F, et al. Magnetic resonance imaging of hyaline cartilage defects at 1.5 T and 3.0 T: comparison of medium T2-weighted fast spin echo, T1-weighted two-dimensional and three-dimensional gradient echo pulse sequences. *Acta Radiol.* 2005;46(1):67-73.
- Fletcher KP, Eadie D. Pre-race drop-out from the Glasgow Marathon. *Br J Sports Med.* 1986;20(2):74-76.
- Fuchs B, Weishaupt D, Zanetti M, Hodler J, Gerber C. Fatty degeneration of the muscles of the rotator cuff: assessment by computed tomography versus magnetic resonance imaging. *J Shoulder Elbow Surg.* 1999;8(6):599-605.
- Goutallier D, Postel J-M, Bernageau J, Lavau L, Voisin M-C. Fatty muscle degeneration in cuff ruptures. *Clin Orthop Relat Res.* 1994; 304:78-83.
- Hohmann E, Wörtler K, Imhoff AB. MR imaging of the hip and knee before and after marathon running. *Am J Sports Med.* 2004;32(1): 55-59.
- Horga LM, Henckel J, Fotiadou A, et al. Can marathon running improve knee damage of middle-aged adults? A prospective cohort study. *BMJ Open Sport Exerc Med.* 2019;5:e000586.
- Horga LM, Henckel J, Fotiadou A, et al. Is the immediate effect of marathon running on novice runners' knee joints sustained within 6 months after the run? A follow-up 3.0 T MRI study. *Skeletal Radiol.* 2020;49(8):1221-1229.
- Krampla W, Mayrhofer R, Malcher J, Kristen KH, Urban M, Hruby W. MR imaging of the knee in marathon runners before and after competition. *Skeletal Radiol.* 2001;30(2):72-76.
- Krampla WW, Newrkla SP, Kroener AH, Hruby WF. Changes on magnetic resonance tomography in the knee joints of marathon runners: a 10-year longitudinal study. *Skeletal Radiol.* 2008;37(7):619-626.
- Kursunoglu-Brahme S, Schwaighofer B, Gundry C, Ho C, Resnick D. Jogging causes acute changes in the knee joint: an MR study in normal volunteers. *AJR Am J Roentgenol.* 1990;154(6):1233-1235.
- Lee S, Nardo L, Kumar D, et al. Scoring hip osteoarthritis with MRI (SHOMRI): a whole joint osteoarthritis evaluation system. *J Magn Reson Imaging.* 2015;41(6):1549-1557.
- Luke AC, Stehling C, Stahl R, et al. High-field magnetic resonance imaging assessment of articular cartilage before and after marathon running: does long-distance running lead to cartilage damage? *Am J Sports Med.* 2010;38(11):2273-2280.
- Marti B, Knobloch M, Tschopp A, Jucker A, Howald H. Is excessive running predictive of degenerative hip disease? Controlled study of former elite athletes. *Br Med J.* 1989;299(6691):91-93.
- Miller RH, Edwards WB, Brandon SCE, Morton AM, Deluzio KJ. Why don't most runners get knee osteoarthritis? A case for per-unit-distance loads. *Med Sci Sports Exerc.* 2014;46(3):572-579.
- Niilsson AK, Lohmander LS, Klässbo M, Roos EM. Hip disability and Osteoarthritis Outcome Score (HOOS)—validity and responsiveness in total hip replacement. *BMC Musculoskelet Disord.* 2003;4(1):10-17.

24. Nyland JA, Shapiro R, Stine RL, Horn TS, Ireland ML. Relationship of fatigued run and rapid stop to ground reaction forces, lower extremity kinematics, and muscle activation. *J Orthop Sports Phys Ther.* 1994; 20(3):132-137.
25. Ponzio DY, Syed UAM, Purcell K, et al. Low prevalence of hip and knee arthritis in active marathon runners. *J Bone Joint Surg Am.* 2018; 100(2):131-137.
26. Schueller-Weidekamm C, Schueller G, Uffmann M, Bader TR. Does marathon running cause acute lesions of the knee? Evaluation with magnetic resonance imaging. *Eur Radiol.* 2006;16(10):2179-2185.
27. Shellock FG, Deutsch AL, Mink JH, Kerr R. Do asymptomatic marathon runners have an increased prevalence of meniscal abnormalities? An MR study of the knee in 23 volunteers. *AJR Am J Roentgenol.* 1991;157(6):1239-1241.
28. Spector TD, Harris PA, Hart DJ, et al. Risk of osteoarthritis associated with long-term weight-bearing sports: a radiologic survey of the hips and knees in female ex-athletes and population controls. *Arthritis Rheum.* 1996;39(6):988-995.
29. Stahl R, Luke A, Ma CB, et al. Prevalence of pathologic findings in asymptomatic knees of marathon runners before and after a competition in comparison with physically active subjects—a 3.0 T magnetic resonance imaging study. *Skeletal Radiol.* 2008;37(7):627-638.
30. Stehling C, Luke A, Stahl R, et al. Meniscal T1rho and T2 measured with 3.0 T MRI increases directly after running a marathon. *Skeletal Radiol.* 2011;40(6):725-735.
31. Tveit M, Rosengren BE, Nilsson JÅ, Karlsson MK. Former male elite athletes have a higher prevalence of osteoarthritis and arthroplasty in the hip and knee than expected. *Am J Sports Med.* 2012;40(3): 527-533.
32. van den Bogert AJ, Read L, Nigg BM. An analysis of hip joint loading during walking, running, and skiing. *Med Sci Sports Exerc.* 1999;31(1): 131-142.