



Endoscopic ultrasound-guided transesophageal drainage for acute mediastinitis caused by pancreatic fistula

Yasuki Hori^{a,*}, Kensuke Fukumitsu^b, Itaru Naitoh^a, Tomohiro Onuki^b, Kazuki Hayashi^a, Akio Niimi^b, Hiromi Kataoka^a

^a Department of Gastroenterology and Metabolism, Nagoya City University Graduate School of Medical Sciences, Nagoya, Japan

^b Department of Respiratory Medicine, Allergy and Clinical Immunology, Nagoya City University Graduate School of Medical Sciences, Nagoya, Japan

ARTICLE INFO

Keywords:

Acute mediastinitis
Endoscopic ultrasound
Pancreatic fistula
Transesophageal nasocystic drainage

ABSTRACT

Acute mediastinitis is a life-threatening condition, and standard treatment is percutaneous drainage and/or surgical treatment with antibiotics. A 58-year-old male diagnosed with acute mediastinitis originating from pancreatic fistula, detected only by endoscopic-ultrasound. We inserted a transesophageal nasocystic tube under endoscopic ultrasound guidance and successfully controlled the infection. The root of the main pancreatic duct for pancreatic juice drainage was recanalized using a duodenal endoscope. Endoscopic diagnosis and treatment by ultrasound have improved significantly; therefore, clinicians should know the potential of these procedures. The results of the present case may aid in the future treatment of patients with acute mediastinitis.

1. Introduction

Despite recent advances in antibiotic therapy and progress in intensive and critical care, acute mediastinitis remains a life-threatening condition with a mortality rate of 19–47% [1]. Common causes of acute mediastinitis are esophageal perforation and surgical infection. Descending mediastinitis from a pharynx infection and ascending mediastinitis from pancreatitis are extremely rare [2]. A few cases of transesophageal endoscopic ultrasound (EUS)-guided drainage for acute mediastinitis have been reported previously. Herein, we report a case of acute mediastinitis controlled by endoscopic nasocystic drainage (ENCD), followed by endoscopic transpapillary pancreatic drainage to treat pancreatic fistula detected by EUS.

2. Case presentation

A 58-year-old male with dyspnea was referred to our emergency department. Cross-sectional imaging revealed bilateral pleural effusion (Fig. 1A). Although pancreatolithiasis was present in the head of the pancreas (Fig. 1B) with atrophic pancreas diagnosed as chronic pancreatitis, pancreatic fistula was not observed on contrast-enhanced computed tomography (Fig. 1C). First, upper esophagogastroduodenoscopy was performed to rule out esophageal rupture, and gastrointestinal perforation was not observed. For symptom relief, bilateral

thoracic drainage was performed, and the pleural effusion was exudative with a mildly elevated amylase level (171 IU/L; normal range, 44–132 IU/L). After treatment, periesophageal fluid accumulation became apparent with a serum inflammatory response, and the patient was diagnosed with acute mediastinitis (Fig. 2A). The inflammation spread to the superior mediastinum (Fig. 2B).

Due to anatomical reasons, respiratory surgeons could not select a percutaneous drainage route; thus, EUS-guided drainage from the esophagus was conducted. A therapeutic endoscope (GF-UCT260, Olympus Medical System Corporation, Tokyo, Japan) was used, and abnormal accumulation of fluid around the lower esophagus was observed. At the same time, the remaining trace of pancreatic fistula from the tail of the pancreas was confirmed by EUS (Fig. 3A). The accumulated mediastinal fluid was drained from the lower esophagus (Fig. 3B). Then, a 0.025-inch guidewire (VisiGlide2™, Olympus Medical System Corporation) was inserted and a 6-Fr nasocystic drainage catheter placed through the guidewire (ENCD) (Fig. 3C and D). Flushing via the ENCD tube allowed control of the cloudy waste fluid, and the accumulated periesophagus fluid disappeared. Biochemical analysis of the collected fluid revealed an extremely high amylase level (95,743 IU/L), and we determined that these events were associated with the pancreatic fistula.

After controlling the mediastinal infection via ENCD, we decided to treat the pancreatic fistula with transpapillary approach using therapeutic duodenoscopy (TJF-260V endoscope, Olympus Medical System

* Corresponding author. 1 Kawasumi, Mizuho-cho, Mizuho-ku Nagoya, 4678601, Japan.

E-mail address: yhori@med.nagoya-cu.ac.jp (Y. Hori).

<https://doi.org/10.1016/j.rmcr.2021.101480>

Received 29 January 2021; Received in revised form 10 July 2021; Accepted 23 July 2021

Available online 28 July 2021

2213-0071/© 2021 Published by Elsevier Ltd. This is an open access article under the CC BY-NC-ND license (<http://creativecommons.org/licenses/by-nc-nd/4.0/>).

Abbreviations

EHL	electronic hydraulic lithotripsy
ENCD	endoscopic nasocystic drainage
EUS	endoscopic ultrasound
MPD	main pancreatic duct.

cross-sectional imaging, and only mediastinal liquid accumulation with infection could be confirmed. Recently, EUS resolution has improved significantly, and pancreatic fistula from the tail of the pancreas can only be identified on EUS. Subsequently, transluminal drainage from the esophagus was performed successfully. Few reports of acute mediastinitis treated via the transesophageal route have been published. In those reports, all subjects were temporally aspirated or subjected to insertion of a plastic or metal stent [4] (internal drainage), but not an ENCD tube (external drainage). An advantage of external drainage is

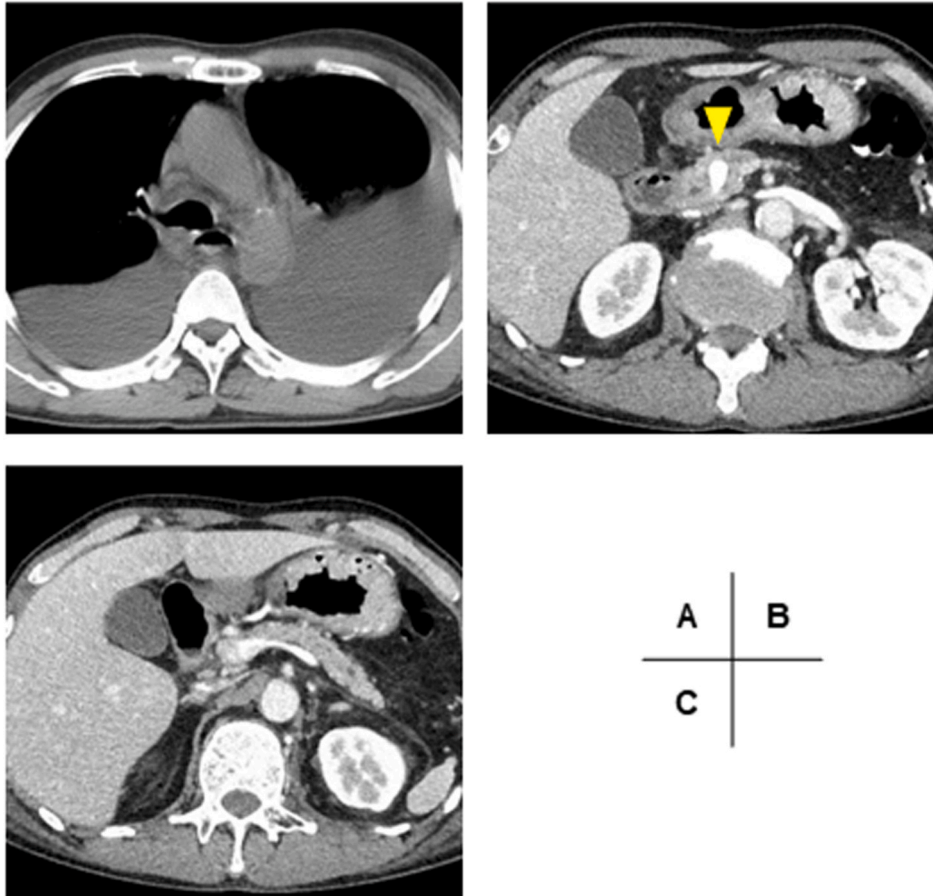


Fig. 1. A 58-year-old male with dyspnea was referred to our emergency department. Cross-sectional imaging revealed bilateral pleural effusion (A). Although pancreatolithiasis was present in the head of the pancreas (arrowhead) (B) with atrophic pancreas diagnosed as chronic pancreatitis, obvious pancreatic fistula was not observed on contrast-enhanced computed tomography (C).

Corporation). However, pancreatolithiasis was completely impacted in the main pancreatic duct and the upstream pancreatic duct could not be accessed. Therefore, a pancreatoscope was inserted via the therapeutic endoscope, and an electronic hydraulic lithotripsy (EHL) system was used for crushing the calculi (Supplemental Figures A and B). Finally, the guidewire was inserted beyond the pancreatolithiasis area, and a plastic pancreatic stent was placed successfully (Supplemental Figures C–E). A series of these treatments would be useful for acute mediastinitis caused by pancreatic fistula. A patient might recover completely without surgical treatment, although if necessary, the surgery can be performed with minimal invasion.

3. Discussion

Pseudocyst formation associated with pancreatic fistula is a common complication of both acute and chronic pancreatitis [3]. In the present case, pancreatic juice leakage around the pancreas was not observed on

that the characteristics of the stored liquid with continuous irrigation can be confirmed. Furthermore, internal drainage poses a risk of reinfection caused by food, digestive juice, or saliva. Therefore, external drainage using EUS might be a useful option for treating acute mediastinitis to avoid percutaneous drainage, surgical treatment, and/or a fatal course.

The previous standard treatment for intraperitoneal necrotizing pancreatitis with infected necrotic tissue was open necrosectomy, however, this invasive procedure is associated with a high rate of complications and death. Currently, a minimally invasive step-up approach is recommended as the standard treatment due to favorable clinical outcomes [5]. Because cases of infected pancreatic fistula extending to the mediastinum are very rare, establishing an evidence-based treatment strategy is difficult. However, in the future, similar to treatment for peripancreatic necrotizing pancreatitis, that for acute mediastinitis may change to the step-up approach with minimally invasive treatment, as selected for our patient. Because diagnosis and

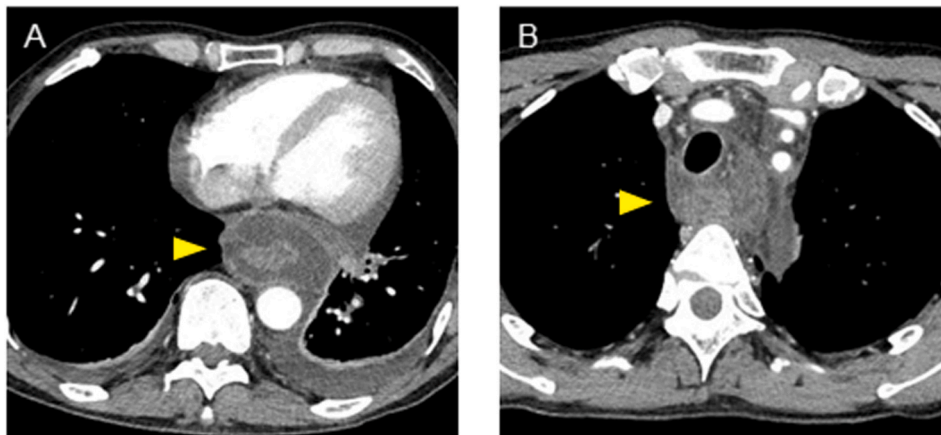


Fig. 2. Periesophageal fluid accumulation became apparent with a serum inflammatory response and was diagnosed as acute mediastinitis (A). The inflammation spread to the superior mediastinum (B).

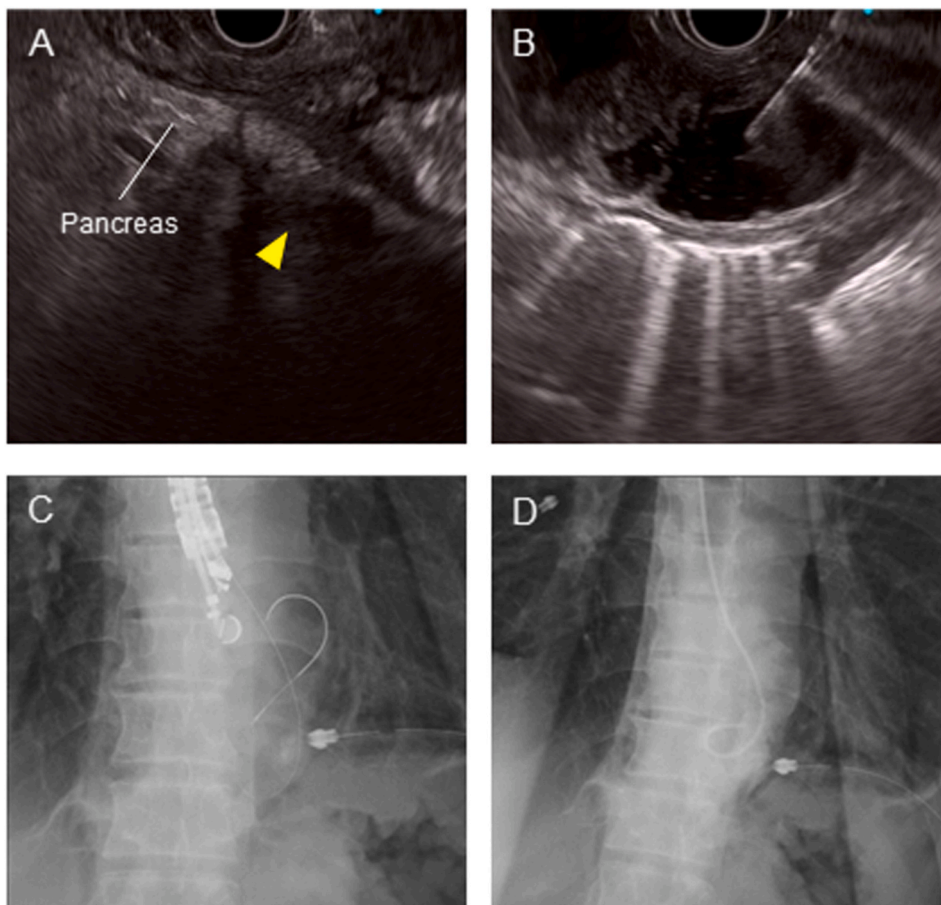


Fig. 3. EUS-guided transesophageal drainage of acute mediastinitis. We confirmed the remaining trace of pancreatic fistula from the tail of the pancreas (*arrowhead*) (A). The accumulated mediastinal fluid was drained from the lower esophagus (B) under EUS guidance. A guidewire was inserted through the puncture needle (C) and an endoscopic nasocystic drainage tube placed (D).

treatment using EUS for intraperitoneal organs have been reported by gastroenterologists to be effective and minimally invasive, this information should be shared with respiratory clinicians. Our experience may be useful for physicians treating patients with acute mediastinitis.

Diagnosis and treatment of pancreatic fistula are difficult and require substantial experience with endoscopy. As presented in this case report, endoscopic diagnosis and treatment, such as EUS and pancreatoscopy (using an EHL system), have significantly improved. We expect that the

recent advances in endoscopic treatment can provide many benefits to patients. Therefore, the information and work should be shared by all departments.

Ethics approval

Written informed consent was obtained from the patient for publication of this case report and any accompanying images. This case report

was approved according to the guidelines of the Review Board of the Nagoya City University Graduate School of Medical Sciences.

Availability of data and materials

Data sharing not applicable to this article as no datasets were generated or analyzed during the current study.

Author contributions

Conception and design: Y.H. and K.F. Analysis and interpretation of the data: Y.H., K.F., T.O. and K.H. Drafting of the article: Y.H., K.F. and I. N. Final approval of the article: H.K. and A.N.

Funding

This work was supported by JSPS KAKENHI Grant Number JP19K17441 for the cost of English editing service.

Declaration of competing interest

The authors have no conflicts of interest to declare.

Acknowledgement

Not applicable.

Appendix A. Supplementary data

Supplementary data to this article can be found online at <https://doi.org/10.1016/j.rmcr.2021.101480>.

References

- [1] G.J. Ridder, W. Maier, S. Kinzer, C.B. Teszler, C.C. Boedeker, J. Pfeiffer, Descending necrotizing mediastinitis: contemporary trends in etiology, diagnosis, management, and outcome, *Ann. Surg.* 251 (2010) 528–534.
- [2] Y.C. Chang, C.W. Chen, Thoracoscopic drainage of ascending mediastinitis arising from pancreatic pseudocyst, *Interact. Cardiovasc. Thorac. Surg.* 9 (2009) 144–145.
- [3] Y. Hori, S.S. Vege, S.T. Chari, F.C. Gleeson, M.J. Levy, R.K. Pearson, et al., Classic chronic pancreatitis is associated with prior acute pancreatitis in only 50% of patients in a large single-institution study, *Pancreatology* 19 (2019) 224–229.
- [4] J.B. Gornals, C. Loras, R. Mast, J.M. Botargues, J. Busquets, J. Castellote, Endoscopic ultrasound-guided transesophageal drainage of a mediastinal pancreatic pseudocyst using a novel lumen-apposing metal stent, *Endoscopy* 44 (Suppl 2 UCTN) (2012) E211–E212.
- [5] S. van Brunschot, J. van Grinsven, H.C. van Santvoort, O.J. Bakker, M.G. Besselink, M.A. Boermeester, et al., Endoscopic or surgical step-up approach for infected necrotising pancreatitis: a multicentre randomised trial, *Lancet* 391 (2018) 51–58.