

# Tolvaptan use during hyperhydration in paediatric intracranial lymphoma with SIADH

Ruben H Willemsen<sup>1</sup>, Violeta Delgado-Carballar<sup>1</sup>, Daniela Elleri<sup>1</sup>, Ajay Thankamony<sup>1</sup>,  
G A Amos Burke<sup>2</sup>, James C Nicholson<sup>2</sup> and David B Dunger<sup>1</sup>

<sup>1</sup>Department of Paediatric Endocrinology, University of Cambridge, Cambridge, UK and <sup>2</sup>Department of Paediatric Haematology and Oncology, Addenbrooke's Hospital, Cambridge University Hospitals NHS Foundation Trust, Cambridge, UK

Correspondence  
should be addressed  
to R H Willemsen  
**Email**  
rw490@medschl.cam.ac.uk

## Summary

An 11-year-old boy developed severe syndrome of inappropriate antidiuretic hormone secretion (SIADH) after diagnosis of an intracranial B-cell lymphoma. His sodium levels dropped to 118–120 mmol/L despite 70% fluid restriction. For chemotherapy, he required hyperhydration, which posed a challenge because of severe hyponatraemia. Tolvaptan is an oral, highly selective arginine vasopressin V2-receptor antagonist, which has been licensed in adults for the management of SIADH and has been used in treating paediatric heart failure. Tolvaptan gradually increased sodium levels and allowed liberalisation of fluid intake and hyperhydration. Tolvaptan had profound effects on urinary output in our patient with increases up to 8 mL/kg/h and required close monitoring of fluid balance, frequent sodium measurements and adjustments to intake. After hyperhydration, tolvaptan was stopped, and the lymphoma went into remission with reversal of SIADH. We report one of the first uses of tolvaptan in a child with SIADH, and it was an effective and safe treatment to manage severe SIADH when fluid restriction was not possible or effective. However, meticulous monitoring of fluid balance and sodium levels and adjustments of fluid intake are required to prevent rapid sodium changes.

## Learning points:

- Tolvaptan can be used in paediatric patients with SIADH to allow hyperhydration during chemotherapy.
- Tolvaptan has profound effects on urinary output and meticulous monitoring of fluid balance and sodium levels is therefore warranted.
- Tolvaptan was well tolerated without significant side effects.

## Background

The syndrome of inappropriate antidiuretic hormone secretion (SIADH) is a common cause of hyponatraemia in paediatrics (1). The aetiology is variable and includes increased cranial ADH production (infections, thrombosis, haemorrhage, cerebral malignancies and other cerebral diseases), drugs, pulmonary disease and ectopic production of ADH (malignancies) (1). The first-line treatment consists of fluid restriction in asymptomatic children. More severe forms with neurological symptoms may require administration of hyperosmolar saline,

which is often combined with furosemide. In most cases, the SIADH is temporary and resolves by treating the underlying cause.

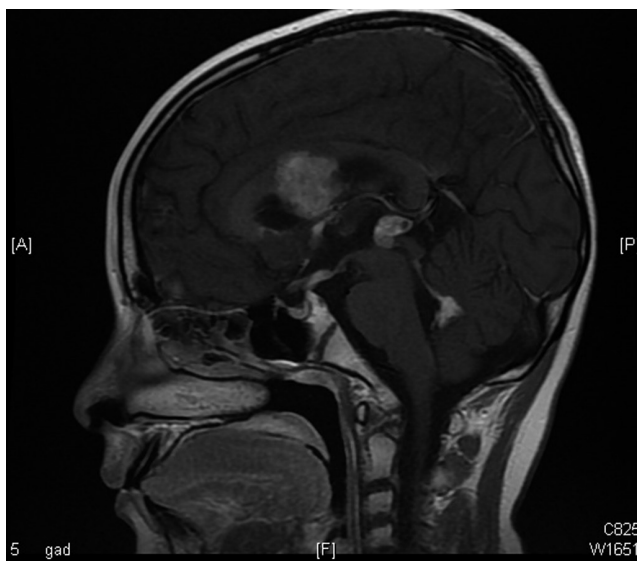In the past decade, an alternative treatment option for SIADH has become available – the vaptans (2). Vaptans are vasopressin receptor antagonists. There are three types of vasopressin receptors: V1a, V1b and V2. Binding of AVP to the V2 receptor in the renal collecting duct leads to insertion of aquaporin 2 water channels in the apical membrane promoting re-absorption of water.

Vaptans compete with AVP at the receptor-binding site, thus promoting the excretion of free water (3). Tolvaptan is a selective V2 receptor antagonist and is the only vaptan approved by the European Medicines Agency. Data regarding the safety and efficacy of vaptan use in paediatrics are limited, and the use of tolvaptan in SIADH in childhood has not previously been reported until recently in infants (4).

We present a case of a child with an intracranial lymphoma and severe SIADH, refractory to treatment with fluid restriction. Although the hyponatraemia was not accompanied by any neurological symptoms, a challenging situation arose as the chemotherapy required hyperhydration. Tolvaptan allowed the liberalisation of his fluid intake and eventually hyperhydration during the first course of chemotherapy.

### Case presentation

An 11-year-old otherwise healthy boy presented to the Emergency Department with a 2-week history of headaches, morning sickness and a collapse on the day of presentation. A CT scan showed a multifocal intracranial tumour with mild hydrocephalus, which was confirmed by MRI (Fig. 1). He was started on dexamethasone and admitted, awaiting further diagnostic tests. In the



**Figure 1**

MRI scan showing a multifocal intracranial mass, with lesions in the anterior part of the corpus callosum, extending inferiorly on the septum pellucidum and columns of the fornices, adjacent foci of subependymal enhancing tumour in the heads of the caudate nuclei and anterior part of the left thalamus, tumour in the pineal region, inferior third ventricle and roof of the fourth ventricle.

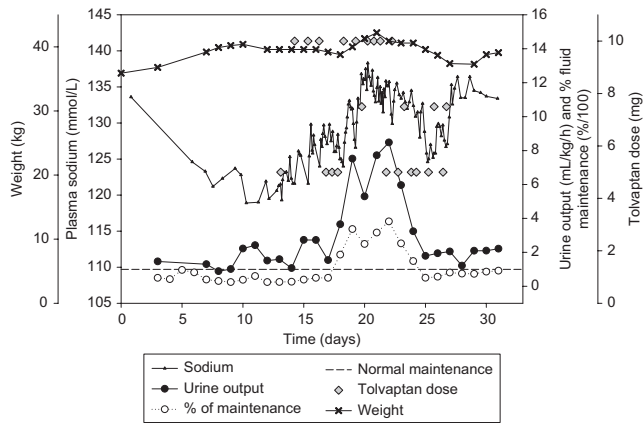
first week of his admission, he developed SIADH in keeping with the diagnostic criteria of Spasovski *et al.* (5): (day 6: plasma sodium 126 mmol/L (ref. 135–145), plasma osmolality 263 mOsm/kg (ref. 280–300), urine osmolality 195 mOsm/kg, urine sodium 36.6 mmol/L and plasma creatinine 39 µmol/L (ref. 35–80)), which was unresponsive to 70% fluid restriction (day 12: plasma sodium 119 mmol/L, plasma osmolality 245 mOsm/kg, urine osmolality 645 mOsm/kg, urine sodium 209 mmol/L, plasma creatinine 32 µmol/L, plasma urea 5.0 mmol/L (ref. 2.9–6.4) and uric acid 107 nmol/L (ref. 140–320)). The possibility of cerebral salt wasting was considered, but the clinical picture was more in keeping with SIADH, with no signs of dehydration, increase in weight and low urine output.

### Investigation

A biopsy on day 5 revealed that the tumour was a B-cell lymphoma. An MRI of spine and CT of thorax–abdomen–pelvis showed no metastases or lymphadenopathy, but some free fluid in the pelvis and left iliac fossa, of uncertain clinical significance. In view of a borderline low free T<sub>4</sub> (FT<sub>4</sub> 11.2 pmol/L (ref. 10–19.9), TSH 0.19 U/L (ref. 0.35–5.3)) and the appearances of an intracranial tumour, the patient was commenced on levothyroxine on day 6.

### Treatment

Treatment for the B-cell lymphoma followed FAB LMB 96 (6). Initial treatment involved the use of hyperhydration to prevent tumour lysis syndrome and to deliver high-dose methotrexate (MTX), which posed a challenging situation in view of his concurrent SIADH and severe hyponatraemia, despite 70% fluid restriction (consistent with allowing an intake equivalent to 30% maintenance fluids). Tolvaptan was started on day 13 at a dose of 0.14 mg/kg once a day and titrated up to 0.28 mg/kg twice a day based on fluid requirements and serum sodium levels. The tablets were dispersed in water and the dose taken as an aliquot. Tolvaptan gradually increased the sodium levels and allowed liberalisation of fluid intake and hyperhydration up to 3.8 times the normal fluid maintenance (Fig. 2). Of note, the administration of tolvaptan in our patient had profound effects on urinary output with increases up to 8 mL/kg/h and required close monitoring in an intensive care setting with frequent sodium measurements and adjustments to intake. The boy also developed a desquamative rash on the dorsal side of both hands.



**Figure 2**

Sodium, weight, tolvaptan doses, urine output (mL/kg/h) and fluid intake as a percentage of normal maintenance vs time. The right y-axis is used for both urine output and fluid intake where '2' resembles a urine output of 2 mL/kg/h or 200% of normal fluid maintenance respectively. Each grey diamond indicates a dose of tolvaptan and the dose in mg can be read from the right off-set y-axis.

As the rash appeared whilst he was also receiving chemotherapy, it was unclear whether this was related to tolvaptan. After hyperhydration and clearance of methotrexate, tolvaptan doses and frequency could be decreased and eventually stopped allowing a normal fluid intake and acceptable sodium levels.

## Outcome and follow-up

After this first course of chemotherapy, the SIADH subsided and subsequent courses could be administered without any problems. The tumour went into remission, and there has been no recurrence of the tumour after almost 2 years of follow-up. The child has entered into spontaneous puberty. Follow-up endocrine testing showed a normal cortisol response but insufficient growth hormone (GH) response on two occasions, and he will be started on GH in due course.

## Discussion

The exact aetiology of SIADH in our case remains unknown, but various mechanisms could be considered, such as ADH production from lymphoma cells or intracranial effects of the tumour. The use of tolvaptan in this child with severe SIADH allowed liberalisation of fluid intake and eventually hyperhydration after high dose MTX. Current treatment options for SIADH are limited and often not effective. In most cases of asymptomatic hyponatraemia as a consequence of SIADH, treatment

can be limited to fluid restriction. However, as our case demonstrates, fluid restriction is not always feasible.

Another drug which has previously been used in patients with hyponatraemia is the tetracycline derivative antibiotic demeclocycline. Although the mode of action is not well understood, it can induce nephrogenic diabetes insipidus, and a recent systematic review reported that demeclocycline was able to increase sodium levels in about 60% of patients with hyponatraemia secondary to SIADH (7). However, the onset of action is unpredictable and varies between 2 and 5 days (7). The effect is considered to be milder than that of the vaptans, and it is questionable whether this would have enabled us to hyperhydrate our patient.

Reports regarding the use of vaptans in paediatrics are scarce. Tolvaptan has been reported in a case series of 28 paediatric patients with heart failure (8), a patient with restrictive cardiomyopathy (9) and a patient with massive oedema due to nephrotic syndrome (10). In these paediatric case reports and case series, tolvaptan was well tolerated and considered to be a safe treatment. There has been a recent report of the use of tolvaptan for SIADH in infancy (4), but experience is scarce. An intravenous form of vaptan, conivaptan, has previously been used in the management of hyperhydration during SIADH (11). Conivaptan is however not licensed in Europe.

Both demeclocycline and vaptans could potentially cause harm, such as the osmotic demyelination syndrome when the sodium increases too rapidly. A recent clinical practice guideline, developed as a joint venture of the European Society of Intensive Care Medicine, European Society for Endocrinology and European Renal Association-European Dialysis and Transplant Association, recommended against using these agents in patients with asymptomatic hyponatraemia as a consequence of SIADH (5). As illustrated by our case, there may however be situations where fluid restriction is not possible.

The administration of tolvaptan in our patient had profound effects on urinary output, and required close monitoring of sodium and fluid balance, and adjustments to the intake in an intensive care setting. Of note, Tzoulis *et al.* described their experiences with tolvaptan in a case series of adult patients (mean age 74.4 years) and highlighted the risk of overly rapid sodium correction, which seemed to be greater in patients with lower starting sodium levels (12). Too rapid correction of hyponatraemia may lead to osmotic demyelination syndrome. We therefore recommend that tolvaptan should be started at a low dose, and then should be slowly increased according to response, and this should



be accompanied by frequent monitoring of sodium levels and urinary output.

In conclusion, tolvaptan is a safe treatment in situations of childhood SIADH where fluid restriction is not possible and hyperhydration is required, but meticulous monitoring of sodium levels and adjustment of fluid intake are warranted.

---

#### Declaration of interest

The authors declare that there is no conflict of interest that could be perceived as prejudicing the impartiality of the research reported.

---

#### Funding

This research did not receive any specific grant from any funding agency in the public, commercial or not-for-profit sector.

---

#### Patient consent

Written informed consent has been obtained from the patient's guardian for publication of the submitted article and accompanying images.

---

#### Author contribution statement

R H W was involved in the paediatric endocrine clinical care of the patient, researched data for the article, wrote the manuscript and reviewed/edited the paper before submission. D E, A T and D B D were involved in the paediatric endocrine clinical care of the patient, contributed to discussion of content and reviewed the paper before submission. V D C contributed to discussion of content and reviewed the paper before submission. A B and J N were involved in the paediatric oncology clinical care of the patient, contributed to discussion of content and reviewed the paper before submission.

---

#### References

- 1 Zieg J 2014 Evaluation and management of hyponatraemia in children. *Acta Paediatrica* **103** 1027–1034. (doi:10.1111/apa.12705)
- 2 Aditya S & Rattan A 2012 Vaptans: a new option in the management of hyponatremia. *International Journal of Applied and Basic Medical Research* **2** 77–83. (doi:10.4103/2229-516X.106347)
- 3 Lehrich RW, Ortiz-Melo DI, Patel MB & Greenberg A 2013 Role of vaptans in the management of hyponatremia. *American Journal of Kidney Diseases* **62** 364–376. (doi:10.1053/j.ajkd.2013.01.034)
- 4 Marx-Berger D, Milford DV, Bandhakavi M, Van't Hoff W, Kleta R, Dattani M & Bockenhauer D 2016 Tolvaptan is successful in treating inappropriate antidiuretic hormone secretion in infants. *Acta Paediatrica* **105** e334–e337. (doi:10.1111/apa.13415)
- 5 Spasovski G, Vanholder R, Allolio B, Annane D, Ball S, Bichet D, Decaux G, Fenske W, Hoorn EJ, Ichai C, et al. 2014 Clinical practice guideline on diagnosis and treatment of hyponatraemia. *European Journal of Endocrinology* **170** G1–G47. (doi:10.1530/EJE-13-1020)
- 6 Patte C, Auperin A, Gerrard M, Michon J, Pinkerton R, Sposto R, Weston C, Raphael M, Perkins SL, McCarthy K, et al. 2007 Results of the randomized international FAB/LMB96 trial for intermediate risk B-cell non-Hodgkin lymphoma in children and adolescents: it is possible to reduce treatment for the early responding patients. *Blood* **109** 2773–2780. (doi:10.1182/blood-2006-07-036673)
- 7 Miell J, Dhanjal P & Jamookeeah C 2015 Evidence for the use of demeclocycline in the treatment of hyponatraemia secondary to SIADH: a systematic review. *International Journal of Clinical Practice* **69** 1396–1417. (doi:10.1111/ijcp.12713)
- 8 Regen RB, Gonzalez A, Zawodniak K, Leonard D, Quigley R, Barnes AP & Koch JD 2013 Tolvaptan increases serum sodium in pediatric patients with heart failure. *Pediatric Cardiology* **34** 1463–1468. (doi:10.1007/s00246-013-0671-y)
- 9 Horibata Y, Murakami T & Niwa K 2014 Effect of the oral vasopressin receptor antagonist tolvaptan on congestive cardiac failure in a child with restrictive cardiomyopathy. *Cardiology in the Young* **24** 155–157. (doi:10.1017/S1047951112002272)
- 10 Shimizu M, Ishikawa S, Yachi Y, Muraoka M, Tasaki Y, Iwasaki H, Kuroda M, Ohta K & Yachie A 2014 Tolvaptan therapy for massive edema in a patient with nephrotic syndrome. *Pediatric Nephrology* **29** 915–917. (doi:10.1007/s00467-013-2687-1)
- 11 Rianthavorn P, Cain JP & Turman MA 2008 Use of conivaptan to allow aggressive hydration to prevent tumor lysis syndrome in a pediatric patient with large-cell lymphoma and SIADH. *Pediatric Nephrology* **23** 1367–1370. (doi:10.1007/s00467-008-0809-y)
- 12 Tzoulis P, Waung JA, Bagkeris E, Carr H, Khoo B, Cohen M & Bouloux PM 2016 Real-life experience of tolvaptan use in the treatment of severe hyponatraemia due to syndrome of inappropriate antidiuretic hormone secretion. *Clinical Endocrinology* **84** 620–626. (doi:10.1111/cen.12943)

---

Received in final form 23 September 2016

Accepted 29 September 2016