

Available online at www.sciencedirect.com

ScienceDirect

journal homepage: <http://Elsevier.com/locate/radcr>

Neuroradiology

Hyperacute unilateral contrast-induced parotiditis during cerebral angiography

Song J. Kim MD*, Jonathan A. Grossberg MD, Raul G. Nogueira MD, Diogo C. Haussen MD

Marcus Stroke and Neuroscience Center—Grady Memorial Hospital, Emory University School of Medicine, 80
Jesse Hill Jr. Drive, Atlanta, GA 30303, USA

ARTICLE INFO

Article history:

Received 20 June 2017

Received in revised form 16

September 2017

Accepted 25 September 2017

Available online 1 November 2017

Keywords:

Cerebral angiography

Iodine contrast

Sialadenitis

ABSTRACT

An uncommon complication of iodinated contrast administration is the development of bilateral sialadenitis. We report a unique case of hyperacute unilateral parotiditis during diagnostic cerebral angiography of the external carotid artery, which mimicked possible iatrogenic vascular event associated with cerebral endovascular procedures. Discussion includes the differential diagnosis, diagnostic studies, and treatments for this unusual condition.

© 2017 the Authors. Published by Elsevier Inc. under copyright license from the University of Washington. This is an open access article under the CC BY-NC-ND license (<http://creativecommons.org/licenses/by-nc-nd/4.0/>).

Introduction

Catheter cerebral angiography has become an integral diagnostic tool in the evaluation of various neurovascular diseases. As the number of endovascular procedures in neurologic patients surged in recent years [1], clinicians can benefit from familiarizing themselves with both common and uncommon complications of cerebral angiography.

The hazards of the use of iodinated contrast merit attention. First described by earlier investigators as iodine mumps,

contrast-induced sialadenitis is a rare complication associated with procedures that involve intravascular administration of iodinated contrast media [2]. Contrast-induced sialadenitis is characterized by warm, erythematous swelling of the bilateral salivary glands accompanied by local pain and tenderness, occurring within hours and up to 5 days after contrast administration [3]. Patients require close clinical monitoring as cervical swelling and airway obstruction can occur.

We report a case of hyperacute unilateral contrast-induced parotiditis during diagnostic cerebral angiogram in a 49-year-old woman presenting with subarachnoid hemorrhage.

Competing Interest: The other authors report no conflicts of interest.

HIPAA: Collection and evaluation of protected patient health information for this report was in compliance with the Health Insurance Portability and Accountability Act and the requirements of the Institutional Review Board.

Prior Publications/Presentations: None.

Research Funding: None.

* Corresponding author.

E-mail address: songkim88@gmail.com (S.J. Kim).

<https://doi.org/10.1016/j.radcr.2017.09.020>

1930-0433/© 2017 the Authors. Published by Elsevier Inc. under copyright license from the University of Washington. This is an open access article under the CC BY-NC-ND license (<http://creativecommons.org/licenses/by-nc-nd/4.0/>).

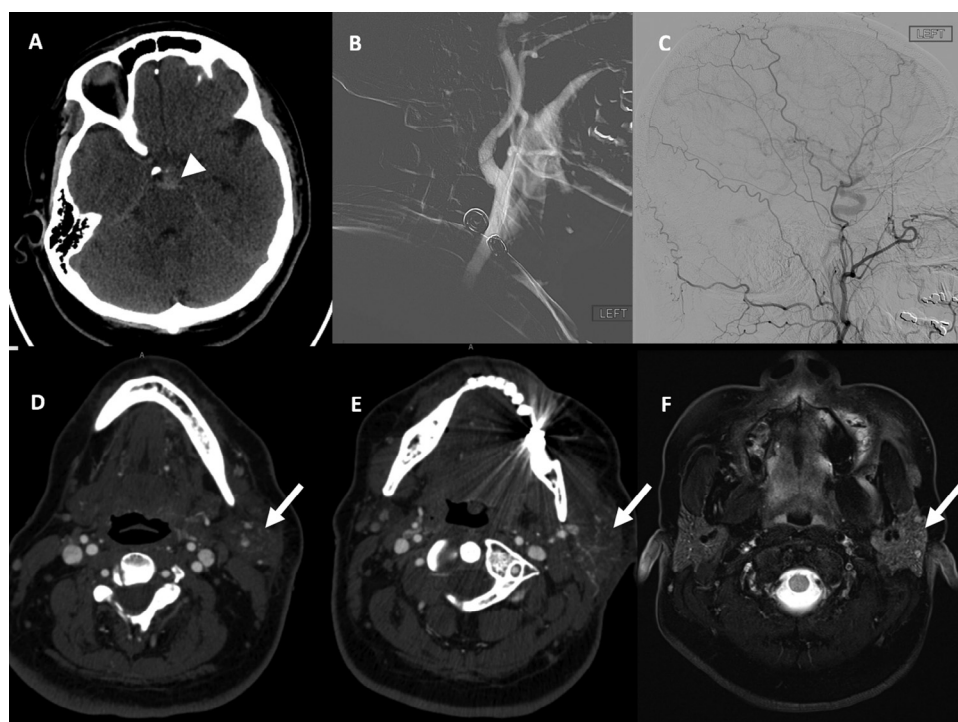


Fig. 1 – (A) Noncontrast computed tomography (CT) scan indicating the subarachnoid hemorrhage (arrowhead); (B) lateral left common carotid artery roadmap angiogram revealing normal carotid bifurcation; (C) lateral left external carotid artery angiogram indicating normal anatomy; (D–F) axial CT with contrast revealing an enlarged and hypervascular left parotid artery (arrow) with normal right parotid anatomy.

Case description

A 49-year-old female patient with medical history of hyperlipidemia experienced a thunderclap headache. Noncontrast computed tomography (CT) of head and CT angiography revealed perimesencephalic subarachnoid hemorrhage (Fig. 1), and no aneurysms or vascular malformations. The patient underwent cerebral angiography under conscious sedation the following morning.

An angiogram of the right internal carotid, external carotid, vertebral artery, thyrocervical trunks, and left internal carotid artery was performed with iohexol (Omnipaque 300, GE Healthcare Inc., Princeton, NJ). The catheter was then maneuvered over a guidewire into the proximal left external artery under roadmap guidance, and angiogram was done with a slow (3 mL/s) injection of 5 mL of contrast (Fig. 1). The patient immediately complained of acute pain involving the left lower facial area. A repeat angiogram was performed and, considering the normal findings, the procedure was completed with left vertebral artery and subclavian trunk angiography. The pain was treated intraprocedurally with intravenous fentanyl. A total of 170 mL of contrast was utilized. Upon completion of the procedure, significant edema of her left lower face and neck was observed. The patient was taken immediately for a repeat noncontrast CT and a CT angiogram to rule out potential arterial injury leading to acute hematoma that could compromise the airway. It demonstrated markedly hyperemic and expanded left parotid gland consistent with left parotiditis (Fig. 1). Intravenous Solu-Medrol and antihistamine were

administered. The pain continued to increase, peaking at 4–6 hours and partially responding to intravenous opiates. The edema peaked at 2–6 hours and was resolved at 24 hours. The right parotid became mildly sore but not swollen at around 2 hours.

Laboratory workup was negative for any underlying renal or hepatic dysfunction. As per institutional workup for perimesencephalic subarachnoid hemorrhage, a repeat vascular imaging study was performed. To avoid further contrast use, CT angiogram was substituted by a magnetic resonance angiogram 1 week after the index event.

Discussion

We report a unique case of hyperacute unilateral contrast-induced parotiditis during diagnostic cerebral angiogram of the external carotid artery.

Since its first case description in 1956, only 35 cases of iodide-associated sialadenitis have been reported in the literature. The majority was described in patients receiving intravenous contrast administration. Zhang et al.'s literature review found that a minority (13.9%) involved unilateral salivary glands; most cases develop within an average of 28 hours [4]. This finding contrasts with the immediate onset in our patient after the injection of the ipsilateral external carotid artery which directly vascularizes the parotid gland, typically via the transverse facial artery. Per literature search, only 4 cases of iodine-induced sialadenitis have been

reported in catheter-based angiograms of the carotid system, one of which presented as submandibular swelling observed on the ipsilateral side following carotid stent placement [5]. These reported cases have not established associations with ionic vs nonionic agent, venous vs arterial injections, or particular imaging modality or procedure performed that could predispose a patient to unilateral sialadenitis.

The pathophysiology of contrast-induced sialadenitis is believed to be a toxic accumulation of contrast material in the glands, leading to edema of mucous membranes, and duct obstruction [6]. Moreover, a large majority of the Na⁺/I⁻ cotransporters are concentrated in the kidneys, and the remainder in the salivary, sweat, and lacrimal glands [7]. Thus, the risk of contrast-induced sialadenitis is presumed to increase with serum iodide levels and with existing renal dysfunction [8]. Indeed, in patients with end-stage renal function, emergent hemodialysis has shown to reduce the duration of the symptoms [9]. In this patient, as she had normal renal function at baseline, the previous contrast load through the CT angiogram may have predisposed to the reaction.

The patient's unilateral acute painful swelling prompted a necessary exclusion of urgent complications as iatrogenic vessel perforation and consequent hematoma. In a survey of 3636 catheter cerebral angiography at 1 center, there was a 0.15% rate of arterial dissections and no perforations [10]. Such iatrogenic vascular events are more often technique-related and more likely to present during interventional (nondiagnostic) procedures, although they still remain rare in occurrence; in 1150 carotid artery stenting procedures, a single case of carotid artery perforation was observed [11]. Another important differential to be considered is allergic angioedema, which is a type I hypersensitivity reaction usually accompanied by urticaria that can be fatal. One Spanish study reports that angioedema can occur in 70% of immediate allergic reactions to contrast media [12].

The most frequently used imaging study for diagnosis of suspected acute parotiditis is CT, MRI with gadolinium, or ultrasound [13]. Serum amylase level can support the diagnosis as well, although not very specific [14]. Because contrast-induced sialadenitis is not an Immunoglobulin E-mediated hypersensitivity reaction, prophylaxis with steroids and diphenhydramine is typically not effective [6]. Most cases self-resolve without treatment, although most providers opt for prompt supportive treatment with hydration and steroids considering the low risks. One reported case described a patient with a known history of iodide mumps who underwent 3 percutaneous coronary interventions over the course of 6 months, who exhibited recurrent sialadenitis—with time of onset and duration essentially unchanged after each of the procedure—despite premedications [15]. This case thus demonstrates potential risks of repeated exposure to contrast. Interestingly, of the contrast-induced sialadenitis cases reported in the literature, none suffered a life-threatening event such as airway obstruction, indicating that the concern for airway compromise as a complication of sialadenitis may be overestimated.

In summary, iodide mumps may present unilaterally and hyperacutely during arterial angiograms. Unnecessary diagnostic evaluations may be avoided with prompt recognition,

especially as the use of iodine-based imaging and interventional techniques is more widespread.

REFERENCES

- [1] Smith EE, Saver JL, Cox M, Liang L, Matsouaka RA, Xian Y, et al. Increase in endovascular therapy in Get With The Guidelines—Stroke after the publication of pivotal trials. *Circulation* 2017; CIRCULATIONAHA.117.031097. Originally published October 5, 2017. doi:10.1161/CIRCULATIONAHA.117.031097.
- [2] Miller J, Sussman RS. Iodine mumps after intravenous urography. *N Engl J Med* 1956;255:433–4. doi:10.1056/NEJM195608302550907.
- [3] Jacquet G. Deep space infections of the head and neck. In: Desai S, Putman SB, editors. *Infectious diseases emergencies*. New York (NY): Oxford University Press; 2016.
- [4] Zhang G, Li Y, Zhang R, Yingying G, Zhulin M, Huqing W, et al. Acute submandibular swelling complicating arteriography with iodide contrast: a case report and literature review. *Medicine (Baltimore)* 2015;94(33):e1380. doi:10.1097/MD.0000000000001380. 2005.
- [5] Capoccia L, Sbarigia E, Speziale F. Monolateral sialadenitis following iodinated contrast media administration for carotid artery stenting. *Vascular* 2010;18(1):34–6. doi:10.2310/6670.2009.00050.
- [6] Gilgen-Anner Y, Heim M, Ledermann HP, Bircher AJ. Iodide mumps after contrast media imaging: a rare adverse effect to iodine. *Ann Allergy Asthma Immunol* 2007;99(1):93–8. doi:10.1016/S1081-1206(10)60628-X.
- [7] Portulano C, Paroder-Belenitsky M, Carrasco N. The Na⁺/I⁻ symporter (NIS): mechanism and medical impact. *Endocr Rev* 2014;35(1):106–49. doi:10.1210/er.2012-1036.
- [8] Christensen J. Iodide mumps after intravascular administration of a nonionic contrast medium. Case report and review of literature. *Acta Radiol* 1995;36(1):82–4. doi:10.1177/028418519503600115.
- [9] Kalaria VG, Porsche R, Ong LS. Iodide mumps: acute sialadenitis after contrast administration for angioplasty. *Circulation* 2001;104(19):2384. doi:10.1161/hc4401.097422.
- [10] Fifi JT, Meyers PM, Lavine SD, Cox V, Silverberg L, Mangla S, et al. Complications of modern diagnostic cerebral angiography in an academic medical center. *J Vasc Interv Radiol* 2009;20(4):442–7. doi:10.1016/j.jvir.2009.01.012.
- [11] Cremonesi A, Setacci C, Manetti R, de Donato G, Setacci F, Balestra G, et al. Carotid angioplasty and stenting: lesion related treatment strategies. *EuroIntervention* 2005;1(3):295–8.
- [12] Rosado Ingelmo A, Doña Diaz I, Cabañas Moreno R, Moya Quesada MC, García-Avilés C, García Nuñez I, et al. Clinical practice guidelines for diagnosis and management of hypersensitivity reactions to contrast media. *J Investig Allergol Clin Immunol* 2016;26(3):144–55. doi:10.18176/jiaci.0058.
- [13] Bialek EJ, Jakubowski W, Zajkowski P, Szopinski KT, Osmolski A. US of the major salivary glands: anatomy and spatial relationships, pathologic conditions, and pitfalls. *Radiographics* 2006;26(3):745–63. doi:10.1148/rg.263055024.
- [14] Fisher RG, Bryce TG, editors. *Mouth and salivary gland syndromes*. In: *Moffet's pediatric infectious diseases: a problem-oriented approach*. 4th ed. Philadelphia (PA): Lippincott Williams; 2005.
- [15] Egan M, Maglione PJ. Multiple reasonably tolerated percutaneous coronary interventions in a patient with iodide mumps. *Ann Allergy Asthma Immunol* 2015;115(3):253–4. doi:10.1016/j.anai.2015.06.020.