

A case of bullous pemphigoid induced by torsemide



Paul Wurtz, BS,^a Robert Borucki, MD,^b and Corey Georgesen, MD^b

Key words: autoimmune bullous disease; bullous pemphigoid; drug-induced bullous pemphigoid; drug-associated bullous pemphigoid; drug reaction; torsemide.

INTRODUCTION

Bullous pemphigoid (BP) is a chronic autoimmune blistering skin condition in which antibodies are generated against portions of the hemidesmosomal proteins of the basement membrane. The disease has a typical onset after 60 years of age, with an increasing prevalence as patients get older.^{1,2} The classic presentation of BP consists of a prodromal phase during which nonspecific pruritus is often the only symptom. Urticarial and eczematous plaques can also be seen. The bullous phase follows and is characterized by the development of tense subepidermal vesicles and bullae. Lesions with hemorrhagic crust are often seen because of excoriation and rupture of bullae.^{3,4} Medications can induce BP, and medication-induced BP can occur at any age. New medication exposures should be evaluated when examining patients with acute onset BP.⁵

CASE REPORT

A 37-year-old man with a history of chronic kidney disease secondary to postinfectious glomerulonephritis presented to the dermatology clinic with a rash that had been present for approximately 3 months. The rash consisted of pink urticarial plaques and tense bullae with areas of erosion and hemorrhagic crust on the trunk and all 4 extremities, predominantly on both the forearms and dorsal aspect of the hands (Fig 1). The rash spared the head and neck and did not involve any mucosal surfaces. Of note, this rash developed in the patient 1 month after starting torsemide for his chronic kidney disease. Aside from torsemide, he did not

Abbreviations used:

BP: bullous pemphigoid
DABP: drug-associated bullous pemphigoid

take any medications regularly. He self-discontinued the torsemide approximately 3 weeks before his dermatology appointment because he suspected that the rash might be an adverse reaction to his new medication. He had no prior significant dermatologic history or history of autoimmune disease.

A shave biopsy of an intact bulla was sent for routine hematoxylin and eosin staining and showed a subepidermal blister with eosinophils and neutrophils (Fig 2). A punch biopsy of perilesional skin was sent for direct immunofluorescence and showed positive linear IgG and C3 staining along the basement membrane. Indirect immunofluorescence testing on salt-split skin showed dermal localization of IgG. Antibody testing for BP 180 and 230 was negative. Despite negative antibody testing, the patient was diagnosed with BP on the basis of clinical and histologic findings, as studies have shown antibody testing to be negative in roughly 10% of cases.¹

The patient was instructed to remain off torsemide and was started on clobetasol 0.05% ointment twice a day in addition to hydroxyzine. At a 4-week follow-up visit, the patient's skin lesions had improved significantly, and he noted a drastic improvement in his itch. Given the similar molecular structure to furosemide, both torsemide and furosemide were added to the patient's allergy list.

From the Department of Dermatology, College of Medicine, University of Nebraska Medical Center, Omaha, Nebraska^a; and Department of Dermatology, University of Nebraska Medical Center, Omaha, Nebraska.^b

Funding sources: None.

IRB approval status: Not applicable.

Correspondence to: Corey Georgesen, MD, Department of Dermatology, University of Nebraska Medical Center, 4014 Leavenworth St, Omaha, NE 68105. E-mail: Corey.georgesen@unmc.edu.

JAAD Case Reports 2022;26:95-7.
2352-5126

© 2022 by the American Academy of Dermatology, Inc. Published by Elsevier, Inc. This is an open access article under the CC BY-NC-ND license (<http://creativecommons.org/licenses/by-nc-nd/4.0/>).

<https://doi.org/10.1016/j.jcdr.2022.06.023>

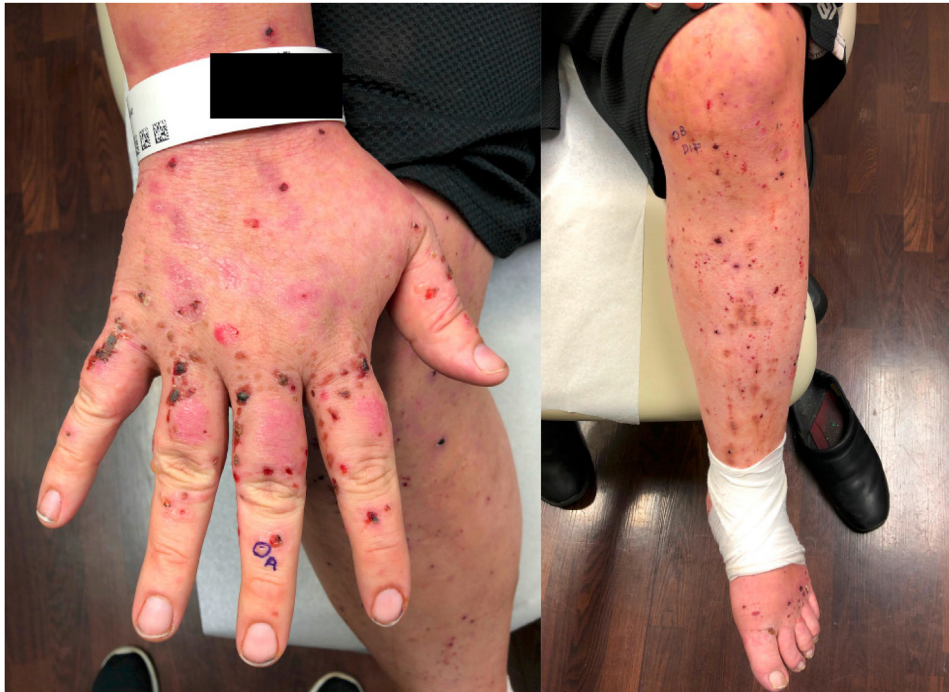

Fig 1. Right hand and left lower extremity of patient.

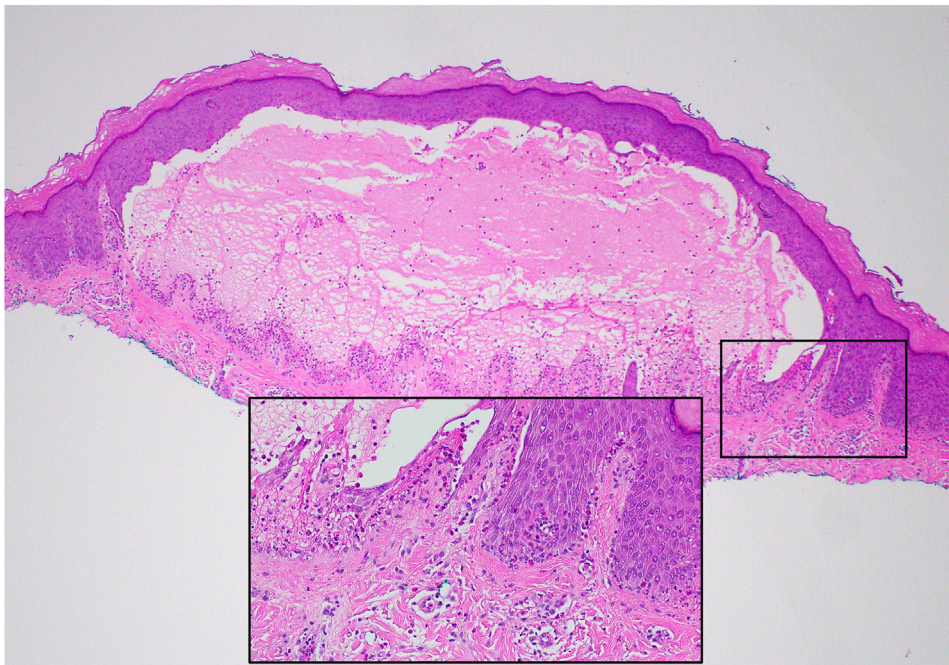


Fig 2. Shave biopsy of the right third digit, stained with hematoxylin and eosin.

DISCUSSION

Drug-associated bullous pemphigoid (DABP) has been reported with several medications and medication classes, including antibiotics, diuretics, non-steroidal anti-inflammatory drugs, angiotensin-converting-enzyme inhibitors, checkpoint inhibitors,

and dipeptidyl peptidase-4 inhibitors.^{5,6} The mechanisms by which these drugs induce BP are not yet fully understood, but several mechanisms have been proposed. The neoantigen theory suggests that these drugs can modify the structure of proteins in the basement membrane of the skin, thereby inducing an

immune response against novel antigens. A similar but distinct mechanism has suggested that certain medications can structurally modify proteins and thereby create novel epitopes that stimulate the immune system.⁵ One of the possible mechanisms by which thiol drugs such as loop diuretics can induce BP is by modifying the structure of the hemidesmosomal proteins themselves, which can uncover novel epitopes and stimulate the immune response.⁷ The loop diuretics furosemide and bumetanide have previously been reported in the literature as causing DABP but torsemide has not.⁸

DABP exhibits the same antibody-antigen pattern as classic BP and presents similarly, consisting of a prodromal phase followed by a bullous phase. However, the presentation often exhibits greater heterogeneity than that of classic BP. Patients with DABP are typically younger and have other hints of hypersensitivity, such as mast cell degranulation toward the offending drug.⁵ The histologic findings of patients with DABP resemble that of classic BP and include subepidermal blisters, eosinophils, and a direct immunofluorescence with linear deposits of IgG and C3 along the epidermal basement membrane.¹ Regardless of etiology, BP typically runs a similar course. The temporal relationship between starting the offending drug and the appearance of blisters can be highly variable, ranging from 2 weeks to several months.⁹ Interestingly, this patient was most prominently affected on the dorsal aspect of the hands and forearms rather than a generalized distribution. It is unclear whether this distribution is more common in DABP or loop diuretic-associated BP because both conditions are so rare.

This patient presented with a rash consistent with BP both clinically and histologically. The case had a score of 6 on the Naranjo Adverse Drug Reaction Probability Scale, indicating a probable adverse drug reaction based on the temporal association of drug administration with the development of the rash.¹⁰ Given the temporal relationship between a new medication and the atypical age of onset in this patient, it is likely that this represents a case of

DABP. Although torsemide has not been associated with BP in the literature, based on its structural similarity to furosemide, it is plausible that this medication could induce BP through similar mechanisms, and should be considered as a potential culprit when history, examination, and histopathology are consistent with DABP.

Conflicts of interest

None disclosed.

REFERENCES

1. Schmidt E, della Torre R, Borradori L. Clinical features and practical diagnosis of bullous pemphigoid. *Immunol Allergy Clin North Am*. 2012;32(2):217-232. <https://doi.org/10.1016/j.jiac.2012.04.002>
2. Wertenteil S, Garg A, Strunk A, Alloo A. Prevalence estimates for pemphigoid in the United States: a sex-adjusted and age-adjusted population analysis. *J Am Acad Dermatol*. 2019; 80(3):655-659. <https://doi.org/10.1016/j.jaad.2018.08.030>
3. Kim M, Borradori L, Murrell DF. Autoimmune blistering diseases in the elderly: clinical presentations and management. *Drugs Aging*. 10 2016;33(10):711-723. <https://doi.org/10.1007/s40266-016-0402-1>
4. Bernard P, Antonicelli F. Bullous pemphigoid: a review of its diagnosis, associations and treatment. *Am J Clin Dermatol*. 2017; 18(4):513-528. <https://doi.org/10.1007/s40257-017-0264-2>
5. Verheyden MJ, Bilgic A, Murrell DF. A systematic review of drug-induced pemphigoid. *Acta Derm Venereol*. 2020;100(15):adv00224. <https://doi.org/10.2340/00015555-3457>
6. Fania L, Salemm A, Provini A, et al. Detection and characterization of IgG, IgE, and IgA autoantibodies in patients with bullous pemphigoid associated with dipeptidyl peptidase-4 inhibitors. *J Am Acad Dermatol*. 2018;78(3):592-595.
7. Lee JJ, Downham TF. Furosemide-induced bullous pemphigoid: case report and review of literature. *J Drugs Dermatol*. 2006;5(6):562-564.
8. Patsatsi A, Vyzantiadis TA, Chrysomallis F, Devliotou-Panagiotidou D, Sotiriadis D. Medication history of a series of patients with bullous pemphigoid from northern Greece - observations and discussion. *Int J Dermatol*. 2009;48(2):132-135. <https://doi.org/10.1111/j.1365-4632.2009.03839.x>
9. Tan CW, Pang Y, Sim B, Thirumoorthy T, Pang SM, Lee HY. The association between drugs and bullous pemphigoid. *Br J Dermatol*. 2017;176(2):549-551. <https://doi.org/10.1111/bjd.15195>
10. Naranjo CA, Busto U, Sellers EM, et al. A method for estimating the probability of adverse drug reactions. *Clin Pharmacol Ther*. 1981;30(2):239-245. <https://doi.org/10.1038/clpt.1981.154>