

Fast Arthroscopic Biceps Tenodesis Without Penetrating Grasper



Giovanni Tiso D'Orazio, M.D., Iñaki Mediavilla Arza, M.D., Ph.D.,
César Hernández Arellano, M.D., and Mikel Aramberri Gutiérrez, M.D., Ph.D.

Abstract: Long head of the biceps pathology is a common cause of shoulder pain and dysfunction. Surgical treatment can be either a tenotomy or a tenodesis. Long-term results may be similar in both surgical techniques; however, the latest systematic reviews indicate that tenodesis offers superior clinical and functional results in young patients and athletes. Considering the favorable results with the biceps tenodesis, we present this arthroscopic tenodesis in which the long head of the biceps is fixed in the bicipital groove with an all-suture anchor passed directly through the tendon, providing a stable and fast fixation without using penetrating grasper.

The long head of the biceps tendon (LHBT) pathology is a frequent cause of shoulder pain. Multiple studies previously identified LHBT injury as a cause of shoulder pain, either in isolation or in conjunction with other shoulder pathologies.¹

LHBT injuries are associated with shoulder pathologies such as rotator cuff injury or anterosuperior labrum injuries. Several authors recommend that they should be treated to improve clinical outcomes after shoulder surgery. Currently, tenotomy and tenodesis are the surgical options in the treatment of the LHBT injuries. However, the patient's age, occupation, hand dominance, recreational activities, and expectations should be considered for the choice of the proper surgical treatment.²

Multiple techniques for performing biceps tenodesis have been previously reported. These procedures have

included soft-tissue fixation and suture, suture anchor fixation, interference screw fixation, or cortical button fixation (unicortical or bicortical).^{3,4}

We present an arthroscopic technique for high suprapectoral tenodesis of LHBT using a fixation with all-suture anchor and a double lasso-loop knot. This is a quick, simple, and reproducible technique that provides a stable fixation of the LHBT.

Surgical Technique (With Video Illustration)

Patient Position

Under general anesthesia with previous interscalene plexus block, the patient is placed in the beach-chair position with arm under 3 kg of traction. Also, an advantage of this technique is that it can be done with patient in lateral decubitus position as well.

The procedure is performed completely arthroscopic in the glenohumeral joint. The standard arthroscopic portals are marked on the skin before starting the surgery (A, posterior standard portal. B, posterolateral portal. C, lateral portal. D, anterolateral portal. E, anterior portal) (Fig 1).

Step 1: Intraarticular Approach

Through the posterior portal (A) with a 4.0-mm 30° arthroscope, the glenohumeral joint is visualized and the arthroscopic diagnosis of the LHBT is checked. With an intra-articular view from the posterior portal, an anterolateral working portal (D) is made. This portal is also known as a sub-bicipital portal and provides optimal access to the biceps tendon through the supraspinatus tendon tear (Video 1).

From Alai Sports Medicine Clinic, Madrid, Spain (G.T.D., M.A.G.); University Hospital of Basurto, Bilbao, Spain (I.M.A.); and Hospital San Vicente, San Vicente, Chile (C.H.A.).

The authors report that they have no conflicts of interest in the authorship and publication of this article. Full ICMJE author disclosure forms are available for this article online, as [supplementary material](#).

Received July 14, 2022; accepted August 27, 2022.

Address correspondence to Giovanni Tiso D'Orazio, M.D., Alai Sports Medicine Clinic, C/ Arturo Soria 342, 28033 Madrid, Spain. E-mail: giovannitiso@gmail.com

© 2022 THE AUTHORS. Published by Elsevier Inc. on behalf of the Arthroscopy Association of North America. This is an open access article under the CC BY-NC-ND license (<http://creativecommons.org/licenses/by-nc-nd/4.0/>).

2212-6287/22935

<https://doi.org/10.1016/j.eats.2022.08.064>

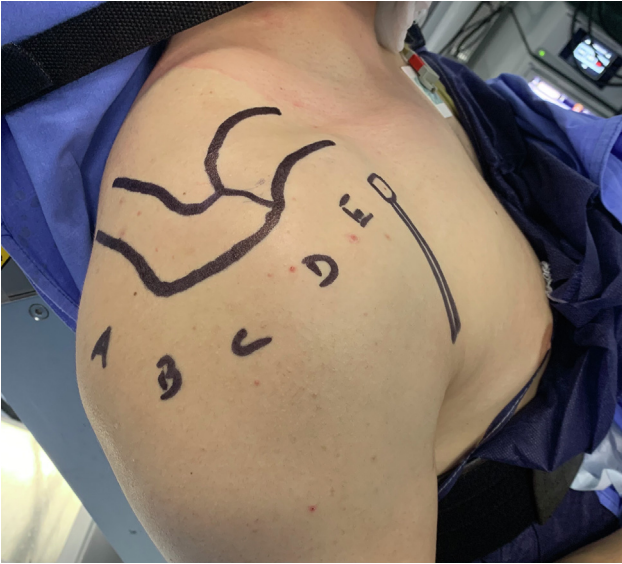

Fig 1. The patient is placed in the beach-chair position. Right shoulder with the standard arthroscopic portals: A, posterior standard portal; B, posterolateral portal; C, lateral portal; D, anterolateral portal; and E, anterior portal.

Step 2: Anchor Placement

Through the working portal (anterolateral portal, D) and viewing the glenohumeral joint from the posterior

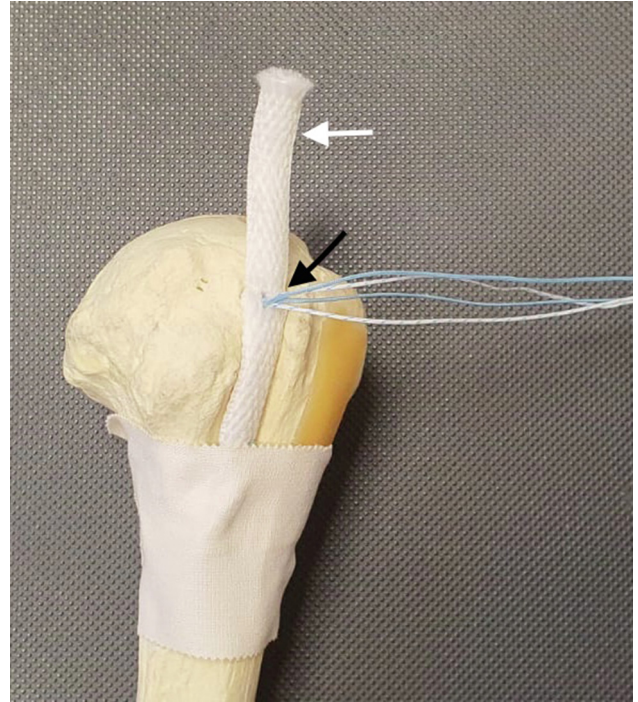


Fig 3. Anatomical model of the humeral head. The Self-Punching All Suture-Anchor completely inserted into the bicipital groove (white arrow), and the sutures stay in the long head of the biceps tendon (black arrow).

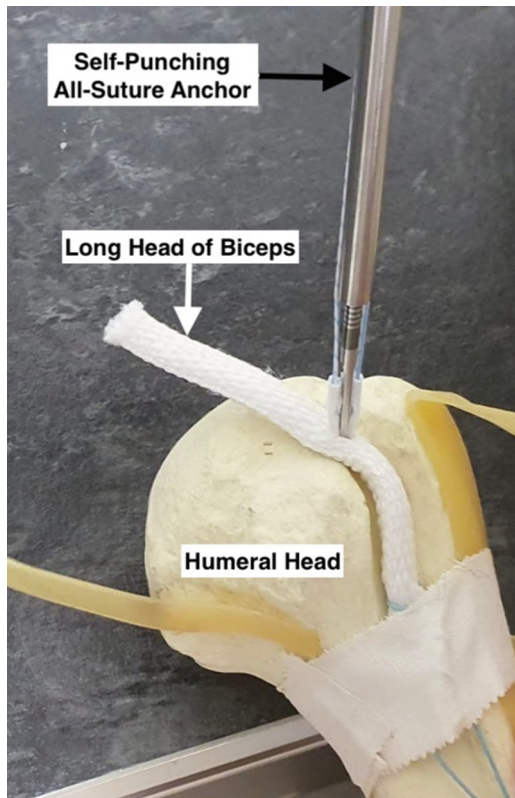


Fig 2. Anatomical model of the humeral head. The Self-Punching All Suture-Anchor (black arrow) is inserted through (penetrating) the long head of the biceps tendon (white arrow).

portal (A), a Self-Punching All Suture-Anchor (ICONIX SPEED, 2.3 mm, Double Loaded; Stryker European Operations, CM Amsterdam, The Netherlands) is introduced in the upper part of the bicipital groove penetrating the biceps tendon (Fig 2). Subsequently, with this step, the sutures will already be passed through the biceps tendon (Fig 3). The optimal anchor position is important to maintain tenodesis in an anatomical tension.

Step 3: Suture Management and Knot-Tying (Without Penetrating Grasper)

To manage the sutures and knot-tying, only a suture grasper (suture manipulator) (Stryker, Mahwah, NJ) is necessary. With a suture grasper inserted through portal D, one of the sutures is retrieved and transported anteriorly to the biceps tendon, and pushed to the space between the anterior glenoid rim and the subscapularis tendon. Next, the suture manipulator is opened and the suture is left there. The suture manipulator is positioned posteriorly to the biceps tendon, advanced medially, and the suture is retrieved laterally with the loop. A lasso loop is made around the whole tendon passing the free limb through the lasso and then it is knotted over the anchor (Fig 4). Notice that the post is the free limb where there is no lasso loop, and that alternating locking half hitches should be made to complete the tenodesis, as the lasso prevents any sliding

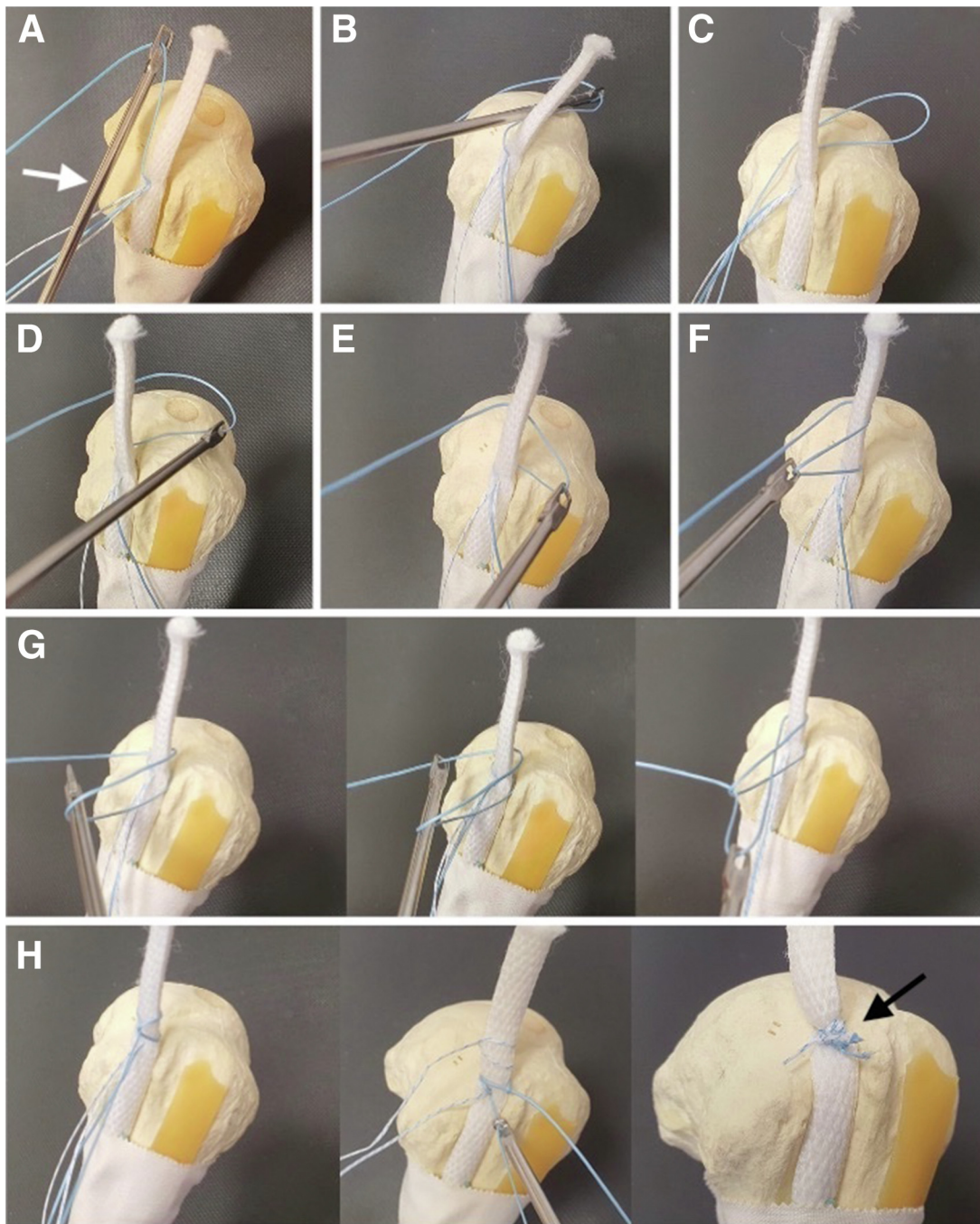


Fig 4. Suture management and knot-tying (step by step) in a left shoulder. A, With the suture manipulator (white arrow), one of the sutures is grabbed and transported anteriorly to the biceps tendon. B, The suture is pushed to the space between the anterior glenoid rim and the subscapularis tendon. C, The suture is left there and the suture manipulator is pulled back. D, the suture manipulator is positioned posteriorly to the biceps tendon. E, The suture loop is lateralized with the suture manipulator. F, With the suture manipulator the loop is retrieved towards anteromedial until the loop is around the biceps. G, The lasso loop is made around the whole tendon passing the free limb through the lasso. H, The lasso loop is knotted after retrieving both of the sutures of the same color, and in this way the tendon is completely fixed to the bicipital groove (black arrow). Then, the same procedure is repeated with the other color sutures.

knot from sliding down into the groove. Subsequently, the same procedure is done with the other color sutures. Then, the tenotomy is performed with a radiofrequency device (90-SMAXEnergy Probe; Stryker,

San Jose, CA). Finally, each lasso loop is knotted after retrieving the same color sutures (the technique is performed without cannulas) and in this way the tendon is completely fixed on the bicipital groove

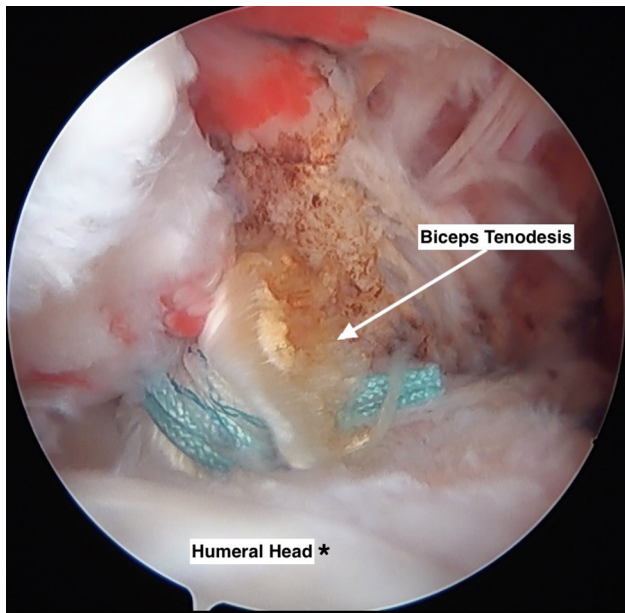


Fig 5. Beach-chair position is shown. Right shoulder: intra-articular view through the posterior portal (A portal) of the biceps tenodesis. The long head of the biceps tendon is completely fixed on the bicipital groove (white arrow).

(Fig 4). Lastly, the fixation of the tenodesis is verified (Fig 5). In some cases, a triple-loaded suture-anchor also can be used, and one of the sutures may be passed through the supraspinatus tendon to repair it.

Postoperative Protocol

The shoulder is placed in a sling for 25 to 30 days and early rehabilitation can be started on the following day after the surgery (passive and light active-assisted exercises). At 4 weeks postoperatively, the patient begins a specific rehabilitation program with a physiotherapist. Return to sports can be done after 3 months.

Discussion

Tenotomy and tenodesis are the 2 procedures described for the treatment of LHB tendinopathy, both procedures have advantages and disadvantages. Tenotomy has the advantages of being less technically demanding and favors early return to the pre-morbid

condition, but the disadvantages of a cosmetic Popeye deformity and its association with muscle cramps must be considered.⁵

Tenodesis provides a better tendon length–tension ratio and thus preserves flexion–supination strength and prevents muscle atrophy. However, it is more technically challenging and has a longer rehabilitation period. Nevertheless, active and young patients can benefit from this technique.^{6,7} The main indications for tenodesis are pain in the long head of the biceps, a positive Speed or Yergason test in active young patients, and magnetic resonance imaging showing subluxed or torn lesions on the biceps tendon or biceps pulley.⁶

Many tenodesis techniques have been proposed. These can be according to the approach (arthroscopic or open procedure), according to the anatomical place of fixation of the tenodesis (suprapectoral or infrapectoral), and according to the device for fixation of the tenodesis (unicortical screws or suture anchors). Some authors have shown that there is no statistically significant difference between the use of interference screws and suture anchors in biceps tenodesis.⁸

Arthroscopic tenodesis has advantages compared with open surgery, since it can reduce the risk of infection, reduce blood loss, and decrease damage to the musculocutaneous nerve.⁹ There is a statistically significant difference in complication rates between open and arthroscopic tenodesis. However, complication rates remain <2% in both techniques.¹⁰

Regarding arthroscopic techniques, some authors showed that a biceps tenodesis using an interference screw could provide greater fixation strength than a biceps tenodesis performed with a double-suture anchor technique,¹¹ but also early failure after biceps tenodesis by use of this technique can be seen.¹² However, current biomechanical reviews describe that biceps tenodesis technique with suture anchor using lasso loop achieve strong and secure tendon fixation, equivalent to interference screws.¹³ For this reason, this technique using a 2 lasso-loop knot configuration offers a stable fixation and is easier because there is no need of using a penetrating grasper.

In conclusion, considering the benefits of arthroscopic tenodesis and the good biomechanical results with all

Table 1. Advantages and Disadvantages and Risks and Limitations

Advantages	Disadvantages
<ul style="list-style-type: none"> • This arthroscopic technique can be done in a beach-chair position or in lateral decubitus. • Surgical time can be reduced because it is a fast arthroscopic technique. • This biceps tenodesis avoids the deformity associated with tenotomy (Popeye sign) 	<ul style="list-style-type: none"> • The all-suture anchor may be used with caution in patients with osteoporosis.
Risk	Limitations
<ul style="list-style-type: none"> • Long head of the biceps tendon damage during Self-Punching All Suture-Anchor placement. 	<ul style="list-style-type: none"> • This arthroscopic technique cannot be performed if the long head of the biceps tendon is retracted or scarred within the bicipital groove.

suture anchor fixation,¹⁴ we believe that our technique is a reproducible, simple, fast, and with many technical advantages (Table 1). In addition, it is an alternative to be used in associated pathologies of the shoulder such as rotator cuff injuries. The clinical results of this technique have been favorable; however, biomechanical studies are required to evaluate the biomechanical properties of this tenodesis technique.

References

1. Vajda M, Szakó L, Hegyi P, et al. Tenodesis yields better functional results than tenotomy in long head of the biceps tendon operations—a systematic review and meta-analysis. *Int Orthop* 2022;46:1037-1051.
2. Angelo RL. Surgical management of proximal long head biceps tendon disorders. *Sports Med Arthrosc* 2018;26:176-180.
3. Lalehzarian SP, Agarwalla A, Liu JN. Management of proximal biceps tendon pathology. *World J Orthop* 2022;13:36-57.
4. Scheibel M, Schröder RJ, Chen J, Bartsch M. Arthroscopic soft tissue tenodesis versus bony fixation anchor tenodesis of the long head of the biceps tendon. *Am J Sports Med* 2011;39:1046-1052.
5. Patel KV, Bravman J, Vidal A, Chrisman A, McCarty E. Biceps tenotomy versus tenodesis. *Clin Sports Med* 2016;35:93-111.
6. Chernchujit B, Agrawal S, Artha A. Arthroscopic biceps tenodesis by bicortical drilling technique. *Arthrosc Tech* 2021;10:e941-e948.
7. Griffin JW, Cvetanovich GL, Kim J, et al. Biceps tenodesis is a viable option for management of proximal biceps injuries in patients less than 25 years of age. *Arthroscopy* 2019;35:1036-1041.
8. Patzer T, Kircher J, Krauspe R. All-arthroscopic supra-pectoral long head of biceps tendon tenodesis with interference screw-like tendon fixation after modified lasso-loop stitch tendon securing. *Arthrosc Tech* 2012;1:e53-e56.
9. Dale WW, McClatchy SG, Field LD. “Triple-fix” arthroscopic biceps tenodesis: Indications and technique. *Arthrosc Tech* 2022;11:e717-e721.
10. Yeung M, Shin JJ, Lesniak BP, Lin A. Complications of arthroscopic versus open biceps tenodesis in the setting of arthroscopic rotator cuff repairs: An analysis of the american board of orthopaedic surgery database. *J Am Acad Orthop Surg* 2020;28:113-120.
11. Jenkins SM, Hwang IM, Del Sol SR, et al. Subpectoral biceps tenodesis using an all-suture anchor. *Arthrosc Tech* 2022;11:e555-e562.
12. Koch BS, Burks RT. Failure of biceps tenodesis with interference screw fixation. *Arthroscopy* 2012;28:735-740.
13. Müller S, Flury R, Zimmermann S, et al. The new LassoLoop360° technique for biomechanically superior tissue grip. *Knee Surg Sport Traumatol Arthrosc* 2019;27:3962-3969.
14. Aramberri-Gutiérrez M, Martínez-Menduiña A, Boyle S, Valencia M. Biomechanical testing of trans-humeral all-suture anchors for rotator cuff repair. *Shoulder Elbow* 2019;11:77-85(1 suppl).