

Ocular adverse events associated with immune checkpoint inhibitors: a novel multidisciplinary management algorithm

Orthi Shahzad, Nicola Thompson, Gerry Clare, Sarah Welsh, Erika Damato and Philippa Corrie 

Ther Adv Med Oncol

2021, Vol. 13: 1–12

DOI: 10.1177/
17588359211992989

© The Author(s), 2021.
Article reuse guidelines:
[sagepub.com/journals-](https://sagepub.com/journals-permissions)
permissions

Abstract: Ocular immune-related adverse events (IrAEs) associated with use of checkpoint inhibitors (CPIs) in cancer therapeutics are relatively rare, occurring in approximately 1% of treated patients. Recognition and early intervention are essential because the degree of tissue damage may be disproportionate to the symptoms, and lack of appropriate treatment risks permanent loss of vision. International guidelines on managing ocular IrAEs provide limited advice only. Importantly, local interventions can be effective and may avoid the need for systemic corticosteroids, thereby permitting the continuation of CPIs. We present a single institution case series of eight affected patients managed by our multidisciplinary team. Consistent with previously published series and case reports, we identified anterior uveitis as the most common ocular IrAE associated with CPIs requiring intervention. Based on our experience, as well as published guidance, we generated a simple algorithm to assist clinicians efficiently manage patients developing ocular symptoms during treatment with CPIs. In addition, we make recommendations for optimising treatment of uveitis and address implications for ongoing CPI therapy.

Keywords: checkpoint inhibitor, corticosteroids, immune-related adverse events, ocular, uveitis

Received: 22 October 2020; revised manuscript accepted: 13 January 2021.

Background

Immunotherapy with checkpoint inhibitors (CPIs) has transformed the treatment of a wide range of malignancies.^{1,2} These drugs work by enabling the host immune system to eliminate malignant cells, recognisable through the expression of neoantigens. The CPIs currently in clinical use are antibodies which target the cytotoxic T-lymphocyte antigen-4 receptor (anti-CTLA-4), the programmed death-1 receptor (anti-PD-1) and its ligand (anti-PD-L1). The CTLA-4 receptor downregulates T-cell activation, whereas the PD-1 receptor inhibits T-cell proliferation, cytokine release, and cytotoxicity. Blocking their function can enhance T-cell response and allow immune-mediated tumour killing.

CPIs generate side effects termed immune-related adverse events (IrAEs), which stem from their

mechanism of action, being predominantly auto-immune in nature and having the potential to affect any body organ. IrAEs range from being mild to life-threatening, or life-changing in some instances.³ Since their first introduction into clinical practice in 2011 as treatment for metastatic melanoma, the use of anti-CTLA-4 and anti-PD-L1 antibodies has expanded to include multiple cancer types including lung and urological cancers as well as lymphomas, with new treatment indications being added frequently. Their increasing use has resulted in greater awareness of both common and rarely seen IrAEs, ranging from mild presentations to severe reactions requiring prompt intervention.⁴

Optimal management of IrAEs is still in its infancy, with limited evidence to inform international guidelines which have been generated to

Correspondence to:
Philippa Corrie
Department of Oncology,
Cambridge University
Hospitals NHS Foundation
Trust (Addenbrooke's
Hospital), Hills Road,
Cambridge CB2 0QQ, UK
[pippa.corrie@](mailto:pippa.corrie@addenbrookes.nhs.uk)
addenbrookes.nhs.uk

Orthi Shahzad
Nicola Thompson
Gerry Clare
Sarah Welsh
Erika Damato
Cambridge University
Hospitals NHS Foundation
Trust, Cambridge, UK

assist clinical practice.^{5,6} The mainstay of treatment for what appear to be inflammatory conditions is immunosuppression with corticosteroids, prompting concerns about their effect on CPI efficacy.⁷ Moreover, the long-term effects on cancer survivors of high dose steroids, sometimes administered for protracted periods of time, have yet to be fully understood. The European Society of Medical Oncology (ESMO) clinical practice guidelines⁵ provide helpful algorithms for managing the more commonly occurring IrAEs, but consensus advice on managing less common IrAEs, such as those affecting the eyes, is also needed to minimise any negative impact of anti-cancer interventions.

Ocular IrAEs occur with an estimated prevalence of 1–3% of all treated patients.^{8,9} While the spectrum of severity is broad, they are highly significant as they can threaten vision. Reports of ocular IrAEs associated with CPIs are limited to small, single-digit case series and individual case reports, which principally report patients experiencing varying degrees of uveitis.^{8,10–13}

Uveitis is a term used to describe inflammation of the uvea, the middle layer of the eye comprising the iris, ciliary body and choroid. It is classified as anterior, intermediate, posterior, or panuveitis, according to the predominant site of inflammation within the eye.¹⁴ Anterior uveitis is characterised by an infiltrate of white blood cells in the anterior chamber of the eye; intermediate uveitis is associated with inflammation in the vitreous gel, resulting in visual blurring, haze and floaters; posterior uveitis is characterised by retinal and/or choroidal inflammation.^{15,16} Symptoms of uveitis include pain, blurred vision and red eye. Involvement of the posterior segment can produce symptoms of floaters, flickering and shimmering lights (photopsias), as well as blind spots.

Anterior uveitis, whether acute or chronic, can often be managed with topical steroid drops alone. Severe uveitis of any subtype may lead to macular oedema, with accumulation of fluid at the most sensitive part of the retina, causing visual distortion and blurring. Severe ocular inflammation requires prompt intervention to avoid permanent loss of vision, and may require periocular or intravitreal steroid injections. More severe cases require systemic steroids, including oral, or pulsed intravenous methylprednisolone. Recalcitrant, chronic inflammatory eye diseases can be managed with secondary non-corticosteroid immunomodulatory

therapeutic agents, including anti-metabolites like mycophenolate mofetil and methotrexate, or biological drugs like adalimumab.¹⁷ Common complications of uveitis and its treatment include cataract, glaucoma and choroidal neovascularisation. While most reports suggest a good response to therapy with complete resolution of inflammation, a minority of patients may develop permanent visual loss.

Other less common ocular IrAEs include ocular myasthenia, optic neuritis and auto-immune retinopathy. Dry eyes are described by up to one in four treated patients, but this is a common condition that is often not reported in clinical trials and is frequently undertreated, even in clinical practice.^{8,9} The risk of ocular IrAEs associated with CPIs was recently quantified using disproportionality analysis; odds ratios for uveitis ranged from 4.6 to 10.8, while that of any ocular IrAE was 2.5 compared with reported events associated with all other drugs.¹⁸

Uncertainties about optimal management of ocular IrAEs persist, such as when to interrupt or discontinue potentially life-saving CPI therapy and whether systemic steroids can influence the efficacy of CPIs. We report our experience of managing ocular IrAEs in a cohort of cancer patients receiving CPIs in a single institution and make management recommendations in a novel treatment algorithm.

Methods

We reviewed the electronic patient records of patients treated with CPIs from January to December 2019, and identified all cases referred to the ophthalmology service. The clinical characteristics, treatment and course of IrAEs over time were recorded. Details of their CPI treatment, other non-ocular IrAEs, and disease response (based on routine radiological imaging and applying RECIST 1.1 response criteria) were also recorded. Survival was measured from the date of first CPI infusion until data cut-off, on 17 March, 2020.

Based on our case series and information contained in published international guidelines,^{5,6} we generated a simple assessment and treatment algorithm for use in routine clinical practice to guide the multidisciplinary team managing ocular symptoms and uveitis; the most common ocular IrAE reported.

This project was registered as a health service evaluation at Cambridge University Hospitals NHS Foundation Trust (CUHFT). The CUHFT research governance lead confirmed that, under the UK Policy Framework for Health and Social Care Research 2017, this project would not be classified or managed as research within the National Health Service and therefore did not require ethical review by a research ethics committee. Written informed consent to publish was obtained from the surviving case study patient.

Results

Patient characteristics

We identified eight patients (three women and five men, aged between 39 and 81 years) who developed ocular IrAEs after starting CPIs (Table 1). Seven patients were treated for advanced cancer; four for metastatic melanoma, two metastatic renal-cell carcinoma and one advanced ovarian carcinoma. One melanoma patient received CPI as an adjuvant therapy, after resection of regional lymph node disease. None had a previous history of uveitis. One patient had a history of glaucoma. Five patients received combination anti-CTLA-4 plus anti-PD-1 antibodies (ipilimumab + nivolumab), two patients received a single agent anti-PD-1 antibody (one pembrolizumab, one nivolumab) and one patient received anti-PD-1 antibody (nivolumab) in combination with a poly-adenosine diphosphate ribose polymerase (PARP) inhibitor (rucaparib). Seven patients had their treatment discontinued early due to treatment-related adverse events; their treatment duration ranged from 3 to 9 weeks. The median number of adverse events contributing to treatment discontinuation was three (range 1–3). One patient completed 2 years of planned anti-PD-1 antibody therapy.

Ocular IrAE characteristics

The median time to the onset of ocular IrAE was 5 weeks from starting CPIs, although one patient developed symptoms after 18 months of treatment (Table 2). In all seven patients who discontinued CPIs early, ocular IrAE contributed to the decision to discontinue therapy. One patient with pre-existing glaucoma experienced ocular IrAE as the only IrAE, occurring after her first dose of pembrolizumab, and this led to treatment discontinuation. Four patients were diagnosed with anterior uveitis, one had intermediate uveitis, one

had melanoma-associated retinopathy (MAR)^{19,20} and one had suspected ocular ischaemic syndrome.²¹ All patients had bilateral eye involvement. There were no hospitalisations associated with ocular IrAEs.

The patient completing 2 years of nivolumab experienced ocular IrAEs both during and after completing CPI treatment. As the symptoms were manageable and no other IrAEs occurred, his planned treatment was not interrupted. He experienced conjunctivitis and left retinal detachment during treatment, both of which were managed successfully. Two years after completing CPIs, he developed bilateral anterior uveitis.

Treatment of ocular IrAEs

All five patients who developed anterior uveitis were treated with topical steroids only. The three other ocular conditions (intermediate uveitis, MAR and suspected ocular ischaemic syndrome) were treated with oral corticosteroids. No patients received intravenous steroids or other immunosuppressive agents to treat their ocular IrAEs. One patient diagnosed with MAR received intravitreal anti-vascular endothelial growth factor injections to treat a juxtafoveal choroidal neovascular membrane, as well as intra-ocular steroid implants to treat chronic photopsia in his only remaining eye.

The median ocular IrAE treatment duration was 11 weeks (range 8 weeks–10 months) with topical steroids and 10 weeks (range 4 weeks–6 months) with oral steroids. Two patients with anterior uveitis had rapid, complete resolution of their symptoms by 8 and 11 weeks. One patient had persistently raised intra-ocular pressures for approximately 6 months. Two patients had a protracted course of inflammatory eye disease, with recurrent episodes lasting 8 and 10 months, respectively. Of two patients re-challenged with CPIs at a later date, (one with ipilimumab, one with ipilimumab + nivolumab), neither had recurrence of ocular IrAEs.

Oncological response to CPIs. Overall, six out of the eight treated patients experienced a partial or near complete response to CPI therapy and seven remain alive and well at data cut-off. One melanoma patient whose adjuvant pembrolizumab treatment was aborted due to uveitis had disease recurrence documented 10 weeks after her first CPI administration, then received ipilimumab,

Table 1. Patient characteristics of patients experiencing ocular IrAEs associated with CPI treatment.

Patient case	CPI regimen	Duration of CPI therapy	Reason for discontinuation	AEs leading to discontinuation	Best response to CPI	Survival outcome
Melanoma-1 Metastatic 50-yr man	Ipilimumab 3 mg/kg + nivolumab 1 mg/kg	9 weeks	Ocular IrAE	Ocular Skin Fatigue	Partial response	Alive 16 months+
Kidney-1 Metastatic 53-yr man	Ipilimumab 1 mg/kg + nivolumab 3 mg/kg	3 weeks	Multiple IrAE	Ocular Skin Liver	Stable disease	Alive 15 months+
Kidney-2 Metastatic 53-yr man	Ipilimumab 1 mg/kg + nivolumab 3 mg/kg	4 weeks	Multiple IrAEs	Ocular Liver Arthritis	Partial response	Alive 16 months+
Ovarian Metastatic 40-yr woman	Nivolumab + rucaparib	8 weeks	Multiple IrAE	Ocular Liver Neutropaenia*	Partial response	Alive 10 months+
Melanoma-2 Resected stage III 74-yr woman	Pembrolizumab 200 mg IV q3w	3 weeks	Ocular IrAE	Ocular	Recurrence	Treated with ipilimumab on recurrence; aborted after 6 weeks due to colitis. Alive with stable disease: 14 months+
Melanoma-3 Metastatic 56-yr man	Ipilimumab 3 mg/kg + nivolumab 1 mg/kg	9 weeks	Multiple IrAEs	Ocular Lung	Partial response	Alive 22 months+
Melanoma-4 Metastatic 40-yr woman	Ipilimumab 1 mg/kg + nivolumab 3 mg/kg	6 weeks	Multiple IrAEs	Ocular Liver	Partial response	Rechallenged with 2 further cycles of ipilimumab + nivolumab on disease progression without significant IrAEs; progressive brain metastases. Died after 11 months
Melanoma-5 Metastatic 81-yr man	Nivolumab 240 mg	2 years	Completed planned treatment	-	Near complete response	Alive 5 years+

*Likely due to PARP inhibitor, not CPI.

AEs, adverse events; CPI, checkpoint inhibitor; IrAEs, immune-related adverse events; yr, year-old; PARP, poly-adenosine diphosphate ribose polymerase.

Table 2. Characteristics of ocular IrAEs experienced and their treatment.

Patient case	Presenting symptoms	Ocular IrAE	Worst CTCAE grade	Time to onset/resolution of ocular IrAE	Worst visual acuity	Visual acuity on resolution	Local treatment	Systemic steroids (starting dose)	Outcome of ocular IrAE
Melanoma 1	Bilateral blurred vision, painful eyes	Anterior uveitis	2	3 weeks/8 weeks	R 6/19 L Normal	R Normal L Normal	Dexamethasone 0.1% drops Cyclopentolate 1% drops	None	Complete resolution
Kidney 1	Bilateral blurred vision, painful eyes, headache	Anterior uveitis High IO pressures	2	5 weeks/11 weeks (uveitis) 6 months (IO pressures)	R 6/9.5 L 6/7.5	R Normal L Normal	Dexamethasone 0.1% drops Timolol Latanprost	None	Complete resolution
Kidney 2	Bilateral painful red eyes, light sensitivity	Anterior uveitis Left disc swelling	2	5 weeks/8 weeks	Normal	Normal	Dexamethasone 0.1% drops Cyclopentolate 1% drops	None	Complete resolution
Ovarian	Bilateral blurred vision. Painful to focus	Anterior uveitis	2	5 weeks/8 months	Normal	Normal	Dexamethasone 0.1% drops Cyclopentolate 1% drops	None	Complete resolution
Melanoma 2	Deterioration in vision	Intermediate uveitis	3	1 week/10 weeks	R 6/9 L Normal	R 6/9 L Normal	None	40 mg prednisolone	Resolved on 10 mg prednisolone; following 2 cycles of ipilimumab, received IV steroids and infliximab for enteritis
Melanoma 3	Flashing lights, visual aura	Melanoma associated retinopathy	4	3 weeks/18 months	R 6/18	R 6/5	Anti-VEGF injections Intra-ocular dexamethasone	50 mg prednisolone	Permanent loss of vision; macular scarring
Melanoma 4	Rapid onset loss of vision in both eyes	Suspected ocular ischaemic syndrome	4	7 weeks/4 weeks	R 6/15 L 6/9	R Normal L Normal	Dexamethasone 0.1% drops Mydrilate 1% drops	40 mg prednisolone	Complete resolution
Melanoma 5	Red, eyes Loss of vision in left eye Blurred vision	Conjunctivitis Left retinal detachment* Anterior uveitis	2 2	18 months 21 months 4 years/10 months	R 6/12 L 6/7.5	R 6/12 L 6/7.5	Dexamethasone 0.1% drops Cyclopentolate 1% drops	None	Quiescent

*Association of retinal detachment as an IrAE could not be confirmed.
CTCAE, common toxicity criteria; IO, intra-ocular; IrEA, immune-related adverse event; IV, intravenous; L, left; R, right; VEGF, vascular endothelial growth factor.

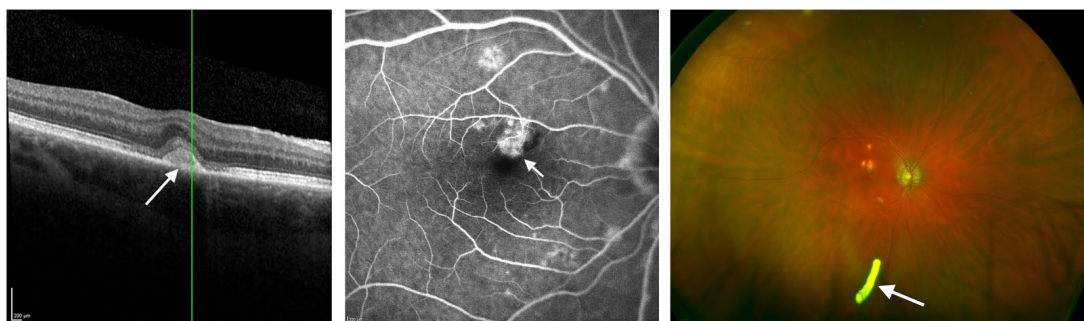


Figure 1. Non-uveitis case study. (a) Optical coherence tomography scan showing a choroidal lesion next to the fovea, possibly representing a neovascular membrane. (b) Fundus fluorescein angiography demonstrating early hyperfluorescence of the juxtafoveal lesion, supporting a diagnosis of choroidal neovascularisation. (c) Pseudocolour image of the fundus showing the dexamethasone 0.7 mg steroid implant.

which was aborted after two cycles due to severe colitis, but her disease has remained stable since that time (15 months at data cut-off). A second melanoma patient who progressed on completing adjuvant pembrolizumab initially responded to ipilimumab + nivolumab, but died of metastatic disease 19 months after her first CPI administration.

Non-uveitis case studies

Case 1: ('Melanoma 3' in Tables 1 and 2). A 56-year-old man received treatment with ipilimumab + nivolumab for metastatic uveal melanoma, having had exenteration of his left eye 4 years previously. Three weeks after his first CPI administration he complained of severe flashing lights in his remaining eye, and he was referred urgently for an ophthalmological assessment.

On slit lamp biomicroscopy, pale lesions were noted in the fundus, and these were presumed to be benign. He continued immunotherapy, but after 9 weeks (three cycles of CPI), he developed moderately severe pneumonitis which was initially treated with 50 mg oral prednisolone daily and CPI therapy was permanently discontinued. The pneumonitis resolved over 12 weeks and he was gradually weaned off steroids. While tapering his steroids, he noticed that his vision was deteriorating and a visual field defect was detected on formal testing.

Optical coherence tomography (OCT) scanning indicated a choroidal lesion next to the fovea, suggesting a possible neovascular membrane (Figure 1a), which could cause visual loss. This suspicion was confirmed by the presence of early leakage during fundus fluorescein angiography (FFA) (Figure 1b). The choroidal neovascular membrane

was treated with a series of intravitreal anti-vascular endothelial growth factor (ranibizumab) injections, until it was deemed to be inactive.

Electrodiagnostic testing subsequently revealed widespread post-photostimulation cone and rod dysfunction, compatible with MAR. His symptoms partially improved on restarting oral steroids (10 mg prednisolone daily), pointing to an inflammatory cause of his visual symptoms. On the basis of this evidence, he was offered short-acting and long-acting intravitreal steroid implants,²² (dexamethasone 0.7 mg and fluocinolone acetonide, respectively, Figure 1c) to avoid chronic side effects of long-term systemic steroids. At the time of data cut-off, the patient remained disease free, with relatively minor persistent visual impairment.

Case 2: ('Melanoma 4' in Tables 1 and 2). A 40-year-old woman received adjuvant pembrolizumab for stage IIIB BRAF wild type melanoma, which was well tolerated, without any IrAEs. After 11 months of treatment, she complained of generalised musculoskeletal pains and fatigue. Restaging scans identified widespread metastases including to liver and bone. She was commenced on ipilimumab + nivolumab. After 6 weeks (post cycle 2), her overall condition deteriorated, with severe fatigue and deterioration in liver function and performance status, although her serum lactate dehydrogenase dropped markedly from 1956 to 498 IU/L during the same time period. Her third cycle of ipilimumab + nivolumab was deferred.

One week later, she presented to the emergency department complaining of sudden onset bilateral loss of vision, worse in the right eye. Visual acuity was 6/15 in the right eye and 6/9 in the left eye, and intraocular pressure was within normal

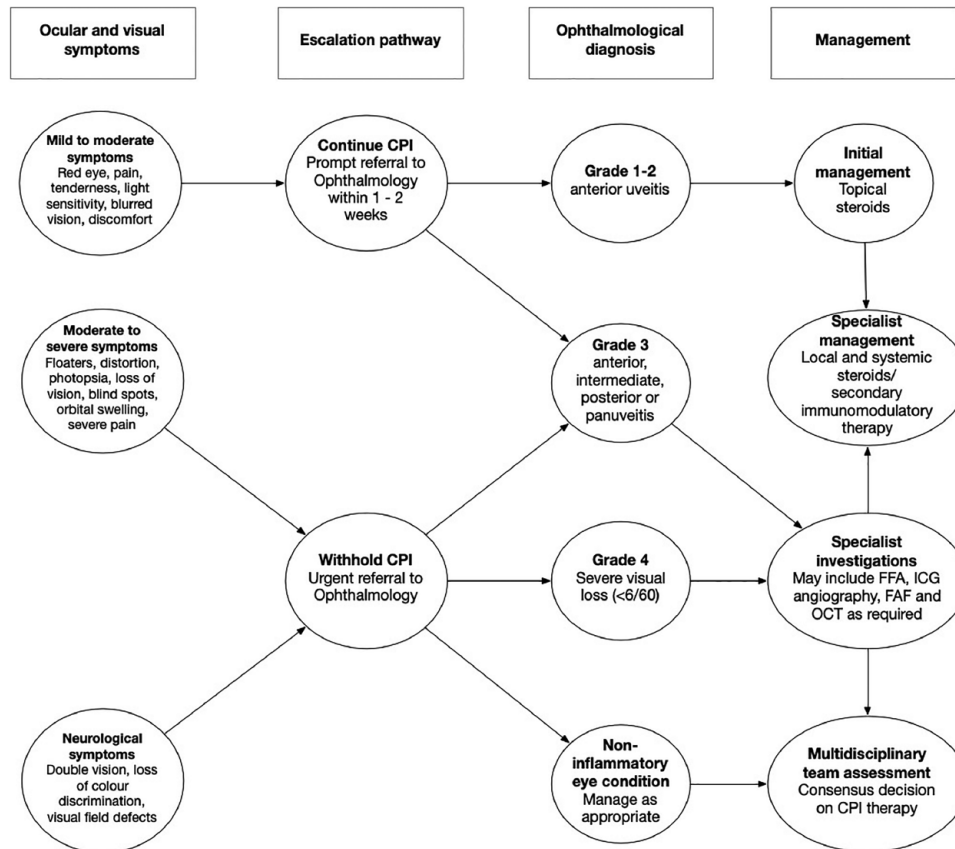


Figure 2. Management algorithm for patients treated with CPIs who present with ocular symptoms. CPI, checkpoint inhibitor; FAF, fundus autofluorescence; FFA, fundus fluorescein angiography; ICG, indocyanine angiography; OCT, optical coherence tomography.

parameters. Iris neovascularisation and a swollen right optic disc were found on slit lamp biomicroscopy and fundoscopy. Brain imaging was requested, and confirmed the absence of metastases. A diagnosis of ocular ischaemic syndrome²¹ was suggested, but after discussion with the oncology specialist, a possible inflammatory aetiology was considered.

The patient was treated with 40mg oral prednisolone daily, 0.1% dexamethasone eye drops and 1% mydrilate drops. She responded well to treatment, and was gradually weaned off steroids, and her vision recovered. Her liver function normalised and her performance status improved sufficiently for a return to normal activities of daily living. Subsequent staging computerised tomography (CT) images indicated a partial response to CPIs. Six months later, despite the patient remaining well and asymptomatic, surveillance imaging identified disease recurrence in previously involved body sites with four new brain metastases. She was re-challenged with ipilimumab + nivolumab. No new IrAEs occurred, but

after the second cycle, she was admitted to hospital with seizures due to haemorrhage into the brain metastases and died 10 weeks later, 11 months after starting CPIs for metastatic disease.

Ocular symptom management algorithm

Based on our own experience, review of the literature and international guidelines, we generated a management algorithm designed for multidisciplinary teams to use in clinical practice (Figure 2).

Patient symptoms and signs are classified according to international common toxicity criteria (CTCAE version 5.0)²³ and management is determined by the severity of the condition. The international CTCAE grades classify the severity of ocular conditions from 1 (mild) to 4 (severe, with sight-threatening consequences). Anterior uveitis is graded in correspondence with the number of cells seen on slit lamp examination of the anterior chamber, as defined by the standardisation of

uveitis nomenclature.¹² Thus, grade 1 uveitis corresponds to a 'trace' of cells (1–5 cells in a 1 mm × 1 mm slit beam), and grade 3 uveitis corresponds to '3+' (26–50 cells per field). Posterior uveitis is graded 3. In addition, a visual acuity of 20/200 (6/60 in European terminology) or less, meeting criteria for blindness in the affected eye, is graded as 4.

The ophthalmological assessments of patients with visual disturbance include visual acuity, colour vision and intraocular pressure measurement. A relative afferent pupillary defect can be tested for by carrying out the swinging flashlight test before dilating drops are instilled into the eyes. Our algorithm includes a pathway for specialist ophthalmic investigations used to diagnose uveitis, which may include FFA and indocyanine angiography (ICG), fundus autofluorescence (FAF) and OCT, depending on the individual case.

In the absence of intermediate or posterior signs, invasive dye-based angiography tests would not normally be indicated, but can be used to exclude retinal vasculitis and leakage (FFA) or undiagnosed choroiditis (ICG) in challenging cases. This can be valuable in both the diagnosis and monitoring of inflammatory eye disease.²⁴ Non-invasive FAF imaging is used to map metabolic activity in the retinal photoreceptor and pigment epithelial layers, and can be useful in identifying inflammatory processes occurring in the outer retina.²⁵ OCT scanning provides high resolution images of the retina in cross-section and has transformed modern ophthalmological practice.

In contrast to recommendations in current international guidelines, we have used clinical evidence to justify avoiding the discontinuation of CPIs as much as possible. The algorithm aims to emphasise the need for close liaison between oncologist and specialist ophthalmologist from the point of recognition to resolution of ocular symptoms, as well as the benefit of a multidisciplinary approach involving good communication between the specialties to balance the need for cancer control alongside patient safety and vision preservation.

Discussion

This report of eight patients experiencing ocular IrAEs associated with CPI treatment is one of the largest series published to date. Anterior uveitis was the most common ocular IrAE that we

identified, occurring in five of our eight cases. The onset of uveitis is reported mainly to occur within 2 months of starting CPIs.^{7,13,26} This was generally the case in our cohort, with a median time to onset of 5 weeks (range 1–7 weeks). The exception was a single patient who developed anterior uveitis 2 years after completing 2 years of nivolumab treatment. It is noteworthy that he had other ocular IrAEs while on treatment that did not lead to CPI discontinuation, while his anterior uveitis was difficult to control. It is well recognised that some IrAEs (including ocular IrAEs)¹³ can occur months and years after stopping CPIs, and this case is a reminder to consider the need for ongoing follow-up, even in patients apparently entering long-term remission after completing treatment.

Ocular IrAEs may occur as the only IrAE, or in association with multiple body system IrAEs. In our series, their occurrence influenced the decision to interrupt CPI treatment in all seven patients who discontinued treatment early: uveitis was the primary reason for discontinuation in two (29%) patients, but contributed to the decision to stop treatment in the remaining five patients, all of whom experienced multiple IrAEs.

A literature review of 33 cases of uveitis secondary to CPIs¹⁰ concluded that one-third of patients experienced anterior uveitis alone, one-third had anterior uveitis plus posterior segment changes including macular oedema, retinal detachment, vitritis or papillitis, and one-third had panuveitis. A very recent larger review of 126 cases of CPI-associated uveitis was broadly consistent, noting that 35% of panuveitis cases occurred as part of a Vogt–Koyanagi–Harada (VKH)-like syndrome.^{27–30} VKH disease is a multisystem disease affecting melanin-containing tissues, which is thought to be autoimmune in origin. The most significant ocular manifestation is bilateral diffuse panuveitis with exudative retinal detachment, often accompanied by a variable spectrum of symptoms involving the skin, nervous system and inner ear.

Recognition of the different presentations of the subtypes of uveitis is clearly important, as this influences whether topical steroids alone can be used for treatment, sparing patients the need for systemic steroids which may adversely affect the outcome of anti-cancer treatment.⁷ As in our own series, most published series describe initial intervention with topical and/or oral corticosteroids.

Although outcomes are generally good, with complete resolution of inflammation in most cases, some cases are recalcitrant, warranting alternative immunomodulatory agents, while peri-ocular or intravitreal steroids²² have been employed as steroid-sparing strategies.

Prompt recognition of ocular and visual symptoms by oncologists and referral to ophthalmology specialists is necessary to ensure rapid investigation, diagnosis and sight-preserving treatment, as well as to inform multidisciplinary team opinion concerning ongoing treatment with CPIs. This can be challenging, because the ocular symptoms experienced may not directly correlate with the severity of inflammation identified.¹⁴ Even so, in most of the case series published to date, the overwhelming majority of patients experiencing ocular irAEs have had their CPIs discontinued,^{12,13} and uncertainty exists whether this line of action may impact overall treatment outcomes.

Perhaps because of its low incidence relative to other IrAEs, the ESMO guidelines⁵ offer very little advice on how to manage ocular IrAEs. The American Society of Clinical Oncology (ASCO) guidelines,⁶ on the other hand, are far more extensive and recommend referral to ophthalmology services for new onset visual symptoms, while they also recognise that symptoms may not always correlate with severity. The guidelines make use of the CTCAE grading system for ocular IrAEs and include management recommendations on whether to withhold, or discontinue, immunotherapy. While these constitute a welcome framework, they may also prove unnecessarily restrictive.

The ASCO guidelines recommend that for grade 1 ocular IrAEs, CPIs can be continued, for grade 2 events CPIs should be withheld and for grades 3 and 4 events they should be permanently discontinued. Ocular IrAEs, while not usually life threatening, may be life changing, so urgent intervention aimed at avoiding permanent loss of eyesight is certainly warranted. However, it is important to note that even severe deterioration in visual acuity can sometimes be reversible. For example, significant visual impairment associated with macular oedema may recover following prompt treatment with oral or intravitreal steroids. In adherence to ASCO guidance, loss of visual acuity may result in an adverse event grading of 3 or 4, which we consider could unnecessarily lead to permanent cessation of immunotherapy.

In some patients who resume CPIs after treatment for IrAEs, relapse with the same symptoms has been observed.^{9,13} We argue that permanent discontinuation of immunotherapy may not always be justified in these circumstances. In our own series, one patient experienced significant bilateral loss of vision associated with an ocular IrAE after two cycles of CPI with ipilimumab + nivolumab, but did not experience further ocular symptoms on retreatment several months later. Moreover, a severe or acute drop in visual acuity may be due to other pathologies unrelated to CPI (for example, incidental retinal detachment, which has a lifetime risk in normal individuals of one in 300).³¹ On the other hand, a patient could have apparently mild visual impairment but severe intra-ocular inflammation.

We recommend early referral to an ophthalmology specialist on recognition of ocular symptoms to diagnose the possible ocular IrAE and accurately grade its severity. We further recommend that both eye treatment and the ongoing use of CPIs are discussed on an individual case basis within a multidisciplinary team of oncologists and ophthalmologists, keeping the option open for retreatment in situations in which the possible benefits outweigh the risks, assuming appropriate patient counselling and support.

Most cases of uveitis associated with CPI, including the majority of our cases, are mild and would be categorised as CTCAE grade 2. These cases do not require cessation of CPI and neither should they require systemic steroids, in general. The outcomes from topical treatment are mainly good, with either a limited course, or sometimes ongoing topical steroids. If systemic steroids are used, the ASCO guidelines recommend that CPIs are withheld until the patient is either off all steroids or is receiving a daily dose of 10mg oral prednisolone (or equivalent) or less. As far as possible, the aim should be to treat ocular IrAEs with local options in order to avoid systemic steroids and cessation of CPI therapy. Aside from concerns regarding their impact on CPI efficacy, long-term steroid use is associated with many well-known harmful effects.

The goal of avoiding the interruption of CPI therapy is best achieved by taking a multidisciplinary approach, with close liaison between ophthalmology and oncology teams, remembering that patients may have a high degree of anxiety about stopping potentially life-saving anti-cancer

therapy. In our cohort, five patients stopped CPIs due to ocular IrAEs, despite being categorised as grade 2, which does not necessarily mandate permanent discontinuation. Three of these patients were treated solely with topical steroids, which suggests a low threat to vision, and which would not normally interfere with CPIs. In cases where topical steroids are not sufficient, intravitreal or periocular steroids should be considered to enable patients to remain on CPIs.

It is possible that patients diagnosed with melanoma may be at increased risk of developing uveitis due to the presence of melanin in the retinal pigment epithelium. An immune-mediated response to melanin-producing cells in the eye may occur both in patients on treatment and in those who develop an immunological reaction to their cancer independent of treatment. In our series, MAR was the most likely diagnosis in one of two patients reporting ocular toxicities that were not due to uveitis, based on symptoms described and investigations performed. The pathology is thought to be due to shared neuroectodermal lineage of melanocytes and retinal cells. Conversely, uveitis is not unique to patients with a diagnosis of melanoma. Patients at increased risk of uveitis may include those with other immune-related side effects and those predisposed to autoimmune disease or with a significant family history.³²

Four of our patients, of whom two had other IrAEs, responded very well to retreatment with CPIs, highlighting a key unanswered question concerning whether the occurrence of IrAEs can predict a therapeutic response.^{32,33} Several studies have reported increased progression-free and overall survival in patients who experienced IrAEs with CPIs compared to those who did not.^{34,35} To date, it remains unclear whether the development of uveitis or other specific IrAEs is associated with better outcomes from treatment with CPIs,^{34,36} although it is quite plausible that an observed inflammatory response within the eye or elsewhere might reflect an enhanced immune response against cancer. The number of patients in our study is insufficient to answer this question, but further study is warranted and, if proved, this could be reassuring for patients who have previously stopped immunotherapy while being treated for inflammatory side effects.

In conclusion, ocular IrAEs are relatively uncommon IrAEs associated with CPIs, but can be dramatic and may lead to permanent visual loss.

Prompt recognition in oncology clinics and early referral to an ophthalmologist is essential. Patients with confirmed ocular inflammation require close monitoring in the eye clinic and ongoing liaison with their oncologist regarding optimal treatment and the use of corticosteroids. The option of intraocular steroid implants should be considered as an alternative to systemic steroids when IrAEs do not resolve with topical steroids alone, with the potential benefit of being able to continue on CPIs.

In conjunction with our ocular IrAE management algorithm (Figure 2), we propose the following basic steps to follow when seeing immunotherapy patients with ocular symptoms in the clinic:

1. document the symptoms and signs and their severity
2. escalate by referral to an ophthalmologist; consider urgency of referral and the need to interrupt CPI therapy depending on symptom severity
3. obtain an ophthalmological diagnosis
4. take a multidisciplinary approach to managing the ocular symptoms and the need or otherwise to restart CPIs, based on risk/benefit considerations.

Acknowledgements

The authors would like to thank the patients and their families for allowing us to share their case studies. Thanks also to the CUHFT research governance and audit teams for their assistance in the conduct of this study.

Conflict of interest

The authors declare that there is no conflict of interest.

Funding

The authors received no financial support for the research, authorship, and/or publication of this article.

ORCID iD

Philippa Corrie  <https://orcid.org/0000-0003-4875-7021>

References

1. Buchbinder EI and Hodi FS. Melanoma in 2015: immune-checkpoint blockade – durable cancer control. *Nat Rev Clin Oncol* 2016; 13: 77–78.

2. Farkona S, Diamandis EP and Blasutig IM. Cancer immunotherapy: the beginning of the end of cancer? *BMC Med* 2016; 14: 73.
3. Martins F, Sofiya L, Sykietis GP, *et al.* Adverse effects of immune-checkpoint inhibitors: epidemiology, management and surveillance. *Nat Rev Clin Oncol* 2019; 16: 563–580.
4. Puzanov I, Diab A, Abdallah K, *et al.* Managing toxicities associated with immune checkpoint inhibitors: consensus recommendations from the Society for Immunotherapy of Cancer (SITC) toxicity management working group. *J Immunother Cancer* 2017; 5: 95.
5. Haanen JBAG, Carbonnel F, Robert C, *et al.* Management of toxicities from immunotherapy: ESMO clinical practice guidelines for diagnosis, treatment and follow-up. *Ann Oncol* 2018; 29: iv264–iv266.
6. Brahmer JR, Lacchetti C, Schneider BJ, *et al.* Management of immune-related adverse events in patients treated with immune checkpoint inhibitor therapy: American Society of Clinical Oncology clinical practice guideline. *J Clin Oncol* 2018; 36: 1714–1768.
7. Fucà G, Galli G, Poggi M, *et al.* Modulation of peripheral blood immune cells by early use of steroids and its association with clinical outcomes in patients with metastatic non-small cell lung cancer treated with immune checkpoint inhibitors. *ESMO Open* 2019; 4: e000457.
8. Dalvin LA, Shields CL, Orloff M, *et al.* Checkpoint inhibitor immune therapy: systemic indications and ophthalmic side effects. *Retina* 2018; 38: 1063–1078.
9. Fortes BH, Liou H and Dalvin LA. Ophthalmic adverse effects of immune checkpoint inhibitors: the Mayo clinic experience. *Br J Ophthalmol*. Epub ahead of print 23 August 2020. DOI: 10.1136/bjophthalmol-2020-316970
10. Conrady CD, Larochelle M, Pecan P, *et al.* Checkpoint inhibitor-induced uveitis: a case series. *Graefes Arch Clin Exp Ophthalmol* 2018; 256: 187–191.
11. Parikh RA, Chaon BC and Berkenstock MK. Ocular complications of checkpoint inhibitors and immunotherapeutic agents: a case series. *Ocul Immunol Inflamm*. Epub ahead of print 9 July 2020. DOI: 10.1080/09273948.2020.1766082
12. Venkat AG, Arepalli S, Sharma S, *et al.* Local therapy for cancer therapy-associated uveitis: a case series and review of the literature. *Br J Ophthalmol* 2020; 104: 703–711.
13. Dow ER, Yung M and Tsui E. Immune checkpoint inhibitor-associated uveitis: review of treatments and outcomes. *Ocul Immunol Inflamm*. Epub ahead of print 20 August 2020. DOI: 10.1080/09273948.2020.1781902
14. Jabs DA, Nussenblatt RB, Rosenbaum JT, *et al.* Standardization of uveitis nomenclature for reporting clinical data. Results of the first international workshop. *Am J Ophthalmol* 2005; 140: 509–516.
15. Gueudry J and Muraine M. Anterior uveitis. *J Fr Ophthalmol* 2018; 41: e11–e21.
16. Uy HS, Yu-Keh E and Chan PS. Posterior uveitis. *Dev Ophthalmol* 2016; 55: 163–166.
17. Dick AD, Rosenbaum JT, Al-Dhibi HA, *et al.* Guidance on noncorticosteroid systemic immunomodulatory therapy in noninfectious uveitis: Fundamentals of Care for Uveitis (FOCUS) initiative. *Ophthalmology* 2018; 125: 757–773.
18. Bitton K, Michot JM, Barreau E, *et al.* Prevalence and clinical patterns of ocular complications associated with anti-PD-1/PD-L1 anticancer immunotherapy. *Am J Ophthalmol* 2019; 202: 109–117.
19. Lu Y, Jia L, He S, *et al.* Melanoma-associated retinopathy: a paraneoplastic autoimmune complication. *Arch Ophthalmol* 2009; 127: 1572–1580.
20. Elsheikh S, Gurney SP and Burdon MA. Melanoma-associated retinopathy. *Clin Exp Dermatol* 2020; 45: 147–152.
21. Luo J, Yan Z, Jia Y, *et al.* Clinical analysis of 42 cases of ocular ischemic syndrome. *J Ophthalmol* 2018; 2018: 2606147.
22. Hasanreisoglu M, Özdemir HB, Özkan K, *et al.* Intravitreal dexamethasone implant in the treatment of non-infectious uveitis. *Turk J Ophthalmol* 2019; 49: 250–257.
23. National Cancer Institute. *Common Terminology Criteria for Adverse Events (CTCAE)*. Washington DC: US Department of Health and Human Services, 2017.
24. Agrawal RV, Biswas J and Gunasekaran D. Indocyanine green angiography in posterior uveitis. *Indian J Ophthalmol* 2013; 61: 148–159.
25. Sparrow JR, Bindewald-Wittich A, Spaide RF, *et al.* Fundus autofluorescence imaging. *Prog Retinal Eye Res*. Epub ahead of print 3 August 2020. DOI: 10.1016/j.preteyeres.2020.100893
26. Sun MM, Levinson RD, Filipowicz A, *et al.* Uveitis in patients treated with CTLA-4 and PD-1 checkpoint blockade inhibition. *Ocul Immunol Inflamm*. Epub ahead of print 1 March 2019. DOI: 10.1080/09273948.2019.1577978

27. Obata S, Saishin Y, Teramura K, *et al.* Vogt–Koyanagi–Harada disease-like uveitis during nivolumab (anti-PD-1 antibody) treatment for metastatic cutaneous malignant melanoma. *Case Rep Ophthalmol* 2019; 10: 67–74.
28. Gambichler T, Seifert C, Lehmann M, *et al.* Concurrent Vogt–Koyanagi–Harada disease and impressive response to immune checkpoint blockade in metastatic melanoma. *Immunotherapy* 2020; 12: 439–444.
29. Kikuchi R, Kawagoe T and Hotta K. Vogt–Koyanagi–Harada disease-like uveitis following nivolumab administration treated with steroid pulse therapy: a case report. *BMC Ophthalmol* 2020; 20: 252.
30. Yoshida S, Shiraishi K, Mito T, *et al.* Vogt–Koyanagi–Harada-like syndrome induced by immune checkpoint inhibitors in a patient with melanoma. *Clin Exp Dermatol*. Epub ahead of print 5 July 2020. DOI: 10.1111/ced.14282
31. Fraser S and Steel D. Retinal detachment. *BMJ Clin Evid* 2014; 2014: 0710.
32. Young A, Quandt Z and Bluestone JA. The balancing act between cancer immunity and autoimmunity in response to immunotherapy. *Cancer Immunol Res* 2018; 6: 1445–1452.
33. Eggermont AMM, Kicinski M, Blank CU, *et al.* Association between immune-related adverse events and recurrence-free survival among patients with stage III melanoma randomized to receive pembrolizumab or placebo. *JAMA Oncol* 2020; 6: 519–527.
34. Haratani K, Hayashi H, Chiba Y, *et al.* Association of immune-related adverse events with nivolumab efficacy in non-small-cell lung cancer. *JAMA Oncol* 2018; 4: 374–378.
35. Das S and Johnson DB. Immune-related adverse events and anti-tumor efficacy of immune checkpoint inhibitors. *J Immunother Cancer* 2019; 7: 306.
36. Horvat TZ, Adel NG, Dang TO, *et al.* Immune-related adverse events, need for systemic immunosuppression, and effects on survival and time to treatment failure in patients with melanoma treated with ipilimumab at Memorial Sloan Kettering cancer center. *J Clin Oncol* 2015; 33: 3193–3198.

Visit SAGE journals online
journals.sagepub.com/
home/tam

 SAGE journals