

Placental Histology After Minor Trauma in Pregnancy: A Pilot Study

BJ van der Knoop¹, JP van der Voorn², PGJ Nikkels³,
IA Zonnenberg⁴, MM van Weissenbruch⁴, RJ Vermeulen⁵, and
JIP de Vries¹

Pediatric and Developmental Pathology
2019, Vol. 22(3) 221–228

© 2018, Society for Pediatric Pathology



All rights reserved.

Article reuse guidelines:

sagepub.com/journals-permissions

DOI: 10.1177/1093526618799292

journals.sagepub.com/home/pdp



Abstract

Objective: Trauma in pregnancy may cause placental abruption. Consequences of moderate placental injury on neurodevelopment are unknown. The aim was to evaluate placental histology after maternal trauma.

Methods: A prospective study was conducted at 2 tertiary medical centers in the Netherlands. Placentas from women exposed to maternal trauma ≥ 20 weeks' gestational age were histologically examined. Neurological follow-up of the infants was performed at 1 year of age by means of Alberta Infant Motor Scale. Histological findings were compared to placentas from pregnancies without trauma.

Principal Results: Thirteen placentas were investigated in the trauma group. The control group consisted of 15 placentas. Placental pathology was seen more often in the trauma cases (11 of the 13) than in the controls (6 of the 15), $P=.024$. Neurological follow-up was normal.

Conclusions: In this small population, majority of the placentas showed pathology after minor trauma in pregnancy without consequences for neurodevelopment at 1 year.

Keywords

trauma in pregnancy, placenta, placental histology, brain ultrasound, neurodevelopment

Introduction

Trauma in pregnancy occurs in approximately 7% of all pregnant women in industrialized countries.¹ Minor and major trauma have been reported to cause fetal brain damage.² The prevalence of fetal brain injury with consequences for later neurological outcome after maternal trauma, however, is not yet known.

Fetal brain injury after mechanical maternal trauma can be elicited by direct injury to the fetal head or indirectly via (partial) placental abruption² or fetomaternal hemorrhage.³ Fetal death has been reported after complete placental abruption following maternal trauma.⁴

This study focused on the role placental pathology in the origin of neurodevelopmental problems after trauma in pregnancy.

In previous research by Redline⁵ and Wu and Colford,⁶ placental lesions (loss of villous or vascular integrity and/or chorioamnionitis) were reported to be related to abnormalities on brain ultrasound and/or neurodisability in infancy.

Placental pathology (such as chronic hypoxic changes or chorioamnionitis) has also been described in neonates with changes on cranial ultrasound and in children who developed cerebral palsy.^{6,7} Furthermore, the association

¹Department of Obstetrics and Gynaecology, VU University Medical Center, Amsterdam, the Netherlands

²Department of Pathology, VU University Medical Center, Amsterdam, the Netherlands

³Department of Pathology, University Medical Center Utrecht, Utrecht, the Netherlands

⁴Department of Neonatology, VU University Medical Center, Amsterdam, the Netherlands

⁵Department of Child Neurology, VU University Medical Center, Amsterdam, the Netherlands

RJ Vermeulen is now at the Department of Child Neurology, Maastricht University Medical Center, P.O. Box 5800, 6202 AZ Maastricht, the Netherlands.

Corresponding Author:

BJ van der Knoop, Department of Obstetrics and Gynaecology, VU University Medical Center, P.O. Box 7057, 1007 MB Amsterdam, the Netherlands.

Email: b.vanderknoop@vumc.nl

between similar placental pathology and moderate grades of prenatal brain injury has been studied before birth in a population at risk of preterm delivery.⁸ To our knowledge, there are no studies that performed placental histology after (minor) trauma exposure without evidence of placental abruption.

The aim of this study was to examine placental histology and obstetrical and neurological outcomes in pregnancies complicated by maternal trauma in a 3-year period. Histological findings were compared to placentas from pregnancies without trauma.

We hypothesize no differences between the cases and controls in case of minor trauma.

Methods

This is a prospective study, part of the Fetal Brain Imaging (FBI) study.

All consecutive women, with uncomplicated pregnancies (no hypertensive disorders and no other maternal or fetal disorders), seeking health care because of exposure to abdominal or high-energy trauma after 20 weeks' gestational age (GA) at VU University Medical Center, Amsterdam, or University Medical Center Utrecht, Utrecht, the Netherlands, were eligible to participate in the Fetal Brain Imaging Study. In this study, serial fetal and neonatal brain imaging by means of ultrasound and magnetic resonance imaging (MRI) as well as histological examination of the placenta and a neurological follow-up of the infant until 5 years of age were performed. When trauma occurred after 38 weeks' GA, women were not invited to participate, as fetal brain imaging was not expected to be feasible before delivery.

Approval from both local medical ethical committees was obtained. All women who participated gave written informed consent.

Histological findings were compared to those in placentas from women who delivered after an uncomplicated pregnancy between 2009 and 2014, matched for GA and mode of delivery (spontaneous or cesarean section). The secondary use of the coded data from the placental samples did not require informed consent according to Dutch legislation.

Cause of Trauma, Fetomaternal Hemorrhage, and Severity of the Injuries

Causes of trauma were classified as motor vehicle accidents, cycle accidents, falls, and other. Fetomaternal transfusion was tested by means of a Kleihauer–Betke test (<400 μ L: no fetomaternal transfusion). Severity of maternal injuries was assessed with the Injury Severity Score (ISS).⁹ The ISS is an international scoring system to provide an overall score (range, 0–75) of the severity of injuries following trauma. The body is divided into 6 regions

(head, face, chest, abdomen, extremities [including pelvis], and external). Each injury is scored per region according to the Abbreviated Injury Scale (AIS), ranging from 1 (minor injury) to 6 (unsurvivable). In each body region, only the highest AIS score is used. The 3 body regions with the highest AIS are squared and summed to calculate the ISS. For clinical use and in accordance to other studies,^{1,10,11} an ISS of ≥ 9 was considered severe.

Placenta

During delivery, clinical confirmation of placental abruption (hemorrhagic amniotic fluid and placental birth directly after the infant) as diagnosed by the obstetrician was recorded.

All placentas were examined by experienced perinatal pathologists (JPvdV and PGJN), both unaware of the type of trauma, severity of maternal injuries, brain ultrasound findings, or neurological outcome of the infants.

Placentas were macroscopically examined for completeness. The membranes were resected, and a roll of the extraplacental membranes from the rupture edge to the placental margin was made. The umbilical cord was examined for the average diameter, obvious strictures, knots, length, and site of insertion. The coiling index (number of coils/10 cm) was determined, and abnormal coiling was recorded (coiling index > 0.30: hypercoiling and coiling index < 0.07: hypocoiling).¹²

The cord was then resected from the placental disk, and the trimmed placental weight was compared to normal values.¹³ A minimum of 2 cassettes containing full-thickness sections from the center of the normal-appearing placental disk, including the one close to the umbilical cord insertion, were taken for microscopic examination. Furthermore, sections were taken from the extraplacental membranes and from both the placental and fetal ends of the umbilical cord. Additional sections were taken from any macroscopically abnormal area.

The placentas were evaluated for pathological findings consistent with maternal vascular malperfusion, fetal vascular malperfusion, and inflammatory signs according to Redline et al.^{14–16} Assessment was performed according to the Amsterdam Placental Workshop Group Consensus Statement;¹⁷ however, the publication was not yet available at the onset of the study (for details, see Table 1).

The presence of hemosiderin in decidua of basal plate, in placental membranes, or in the placental parenchyma was identified by light microscopy on hematoxylin and eosin-stained sections and confirmed by Prussian blue stain.

Ultrasound

Fetuses underwent biweekly brain ultrasound. Assessment consisted of echogenicities surrounding the ventricles and/or basal ganglia and peri- and intraventricular hemorrhage.⁸

Table 1. Classification of Placental Pathology.**Maternal Vascular Malperfusion¹⁴**Placental hypoplasia *weight < 10 percentile*Infarction *> 5%*Retroplacental hematomas *blood accumulation under the maternal surface with congestion and/or hemorrhage within or compression of the overlying parenchyma*Distal villous hypoplasia *paucity of villi in relation to the surrounding stemvilli in lower two-third and at least 30% of 1 full-thickness parenchymal slide*Accelerated villous maturation *presence of term-appearing villi with increased syncytial knots***Fetal Vascular Malperfusion¹⁵**

Thrombosis of umbilical and/or chorionic plate vessels

Segmental avascular villi

Villous stromal-vascular karyorrhexis

Ascending Intrauterine Infection As proposed by Society for Pediatric Pathology¹⁶

Maternal inflammatory response

Stage—1: *acute (sub)chorionitis*; 2: *acute chorioamnionitis*; 3: *necrotizing chorioamnionitis*Grade—1: *not severe*; 2: *severe*

Fetal inflammatory response

Stage—1: *chorionic vasculitis/umbilical phlebitis*; 2: *umbilical vein involvement and 1 or more umbilical arteries*; 3: *necrotizing funitis*Grade—1: *not severe*; 2: *severe***Diverse**Reactive amniotic epithelium *degenerative changes: vacuolation, heaping up of cells, and dissociation*Intervillous thrombi *localized clot with (layers) of fibrin in intervillous space*

Echogenicity changes had to be present in at least 2 directions (coronal, sagittal, and/or axial) in order to be graded. In case echogenicity changes were seen in 1 plane only or in case the quality of the images was insufficient, the ultrasound was considered inconclusive.

Obstetric Outcome

GA, mode of delivery (spontaneous, vacuum extraction, and cesarean section), birth weight, and Apgar scores (<7 abnormal) at 1 and 5 minutes were recorded.

Neurological Outcome

The infants were seen for neurological examination according to Prechtl¹⁸ at term-equivalent age and Touwen¹⁹ and Alberta Infant Motor Scale²⁰ at 1 year.

Data Analysis

To compare placental pathological findings between the trauma and control group, the Fisher's exact test was used. $P < .05$ was considered statistically significant. Statistical analysis was performed using IBM SPSS Statistics version 20.

Results

Seventy-five women were invited to participate in the Fetal Brain Imaging study between October 2011 and July 2014. Figure 1 depicts the number of women who accepted and declined participation. Almost half of the women, who were invited, declined to participate mainly due to anxiousness over unwanted test results or experiencing participation in scientific research too burdensome. Therefore, placentas of 13 women were available for pathological examination. GA at the time of trauma, type of trauma, ISS score, and Kleihauer–Betke outcome per case are shown in Table 2. Injuries were minor in all but 1 case, and 9 of the 13 women experienced contractions and/or abdominal pain. The 3 cases with increased Kleihauer–Betke test results were clinically stable, and pregnancy was not terminated. Controls: 15 placentas matched the criteria for the control group.

Placenta

Characteristics at delivery of the trauma and control group are shown in Table 3. The obstetrician encountered a placental abruption in 1 of the 13 cases: A large organized blood clot followed directly after the placental birth in case 8. Macroscopic and histological findings in the trauma and control group at pathological examination are depicted in Table 4. The presence of hemosiderin was confirmed in 7 of the 13 cases and none of the controls. All 7 cases with hemosiderin depositions had intervillous thrombi and/or retroplacental hematomas. In 6 of the 7 cases, hemosiderin depositions were present in decidua and/or membranes; in 1 of the 7 cases, the hemosiderin deposition was present in an intervillous thrombus alone.

Three placental weights were below the 10th percentile: 2 cases and 1 control. The histology in case 6 was chorioamnionitis st2/gr1 with st1/gr1 fetal response and reactive amniothelium, and in case 13, 2 intervillous thrombi, thrombus in fetal chorionic plate vessel and hypercoiling; in the control, the histology showed a small thrombus in a chorionic plate vessel.

Main pathological findings were chorioamnionitis, retroplacental hematomas, and intervillous thrombi. In 1 of the 6 cases and in 1 control with reactive amniothelium, meconium-stained amniotic fluid was reported.

Ultrasound

Fetal ultrasound examinations were performed in 10 cases. In 4 cases, the assessment was inconclusive. Due to the limited number of conclusive ultrasound examinations, they were excluded from the analyses.

Obstetric, Neonatal, and Neurological Outcomes

Two infants had Apgar scores <7: the infant of case 1 (whose delivery was complicated by shoulder dystocia)

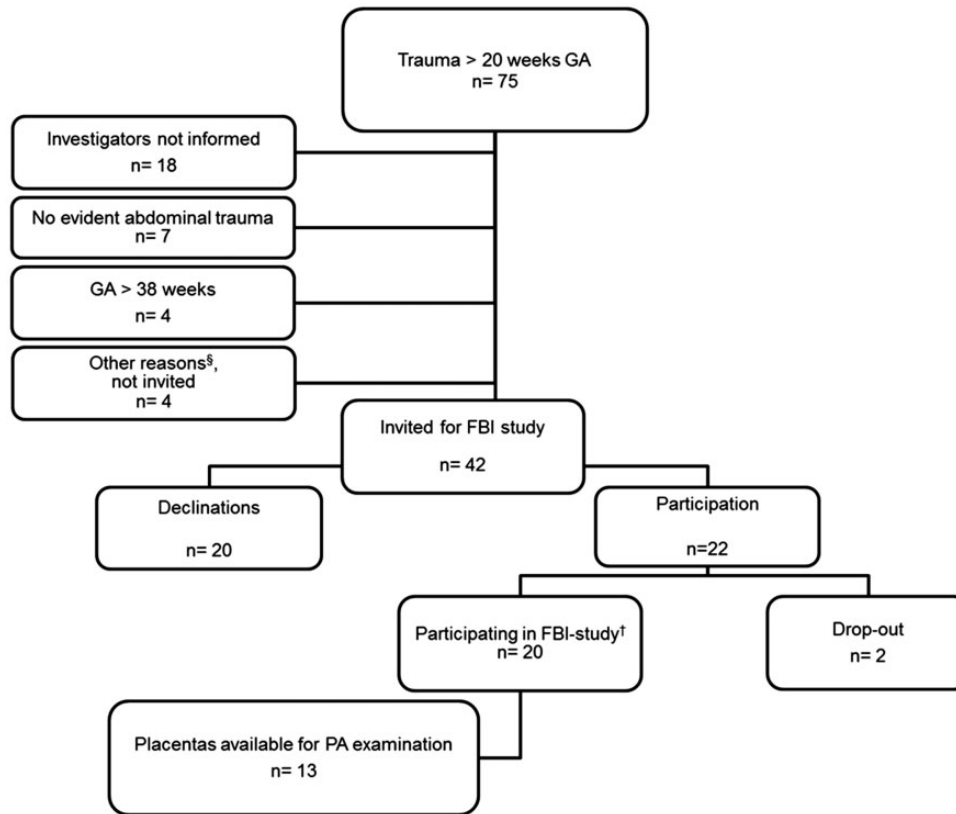


Figure 1. Patient inclusion characteristics. §Other reasons: one woman was admitted for psychiatric treatment and one other woman was admitted to the cardiac care unit, both not in a condition to be invited for scientific research. The third woman was a foreign woman who continued her way home after the admission. The fourth woman could not be invited because of practical difficulties. †FBI-study: Fetal brain imaging in fetuses at high risk of acquired anomalies. The study aims to investigate the value of advanced brain sonography and magnetic resonance imaging in a high-risk population for fetal brain damage (such as trauma in pregnancy, cytomegalovirus/toxoplasmosis infection, early fetal growth restriction).

FBI: Fetal Brain Imaging; GA: gestational age; PA: pathological.

was born with Apgar score 5 at 1 minute, recovering to 8 at 5 minutes and 10 at 10 minutes. The infant of case 8 was born prematurely with Apgar scores of 7, 6, and 7 at 1, 5, and 10 minutes respectively. She was noted to have hepatomegaly, hematomas, and epistaxis as well as respiratory problems for which she was admitted and treated with CPAP. Cases 7 and 9 withdrew from further study participation and therefore did not attend the follow-up examinations. Case 7 did give permission to obtain developmental information from the infants' medical file in our hospital. Cases 5 and 13 were not able to attend one of the neurological follow-up examinations but agreed on retrieving information on their infants' motor and neurological development from the well-baby clinic. In the well-baby clinic, motor development is monitored according to the "van Wiechen" schedule (a Dutch developmental milestone scheme for the assessment of the motor, language, and social development of the infant).

Neurodevelopment at term-equivalent age was normal in 10 of the 11 cases (case 11 suspect) and normal in 11 of the 11 cases at 1 year. The infant of case 7 visited a pediatric neurologist at 2 years of age, and a motor developmental delay was diagnosed. Additional testing (MRI and DNA microarray) did not reveal any abnormalities.

Discussion

To our knowledge, this is the first prospective study to assess histological pathology of the placenta after maternal trauma in pregnancy. We found placental pathology in 85% (11 of the 13) of our trauma population, with normal neurodevelopment at 1 year of age.

The prevalence of placental pathology in this prospective trauma study was higher than in the control group and consisted mainly of retroplacental hematomas, intervillous thrombi, chorioamnionitis, and reactive amniothelium. From the individual items, intervillous

Table 2. Characteristics at Trauma Admission and Placental Pathology per Case.

Case	GA at Trauma	Cause of Trauma	ISS	Kleihauer Betke	GA and Mode of Delivery	Placental Histology
1	33 + 4	Fall from stairs	0	25 269	39 + 2 S	- Chorionitis st1/gr1 - Hypercoiling
2	22 + 6	MVA head-tail, 50 km/h, driving seat, seat belt just removed because of inconvenience	5	421	40 + 5 S	- Chorionitis st1/gr1 with fetal response st1/gr1 - Intervillous thrombus - Thrombus in fetal chorionic plate vessel
3	29 + 0	CA thrown over handlebars, handlebars in abdomen	0	nl	37 + 3 S	- No abnormalities
4	25 + 5	CA thrown over handlebars, handlebars in abdomen	1	nl	40 + 5 S	- No abnormalities
5	26 + 0	Other ^b Kicking in abdomen, back, and extremities	9	nl	41 + 0 S	- Chorioamnionitis st2/gr1 - Intervillous thrombus, 5 mm - Retroplacental hematoma, 5 mm and 7 mm - Reactive amniothelium
6	24 + 1	Fall on abdomen, tripping	0	57 886 ^a	39 + 1 S	- Chorioamnionitis st2/gr1 with st1/gr1 fetal response - Reactive amniothelium
7	37 + 2	MVA Tail-head at traffic light, 70 km/h, driving seat, seat belts on	0	nl	38 + 4 pC	- Retroplacental hematoma, 20 mm
8	20 + 0	Other ^c Kick in abdomen by 2-year-old	0	nl	34 + 2 S	- Retroplacental hematoma (organized, 80 mm diameter)
9	32 + 5	Fall On abdomen, tripping	0	nl	41 + 5 sC	- Intervillous thrombus
10	34 + 0	MVA Head full stop in crush barrier, skidded on frost, 40 km/h, in driving seat, seat belts on	0	nl	39 + 0 S	- Chorioamnionitis st1/gr1 - Intervillous thrombus - Subchorionic hematoma, 2 × 20 mm - Reactive amniothelium
11	25 + 3	Fall On abdomen (tripping)	0	nl	41 + 0 S	- Retroplacental hematoma, 4 mm
12	28 + 3	Fall On abdomen (tripping)	0	nl	39 + 6 S	- Intervillous thrombus - Retroplacental hematoma, 3 mm
13	28 + 6	Fall On abdomen and knees (tripping)	1	528	39 + 5 S	- Intervillous thrombi - Thrombus in fetal chorionic plate vessel - Hypercoiling

Abbreviations: C, cesarean section; CA, cycle accident; GA, gestational age in weeks + days; ISS, Injury Severity Score; MVA, motor vehicle accident; pC, primary; S, spontaneous; sC, secondary; TEA, term-equivalent age; X, ultrasound not performed.

Kleihauer–Betke results in μL or “nl” in case not increased.

^aMaternal HbF was found.

^bDomestic violence.

^cAccidental kick in abdomen by 2-year-old infant.

thrombi and reactive amniothelium were significantly more frequent in the cases. The degenerative changes of the amnioepithelium have been described in the presence of meconium in the amniotic cavity, elicited by fetal

distress. Meconium, however, was not or no longer visible in 5 of the 6 cases with reactive amnioendothelium.

The prevalence of retroplacental hematomas in this prospective study was 38% and consisted of mainly

small lesions, which is higher than the prevalence of placental abruption (8.5% without, 7.4% with nonsevere [ISS=1–8], and 13.1% with severe injuries [ISS ≥ 9]) after motor vehicle accidents reported in a large

retrospective cohort.¹¹ In this and other retrospective series reporting on the effects of trauma on obstetrical outcome, placental histology was not reported.^{1,10}

In our population with minor trauma, almost half of the placentas showed small intervillous thrombi, whereas none of the control placentas showed intervillous thrombi. In a study on placental pathology in pregnancies complicated by fetal growth restriction, intervillous thrombi were found in 42% of the placentas from pregnancies with fetal growth restriction and in 12% of a healthy control group.²² Intervillous thrombi are the result of leakage of fetal erythrocytes in the intervillous space, a process caused by the loss of fetal vascular integrity within the villi.⁵ It is interesting that we found no correlation between the intervillous thrombi and the presence of positive Kleihauer–Betke test. Retroplacental hemorrhage is seen after the loss of integrity of the maternal vascularization.⁵ Isolated retroplacental hematomas may be associated with fetomaternal hemorrhage.^{23,24} Thus, the presence of intervillous thrombi and retroplacental hematomas reflects hypoxic events and/or fetomaternal hemorrhage, which may explain the high prevalence after maternal trauma. In a previous study by Salafia et al., not related to trauma, the presence of hemosiderin (which derives from hemolyzed red blood cells, indicating old hemorrhage) in the basal decidua

Table 3. Characteristics at Delivery of Trauma and Control Group.

	Trauma	Control
Total (number)	13	15
Gestational age at delivery median (range), weeks + days	39 + 5 (34 + 2–41 + 5)	39 + 4 (34 + 3–41 + 0)
Preterm birth, n	1/13	2/15
Mode of delivery (number)		
Spontaneous	11	13
Vacuum extraction	0	0
Cesarean section	2	2
Birth weight median (range), g	3610 (2050–4035)	3471 (2020–4640)
Apgar scores, median (range)		
1 min	9 (5–10)	9 (3–10)
5 min	10 (6–10)	10 (5–10)
Male gender (number)	3	5

Table 4. Placental Macroscopy and Histology of Trauma and Control Group.

	Trauma (n = 13)	Control (n = 15)	P
<i>Macroscopy</i>			
Weight median (range), g	500 (335–600)	498 (351–660)	
Weight < 10th percentile	2/13	1/15	.583
Complete	13/13	15/15	–
(Para)central cord insertion	13/13	15/15	–
Umbilical cord knots	0/13	0/15	–
Diameter median (range), cm	1.0 (0.7–1.2)	1.0 (0.8–1.3)	.237
Coiling index median (range)	0.21 (0.05–0.36)	0.20 (0.10–0.50)	.936
Hypercoiling	2/11	1/14	.565
Hypocoiling	1/11	0/14	.440
<i>Histology</i>			
Maternal vascular malperfusion	5/13	2/15	.198
Accelerated villous maturation	0/13	1/15	1.0
Retroplacental hematoma	5/13	1/15	.069
Fetal vascular malperfusion			
Thrombus fetal chorionic plate	2/13	1/15	.583
Ascending intrauterine infection			
Maternal response	5/13	2/15	.198
Fetal response	2/5	0/2	
<i>Diverse</i>			
Intervillous thrombi	6/13	0/15	.005*
Reactive amniothelium	6/13	1/15	.0029*
Overall pathology	11/13	6/15	.0024*

*P < .05 (Fisher's exact test or Mann–Whitney U test) are significant.

and/or extraplacental membranes was described in 64% of cases with nonhypertensive placental abruption.²¹ In our study, 54% of the cases had hemosiderin depositions, almost all of them located around retroplacental and/or intervillous hematomas, compared to none of the controls. This indicates an event causing vascular damage (long) before birth.

The 40% chorioamnionitis in our trauma population is comparable to a 47% found in population with hypertensive disorders;⁸ however, we found no difference between the prevalence in the trauma and the control group, which corresponds to the fact that chorioamnionitis has been reported as a common finding in normal populations in former research.^{5,25}

We do not yet understand the findings of chorioamnionitis or hypercoiling, but both have been described as histological indicators of fetal hypoxia or ischemia.^{5,8,26} As chorioamnionitis occurs around the delivery, and it is considered unlikely that coiling density changes occur after 20 weeks' GA,²⁶ we cannot explain the role of (minor) trauma in the finding of chorioamnionitis and hypercoiling, as the traumas occurred after 20 weeks' GA and not directly prior to delivery.

Evaluating the histological abnormalities per type of accident, we could not find a clear difference in the distribution of the abnormalities. In the 3 cases with motor accidents, 2 had intervillous thrombi, 1 retroplacental hematoma, 2 chorioamnionitis, and 1 reactive amniothelium.

In the 6 cases with falls, 3 had intervillous thrombi, 2 retroplacental hematoma, 2 chorioamnionitis, 1 reactive amniothelium, 1 thrombus in fetal chorionic plate vessel, and 2 hypercoiling. In the 2 cases with other trauma and in 1 case with domestic violence chorioamnionitis, intervillous thrombus, retroplacental hematoma, and reactive amniothelium were found, and in the case with accidental kick in the abdomen, a retroplacental hematoma of 8 cm was demonstrated 14 weeks after the incident after preterm delivery. The 2 women with cycle accidents had no anomalies in the placenta.

The number per type of accident is too small to correlate these findings; however, they demonstrate that even small incidents such as accidental kicking in the abdomen, falls, and also domestic violence can elicit histological abnormalities.

A relation between placental pathology and findings on brain ultrasound could not be made due to the limited availability of complete data of both brain imaging and placental histology.

Nearly, all fetuses in the trauma group were delivered at term and vaginally. Moreover, median Apgar scores at 1 and 5 minutes were normal, which underlines a lack of perinatal hypoxic ischemia, accentuating the fact that placental pathological findings most probably do not originate from intrapartum events, but from hypoxic events earlier in pregnancy.

Our finding of more placental pathology after minor trauma in pregnancy, together with previous reports linking similar pathological findings to abnormal findings on brain ultrasound and/or neurodevelopmental abnormalities,^{6,27} may elucidate a first step in the pathogenesis and therefore stimulates to conduct a larger study investigating the placenta after maternal trauma in pregnancy, together with follow-up of the neurological outcome of the infant.

Strengths and Limitations

The limited number of placentas and fetuses has to be considered as well as the fact that maternal injuries were mainly minor. This occurred despite the effort to invite women regardless of the severity of maternal injuries. The main reason for declining was the anxiousness for unwanted test results from brain imaging. Nonetheless, previous research focused on the effects of major placental abruption, often followed by preterm delivery (possibly influencing placental histology as well) and does not take into account that minor trauma may also cause placental pathology. Modesty about the severity of placental pathology in the trauma group is in order; however, the high prevalence after trauma compared to the control population did allow us to interpret the findings as abnormal.

In conclusion, the majority of the cases showed placental pathology after minor trauma in pregnancy in this small data set. This finding underlines the importance of placental histology and the need of a larger study. Narrowing the examination to placental histology only (instead of a broad observational study including brain imaging and a long infant follow-up until 5 years of age) may increase women's willingness to participate in such study.

Acknowledgments

The authors are most grateful to LS de Vries, LR Pistorius, and JIML Verbeke for their help in the performance and/or assessment of brain ultrasounds. The authors would also like to thank PEM van Schie and VAM Schaaf for their contribution in carrying out the neurological follow-up examinations.

Declaration of Conflicting Interests

The author(s) declared no potential conflicts of interest with respect to the research, authorship, and/or publication of this article.

Funding

The author(s) received no financial support for the research, authorship, and/or publication of this article.

References

1. Kuo C, Jamieson DJ, McPheeters ML, Meikle SF, Posner SF. Injury hospitalizations of pregnant women in the United States, 2002. *Am J Obstet Gynecol.* 2007;196(2):161–166.

2. Hayes B, Ryan S, Stephenson JB, King MD. Cerebral palsy after maternal trauma in pregnancy. *Dev Med Child Neurol*. 2007;49(9):700–706.
3. Goodwin TM, Breen MT. Pregnancy outcome and fetomaternal hemorrhage after noncatastrophic trauma. *Am J Obstet Gynecol*. 1990;162(3):665–671.
4. Klinich KD, Flannagan CA, Rupp JD, Sochor M, Schneider LW, Pearlman MD. Fetal outcome in motor-vehicle crashes: effects of crash characteristics and maternal restraint. *Am J Obstet Gynecol*. 2008;198(4):450–459.
5. Redline RW. Placental pathology: a systematic approach with clinical correlations. *Placenta*. 2008;29(Suppl A): S86–S91.
6. Wu YW, Colford JM Jr. Chorioamnionitis as a risk factor for cerebral palsy: a meta-analysis. *JAMA*. 2000;284(11):1417–1424.
7. Viscardi RM, Sun CC. Placental lesion multiplicity: risk factor for IUGR and neonatal cranial ultrasound abnormalities. *Early Hum Dev*. 2001;62(1):1–10.
8. Rosier-van Dunne FM, van Wezel-Meijler G, Kaschula RO, Wranz PA, Odendaal HJ, de Vries JI. Placental histology related to fetal brain sonography. *Arch Dis Child Fetal Neonatal Ed*. 2011;96(1):F53–F58.
9. Schiff MA, Holt VL. The Injury Severity Score in pregnant trauma patients: predicting placental abruption and fetal death. *J Trauma*. 2002;53(5):946–949.
10. El-Kady D, Gilbert WM, Anderson J, Danielsen B, Towner D, Smith LH. Trauma during pregnancy: an analysis of maternal and fetal outcomes in a large population. *Am J Obstet Gynecol*. 2004;190(6):1661–1668.
11. Schiff MA, Holt VL. Pregnancy outcomes following hospitalization for motor vehicle crashes in Washington State from 1989 to 2001. *Am J Epidemiol*. 2005;161(6):503–510.
12. de Laat MW, Franx A, van Alderen ED, Nikkels PG, Visser GH. The umbilical coiling index, a review of the literature. *J Matern Fetal Neonatal Med*. 2005;17(2):93–100.
13. Wigglesworth JS, Singer DB. *Textbook of Fetal and Perinatal Pathology*. Oxford, England: Wiley-Blackwell, 1998.
14. Redline RW, Boyd T, Campbell V, et al. Maternal vascular underperfusion: nosology and reproducibility of placental reaction patterns. *Pediatr Dev Pathol*. 2004;7(3):237–249.
15. Redline RW, Ariel I, Baergen RN, et al. Fetal vascular obstructive lesions: nosology and reproducibility of placental reaction patterns. *Pediatr Dev Pathol*. 2004;7(5):443–452.
16. Redline RW, Faye-Petersen O, Heller D, Qureshi F, Savell V, Vogler C. Amniotic infection syndrome: nosology and reproducibility of placental reaction patterns. *Pediatr Dev Pathol*. 2003;6(5):435–448.
17. Khong TY, Mooney EE, Ariel I, et al. Sampling and definitions of placental lesions: Amsterdam Placental Workshop Group consensus statement. *Arch Pathol Lab Med*. 2016;140(7):698–713.
18. Prechtl HF. *The Neurological Examination of the Full Term Newborn Infant: A Manual for Clinical Use* 2 ed. London, England: Heinemann, 1977.
19. Touwen B. *Neurological Development in Infancy*. London, England: Heinemann, 1976.
20. Piper MC, Darrah J. *Motor Assessment of the Developing Infant*. Philadelphia, PA: WB Saunders, 1994.
21. Salafia CM, Minior VK, Rosenkrantz TS, et al. Maternal, placental, and neonatal associations with early germinal matrix/intraventricular hemorrhage in infants born before 32 weeks' gestation. *Am J Perinatol*. 1995;12(6):429–436.
22. Vedmedovska N, Rezeberga D, Teibe U, Melderis I, Donders GG. Placental pathology in fetal growth restriction. *Eur J Obstet Gynecol Reprod Biol*. 2011;155(1):36–40.
23. Devi B, Jennison RF, Langley FA. Significance of placental pathology in transplacental haemorrhage. *J Clin Pathol*. 1968;21(3):322–331.
24. Maier JT, Schalinski E, Schneider W, Gottschalk U, Hellmeyer L. Fetomaternal hemorrhage (FMH), an update: review of literature and an illustrative case. *Arch Gynecol Obstet*. 2015;292:595–602.
25. Houben ML, Nikkels PG, van Bleek GM, et al. The association between intrauterine inflammation and spontaneous vaginal delivery at term: a cross-sectional study. *PLoS One*. 2009;4(8):e6572.
26. de Laat MW, van der Meij JJ, Visser GH, Franx A, Nikkels PG. Hypercoiling of the umbilical cord and placental maturation defect: associated pathology? *Pediatr Dev Pathol*. 2007;10(4):293–299.
27. Redline RW, Minich N, Taylor HG, Hack M. Placental lesions as predictors of cerebral palsy and abnormal neurocognitive function at school age in extremely low birth weight infants (<1 kg). *Pediatr Dev Pathol*. 2007;10(4):282–292.