

Case report

Gestational choriocarcinoma complicated by infective endocarditis during chemotherapy



Tadaharu Nakasone, Yutaka Nagai, Yoshihisa Arakaki, Yoshino Kinjyo, Yoichi Aoki*

Department of Obstetrics and Gynecology, Graduate School of Medicine, University of the Ryukyus, Okinawa, Japan

ARTICLE INFO

Article history:

Received 8 January 2017

Received in revised form 2 February 2017

Accepted 4 February 2017

Available online 6 February 2017

Keywords:

Gestational trophoblastic neoplasia

Choriocarcinoma

Infective endocarditis

Chemotherapy

© 2017 The Authors. Published by Elsevier Inc. This is an open access article under the CC BY-NC-ND license (<http://creativecommons.org/licenses/by-nc-nd/4.0/>).

1. Introduction

The frequency of infective endocarditis (IE) in patients with predominant cancers was not greater than that reported in general hospital populations (Rosen and Armstrong, 1973). However, little is known about the extent of the association between IE and cancer and the history of cancer patients with a concomitant diagnosis of IE. The incidence of IE associated with neoplasms and/or insertion of an indwelling central venous catheter has recently increased in Japan (Hase et al., 2015). Nonetheless, IE is rarely encountered among patients with cancer, and there are few reports on IE during cancer chemotherapy.

Gestational choriocarcinoma is a highly curable form of adult malignancy, largely because this tumor is exceptionally sensitive to chemotherapy. Well-established first-line chemotherapy [such as EMA-CO (Bower et al., 1997)] is highly active against gestational choriocarcinoma. However, it is very important to perform the appropriate chemotherapy without delay to achieve excellent treatment outcomes. Here we report the case of a patient with gestational choriocarcinoma complicated by IE during EMA-CO treatment, wherein the chemotherapy had to be halted until the IE settled down.

2. Case report

A 49-year-old Japanese woman, (gravida 6, para 6-0-0-6), who had a normal vaginal delivery 8 years ago, presented with lower abdominal pain and massive vaginal bleeding to her gynecologist. She had severe anemia (3.1 g/dl Hb) because of atypical vaginal bleeding for the prior six months and was referred to our institution. A transvaginal ultrasound examination showed that the uterine cavity was occupied with tumor 69 × 27 mm in size with high vascularization. Her serum hCG level was 1,072,560 mIU/ml and was negative for hPL. Pelvic magnetic resonance imaging (MRI) revealed that a well-enhanced tumor was located in the uterine fundus (Fig. 1). A computed tomography (CT) scan revealed no abnormality in the distant organs. She was diagnosed with high-risk gestational trophoblastic neoplasia (presumably choriocarcinoma, histologically not proven) International Federation of Gynecology and Obstetrics (FIGO) stage I: 13. EMA-CO was commenced as the initial chemotherapy regimen [Day 1: actinomycin D, 0.5 mg; etoposide, 100 mg/m²; methotrexate, 100 mg/m²; followed by 200 mg/m² over 12 h. Day 2: actinomycin D, 0.5 mg; etoposide, 100 mg/m²; leucovorin, 15 mg q 6 h (4 doses, 24 h after the first methotrexate dose). Day 8: vincristine, 1 mg; cyclophosphamide, 600 mg/m²].

On day 4 of the first cycle of EMA-CO treatment, however, high fever (40.0 °C) and elevated levels of C reactive protein in the serum were observed. The abdominal and pelvic CT scan revealed a low-density area in the posterior wall of the uterine corpus and multiple low-density areas

* Corresponding author at: Department of Obstetrics and Gynecology, Graduate School of Medicine, University of the Ryukyus, 207 Uehara Nishihara, Okinawa 903-0215, Japan.
E-mail address: yoichi@med.u-ryukyu.ac.jp (Y. Aoki).

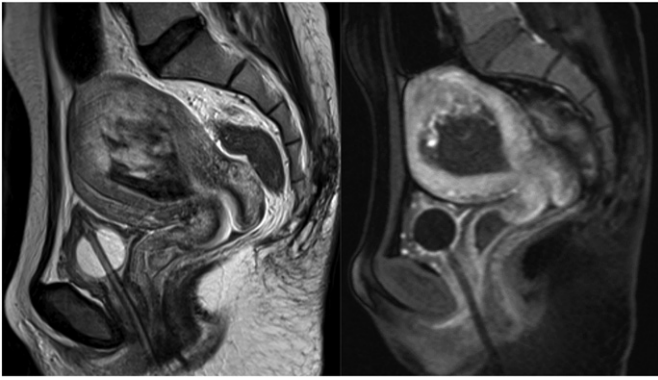


Fig. 1. Pelvic magnetic resonance imaging revealed well-enhanced tumor in the uterine fundus. (lt.; T2-weighted sagittal image, rt.; T1-weighted contrast enhanced image).

in the bilateral kidneys, indicating uterine abscess and renal infarctions (Fig. 2). While waiting for blood and vaginal discharge culture results, empiric antibiotic therapy, with 2 g ceftriaxone intravenously administered every 12 h and 400 mg clindamycin intravenously every 6 h a day, was started for the suspected uterine abscess. Meanwhile, methicillin-sensitive *Staphylococcus aureus* (MSSA) was isolated from the blood cultures and vaginal discharge. Transthoracic echocardiography showed an endocardial vegetation stack on the anterior leaflet of mitral valve protruding in the inflow tract of the left ventricle, and the renal infarction was thought to be caused by a renal artery embolism from IE. IE was diagnosed as per the Duke criteria (Li et al., 2000). The antibiotic treatment was changed to metronidazole (500 mg, oral three times a

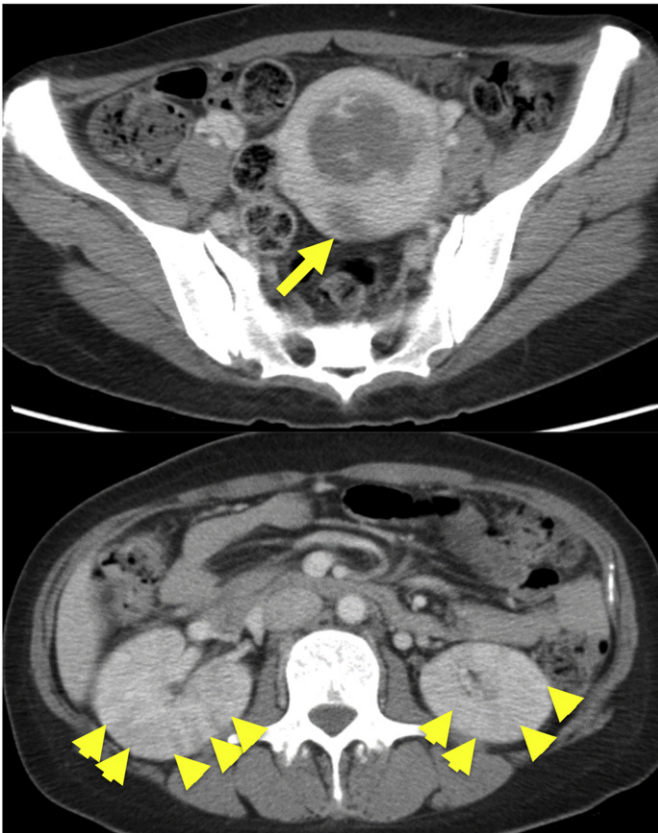


Fig. 2. Pelvic computed tomography (CT) scan (upper panel) showed low density area in the posterior wall of uterine corpus, indicating the uterine abscess (arrow). Abdominal CT scan (lower panel) revealed multiple low density areas in bilateral kidneys, indicating renal infarctions (arrow heads).

day), penicillin G (4×10^6 U, intravenous, every 4 h), and gentamycin (60 mg, intravenous, every 8 h for 5 days).

Seven days after the antibiotic treatment, echocardiography revealed no endocardial vegetation or mitral valve destruction, and the blood culture was negative. Thereafter, EMA-CO treatment was resumed. On days 14, 15, neutropenic fever was developed and rescued by granulocyte-colony stimulating factor (G-CSF) and meropenem (1 g, intravenous, every 8 h for 5 days). Her urine and blood cultures were negative at this time. No IE deterioration was observed at that time. Eventually, she was treated with intravenous antibiotics for IE with penicillin G for 5 days and meropenem for 5 days, thereafter cefazolin for 4 weeks. After completing 8 cycles, her serum hCG dropped to the cut-off level. Three additional cycles of EMA-CO were administered. She received therapeutic G-CSF on 1, 4, 6, 8, 10 cycles of EMA-CO. She remained clinically free of the disease with normal serum hCG levels for 8 months.

3. Discussion

Chemotherapy for choriocarcinoma had already been started when the patient developed bacteremia and IE secondary to the infection with MSSA. The infection occurred as a consequence of the suppressed immune system due to chemotherapy. We had to halt the chemotherapy until the IE settled down. Because IE is a high mortality rate of 20 to 25% (Mylonakis and Calderwood, 2001), we had to give precedence to treatment for IE. We suspect that IE developed as a result of the transmission of the MSSA into the bloodstream through the uterine choriocarcinoma lesion, because MSSA was isolated both from the blood cultures and vaginal discharge.

Generally, the presentation of IE is indolent, with fever and a variety of somatic symptoms including fatigue, weakness, arthralgias, myalgias, weight loss, rigor, and diaphoresis. In our case, high fever and kidney infarction detected in the CT scan led to the diagnosis of IE. A positive blood culture is a major diagnostic criteria for the diagnosis of IE. Renal infarction together with the positive MSSA blood culture allowed us to identify the echocardiographic vegetation. It is known that IE can cause renal infarction and Millaire et al. found five cases (7%) of renal infarction in 68 cases with IE (Millaire et al., 1997). Because of a high mortality, IE requires immediate and adequate treatment. Therefore, the appropriate diagnosis of IE for patients with renal infarction without any other contributing cause is required.

In the case of colon cancer, the incidence of *Streptococcus bovis* endocarditis was between 18% and 62% (Gupta et al., 2010). A recent study suggested that a majority of patients affected by colonic cancer develop a silent infection; however, it becomes apparent with immune system disorders or cardiac valve lesions (Tjalsma et al., 2006). In the elderly population, the incidence of IE in colorectal cancer was substantially higher than that in lung, breast and prostate cancers (García-Albéniz et al., 2016). However, as with other cancers, patients undergoing chemotherapy are highly prone to infections because of the suppressed immune system. This should be taken into account because IE has a high mortality, treatment by a team of several specialists (cardiologist, infectiologist, radiologist, and gynecologic oncologist) remains the gold standard for an accurate diagnostic workup and prompt treatment decisions of IE and cancer.

COI

The authors declare that there is no conflict of interest regarding the publication of this paper.

References

- Bower, M., Newlands, E.S., Holden, L., Short, D., Brock, C., Rustin, G.J., Begent, R.H., Bagshawe, K.D., 1997. EMA/CO for high-risk gestational trophoblastic tumours; results from a cohort of 272 patients. *J. Clin. Oncol.* 15, 2636–2643.

- García-Albéniz, X., Hsu, J., Lipsitch, M., Logan, R.W., Hernández-Díaz, S., Hernán, M.A., 2016. Infective endocarditis and cancer in the elderly. *Eur. J. Epidemiol.* 31, 41–49.
- Gupta, A., Madani, R., Mukhtar, H., 2010. *Streptococcus bovis* endocarditis; a silent sign for colonic tumour. *Color. Dis.* 12, 164–171.
- Hase, R., Otsuka, Y., Yoshida, K., Hosokawa, N., 2015. Profile of infective endocarditis at a tertiary-care hospital in Japan over a 14-year period: characteristics, outcome and predictors for in-hospital mortality. *Int. J. Infect. Dis.* 33, 62–66.
- Li, J.S., Sexton, D.J., Mick, N., Nettles, R., Fowler Jr., V.G., Ryan, T., Bashore, T., Corey, G.R., 2000. Proposed modifications to the Duke criteria for the diagnosis of infective endocarditis. *Clin. Infect. Dis.* 30, 633–638.
- Millaire, A., Leroy, O., Gaday, V., de Groote, P., Beuscart, C., Goullard, L., Beaucaire, G., Ducloux, G., 1997. Incidence and prognosis of embolic events and metastatic infections in infective endocarditis. *Eur. Heart J.* 18, 677–684.
- Mylonakis, E., Calderwood, S.B., 2001. Infective endocarditis in adults. *N. Engl. J. Med.* 345, 1318–1330.
- Rosen, P., Armstrong, D., 1973. Infective endocarditis in patients treated for malignant neoplastic diseases: a postmortem study. *Am. J. Clin. Pathol.* 60, 241–250.
- Tjalsma, H., Schöller-Guinard, M., Lasonder, E., Ruers, T.J., Willems, H.L., Swinkels, D.W., 2006. Profiling the humoral immune response in colon cancer patients: diagnostic antigens from *Streptococcus bovis*. *Int. J. Cancer* 119, 2127–2135.