

# Massive hemobilia due to a ruptured mycotic hepatic artery aneurysm associated with streptococcal endocarditis: case report

Journal of International Medical Research

48(3) 1–7

© The Author(s) 2019

Article reuse guidelines:

[sagepub.com/journals-permissions](http://sagepub.com/journals-permissions)

DOI: 10.1177/0300060519883554

[journals.sagepub.com/home/imr](http://journals.sagepub.com/home/imr)

Jia-Ying Zhu\* , Jia Huang\*, Wei Fan, Xia Lv, Yi-Pin Ren and Xiu-Lin Yang

## Abstract

Hepatic artery aneurysm rupture is a rare cause of massive hemobilia, which is potentially life-threatening, cause of upper gastrointestinal hemorrhage. Cases of mycotic hepatic artery aneurysm associated with streptococcal endocarditis have rarely been reported. In the present study, we report a case of massive hemobilia that was caused by ruptured mycotic hepatic artery aneurysm in a patient who was infected with streptococcal endocarditis 3 months previously. Transarterial embolization in the patient failed, possibly due to vascular variations. However, surgical treatment was successfully performed, and the patient completely recovered. In conclusion, surgical treatment may be useful in treating massive hemobilia under life-threatening conditions, even in cases of vascular variations and failure of transarterial embolization.

## Keywords

Massive hemobilia, streptococcal endocarditis, mycotic hepatic artery aneurysm, surgical treatment, transarterial embolization, vascular variation

Date received: 9 May 2019; accepted: 27 September 2019

## Introduction

Cases of mycotic hepatic artery aneurysms have rarely been observed or reported owing to the widespread use of effective antibiotics to treat this disease.<sup>1,2</sup> These aneurysms represent a complication of bacterial endocarditis, which possesses a high

Department of Emergency, Gui Zhou Provincial People's Hospital, Guiyang, China

\*These authors contributed equally to this work.

### Corresponding author:

Xiu-Lin Yang, Department of Emergency, Gui Zhou Provincial People's Hospital, No. 1 Baoshan South Road, Guiyang 550002, China.

Email: [miracle5055@163.com](mailto:miracle5055@163.com)



Creative Commons Non Commercial CC BY-NC: This article is distributed under the terms of the Creative Commons Attribution-NonCommercial 4.0 License (<http://www.creativecommons.org/licenses/by-nc/4.0/>) which permits non-commercial use, reproduction and distribution of the work without further permission provided the original work is attributed as specified on the SAGE and Open Access pages (<https://us.sagepub.com/en-us/nam/open-access-at-sage>).

probability of causing rupture of the artery, leading to hemobilia. To the best of our knowledge, there is no specific technique to manage this condition. In the current study, we report a case of massive hemobilia, which was caused by hepatic mycotic aneurysm rupture in a patient with streptococcal endocarditis. The patient was treated until successful recovery.

### Case report

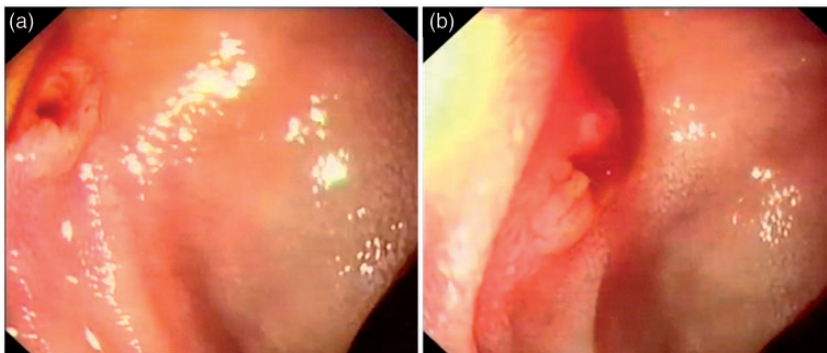
A 28-year-old patient was admitted to the Emergency Department for 3 days because of persistent upper abdominal pain, hematemesis, and melena. The patient suffered from hypovolemic shock and the volume of total blood loss was approximately 2800 mL.

Three months before the current hospital admission, the patient was admitted to a local hospital for fever, chest congestion, and breathing difficulty. The patient's body temperature increased to 39.5°C, and systolic murmurs with grade 3/6 to 4/6 were detected at the mitral valve and aortic valve auscultation areas. Severe mitral valve regurgitation and Lambli's excrescence were also detected by echocardiography. Furthermore, a blood culture test indicated the presence of *Streptococcus pyogenes*. However, abdominal ultrasonography results

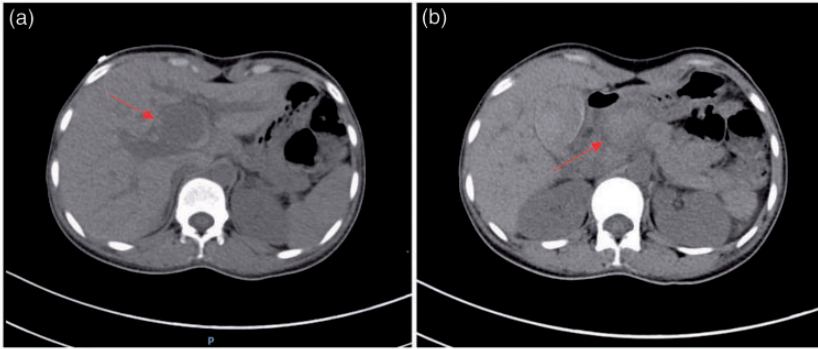
did not show any liver anomalies. On the basis of these findings, the patient was diagnosed with rheumatic heart disease and streptococcal bacterial endocarditis. After daily treatment with an intravenous drip of penicillin sodium (4 million IU; 4 times per day for 17 days), the patient's fever subsided, and chest congestion and breathing difficulties were alleviated. The patient then underwent surgical treatment, including mitral valve replacement and clearing of the left atrial excrescence. The patient was discharged without fever, chest congestion, or breathing difficulties.

In the current hospital admission, written informed consent was obtained from the patient after receiving a detailed explanation about this case report for publication and the images presented in this report. The protocol was approved by Guizhou Provincial People's Hospital Medical Ethics Committee. The patient's total bilirubin level, which was tested using a serological test, was 41.0 μmol/L. Under this circumstance, gastroscopy was immediately performed. This procedure showed that there was bleeding from the papilla of Vater (Figure 1).

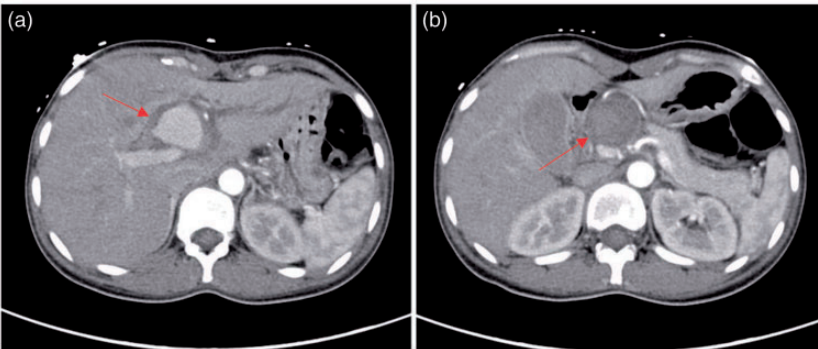
An abdominal non-enhanced computed tomography (CT) scan showed a mass in the porta hepatis area (Figure 2) and it was approximately 30 × 29 mm in diameter.



**Figure 1.** Intermittent bleeding from the papilla of Vater.



**Figure 2.** Non-enhanced computed tomography scan shows a mass in the porta hepatis area. Red arrows indicate the mass.



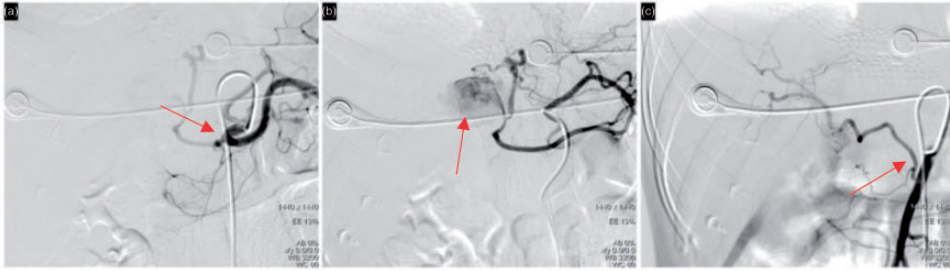
**Figure 3.** Enhancement of the mass on a contrast-enhanced computed tomography scan. Red arrows indicate the mass.

Furthermore, by performing a contrast-enhanced CT scan, the enhancement values during three periods were 115 HU, 180 HU, and 136 HU. Additionally, there was a low-density shadow around the mass and a quasi-circular density shadow underneath it (Figure 3).

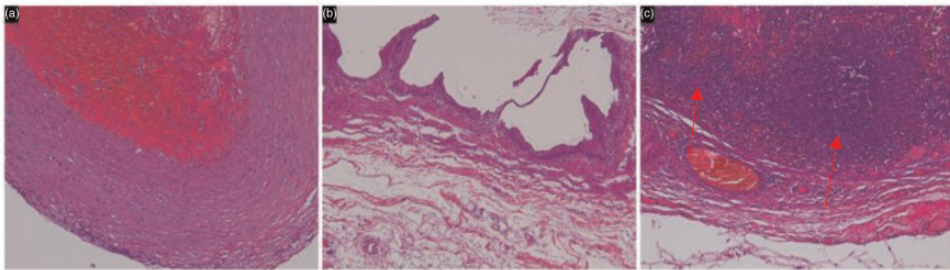
A ruptured hepatic aneurysm was confirmed by hepatic angiography, which showed that there was almost complete occlusion of the common hepatic artery and the right hepatic artery originated from the superior mesenteric artery. After angiography, blood was supplied to the proper hepatic artery via the left gastric artery through anastomosis, following

detection of a hepatic artery pseudoaneurysm (Figure 4).

An attempt was made to manipulate a 2.6F microcatheter (Stride; Asahi Intecc Co., Ltd., Seto, Japan) into the proper hepatic artery through the left gastric artery during pseudoaneurysm embolization, but this attempt failed. Open abdominal surgery was performed after obtaining informed consent from the patient and family members. Surgeons found a mass that had a diameter of  $2.0 \times 2.0$  cm with a rhythmic beat on the right side of the common bile duct, which was in the hepatic hilar region. Cholecystectomy was performed because the surgeons could not



**Figure 4.** Angiographic images. (a) The common hepatic artery shows almost complete occlusion (red arrow). (b) The proper hepatic artery is anastomosed with the left gastric artery wherein a pseudoaneurysm was detected (red arrow). (c) The right hepatic artery originates from the superior mesenteric artery (red arrow).



**Figure 5.** Tissue sections of the fiber wall of the mass as shown by hematoxylin and eosin staining. The presence of lymphocytes and lymphoid nodules was detected in the fiber wall (red arrows). Magnification,  $\times 100$ .

rule out the possibility of gall bladder bleeding in the patient. After cholecystectomy, surgeons separated the peripheral anterior synechiae of the mass and found that the pseudoaneurysm stemmed from the proper hepatic artery. The aneurysm was then successfully resected after selective ligation of the proximal and distal vessels. When the left hepatic artery was isolated upwards, another aneurysm with a diameter of  $2.0 \times 2.0$  cm was found, which originated from the left hepatic artery. The aneurysm was then successfully resected via the same method, and a 0.3-cm fistula was found on the inferior wall of the left hepatic duct and bile was flowing through it. The fistula was repaired by surgeons after the common bile

duct exploration procedure and the T-tube drainage method was subsequently carried out. The incision was sutured, followed by abdominal irrigation. The patient did not bleed after the surgery. A pathological examination of the tissue obtained from the proper hepatic artery showed a taupe mass, whereas the tissue obtained from the left hepatic artery showed several taupe and gray-white components. Tissue sections also showed a taupe color, and fiber wall sample tissues showed the presence of lymphocytes and lymphoid nodules (Figure 5). The T-drainage tube in the common bile duct was successfully removed 3 months after surgery and the patient fully recovered.

## Discussion

The term “hemobilia” was first used by Sandblom to describe bleeding in the biliary tract in 1948.<sup>3</sup> Massive hemobilia is rarely observed, but it is a potential life-threatening condition. The classic clinical manifestations of hemobilia are Quincke’s triad of symptoms, including abdominal pain (70%), bleeding at the upper digestive tract (melena in 90% and hematemesis in 60% of patients), and jaundice (60%).<sup>4,5</sup> We describe here a case of a patient who showed the classic Quincke’s triad of symptoms.

Hemobilia is difficult to diagnose because of intermittent bleeding. In such cases, upper gastrointestinal endoscopy should be the primary approach for investigation because it can directly show blood flowing out of the papilla of Vater. Additionally, this technique can indirectly indicate the presence of hemobilia based on the presence of fresh blood in the duodenum. Therefore, upper gastrointestinal endoscopy may help rule out other common causes of bleeding. Murugesan et al. retrospectively analyzed 20 patients with hemobilia, including a group of patients (n = 6, 30%) with fresh blood oozing from the papilla, a group of patients (n = 6, 30%) with indirectly inferred diagnosis, and a group of patients (n = 8, 40%) with normal endoscopic findings.<sup>5</sup> In the present case, fresh blood oozing from the papilla of Vater was directly observed. Abdominal ultrasonography may also be helpful for diagnosing hemobilia and help in detecting dilatation of the biliary tract in cases of partial or total biliary obstruction.

Post-traumatic hemobilia is the most common cause of biliary tract bleeding.<sup>6,7</sup> Because of the widespread use of diagnostic and therapeutic interventional procedures, iatrogenic hemobilia was found to be the most frequent etiological factor, whereas other factors include gallstones, inflammation,

neoplastic disease, and vascular conditions.<sup>5-8</sup> A few cases of hemobilia that were caused by aneurysmal disease of the artery have also been reported.<sup>1,9-11</sup> However, cases of hemobilia that were caused by mycotic hepatic artery aneurysm have rarely been reported because of low morbidity.<sup>12</sup>

Mycotic aneurysm is a rare complication, which is characterized by the presence of septic emboli associated by bacterial endocarditis. Since the introduction of antibiotics, only a few similar cases of mycotic aneurysm have been reported, and the incidence of mycotic hepatic artery aneurysm is considered to be rare.<sup>12,13</sup> A total of 306 patients with visceral aneurysms presented to the Mayo Clinic between 1980 and 1998, and only 36 of them were confirmed to have a hepatic artery aneurysm.<sup>2,12,13</sup> However, one of these patients had a history of infective endocarditis. A blood culture test in the current patient showed streptococcal endocarditis 3 months before hospital admission and abdominal ultrasonography did not show any liver anomalies. Therefore, we speculated that the hepatic artery aneurysm was associated with endocarditis.

Angiography is the preferred method for confirming a hepatic artery aneurysm, whereas CT is an effective non-invasive method for detecting aneurysms.<sup>14,15</sup> In particular, arterial phase multi-detector row CT is more accurate for detecting and localizing bleeding sites in patients with acute massive gastrointestinal bleeding.<sup>16</sup> In the present case, abdominal CT showed the localized bleeding sites. Angiography confirmed the hepatic artery aneurysm and indicated hepatic vascular variation, which might be a risk factor for formation of mycotic hepatic artery aneurysm. However, angiography results are not always accurate and reliable. In the present study, angiography showed only one hepatic artery aneurysm, but two aneurysms were found during open surgery.

Hepatic artery aneurysms are at definite risk for rupture (14%), and the risk factors for rupture include multiple hepatic artery aneurysms and a non-atherosclerotic origin.<sup>13</sup> However, the incidence of rupture of mycotic hepatic artery aneurysm remains unknown because of its low morbidity. Furthermore, the present case presented with aneurysms in multiple hepatic arteries. Two aneurysms, which were non-atherosclerotic in origin, were found in the proper hepatic artery and left hepatic artery.

Patients with massive hemobilia, such as the present case, usually suffer from hypovolemic shock, resuscitation, and hemodynamic stabilization. Therefore, the most important part of treatment of massive hemobilia is to stop bleeding and restore bile flow. In this regard, the therapeutic options include transarterial embolization and surgery. Transarterial embolization is used as the initial treatment, and generally, 75% to 100% of cases achieve good results with this method.<sup>3,17,18</sup> However, transarterial embolization failed in the present case because of vascular variation and/or insufficient experience of the operator dealing with this disease. In the present case, the patient was successfully treated surgically. Surgical treatments performed on patients with iatrogenic hemobilia,<sup>19</sup> pseudoaneurysm of the cystic artery that causes hemobilia,<sup>20</sup> and acute cholecystitis secondary to hemobilia have been reported.<sup>21</sup> However, to the best of our knowledge, no studies on surgical treatment for mycotic hepatic artery aneurysm have been reported. In the present case, vascular variation appeared to be an unexpected event that further complicated the treatment options. The proper hepatic artery was anastomosed via the left gastric artery, while the right hepatic artery originated from the superior mesenteric artery. We removed the two mycotic hepatic artery aneurysms after selective ligation of the proximal and distal vessels of the aneurysm. Finally, the

patient completely recovered. Therefore, we believe that the surgical method was useful and successful. Moreover, on the basis of our follow-up records with the patient for 2 years, the patient did not manifest any signs of recurrent hemobilia.

## Conclusion

Mycotic hepatic aneurysm associated with endocarditis is a rare cause of hemobilia in the antibiotic era. In the present case, transarterial embolization failed because of the patient's vascular variation and life-threatening condition of the patient. However, surgical treatment of mycotic hepatic artery aneurysms after selective ligation of the proximal and distal vessels of the aneurysm may be useful.

## Author contributions

Jia Huang drafted the manuscript. Wei Fan carried out the operation. Xiu-Lin Yang, Xia Lv, and Yi-Pin Ren were responsible for acquisition, analysis, and interpretation of the data. Jia-Ying Zhu revised the manuscript for important intellectual content.

## Declaration of conflicting interest

The authors declare that there is no conflict of interest.

## Funding

This research received no specific grant from any funding agency in the public, commercial, or not-for-profit sectors.

## ORCID iD

Jia-Ying Zhu  <https://orcid.org/0000-0003-0535-6877>

## References

1. Fong KL, Zwierzchniewska M, Patel D, et al. Mycotic aneurysm of the hepatic artery causing haemobilia. *ANZ J Surg*

- 2018; 88: E350–E351. DOI: 10.1111/ans.13351.
2. Abbas MA, Fowl RJ, Stone WM, et al. Hepatic artery aneurysm: factors that predict complications. *J Vasc Surg* 2003; 38: 41–45.
  3. Sandblom P. Hemorrhage into the biliary tract following trauma; traumatic hemobilia. *Surgery* 1948; 24: 571–586.
  4. Merrell SW and Schneider PD. Hemobilia—evolution of current diagnosis and treatment. *West J Med* 1991; 155: 621–625.
  5. Murugesan SD, Sathyanesan J, Lakshmanan A, et al. Massive hemobilia: a diagnostic and therapeutic challenge. *World J Surg* 2014; 38: 1755–1762. DOI: 10.1007/s00268-013-2435-5.
  6. Curet P, Baumer R, Roche A, et al. Hepatic hemobilia of traumatic or iatrogenic origin: recent advances in diagnosis and therapy, review of the literature from 1976 to 1981. *World J Surg* 1984; 8: 2–8.
  7. Yoshida J, Donahue PE and Nyhus LM. Hemobilia: review of recent experience with a worldwide problem. *Am J Gastroenterol* 1987; 82: 448–453.
  8. Lee SP, Tasman-Jones C and Wattie WJ. Traumatic hemobilia: a complication of percutaneous liver biopsy. *Gastroenterology* 1977; 72: 941–944.
  9. Shussman N, Edden Y, Mintz Y, et al. Hemobilia due to hepatic artery aneurysm as the presenting sign of fibro-muscular dysplasia. *World J Gastroenterol* 2008; 14: 1797–1799.
  10. Komatsu S, Iwasaki T, Nishioka N, et al. Hemobilia associated with a giant thrombosed aneurysm of the hepatic artery requiring hepatectomy. *Ann Vasc Surg* 2014; 28: 1934.e1913–1934.e1917. DOI: 10.1016/j.avsg.2014.06.078.
  11. Priya H, Anshul G, Alok T, et al. Emergency cholecystectomy and hepatic arterial repair in a patient presenting with haemobilia and massive gastrointestinal haemorrhage due to a spontaneous cystic artery gallbladder fistula masquerading as a pseudoaneurysm. *BMC Gastroenterol* 2013; 13: 43. DOI: 10.1186/1471-230X-13-43.
  12. Jordan M, Razvi S and Worthington M. Mycotic hepatic artery aneurysm complicating *Staphylococcus aureus* endocarditis: successful diagnosis and treatment. *Clin Infect Dis* 2004; 39: 756–757. DOI: 10.1086/423279.
  13. Chaudhari D, Saleem A, Patel P, et al. Hepatic artery mycotic aneurysm associated with staphylococcal endocarditis with successful treatment: case report with review of the literature. *Case Reports Hepatol* 2013; 2013: 610818. DOI: 10.1155/2013/610818.
  14. Mortimer AM, Wallis A and Planner A. Multiphase multidetector CT in the diagnosis of haemobilia: a potentially catastrophic ruptured hepatic artery aneurysm complicating the treatment of a patient with locally advanced rectal cancer. *Br J Radiol* 2011; 84: e95–e98. DOI: 10.1259/bjr/20779582.
  15. Deipolyi AR, Bailin A, Khademhosseini A, et al. Imaging findings, diagnosis, and clinical outcomes in patients with mycotic aneurysms: single center experience. *Clin Imaging* 2016; 40: 512–516. DOI: 10.1016/j.clinimag.2015.12.002.
  16. Yoon W, Jeong YY, Shin SS, et al. Acute massive gastrointestinal bleeding: detection and localization with arterial phase multi-detector row helical CT. *Radiology* 2006; 239: 160–167. DOI: 10.1148/radiol.2383050175.
  17. Moodley J, Singh B, Lalloo S, et al. Non-operative management of haemobilia. *Br J Surg* 2001; 88: 1073–1076. DOI: 10.1046/j.0007-1323.2001.01825.x.
  18. Forlee MV, Krige JE, Welman CJ, et al. Haemobilia after penetrating and blunt liver injury: treatment with selective hepatic artery embolisation. *Injury* 2004; 35: 23–28.
  19. Dousset B, Sauvanet A, Bardou M, et al. Selective surgical indications for iatrogenic hemobilia. *Surgery* 1997; 121: 37–41.
  20. Kaman L, Kumar S, Behera A, et al. Pseudoaneurysm of the cystic artery: a rare cause of hemobilia. *Am J Gastroenterol* 1998; 93: 1535–1537. DOI: 10.1111/j.1572-0241.1998.475\_y.x.
  21. Lee SL and Caruso DM. Acute cholecystitis secondary to hemobilia. *J Laparoendosc Adv Surg Tech A* 1999; 9: 347–349. DOI: 10.1089/lap.1999.9.347.