



## Case report

# Fertility sparing treatment of vaginal clear cell adenocarcinoma in a DES-Naïve young woman

Melissa Elizabeth Chambers<sup>a,\*</sup>, Robert Bristow<sup>b</sup>, Jill Tseng<sup>b</sup>

<sup>a</sup> Department of Obstetrics and Gynecology, University of California Irvine, Orange 92868, USA

<sup>b</sup> Department of Gynecologic Oncology, University of California Irvine, Orange 92868, USA

## ARTICLE INFO

## Keywords:

Women's health  
Vaginal clear cell adenocarcinoma  
Fertility-sparing  
Surgery  
Early stage

## ABSTRACT

**Background:** Primary vaginal cancer is rare and comprises 1–2% of female genital tract cancers. Among the types of vaginal cancer, adenocarcinoma accounts for only 10% with the peak incidence in women less than 20 years old. Clear cell type vaginal adenocarcinoma is most associated with exposure to diethylstilbestrol (DES) in-utero. **Case:** We present a case of an 18-year-old nulliparous woman, DES-exposure naïve, who was diagnosed with stage I clear cell vaginal adenocarcinoma during a routine pelvic exam for abnormal vaginal bleeding. She underwent a fertility-preserving radical vaginectomy and pelvic lymphadenectomy with neovagina creation and uterovaginal cervical reconstruction. She has been without disease for 28 months.

**Conclusion:** Although rare, vaginal cancer can be diagnosed on routine women's health exams. Early screening and diagnosis allow for innovative fertility-preserving surgical approaches without compromising oncologic outcomes. To our knowledge, this is the first case of a fertility-preserving radical vaginectomy, neovagina creation using a vertical rectus abdominis myocutaneous (VRAM) flap, and uterocervicovaginal reconstruction to successfully treat early stage clear cell vaginal adenocarcinoma with surgery alone, sparing the patient from adjuvant chemotherapy or radiation.

## 1. Introduction

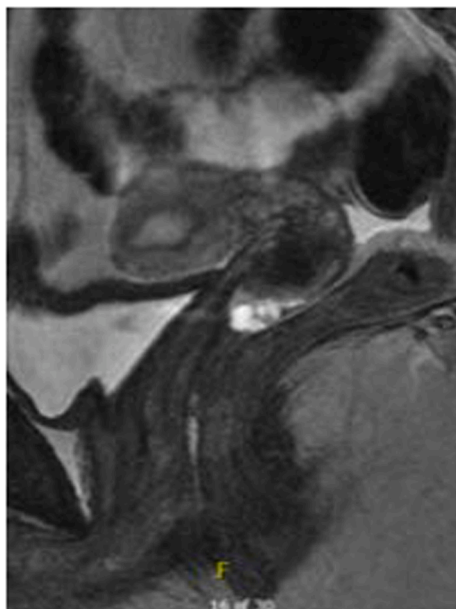
Primary vaginal cancer is rare and comprises 1–2% of female genital tract cancers (Adams et al., 2021). Among all types of vaginal cancer, adenocarcinoma accounts for only 10% with the peak incidence in women less than 20 years old<sup>1</sup>. Clear cell vaginal adenocarcinoma is most commonly associated with exposure to diethylstilbestrol (DES) in-utero. We present a case of an 18-year-old nulliparous woman without known DES exposure who was diagnosed with stage I clear cell vaginal adenocarcinoma and underwent a fertility-preserving radical vaginectomy with uterocervicovaginal reconstruction. This case demonstrates the importance of annual women's health exams in diagnosing early-stage cancer. Additionally, it highlights the importance of a multidisciplinary team in developing novel surgical approaches to managing vaginal cancer young women desiring future fertility.

## 2. Case

We present a case of an 18-year-old nulliparous woman who initially presented to her benign gynecologist with post-coital bleeding for one

year. Pelvic examination revealed a posterior vaginal lesion and a biopsy was performed. Pathology demonstrated a high-grade clear cell vaginal adenocarcinoma. One month later, she presented to the gynecology oncology clinic where she was found to have a well-circumscribed, irregular, friable lesion measuring 2.5 cm × 1.5 cm along the mid to proximal posterior wall of the vagina without palpable rectal invasion or cervical involvement. An MRI demonstrated an aggregate of cystic lesions measuring 10 mm × 19 mm × 16 mm in the posterior wall of the vagina adjacent to the cervix with no mural nodularity or internal contrast enhancement (Fig. 1). Because the lesion was confined to the vagina measuring greater than 2 cm, it was characterized as a stage IB lesion. Computed tomography (CT) imaging of the chest showed no evidence of metastasis to the lungs. A multidisciplinary discussion was held between gynecologic oncology, plastic surgery, radiation oncology, radiology, and pathology to determine the optimal treatment modality. Given her clinical and radiographically early-stage disease and desire for future fertility, the decision was made to proceed with a radical vaginectomy and pelvic lymphadenectomy with vaginal reconstruction rather than pelvic radiotherapy. The patient subsequently underwent a fertility-preserving radical vaginectomy with resection of the upper and

\* Corresponding author at: Department of Obstetrics and Gynecology, University of California, Irvine, 3800 West Chapman Ave #3400, Orange, CA 92868, USA.  
E-mail addresses: [mechambe@hs.uci.edu](mailto:mechambe@hs.uci.edu) (M.E. Chambers), [rbristow@hs.uci.edu](mailto:rbristow@hs.uci.edu) (R. Bristow), [jillt2@hs.uci.edu](mailto:jillt2@hs.uci.edu) (J. Tseng).



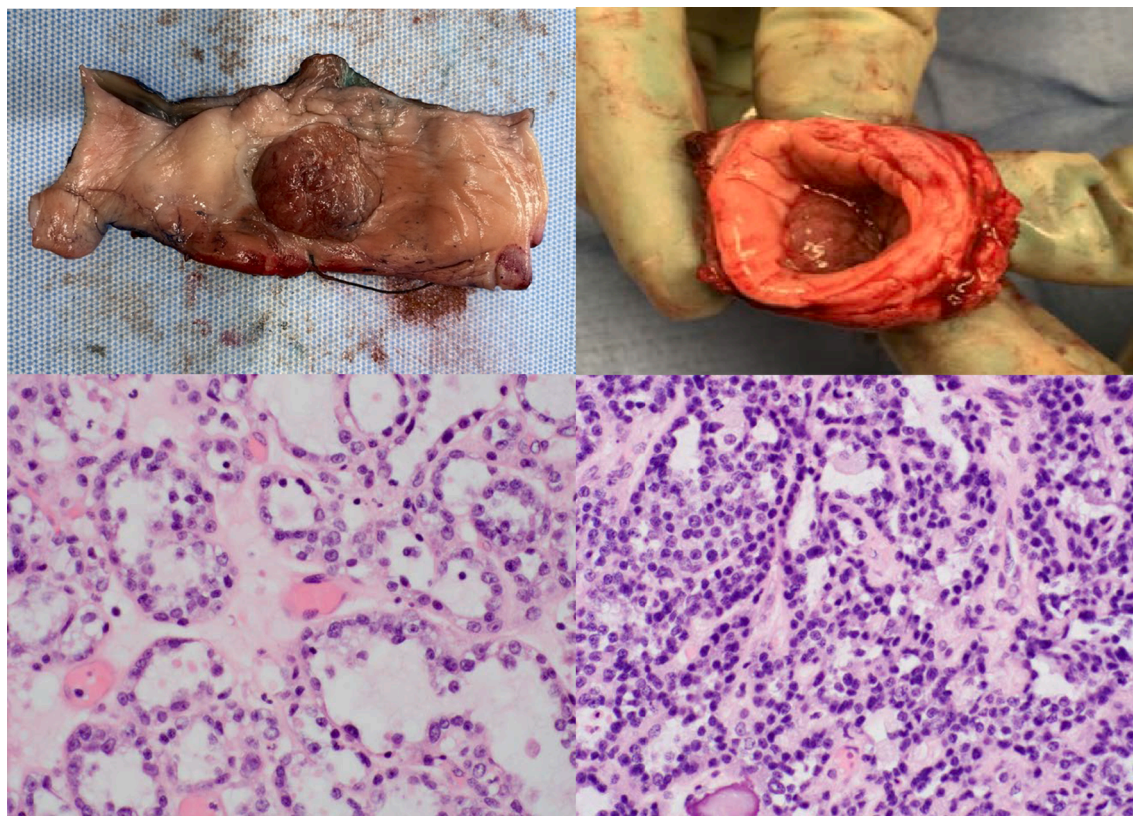
**Fig. 1.** A T2 weighted image of the patient's clear cell vaginal carcinoma. The MRI demonstrates an aggregate of cystic lesions measuring 10 mm × 19 mm × 16 mm in the posterior wall of the vagina adjacent to the cervix with no mural nodularity or internal contrast enhancement. No invasion into the rectum seen.

mid-vagina and associated paravaginal tissue, pelvic lymphadenectomy, neovaginal creation with a vertical rectus abdominis myocutaneous (VRAM) flap, and uterocervicovaginal reconstruction. During surgery, the mid and upper vagina with associated paravaginal tissue were first resected with preservation of the uterine arteries (Fig. 2). The VRAM

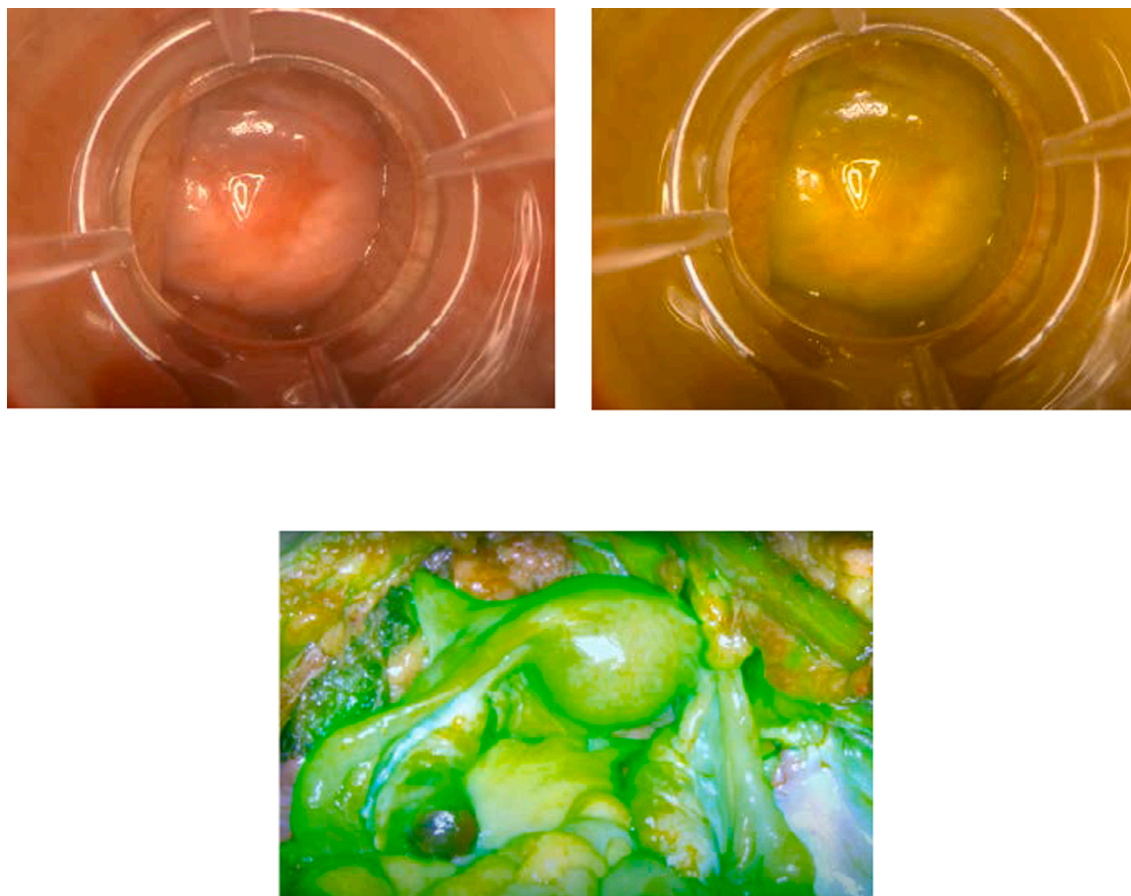
flap was then harvested, configured cylindrically and sutured to the distal vagina. Finally, the uterus and cervix were sutured to the proximal aspect of the neovagina. Intra-operative Near Infrared (NIR) Imaging with Indocyanine-Green dye (ICG) demonstrated excellent perfusion of the uterus, cervix, ovaries and neovagina (Fig. 3). Final pathology revealed a stage IB clear cell carcinoma measuring 2.2 cm in the greatest dimension, with 19 negative lymph nodes and negative margins (Fig. 2). The tumor was sent for molecular sequencing and is currently pending. The patient did well post-operatively and was discharged home on day 7. One week later, she was readmitted to the hospital with fevers and leukocytosis. A CT scan of the abdomen and pelvis demonstrated a non-drainable pelvic collection that was successfully treated with 3 weeks of intravenous antibiotics. The patient has subsequently been followed with clinical exam as well as alternating MRI and PET scans every 3 months with no evidence of recurrence. She resumed her menstrual cycles and has now been disease-free for 28 months.

### 3. Discussion

Primary vaginal cancer is rare and comprises 1–2% of female genital tract cancers (Adams et al., 2021). Amongst the types of vaginal cancer, adenocarcinoma accounts for only 10% (Adams et al., 2021). Clear cell vaginal adenocarcinoma is most associated with exposure to diethylstilbestrol (DES) in-utero. The incidence has been reported to be in 1/1000 cases of in-utero DES exposure (Trimble et al., 1996) and roughly 67% of cases have been diagnosed in women exposed to DES in-utero (Uehara et al., 2010). DES is a synthetic estrogen that was prescribed to pregnant women between 1940 and 1971 and was thought to prevent miscarriage and preterm birth. Although there is reportedly a strong association between DES and development of vaginal adenocarcinoma of the fetus (Monaghan and Sirisena, 1978; Keller et al., 2001), there have been few cases of vaginal adenocarcinoma in the absence of DES



**Fig. 2.** Radical vaginectomy specimen with cystic lesion representing clear cell adenocarcinoma. Histologic evidence of clear cell adenocarcinoma of the vagina: cystic pattern with clear cytoplasm and hobnail cells (left) and solid pattern with hyaline bodies (right).



**Fig. 3.** A. Transvaginal view of the uterocervicovaginal reconstruction. B. Demonstration of perfusion of the cervix and VRAM flap after vaginal resection with uterocervicovaginal reconstruction using ICG and NIR imaging. C. NIR intra-abdominally demonstrating excellent perfusion of the uterus, fallopian tubes, and ovaries with preserved ascending branches of the bilateral uterine arteries after vaginal resection with uterocervicovaginal reconstruction. **NIR:** Near Infrared; **ICG:** Indocyanine Green; **VRAM:** vertical rectus abdominis myocutaneous. (For interpretation of the references to colour in this figure legend, the reader is referred to the web version of this article.)

exposure (Uehara et al., 2010; Ikeda et al., 2014; Alipour et al., 2008; Zeeshan-ud-din, 2009) including the case presented here.

While vaginal clear cell adenocarcinoma is rare, it most commonly affects young women in their 2nd decade (Adams et al., 2021). Therefore, it is essential to educate young women on the importance of annual health examinations and symptoms of concern. In this case, the diagnosis was made by a women's health provider at Planned Parenthood after one year of post-coital bleeding. However, 14% percent of vaginal carcinoma cases reported no symptoms and were diagnosed incidentally on routine pap smear and pelvic examination (Underwood and Smith, 1971). Therefore, primary care providers, pediatricians, general obstetricians and gynecologists, and other women's healthcare providers are encouraged to perform annual well woman visits with a thorough patient history and pelvic examination. By taking a thorough history and implementing appropriate routine screening, clinicians will have the opportunity to detect disease earlier, treat appropriately, and possibly preserve a women's fertility.

This case also highlights the importance of having a multidisciplinary approach to care. Collaborative efforts between gynecologic oncologists, plastic surgeons, radiation oncologists, radiologists, and pathologists with the ability to develop innovative care plans for complex cases can have tremendous patient benefits, to both oncologic outcomes and quality of life. Because of the rarity of vaginal clear cell adenocarcinoma and lack of an established standard of care, an integrative and creative approach was even more crucial for our patient. Historically, most early-stage disease has been successfully treated with a combination of surgery and chemoradiation. Several such cases have

been reported of young nulliparous women with early-stage disease desiring future fertility being successfully treated from an oncologic standpoint. One case of a 28 year-old woman with stage I disease treated with wide local excision, lymph node dissection and adjuvant pelvic radiation was followed for five years without evidence of disease recurrence (Di Cello et al., 2019). Another case of a 24-year-old woman with early-stage disease treated with pelvic lymphadenectomy, omentectomy, extra pelvic transposition of ovaries followed by brachytherapy was followed for six years without disease recurrence (Vlachos et al., 2021). In a study examining three treatment modalities (surgery, radiation, surgery and radiation) for patients with Stage II disease, they found no significant difference in recurrence or survival rates (Senekjian et al., 1988). However, a more recent study (Nomura et al., 2023) concluded that surgery alone for early-stage non-squamous cell carcinoma of the vagina had a five-year local control rate of 75% and 100% for stage I and stage II respectively, and survival rates of 81% and 100% for stage I and stage II, respectively.

Amongst fertility sparing cases, none utilizing reconstructive surgery with VRAM flap neovagina creation has been reported. We report the first case to our knowledge of a fertility-preserving radical vaginectomy with neovaginal creation using a vertical rectus abdominis myocutaneous (VRAM) flap and uterocervicovaginal reconstruction. This innovative approach for early-stage vaginal cancer incorporates fertility preservation and prioritizes the patient's quality of life while minimizing the effects of chemotherapy or radiation treatment. This approach has shown to be successful as this patient has had 28 months without disease recurrence.

Written informed consent was obtained from the patient for publication of this case report and accompanying images. A copy of the written consent is available for review by the Editor-in-Chief of this journal on request.

#### CRedit authorship contribution statement

**Melissa Elizabeth Chambers:** Writing - original draft, Writing - review & editing. **Robert Bristow:** Conceptualization, Supervision. **Jill Tseng:** Conceptualization, Supervision, Writing - original draft, Writing - review & editing.

#### Declaration of Competing Interest

The authors declare that they have no known competing financial interests or personal relationships that could have appeared to influence the work reported in this paper.

#### References

- Adams, T.S., Rogers, L.J., Cuello, M.A., 2021. Cancer of the vagina: 2021 update. *Int. J. Gynecol. Obstet.* 155 (S1), 19–27. <https://doi.org/10.1002/IJGO.13867>.
- Alipour, P., Arjmandi, K., Hallaji, F., 2008. Vaginal clear cell adenocarcinoma with early pulmonary metastasis in a child. *Pediatr. Hematol. Oncol.* 25 (7), 679–684. <https://doi.org/10.1080/08880010802313723>.
- Di Cello, A., Quaresima, P., Bitonti, G., Zullo, F., Visconti, F., 2019. Vaginal clear cell adenocarcinoma in a young woman with a Müllerian duct anomaly and no history of in utero diethylstilbestrol exposure: a fertility-sparing approach. *Eur. J. Gynaecol. Oncol.* 40 (2), 334–336. [https://doi.org/10.12892/EJGO4517.2019/0392-2936-40-2-334/IMG\\_3.PNG](https://doi.org/10.12892/EJGO4517.2019/0392-2936-40-2-334/IMG_3.PNG).
- Ikeda, Y., Oda, K., Aburatani, H., Kawana, K., Osuga, Y., Fujii, T., 2014. Non-diethylstilbestrol exposed vaginal clear cell adenocarcinoma has a common molecular profile with ovarian clear cell adenocarcinoma: a case report. *Gynecol. Oncol. Reports* 10, 49. <https://doi.org/10.1016/J.GYNOR.2014.05.006>.
- Keller, C., Nanda, R., Shannon, R.L., Amit, A., Kaplan, A.L., 2001. Concurrent primaries of vaginal clear cell adenocarcinoma and endometrial adenocarcinoma in a 39-year old woman with in utero diethylstilbestrol exposure. *Int. J. Gynecol. Cancer* 11 (3), 247–250. <https://doi.org/10.1136/IJGC-00009577-200105000-00016>.
- Monaghan, J.M., Sirisena, L.A.W., 1978. Stilboestrol and vaginal clear-cell adenocarcinoma syndrome. *Br. Med. J.* 1 (6127), 1588–1590. <https://doi.org/10.1136/BMJ.1.6127.1588>.
- Nomura, H., Tanaka, Y., Omi, M., et al., 1234. Surgical outcomes of early-stage primary vaginal nonsquamous cell carcinoma. *Int. J. Clin. Oncol.* 25, 1412–1417. doi: 10.1007/s10147-020-01663-4.
- Senekjian, E.K., Frey, K.W., Stone, C., Herbst, A.L., 1988. An evaluation of stage II vaginal clear cell adenocarcinoma according to substages. *Gynecol. Oncol.* 31 (1), 56–64. [https://doi.org/10.1016/0090-8258\(88\)90269-7](https://doi.org/10.1016/0090-8258(88)90269-7).
- Trimble, E.L., Rubinstein, L.V., Menck, H.R., Hankey, B.F., Kosary, C., Giusti, R.M., 1996. Vaginal clear cell adenocarcinoma in the United States. *Gynecol. Oncol.* 61 (1), 113–115. <https://doi.org/10.1006/GYNO.1996.0107>.
- Uehara, T., Onda, T., Sasajima, Y., Sawada, M., Kasamatsu, T., 2010. A case of vaginal clear cell adenocarcinoma complicated with congenital anomalies of the genitourinary tract and metanephric remnant without prenatal diethylstilbestrol exposure. *J. Obstet. Gynaecol. Res.* 36 (3), 681–685. <https://doi.org/10.1111/J.1447-0756.2010.01178.X>.
- Underwood, P.B., Smith, R.T., 1971. Carcinoma of the vagina. *J. Am. Med. Assoc.* 217 (1), 46–52. <https://doi.org/10.1001/JAMA.1971.03190010028006>.
- Vlachos, D.E., Protopapas, A., Vlachos, G., et al., 2021. Menstrual function preservation treatment of a primary vaginal clear cell carcinoma with ovarian transposition and vaginal brachytherapy. *Gynecol. Oncol. Reports* 36, 100764. <https://doi.org/10.1016/J.GORE.2021.100764>.
- Zeeshan-ud-din, A.A., 2009. Vaginal clear cell adenocarcinoma with associated Mullerian duct anomalies, renal agenesis and situs inversus: report of a case with no known in-utero exposure with diethyl stilboestrol. *J. Pak. Med. Assoc.* 59 (8). Available from: <[https://ecommons.aku.edu/pakistan\\_fhs\\_mc\\_pathol\\_microbiol/35](https://ecommons.aku.edu/pakistan_fhs_mc_pathol_microbiol/35)>. Accessed October 10, 2022.