

Crouzon syndrome - A rare case report

Vidhya Kalanjiam,
G. V. Murali Gopika Manoharan

Department of Oral Medicine and Radiology,
Tamil Nadu Government Dental College and
Hospital, Chennai, Tamil Nadu, India

Address for correspondence:

Dr. Vidhya Kalanjiam,
No 4, Elango Street,
J.B. Nagar, R.C.C. [Post],
Avadi, Chennai - 600 109, Tamil Nadu, India.
Phone: +91-8056288034.
E-mail: vidhya.kalanjiam@gmail.com

WEBSITE: ijhs.org.sa

ISSN: 1658-3639

PUBLISHER: Qassim University

ABSTRACT

Crouzon syndrome is the most common syndrome among the craniosynostosis group. Crouzon syndrome accounts for about 4.8% of all of them. It commonly has autosomal dominant inheritance with complete penetrance and variable expressivity from subtle to severe forms and characterized by craniosynostosis, exophthalmos, and hypoplastic maxilla with relative mandibular prognathism. Mutation of the fibroblast growth factor receptor-2 gene is responsible for the occurrence of this rare genetic disorder. Our paper reports the diagnosis of this rare syndrome in a young female patient based on clinical and radiographical features. Prompt and timely management of the syndrome has enabled this patient to lead a normal life despite the syndrome.

Keywords: Craniofacial dysostosis, craniosynostosis, crouzon syndrome, exophthalmos

Introduction

Premature fusion of one or more sutures results in craniofacial malformation called craniosynostosis.¹ Craniosynostosis restricts the growth of the brain perpendicular to the suture, and so compensatory growth takes place in the direction of open sutures. This asymmetrical growth alters the shape of the cranial base and the vault, resulting in characteristic deformities. More than 100 syndromes are associated with craniosynostosis - some of them are - Crouzon syndrome, Apert syndrome, Pfeiffer syndrome, Carpenter syndrome, Saethre-Chotzen syndrome, and Jackson-Weiss syndrome.²

Case Report

A 4-year-old female patient reported with the chief complaint of protrusion of lower jaw. History revealed that the parents noticed the developing protrusion of lower jaw when she was around 1 year old, and it has been progressively increasing since then. Her mother also reported that the child cries a lot and frequently rubs her eyes with complaints of headache. Past medical, past surgical, past dental history, and family history were not contributory.

On extraoral examination, the patient had frontal bossing, asymmetrical skull growth, exophthalmos, hypertelorism, wide nasal bridge, low-set ears, and hypoplastic maxilla with relative mandibular prognathism (Figure 1). The orthopantomogram revealed the presence of deciduous and succedaneous teeth with no obvious abnormality. Lateral view

and PA view of skull demonstrated copper beaten appearance indicating the remodeling of the brain due to the increased intracranial pressure due to fused sutures (Figure 1). Computed tomography scan and three-dimensional reconstruction revealed prominent convolutions in the inner table of the skull and shallow orbit with exophthalmos and fusion of right coronal suture, and multiple small holes were noted in the occipital and right temporal bones, which suggested unilateral anterior plagiocephaly (Figure 1). Based on these, the case was diagnosed as Crouzon syndrome.

Discussion

In 1912, a French neurologist Octave Crouzon was the first to describe Crouzon syndrome. It occurs due to mutation in fibroblast growth factor receptor II (FGFR-2) gene mapped on the chromosome loci 10q25-10q26.³ The prevalence rate of this syndrome is approximately 1 in 25,000 live births.⁴

Early prenatal diagnosis such as prenatal DNA testing for mutation of FGFR-2 gene and prenatal ultrasonography may be useful in providing indications of forthcoming developmental problems, thus providing the option of termination or optimal postnatal management for families who choose to continue the pregnancy.⁵

Very little documentation exists on the quality of life such patients can lead after the treatment. In this case, the patient was diagnosed during the early stages of this syndrome when the symptoms were just setting in. The treatment thus provided to the patient has proven to be very effective, and during follow-up, it has been documented that the patient

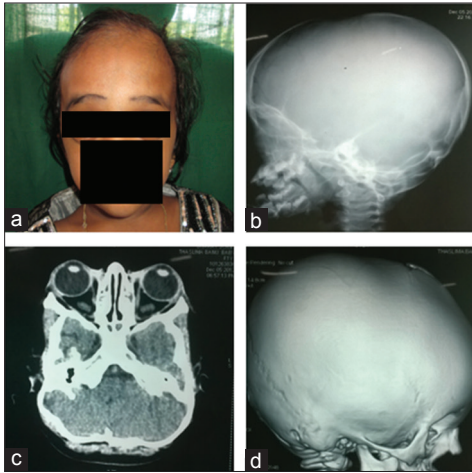


Figure 1: (a-d) Extraoral, lateral skull radiograph, and computed tomography scan of the patient

has been able to lead a symptom-free normal life with no evidence of mental retardation, ocular changes, headache,

etc. Craniectomy done to release the fused sutures provided adequate cranial volume and allowed normal brain growth. Further treatment like midface deficiency correction at the appropriate time can help to bring a more normal facial appearance.

References

1. Cohen MM Jr. Craniosynostosis and syndromes with craniosynostosis: Incidence, genetics, penetrance, variability, and new syndrome updating. *Birth Defects Orig Artic Ser* 1979;15:13-63.
2. Panigrahi I. Craniosynostosis genetics: The mystery unfolds. *Indian J Hum Genet* 2011;17:48-53.
3. Reardon W, Winter RM, Rutland P, Pulleyn LJ, Jones BM, Malcolm S. Mutations in the fibroblast growth factor receptor 2 gene cause Crouzon syndrome. *Nat Genet* 1994;8:98-103.
4. Cohen MM Jr. Craniosynostosis update 1987. *Am J Med Genet Suppl* 1988;4:99-148.
5. Phupong V, Srichomthong C, Shotelersuk V. Prenatal exclusion of Crouzon syndrome by mutation analysis of FGFR2. *Southeast Asian J Trop Med Public Health* 2004;35:977-9.