

Treatment of Grade II and III Actinic Keratosis Lesions with a Film-Forming Medical Device Containing Sunscreen/Piroxicam 0.8% and a Retinoic Acid/Glycolic Gel: A Pilot Trial

Mario Puviani · Massimo Milani

Received: April 23, 2018 / Published online: May 31, 2018
© The Author(s) 2018

ABSTRACT

Introduction: Lesion and field-targeted treatments of actinic keratosis (AK) are commonly indicated for grade I and II type lesions. Grade III lesions are in general more difficult to treat. A film-forming medical device containing piroxicam 0.8% and sunscreen (SPF 50+) (PS) has been shown to be effective in the treatment of grade I and II AK lesions. Topical and oral retinoids have been utilized in AK and non-melanoma skin cancers. Topical glycolic acid promotes keratolysis and stimulates collagen synthesis for repair and skin rejuvenation and could be useful in AK treatment strategies. A gel containing retinoid acid (0.02%) and glycolic acid (4%) (RC) is commercially available. The objective of the study was to evaluate the efficacy and local tolerability of a combined treatment approach with PS and RC in subjects with multiple grade II and III AK lesions.

Enhanced digital features To view enhanced digital features for this article, go to <https://doi.org/10.6084/m9.figshare.6292316>.

M. Puviani · M. Milani (✉)
Dermatology Division, Sassuolo Hospital, Sassuolo, Italy
e-mail: massimo.milani@difacooper.com

M. Puviani · M. Milani
Medical Department, Cantabria Labs Difa Cooper, Caronno Pertusella, VA, Italy

Methods: Twenty-two subjects (16 males and 6 females; mean age 68 years) with more than five AK lesions were enrolled after obtaining their informed consent in a 3-month trial. PS cream was applied twice daily every day and RC gel was applied twice daily for 2 consecutive days every week. The primary endpoint was the evolution of the AK mean number from baseline to the end of the trial. Secondary endpoints were the thickness of the target lesion (expressed in mm³) and the erythema score (hemoglobin content), evaluated using a standardized computer-based image acquisition analysis system (Anthera 3D).

Results: At baseline, the mean (SD) lesion number was 7.7 (3) for grade II and 1.4 (1) for grade III AK. At the end of the study, a significant ($P = 0.001$) reduction was observed for both grade II (– 81%; from 7.7 to 1.5) and grade III (– 22%) lesions. Six grade III lesions out of 31 (20%), presented at baseline, completely disappeared at month 3. For grade III lesions, a significant mean thickness reduction of 51% was observed at month 3. The erythema score (all lesions) was reduced by 70%. Four patients out of 22 (18%) were completely free of AK lesions at month 3. No severe side effects were reported.

Conclusion: In this exploratory trial, a combined treatment with a cream containing piroxicam and sunscreen and a retinoic/glycolic gel was associated with a substantial reduction

of both grade II and III AK lesions with good local tolerability.

Funding: Cantabria Labs Difa Cooper.

Keywords: Actinic Keratosis; Pilot trial; Piroxicam; Sunscreens; Retinoids

INTRODUCTION

Actinic keratosis (AK) is a very common cause of dermatologic consultation [1]. AK presents a strong association with squamous cell carcinoma and is now considered an in situ non-melanoma skin cancer form caused by chronic sun exposure [2–4]. AKs are defined as keratinocyte intraepithelial neoplasia (KIN) with different grades of alteration: grade I with mild, grade II with moderate and grade III with severe atypical keratinocytes [5]. From a clinical point of view, grade I AK lesions are described as flat pink maculae without signs of hyperkeratosis and erythema often easier felt than seen, grade II lesions as moderately thick and easily felt and seen, and grade III AKs as very thick hyperkeratotic lesions [6]. Sunscreen protection in subjects with AK is considered a key factor in preventing the clinical evolution of this condition, reducing the risk of new AK lesion development [7]. Increased cyclooxygenase enzyme (both COX-2 and COX-1) activity at the keratinocyte level plays a relevant role [8, 9] in the pathogenesis and evolution of AK. Furthermore, the use of topical anti-cyclooxygenase drugs, such as diclofenac [10] and recently piroxicam [11], has been shown to reduce the lesion number and improve the cancerization field in subjects with AK and actinic damage. Two controlled trials [12] involving more than 100 AK subjects have shown that using a topical formulation containing piroxicam 0.8% and sunscreens with SPF protection of 50+ is effective in reducing the number of grade I and II AK lesions by up to 55% compared with baseline. Topical and oral retinoids have been utilized in AK and non-melanoma skin cancers as both treatment and prevention [13]. Lesion and field-targeted treatments of AK are commonly indicated for grade I and II lesions [14]. Grade III lesions are in general more difficult to treat [15].

Topical glycolic acid promotes keratolysis and stimulates collagen synthesis for repair and skin rejuvenation, and it could be useful in AK treatment strategies [16]. Keratolytic agents such as salicylic acid are sometimes used as a preliminary treatment to remove overlying keratin in hyperproliferative AK lesions [17]. A gel containing retinoid acid (0.02%), glycolic acid (4%) and polyvinyl alcohol (0.20%) (RC) (Retincare Gel; Cantabria Labs Difa Cooper; Italy) is commercially available. Retinoids and glycolic acid could be useful in reducing the hyperkeratosis of grade III AK lesions.

Study Aim

We investigated the efficacy and local tolerability of the combination of piroxicam/sunscreen 50+ (PS) cream and a topical retinoid, glycolic acid gel (RC), in the treatment of grade II and III AK lesions.

METHODS

Subjects

The study was performed in a second-level outpatient dermatology clinic in Italy. The study was approved by the human research committee of the institution, and written informed consent was requested and received from all subjects in the study. The study was carried out between January and December 2017. Eligibility criteria included an age \geq 18 years and the presence of multiple AK lesions on the face, scalp, trunk or extremities. Patients were excluded from the study if they had recently received previous treatments interfering with the evaluation of the treatment area (topical medications, immunosuppressive or immunomodulating agents, phototherapy, oral retinoids or other therapies for AKs). Pregnancy and breast-feeding were also exclusion criteria. Twenty-two subjects (16 males and 6 females; mean age 68 years) with $>$ 5 AK lesions were enrolled in this 3-month pilot trial. All procedures performed in this trial were done in accordance with the ethical standards of the

institutional and/or national research committee and with the 1964 Helsinki Declaration and its later amendments or comparable ethical standards. Informed consent was obtained from all individual participants included in the study.

Treatments

PS cream was applied twice daily every day, and RC gel was applied twice daily for 2 consecutive days every week (Saturday and Sunday). All patients were instructed to self-apply the products (PS cream and RC) on the target AK lesion as well as on the perilesional field cancerization in a pre-specified 35-cm² area using a finger-tip unit (0.5 g) for each application.

Outcomes

The primary endpoint was the clinical evolution of the AK mean number from baseline to the end of the trial. Secondary endpoints were the thickness of the target lesion and the erythema score evaluated using a standardized computer-based image acquisition analysis system (Antera 3D CS; Miravex, Dublin, Ireland). Antera 3D CS pictures were taken at baseline and after 3 months. The Antera 3D CS image system could measure the volume and the hemoglobin content (as a surrogate parameter for erythema) of a skin lesion of a prespecified area in an objective and operator-independent manner [18].

Statistical Analysis

Statistical analysis was performed using GraphPad Statistical Software (GraphPad Software, Inc., La Jolla, CA, USA). Continuous variables were expressed as mean \pm standard deviation (SD). The primary outcomes of the study were to evaluate the evolution of the AK lesion number using a paired non-parametric test (Wilcoxon test) comparing baseline with end-of-treatment values. In view of the proof-of-concept nature of the present trial, a formal sample size calculation was not performed. We decided to enroll at least 20 evaluable subjects.

RESULTS

Twenty-two subjects (16 males and 6 females; mean age 65 years) participated in this trial. All the subjects concluded the 3-month observation period. At baseline, the mean (SD) lesion number was 7.7 (3), range 2–19, for grade II and 1.7 (1), range 1–4, for grade III AK. Grade III lesions were detected in 19 out of 22 subjects (86%) for a total of 31 lesions. At the end of the study, a significant ($P = 0.0001$; Wilcoxon test) reduction was observed for both grade II (-81% ; from 7.7 to 1.5) (Fig. 1) and grade III (-22%) lesions (from 1.7 to 1.3; 0.019 Wilcoxon test) (Fig. 2). Six of 31 (20%) grade III lesions presenting at baseline completely disappeared at month 3 (Fig. 3). In addition, for grade III lesions, a 59% mean volume reduction of lesion thickness was observed at month 3 compared with baseline from 4.1 to 1.7 mm³ (Fig. 4). The erythema score, evaluated as the hemoglobin content of the target lesion, was reduced by 70% (all lesions). Four patients out of 22 (18%) were completely free of lesions at month 3. The two products were well tolerated; no severe side effects were reported supporting the good local tolerability of this therapeutic approach.

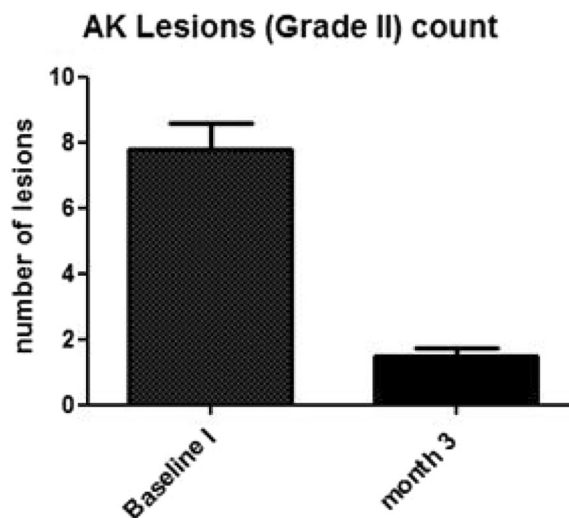


Fig. 1 Evolution of the AK lesion count of grade II from baseline to month 3 ($P = 0.0001$; Wilcoxon test)

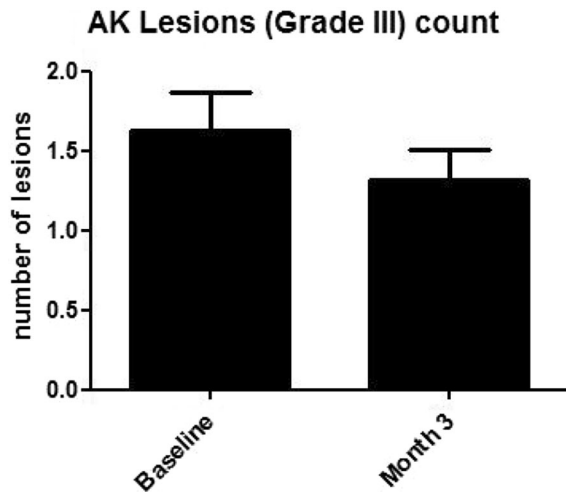


Fig. 2 Evolution of the AK lesion count of grade III from baseline to month 3 ($P = 0.019$; Wilcoxon test)

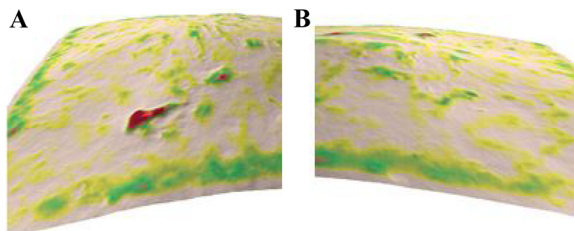


Fig. 3 A grade III lesion evaluated with Anthera 3D at baseline (a), which disappeared after 3 months of treatment (b)

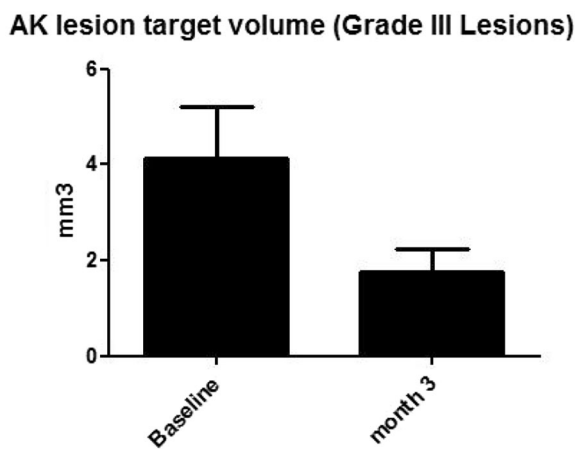


Fig. 4 AK grade III lesion target volume evaluated using Anthera 3D imaging analysis ($P = 0.0156$; Wilcoxon test)

DISCUSSION

AK is a common UV-induced scaly or hyperkeratotic skin lesion [19]. AKs are typically detected on sun-damaged skin areas like the face, ear lobes and dorsum of the hands, with a predominance on the male scalp [20]. The main goals of AK treatments are to reduce the lesion number, improve the cosmetic appearance of the involved area and above all to reduce the risk of new AK lesion formation, which in turn could be linked to a risk reduction of malignant evolution (i.e., squamous cell carcinoma) [21]. Several therapeutic strategies are available for treatment of both lesions and field cancerization such as topical compounds like diclofenac, piroxicam, 5-FU and imiquimod or ablative strategies such as curettage, cryotherapy, traditional and daylight photodynamic therapy [22]. These therapeutic approaches are in general very effective in reducing grade I and II AK. Grade III AK lesions remain a therapeutic challenge. Only curettage and cryotherapy are so far recommended for the treatment of AK grade III lesions [23]. In our pilot study, the combination of a topical product containing piroxicam and sunscreens and a product containing a retinoid and a keratolytic agents was able to reduce grade II AK lesions up to -80% . A significant and clinically relevant reduction (-22%) of AK was also observed for grade III lesions even if the efficacy was lower compared with grade II AK lesions. Interestingly, this combined topical treatment reduced the thickness of AK grade III lesions by 51% compared with baseline. The use of topical piroxicam and sunscreen has been shown to be effective in reducing AK lesions also in subjects with solid transplant organs [24]. The use of systemic and topical retinoids is considered of clinical value in the treatment and prevention of non-melanoma skin cancers and AK [25]. Retinoids have anti-proliferative and anti-apoptotic properties, interfering in the process of tumor initiation [26, 27]. The therapeutic strategy we utilized in this study could also have a role in preparation of the cancerization field before photodynamic therapies or other ablative strategies. Reducing the burden of AK lesions (both grade II and III) could in fact

increase the success rate for complete clearance in PDT/ablative treatment options. This latter point should be demonstrated by performing specific controlled clinical trials. Some study limitations should be taken in account evaluating the study results. First, this was not a double-blind trial, and there was not a control group. However, the present study was a pilot proof-of-concept trial. Further larger prospective controlled studies are warranted to evaluate whether this combined therapeutic strategy could be helpful in the management of “difficult” AK lesions such as grade III. In addition, the lesion thickness and erythema values (secondary outcomes of the present study) were evaluated in an objective manner (computer analysis of standardized acquired images). A second limit of the present study was the relatively short treatment period (3 months). However, the goal of our study was to evaluate the clinical efficacy of this therapeutic approach in the short term and also as an initial feasible stage in a more articulate multi-step therapeutic AK strategy.

CONCLUSIONS

In this exploratory trial, a combined treatment with a cream containing piroxicam and sunscreen and a retinoic/glycolic gel was associated with a substantial reduction in both the “target volume and count” of treated grade III AK lesions with good local tolerability.

ACKNOWLEDGEMENTS

Funding. The study was partially funded by Cantabria Labs Difa Cooper. Article processing charges were funded by Cantabria Labs Difa Cooper. All authors had full access to all of the data in this study and take complete responsibility for the integrity of the data and accuracy of the data analysis.

Authorship. All named authors meet the International Committee of Medical Journal Editors (ICMJE) criteria for authorship for this

article, take responsibility for the integrity of the work as a whole and have given their approval for this version to be published.

Disclosures. Massimo Milani is an employee of Cantabria Labs Difa Cooper, the Pharma Company selling the two products evaluated in this trial. Massimo Milani was not involved in the collection and statistical analysis of the study data. Mario Puviani has nothing to disclose.

Compliance with Ethics Guidelines. All procedures performed in studies involving human participants were in accordance with the ethical standards of the institutional and/or national research committee and with the 1964 Helsinki Declaration and its later amendments or comparable ethical standards. Informed consent was obtained from all individual participants included in the study.

Open Access. This article is distributed under the terms of the Creative Commons Attribution-NonCommercial 4.0 International License (<http://creativecommons.org/licenses/by-nc/4.0/>), which permits any noncommercial use, distribution, and reproduction in any medium, provided you give appropriate credit to the original author(s) and the source, provide a link to the Creative Commons license, and indicate if changes were made.

REFERENCES

1. Schmitt JV, Miot HA. Actinic keratosis: a clinical and epidemiological revision. *Anais brasileiros de dermatologia*. 2012;87(3):425–34.
2. Vitasa BC, Taylor HR, Strickland PT, Rosenthal FS, West S, Abbey H, et al. Association of non-melanoma skin cancer and actinic keratosis with cumulative solar ultraviolet exposure in Maryland watermen. *Cancer*. 1990;65(12):2811–7.
3. Ziegler A, Jonason AS, Leffell DJ, Simon JA. Sunburn and p53 in the onset of skin cancer. *Nature*. 1994;372(6508):773.
4. Röwert-Huber J, Patel MJ, Forschner T, Ulrich C, Eberle J, Kerl H, et al. Actinic keratosis is an early in situ squamous cell carcinoma: a proposal for reclassification. *Br J Dermatol*. 2007;156(s3):8–12.

5. Cockerell CJ. Histopathology of incipient intraepidermal squamous cell carcinoma (“actinic keratosis”). *J Am Acad Dermatol*. 2000;42:11–7.
6. Zalaudek I, Piana S, Moscarella E, Longo C, Zendri E, Castagnetti F, Argenziano G. Morphologic grading and treatment of facial actinic keratosis. *Clin Dermatol*. 2014;32(1):80–7.
7. Stockfleth E, Kerl H. Guidelines for the management of actinic keratoses. *Eur J Dermatol*. 2006;16(6):599–606.
8. Buckman SY, Gresham A, Hale P, Hruza G, Anast J, Masferrer J, Pentland AP. COX-2 expression is induced by UVB exposure in human skin: implications for the development of skin cancer. *Carcinogenesis*. 1998;19(5):723–9.
9. Seed MP, Freemantle CN, Alam CA, Colville-Nash PR, et al. Apoptosis induction and inhibition of colon-26 tumour growth and angiogenesis: findings on COX-1 and COX-2 inhibitors in vitro & in vivo and topical diclofenac in hyaluronan. In: Sinzinger H, Samuelsson B, Vane JR, Paoletti R, Ramwell P, Wong PY-K, editors. *Recent advances in prostaglandin, thromboxane, and leukotriene research*. New York: Springer, 1997. pp 339–342.
10. Nelson C, Rigel D, Smith S, Swanson N, Wolf J. Phase IV, open-label assessment of the treatment of actinic keratosis with 3.0% diclofenac sodium topical gel (Solaraze). *J Drugs Dermatol*. 2003;3(4):401–7.
11. Campione E, Diluvio L, Paterno EJ, Chimenti S. Topical treatment of actinic keratoses with piroxicam 1% gel. *Am J Clin Dermatol*. 2010;11(1):45–50.
12. Babino G, Diluvio L, Bianchi L, Orlandi A, Di Prete M, Chimenti S, Campione E. Long-term use of a new topical formulation containing piroxicam 0.8% and sunscreen: efficacy and tolerability on actinic keratosis. A proof of concept study. *Curr Med Res Opin*. 2016;32(8):1345–9.
13. Moon TE, Levine N, Cartmel B, Bangert JL, Rodney S, Dong Q, et al. Effect of retinol in preventing squamous cell skin cancer in moderate-risk subjects: a randomized, double-blind, controlled trial. Southwest Skin Cancer Prevention Study Group. *Cancer Epidemiol Prev Biomark*. 1997;6(11):949–56.
14. Szeimies RM, Karrera S, Radakovic-Fijanb S, Tanewb A, Calzavara-Pintonc PG, Zanec C, Mefferth H. Photodynamic therapy using topical methyl 5-aminolevulinate compared with cryotherapy for actinic keratosis: a prospective, randomized study. *J Am Acad Dermatol*. 2002;47(2):258–62.
15. Roewert-Huber J, Stockfleth E, Kerl H. Pathology and pathobiology of actinic (solar) keratosis—an update. *Br J Dermatol*. 2007;157(s2):18–20.
16. Moy LS, Murad H, Moy RL. Glycolic acid peels for the treatment of wrinkles and photoaging. *J Dermatol Surg Oncol*. 1993;19(3):243–6.
17. Swinehart JM. Salicylic acid ointment peeling of the hands and forearms: effective nonsurgical removal of pigmented lesions and actinic damage. *J Dermatol Surg Oncol*. 1992;18(6):495–8.
18. Linming F, Wei H, Anqi L, et al. Comparison of two skin imaging analysis instruments: the VISIA from Canfield vs the ANTERA 3D CS from Miravex. *Skin Res Technol*. 2018;24(1):3–8.
19. Fu W, Cockerell CJ. The actinic (solar) keratosis: a 21st-century perspective. *Arch Dermatol*. 2003;139(1):66–70.
20. Moy RL. Clinical presentation of actinic keratoses and squamous cell carcinoma. *J Am Acad Dermatol*. 2000;42(1):S8–10.
21. Dirschka T, Gupta G, Micali G, Stockfleth E, Basset-Séguin N, Del Marmol V, et al. Real-world approach to actinic keratosis management: practical treatment algorithm for office-based dermatology. *J Dermatol Treat*. 2017;28(5):431–42.
22. Jetter N, Chandan N, Wang S, Tsoukas M. Field Cancerization therapies for management of actinic keratosis: a narrative review. *Am J Clin Dermatol* 2018. <https://doi.org/10.1007/s40257-018-0348-7>.
23. De Berker D, McGregor JM, Hughes BR, British Association of Dermatologists Therapy Guidelines and Audit Subcommittee. Guidelines for the management of actinic keratoses. *Br J Dermatol*. 2007;156(2):222–30.
24. Garofalo V, Ventura A, Mazzilli S, Diluvio L, Bianchi L, Toti L, Campione E. Treatment of multiple actinic keratosis and field of cancerization with topical piroxicam 0.8% and sunscreen 50+ in organ transplant recipients: a series of 10 cases. *Case Rep Dermatol*. 2017;9(3):211–6.
25. Ianhez M, Fleury Junior LFF, Miot HA, Bagatin E. Retinoids for prevention and treatment of actinic keratosis. *Anais brasileiros de dermatologia*. 2013;88(4):585–93.
26. Lens M, Medenica L. Systemic retinoids in chemoprevention of non-melanoma skin cancer. *Expert Opin Pharmacother*. 2008;9(8):1363–74.
27. Mrass P, Rendl M, Mildner M, Gruber F, Lengauer B, Ballaun C, Tschachler E. Retinoic acid increases the expression of p53 and proapoptotic caspases and sensitizes keratinocytes to apoptosis: a possible explanation for tumor preventive action of retinoids. *Can Res*. 2004;64(18):6542–8.