

Subacute Thyroiditis After Sars-COV-2 Infection

Alessandro Brancatella,¹ Debora Ricci,¹ Nicola Viola,¹ Daniele Sgrò,¹ Ferruccio Santini,¹ and Francesco Latrofa¹

¹Endocrinology Unit I, Department of Clinical and Experimental Medicine, University Hospital of Pisa, Pisa 56127, Italy

ORCID numbers: 0000-0002-5615-6325 (A. Brancatella); 0000-0003-0297-5904 (F. Latrofa).

Context: Subacute thyroiditis (SAT) is a thyroid disease of viral or postviral origin. The severe acute respiratory syndrome coronavirus 2 (SARS-CoV-2) that began in Wuhan, China, has spread rapidly worldwide and Italy has been severely affected by this outbreak.

Objectives: The objective of this work is to report the first case of SAT related to SARS-CoV-2 infection.

Methods: We describe the clinical, laboratory, and imaging features of an 18-year-old woman who came to our attention for fever, neck pain radiated to the jaw, and palpitations occurring 15 days after a SARS-CoV-2–positive oropharyngeal swab. Coronavirus disease 2019 (COVID-19) had been mild and the patient had completely recovered in a few days.

Results: At physical examination the patient presented with a slightly increased heart rate and a painful and enlarged thyroid on palpation. At laboratory exams free thyroxine and free triiodothyronine were high, thyrotropin undetectable, and inflammatory markers and white blood cell count elevated. Bilateral and diffuse hypoechoic areas were detected at neck ultrasound. One month earlier, thyroid function and imaging both were normal. We diagnosed SAT and the patient started prednisone. Neck pain and fever recovered within 2 days and the remaining symptoms within 1 week. Thyroid function and inflammatory markers normalized in 40 days.

Conclusions: We report the first case of SAT after a SARS-CoV-2 infection. We alert clinicians to additional and unreported clinical manifestations associated with COVID-19. (*J Clin Endocrinol Metab* 105: 1–4, 2020)

Freeform/Key Words: subacute thyroiditis, coronavirus, COVID-19, SARS-CoV-2, thyroid, virus

Subacute thyroiditis (SAT) is a self-limited inflammatory thyroid disease characterized by neck pain, general symptoms, and thyroid dysfunction (1, 2). SAT is usually preceded by an upper respiratory tract infection. Direct and indirect evidence support a viral or postviral origin of this disease, and many viruses have been reported as potentially causative agents (3).

Since January 2020, coronavirus disease 2019 (COVID-19), caused by severe acute respiratory syndrome coronavirus 2 (SARS-CoV-2), has resulted in an emerging respiratory infection with a pandemics diffusion (4). Here, we report the first case of SAT in a patient affected by SARS-CoV-2.

ISSN Print 0021-972X ISSN Online 1945-7197

Printed in USA

© Endocrine Society 2020. All rights reserved. For permissions, please e-mail: journals.permissions@oup.com

Received 15 April 2020. Accepted 13 May 2020.

First Published Online 21 May 2020.

Corrected and Typeset 28 May 2020.

Abbreviations: COVID-19, coronavirus disease 2019; CRP, C-reactive protein; ESR, erythrocyte sedimentation rate; FT3, free triiodothyronine; FT4, free thyroxine; HLA, human leukocyte antigen; SARS-CoV-2, severe acute respiratory syndrome coronavirus 2; SAT, subacute thyroiditis; Tg, thyroglobulin; TgAb, thyroglobulin antibodies; TPOAb, thyroperoxidase antibodies; TSH, thyrotropin.

Material and Methods

Case presentation

On February 28, 2020, an 18-year-old woman underwent an oropharyngeal swab for SARS-CoV-2 on the evidence that his father, who lived with her, had been hospitalized 2 days earlier because of COVID-19. Her swab turned out to be positive. In the next few days, the woman developed mild upper respiratory symptoms (rhinorrhea and cough). She was left untreated and recovered completely in 4 days (Fig. 1). Two additional swabs for SARS-CoV-2 (March 13 and 14) both turned out to be negative.

On March 17, the patient presented with sudden fever (37.5 °C), fatigue, palpitations, and anterior neck pain radiating to the jaw (Fig. 1). Because of worsening of the neck pain, on March 19 the patient was referred to us. For the previous finding of isolated hyperthyrotropinemia, on February 21 she had undergone thyroid evaluation: Thyroid function was normal, antibodies to thyroglobulin (TgAb) and to thyroperoxidase (TPOAb) negative, and thyroid ultrasound unremarkable (Table 1).

Results

On March 19, at physical examination, the patient’s heart rate was 90 beats per minute and on palpation the thyroid gland was markedly painful and slightly tender and enlarged. The patient did not refer to any upper respiratory symptom. At laboratory exams, free thyroxine (FT4) and free triiodothyronine (FT3) were both mildly elevated, thyrotropin (TSH) undetectable, thyroglobulin (Tg) detectable at low level with positive TgAb. TPOAb and antibodies to the TSH receptor were negative. Erythrocyte sedimentation rate (ESR), C-reactive protein (CRP), and white cell blood count were high (Table 1). Thyroid ultrasound showed multiple, diffuse hypoechoic areas (Fig. 2). Thus, SAT was diagnosed and March 20 the patient started prednisone (25 mg/d). Neck pain and fever disappeared within 2 days and the remaining symptoms within 1 week

(Fig. 1). On April 1, FT4 concentration had declined to the upper normal range, TSH had risen to almost normal level, ESR was slightly elevated, and white cell blood count and CRP were normal (Table 1). Steroid was progressively tapered and at the last evaluation (April 27), while taking prednisone 16 mg/day, the patient was asymptomatic. Thyroid functional tests and inflammatory markers were normal (Fig. 1 and Table 1).

Discussion

SAT is a self-limited, inflammatory disorder characterized by neck pain and general symptoms, often associated with thyroid dysfunction (1, 2). Clinically, neck pain, frequently radiating to the upper neck, is the presenting symptom of SAT. On palpation, the thyroid is painful, tender, and enlarged. Systemic symptoms, including fever, fatigue, myalgia, and anorexia are common (1, 2). Thyroid dysfunction usually follows a triphasic course (thyrotoxicosis, hypothyroidism, and euthyroidism) that usually lasts 3 months. Symptomatic thyrotoxicosis occurs in the majority of patients, whereas clinical hypothyroidism is uncommon.

Although the diagnosis of SAT is usually based on clinical grounds, laboratory tests and neck imaging are useful (1, 2, 5). A marked elevation of inflammatory markers (ESR and CRP) is common. In the acute phase, most individuals present with overt thyrotoxicosis (high FT4 levels and low to undetectable TSH levels) (1). As a consequence of the destructive process, the FT3/FT4 ratio is usually low and Tg elevated (1, 2). TSH receptor antibodies are generally absent, whereas TPOAb are positive in some and TgAb in a larger number of patients (6-8). During the acute phase, radionuclide thyroid scanning typically shows reduced or absent tracer uptake, whereas thyroid ultrasound shows bilateral




Figure 1. Symptoms and maximum body temperatures referred to by the patient.

Table 1. Clinical laboratory results

Measure	Reference range	February 21	March 19	April 1	April 27
FT4, nmol/L	11-23	15.4	27.2	21.7	16.2
FT3, pmol/L	4.6-8.4	5.5	8.7	7.5	5.3
TSH, mIU/L	0.5-4.1	2.1	< 0.04	0.2	2.9
TgAb, IU/mL	< 30	< 30	120.2		
TPOAb, IU/mL	< 10	< 10	< 10		
TRAb, IU/mL	< 1.5		< 1.5		
Tg, µg/L			5.6		
White cell count, per L	3800-11 000		11 200	6900	6600
ESR, mm/h	0-13		90	28	2
CRP, mg/L	< 2		6.9	1.2	0.9

Abbreviations: CRP, C-reactive protein; ESR, erythrocyte sedimentation rate; FT3, free triiodothyronine; FT4, free thyroxine; Tg, thyroglobulin; TgAb, thyroglobulin antibodies; TPOAb, thyroperoxidase antibodies; TRAb, TSH receptor antibodies; TSH, thyrotropin.

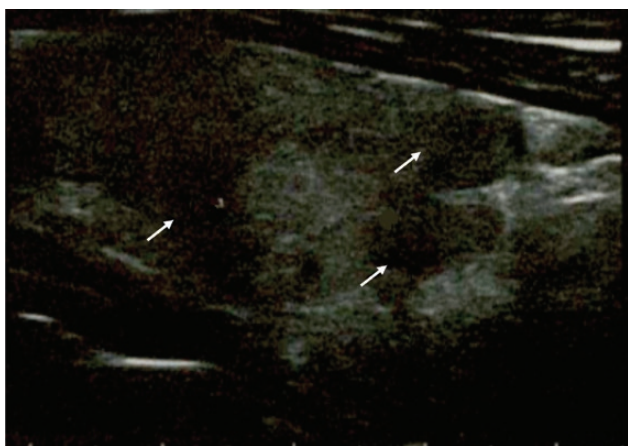


Figure 2. Thyroid ultrasound performed during the thyrotoxic phase, showing multiple hypoechoic areas (arrows).

hypoechoic areas associated with low to absent vascularization (5).

Thyroid evaluation performed 1 month earlier in the patient herein reported had ruled out thyroid diseases. She then presented with clinical, biochemical, and imaging stigmata of SAT. Of note, as previously reported, SAT was associated with the de novo appearance of TgAb (6, 8). Because of positive TgAb, Tg levels were inappropriately normal (9). Although the benefit of glucocorticoid is debated (10), in our experience the administration of prednisone during the acute phase is associated with a faster resolution of symptoms and a lower risk of recurrence (11). Indeed, within 2 weeks of treatment, we obtained a complete recovery of symptoms and a remarkable improvement both in thyroid function and inflammatory markers.

The etiology and the pathogenesis of SAT have not been completely understood, but it is common opinion that the disease is due to a viral infection or to a post-viral inflammatory reaction in genetically predisposed individuals (1, 3). Some human leukocyte antigen (HLA) haplotypes (mainly HLA-Bw35, but also HLA-B67, HLA-B15/62, and HLA-Drw8) have been reported

to predispose to SAT (12, 13). SAT is usually preceded by an upper respiratory infection and usually presents in association with characteristic symptoms of viral disease. In addition, several cases of the disease have been reported during viral outbreaks (2, 3). Some authors have reported a higher incidence of SAT in summer, during the outbreaks of echovirus and coxsackievirus (14, 15). Many other viruses, including mumps, adenovirus, orthomyxovirus, Epstein-Barr virus, hepatitis E, HIV, cytomegalovirus, dengue fever, and rubella have also been related to SAT (3, 16-18). At autopsy, thyroid injury was demonstrated in patients with SARS-CoV infection during the 2002 outbreak (19). However, coronavirus infection has never been associated with clinical SAT.

In conclusion, to our knowledge, this is the first case of SAT related to SARS-CoV-2. Because of the chronological association, SARS-CoV-2 may be considered accountable for the onset of SAT. COVID-19, originating from Wuhan, is spreading around the world as a pandemic disease (4). Since initial detection of the virus, more than 3 million cases of COVID-19 have been confirmed worldwide and Italy has been severely affected since February 2020 (20).

We therefore believe physicians should be alerted about the possibility of this additional clinical manifestation related to SARS-CoV-2 infection.

Acknowledgments

We thank the patient, whose written informed consent was obtained and who graciously agreed to collaborate with this study. We also thank Ms Laura Macri for her technical help in drawing the figure.

Financial Support: This work was supported by “Fondi di Ateneo 2018,” University of Pisa (to F.L.).

Author Contributions: Discussion of study results: A.B., D.R., N.V., D.S., F.S., and F.L.; writing of the manuscript: A.B., F.S., and F.L.

Additional Information

Correspondence and Reprint Requests: Francesco Latrofa, MD, Endocrinology Unit I, Department of Clinical and Experimental Medicine, University Hospital of Pisa, Via Paradisa 2, Pisa 56127, Italy. E-mail: francesco.latrofa@unipi.it.

Disclosure Summary: The authors declare no potential conflicts of interest.

Data Availability: Data sharing is not applicable to this article as no datasets were generated or analyzed during the current study.

References

- Nishihara E, Ohye H, Amino N, et al. Clinical characteristics of 852 patients with subacute thyroiditis before treatment. *Intern Med.* 2008;47(8):725-729.
- Benbassat CA, Olchovsky D, Tsvetov G, Shimon I. Subacute thyroiditis: clinical characteristics and treatment outcome in fifty-six consecutive patients diagnosed between 1999 and 2005. *J Endocrinol Invest.* 2007;30(8):631-635.
- Desailloud R, Hober D. Viruses and thyroiditis: an update. *Virology.* 2009;6:5.
- Guan WJ, Ni ZY, Hu Y, et al; for the China Medical Treatment Expert Group for Covid-19. Clinical characteristics of coronavirus disease 2019 in China. *N Engl J Med.* 2020;382:1708-1720.
- Bennedbaek FN, Hegedüs L. The value of ultrasonography in the diagnosis and follow-up of subacute thyroiditis. *Thyroid.* 1997;7(1):45-50.
- Latrofa F, Ricci D, Montanelli L, et al. Thyroglobulin autoantibodies of patients with subacute thyroiditis are restricted to a major B cell epitope. *J Endocrinol Invest.* 2012;35(8):712-714.
- Nishihara E, Amino N, Kudo T, et al. Moderate frequency of anti-thyroglobulin antibodies in the early phase of subacute thyroiditis. *Eur Thyroid J.* 2019;8(5):268-272.
- Ricci D, Brancatella A, Marinò M, et al. The detection of serum IgMs to thyroglobulin in subacute thyroiditis suggests a protective role of IgMs in thyroid autoimmunity. *J Clin Endocrinol Metab.* 2020;105(6).
- Latrofa F, Ricci D, Bottai S, et al. Effect of thyroglobulin autoantibodies on the metabolic clearance of serum thyroglobulin. *Thyroid.* 2018;28(3):288-294.
- Fatourehchi V, Aniszewski JP, Fatourehchi GZ, Atkinson EJ, Jacobsen SJ. Clinical features and outcome of subacute thyroiditis in an incidence cohort: Olmsted County, Minnesota, study. *J Clin Endocrinol Metab.* 2003;88(5):2100-2105.
- Arao T, Okada Y, Torimoto K, et al. Prednisolone dosing regimen for treatment of subacute thyroiditis. *J UOEH.* 2015;37(2):103-110.
- Ohsako N, Tamai H, Sudo T, et al. Clinical characteristics of subacute thyroiditis classified according to human leukocyte antigen typing. *J Clin Endocrinol Metab.* 1995;80(12):3653-3656.
- Farwell AP. Sporadic painless, painful subacute and acute infectious thyroiditis. In: Braverman LE, Cooper DS, eds. *Werner & Ingbar's The Thyroid: A Fundamental and Clinical Text.* 10th ed. Philadelphia, PA: Wolters Kluwer; 2013:414-427.
- Saito S, Sakurada T, Yamamoto M, Yamaguchi T, Yoshida K. Subacute thyroiditis: observations on 98 cases for the last 14 years. *Toboku J Exp Med.* 1974;113(2):141-147.
- Martino E, Buratti L, Bartalena L, et al. High prevalence of subacute thyroiditis during summer season in Italy. *J Endocrinol Invest.* 1987;10(3):321-323.
- Assir MZ, Jawa A, Ahmed HI. Expanded dengue syndrome: subacute thyroiditis and intracerebral hemorrhage. *BMC Infect Dis.* 2012;12:240.
- Bouillet B, Petit JM, Piroth L, Duong M, Bourg JB. A case of subacute thyroiditis associated with primary HIV infection. *Am J Med.* 2009;122(4):e5-e6.
- Martínez-Artola Y, Poncino D, García ML, Munné MS, González J, García DS. Acute hepatitis E virus infection and association with a subacute thyroiditis. *Ann Hepatol.* 2015;14(1):141-142.
- Wei L, Sun S, Xu CH, et al. Pathology of the thyroid in severe acute respiratory syndrome. *Hum Pathol.* 2007;38(1):95-102.
- Remuzzi A, Remuzzi G. COVID-19 and Italy: what next? *Lancet.* 2020;395(10231):1225-1228.