

Received:
18 February 2019

Revised:
15 March 2019

Accepted:
19 March 2019

Cite this article as:

Shim YS, Park SH, Choi SJ, Ahn S-J, Jeong YM, Kim TB, et al. Sonographic findings of mass-forming extramammary Paget's disease in the scrotum. *BJR Case Rep* 2019; **5**: 20190018.

CASE REPORT

Sonographic findings of mass-forming extramammary Paget's disease in the scrotum

¹YOUNG SUP SHIM, MD, ¹SO HYUN PARK, MD, ¹SEUNG JOON CHOI, MD, ¹SU-JOA AHN, MD, ¹YU MI JEONG, MD, ²TAE BEOM KIM, ²JUHYEON JEONG and ³HEE JOO KIM

¹Department of Radiology, Gil Medical Center, Gachon University College of medicine, Incheon, South Korea

²Department of Urology, Gil Medical Center, Gachon University College of medicine, Incheon, South Korea

³Department of Dermatology, Gil Medical Center, Gachon University College of medicine, Incheon, South Korea

Address correspondence to: So Hyun Park, MD., Ph.D. Department of Radiology, Gil Medical Center, Gachon University College of medicine, 21, Namdong-daero 774beon-gil, Namdong-gu, Incheon, 21565, Korea E-mail: E-mail: nnoleeter@naver.com

ABSTRACT

Extramammary Paget's disease (EMPD) is a rare cutaneous malignancy involving the scrotum and may be confused with other scrotal malignancy. We describe the sonographic findings of an extremely rare case of mass-forming EMPD of the scrotal wall. Ultrasonography, which shows mild heterogeneous hyperechoic masses with a stalk connected to the dermis, can help predict the depth of vertical invasion of the lesion. The lesion extent should be precisely evaluated because the presence of dermal invasion of EMPD is the risk factor in distant metastasis and is known to result in a worse prognosis. Ultrasonography is a primary imaging modality to evaluate the extent and vertical invasion of EMPD. Surgical local wide excision is the treatment of choice for EMPD and histopathology confirmed the diagnosis.

INTRODUCTION

Extramammary Paget's disease (EMPD) is a rare cutaneous malignancy. The common sites of EMPD are those rich in apocrine glands, such as the perineum, vulva, axilla, scrotum, and penis.¹ EMPD of the scrotum was first reported by Crocker in 1889.² The clinical manifestations of EMPD are erythematous, eczematous, or erosive lesions; pink or red plaques with scaling; and papillomatous surface of the skin.³ EMPD is a dermatologic disease; hence, only few reports to date have documented its radiologic findings.⁴⁻⁶ Herein, we report the sonographic findings of a case of mass-forming EMPD of the scrotal wall.

CASE REPORT

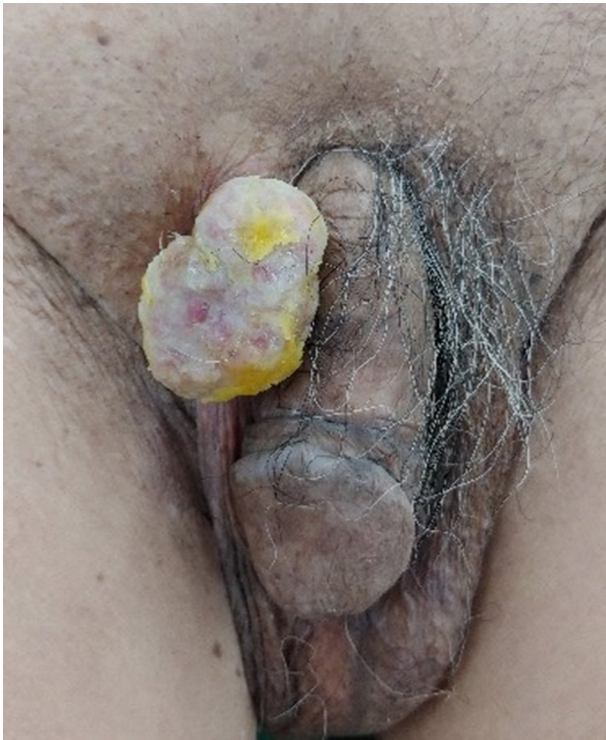An 84-year-old male presented to our hospital with skin erosion and a palpable mass on the scrotum. One year ago, the patient had undergone CO₂ laser treatment for the mass at a local clinic, but recently, the size of the mass had increased. The patient had no symptoms such as pain, swelling, or itching associated with the mass. A visual evaluation revealed a multilobular contoured whitish mass with small erosions in the right upper scrotal wall (Figure 1). No additional skin lesions were observed around the scrotal mass. He had no other diseases, except Alzheimer's disease. Moreover, no significant findings were found on complete blood count (CBC), chemistry profile, serum tumor marker

tests (carcinoembryonic antigen [CEA], prostate-specific antigen [PSA], and cancer antigen [CA 19-9]), and urine analysis. The patient underwent diagnostic ultrasonography using a 12-MHz linear transducer (iU22, Philips Medical Systems, Bothell, Washington). Ultrasonography revealed a 3.7 × 2.9 cm polypoid, mild heterogeneous, and hyperechoic mass in the right upper scrotal wall (Figure 2). The stalk of the mass was connected to the dermis, without extending to the subcutaneous layer. There was no calcification, fat, or cyst in the mass. Color Doppler ultrasonography revealed remarkable intratumoral vascularity in the peripheral portion of the mass from the stalk. The physician determined the best option was surgical excision for diagnosis and treatment of the slowly growing hypervascular tumor; therefore, the patient underwent tumor excision. The tumor was histopathologically diagnosed as EMPD (Figure 3). The tumor invaded the deep dermis without invading the subcutaneous layer. The patient underwent CT, PET/CT, and colonoscopy to exclude underlying malignancies, and these revealed no malignancy or metastasis.

DISCUSSION

Masses in the scrotal wall are one of the common reasons for patient visits to the urology outpatient department. Skin erosion with mass formation on the scrotal wall is rare, and is suspected to be a malignant tumor.⁷⁻⁹ Basal cell

Figure 1. Photograph of the patient. A multilobular contoured whitish mass with small erosions in the right upper scrotum. No skin lesion is observed around the mass.



carcinoma, squamous cell carcinoma, and cutaneous metastasis from other malignant tumors have been reported as possible causes.⁷⁻⁹ EMPD occurs rarely, and is mainly observed in elderly patients.¹⁰ Because these skin tumors are easily subjected to biopsy, clinicians usually do not perform imaging tests for diagnosis. However, attempts have been made to differentiate skin tumors and delineate margins by using ultrasonography.¹¹ Recently, ultrasonography has been principally used to diagnose mass in the scrotal wall and to evaluate the depth of skin invasion.

However, only a few case reports and reviews of the radiologic results of EMPD have been documented,^{4-6,12} and the MRI findings of EMPD in the external genitalia have thus far been reported in only four cases (2 male and two female patients) in

two studies.^{4,6} EMPD shows low-to-intermediate signal intensity on T2- and T₁-weighted images, high intensity on diffusion-weighted images, and marked homogeneous enhancement on gadolinium-enhanced T₁-weighted images. Moreover, the vertical invasion of EMPD measured on MRI showed a good correlation with that of the postoperative histopathological results.^{4,6} Ultrasonography is widely available, safe, and relatively inexpensive, and high-resolution ultrasonography can be very useful in evaluating the depth of invasion of the scrotal wall.^{5,12} In a previous report,⁵ high-resolution ultrasonography showed an irregularly contoured and heterogeneous echogenicity mass invading the dermis and subcutaneous layer of the scrotal wall. Furthermore, Doppler ultrasonography revealed increased intralesional vascularity. These ultrasonographic findings are very similar to those observed in our case. Ultrasonography helped predict the extent and vertical invasion of EMPD from the subcutaneous layer to the dermis.

Surgical local wide excision is the treatment of choice for EMPD.¹³ The presence of dermal invasion is the risk factor in distant metastasis and is known to result in a worse prognosis.¹⁴ Therefore, preoperative information about the depth of EMPD is important. In addition, possible underlying malignancy has been described in EMPD. Prior studies have described gastrointestinal/genitourinary malignancies associated with EMPD.¹⁴⁻¹⁶ If the EMPD is suspected, extensive examinations (*i.e.* colonoscopy, PET/CT, abdominal CT) are recommended to rule out underlying malignancies. In our patient, despite the use of several diagnostic modalities, no malignancy was detected. The disease is known to have a high frequency of recurrence.¹⁵ After the 7-month follow-up period, our patient was alive with no evidence of local tumor recurrence, when the surgical scar was visually checked and evaluated by urologists and plastic surgeons in outpatient departments.

In our patient, the main symptom was the palpable mass on the skin of the scrotum. Although there was some erosion on the surface of the mass, mass was not a common sign observed in EMPD. Further, no additional skin lesion was observed around the mass, and the patient did not complain of pain or pruritus. Therefore, our case was more difficult to distinguish from other malignancy (*i.e.* basal cell carcinoma, squamous cell carcinoma, cutaneous metastasis). A previous study reported that 6 of the 25 EMPD in the scrotum presented papillary lesions.¹⁰ These

Figure 2. A, Ultrasonography shows a mild heterogeneous hyperechoic polypoid mass in the right upper scrotal wall. The stalk of the mass is connected to the dermis, but the subcutaneous fat is not invaded (white arrows). B, Color Doppler ultrasonography shows remarkable intratumoral vascularity in the peripheral portion of the mass from the stalk.

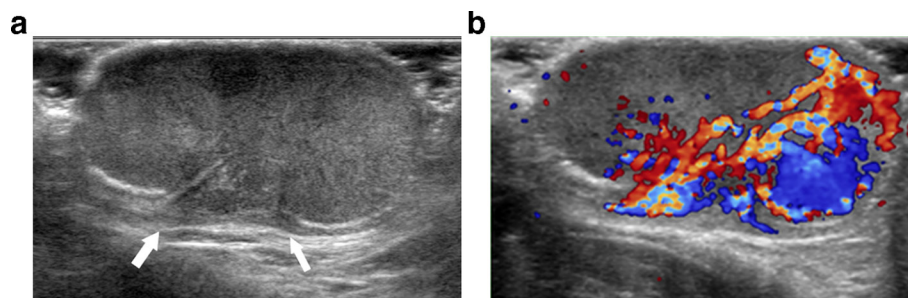
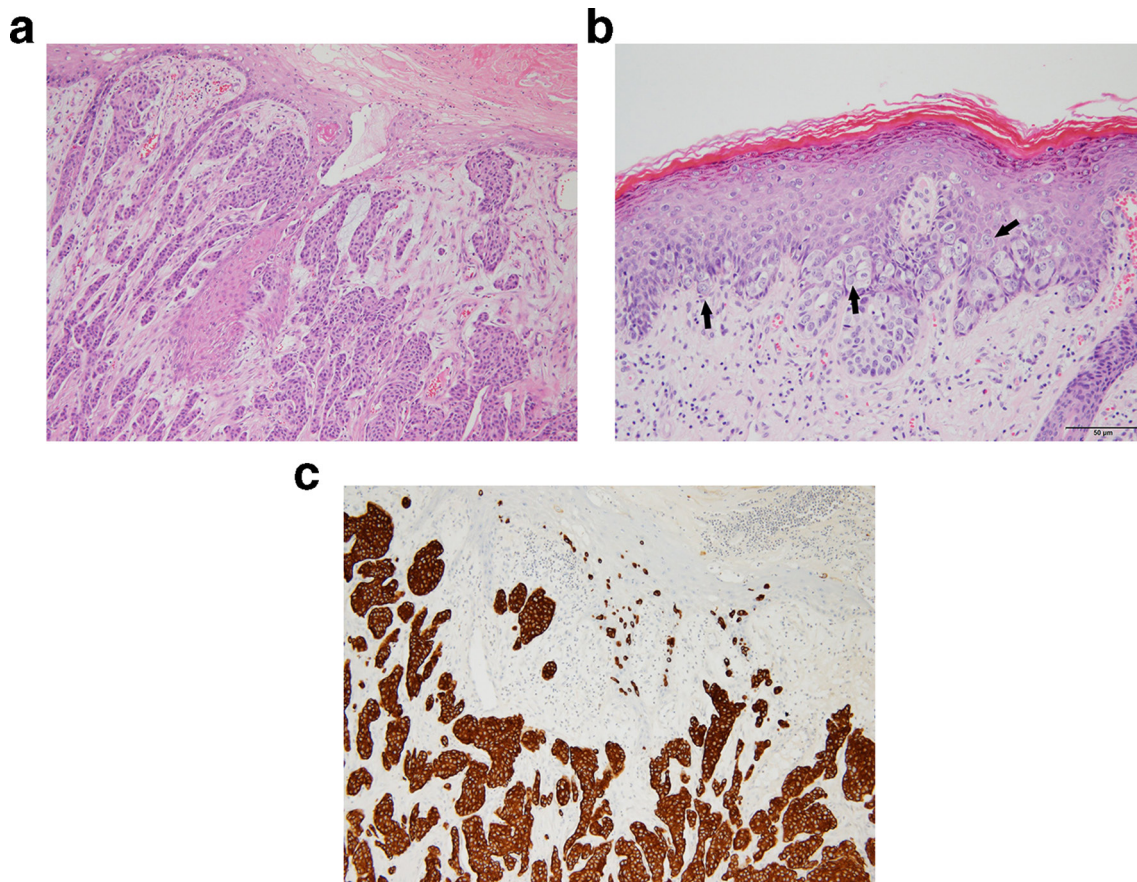


Figure 3. Extramammary Paget's disease with an invasive component. A, Single and nested tumor cells are arranged within the epidermis and infiltrate into the dermis (hematoxylin and eosin staining). B, Large pale and vacuolated Paget cells are found mostly in basal layer of epidermis (black arrows). C, Tumor cells diffusely express cytokeratin 7.



findings suggested that a few cases revealed papillary or mass-forming EMPD when evaluating scrotal lesion.

In conclusion, mass-forming EMPD is rare and may be confused with other scrotal malignancy. Ultrasonography is a primary imaging modality to evaluate the extent and vertical invasion of EMPD.

LEARNING POINTS

1. Ultrasonography is a helpful and safe modality for the exact lesion extent in the scrotal wall.

2. Extramammary Paget's disease is a rare dermatologic malignancy involving the scrotum. Sonography can predict the depth of invasion of mass-forming extramammary Paget's disease in the scrotal wall. The lesion extent should be precisely evaluated because the presence of dermal invasion is the risk factor in distant metastasis and is known to result in a worse prognosis.

CONSENT

Written consent for publication of the case and imaging data was obtained from the patient and his legal guardian.

REFERENCES

1. Isrow D, Oregel KZ, Cortes J, Gomez H, Milikowski C, Feun L, et al. Advanced extramammary Paget's disease of the groin, penis, and scrotum. *Clin Med Insights Oncol* 2014; **8**: CMO.S13107–90. doi: <https://doi.org/10.4137/CMO.S13107>
2. Crocker HR, disease Paget's. Affecting the scrotum and penis. *Transactions of the Pathological Society of London* 1889; **40**: 187–91.
3. Asel M, LeBoeuf NR, disease Extramammary Paget's. Extramammary Paget's disease. *Hematol Oncol Clin North Am* 2019; **33**: 73–85. doi: <https://doi.org/10.1016/j.hoc.2018.09.003>
4. Akaike G, Nozaki T, Matsusako M, Matsui M, Ohtake N, Eto H, et al. Magnetic resonance imaging for extramammary Paget's disease: radiological and pathological correlations. *Skeletal Radiol* 2013; **42**: 437–42. doi: <https://doi.org/10.1007/s00256-012-1540-0>
5. Choi SL, Park SB, Lee ES, Park HJ, Lee JB, Choi BI. Imaging features of extramammary Paget disease of the scrotum. *Ultrasound*

- Quarterly 2018; 1. doi: <https://doi.org/10.1097/RUQ.0000000000000362>
6. Andres V, Cristina D, Mariam R. Extramammary Paget's disease. *BJR|case reports* 2016; 2.
 7. Montgomery JS, Bloom DA. The diagnosis and management of scrotal masses. *Med Clin North Am* 2011; 95: 235–44. doi: <https://doi.org/10.1016/j.mcna.2010.08.029>
 8. Vyas R, Zargar H, Trolie RD, Di Lorenzo G, Autorino R. Squamous cell carcinoma of the scrotum: a look beyond the chimneystacks. *World J Clin Cases* 2014; 2: 654–60. doi: <https://doi.org/10.12998/wjcc.v2.i11.654>
 9. Ali Eissa AH, Jamil A, Md Nor N, Low DW, Lee BR. Basal cell carcinoma of the scrotum: a rare occurrence in SUN protected skin. *African Journal of Urology* 2018; 24: 160–2. doi: <https://doi.org/10.1016/j.afju.2018.04.004>
 10. Zhang N, Gong K, Zhang X, Yang Y, Na Y. Extramammary Paget's disease of scrotum—report of 25 cases and literature review. *Urologic Oncology: Seminars and Original Investigations* 2010; 28: 28–33. doi: <https://doi.org/10.1016/j.urolonc.2008.07.002>
 11. Mandava A, Ravuri PR, Konathan R. High-resolution ultrasound imaging of cutaneous lesions. *Indian J Radiol Imaging* 2013; 23: 269–77. doi: <https://doi.org/10.4103/0971-3026.120272>
 12. Bayan C-AY, Khanna T, Rotemberg V, Samie FH, Zeitouni NC. A review of non-invasive imaging in extramammary Paget's disease. *J Eur Acad Dermatol Venereol* 2018; 32: 1862–73. doi: <https://doi.org/10.1111/jdv.15072>
 13. Karam A, Dorigo O. Treatment outcomes in a large cohort of patients with invasive extramammary Paget's disease. *Gynecol Oncol* 2012; 125: 346–51. doi: <https://doi.org/10.1016/j.ygyno.2012.01.032>
 14. Lai Y-L, Yang W-G, Tsay P-K, Swee H, Chuang S-S, Wen C-J. Penoscrotal extramammary Paget's disease: a review of 33 cases in a 20-year experience. *Plast Reconstr Surg* 2003; 112: 1017–23. doi: <https://doi.org/10.1097/01.PRS.0000076193.67701.6A>
 15. Lee S-J, Choe YS, Jung HD, Ahn SK, Cha YC, Cho KH, et al. A multicenter study on extramammary Paget's disease in Korea. *Int J Dermatol* 2011; 50: 508–15. doi: <https://doi.org/10.1111/j.1365-4632.2010.04661.x>
 16. Siesling S, Elferink MAG, van Dijck JAAM, Pierie JPEN, Blokx WAM. Epidemiology and treatment of extramammary Paget disease in the Netherlands. *Eur J Surg Oncol* 2007; 33: 951–5. doi: <https://doi.org/10.1016/j.ejso.2006.11.028>