

Case Report

Delayed Diagnosis of *Mycobacterium bovis bacillus Calmette-Guérin* Periprosthetic Joint Infection Following Total Knee Arthroplasty

Christopher E. Pelt, MD^{a,*}, Salika Shakir, PhD, D(ABMM)^{b,c,d}, Michael J. Cahill, MSc^e, Jakrapun Pupaibool, MD^c, Barbara C. Cahill, MD^f

^a Department of Orthopaedic Surgery, University of Utah, Salt Lake City, UT, USA

^b ARUP Laboratories, Salt Lake City, UT, USA

^c Division of Infectious Diseases, University of Utah, Salt Lake City, UT, USA

^d Department of Pathology, University of Utah, Salt Lake City, UT, USA

^e Sidney Kimmel Medical College, Thomas Jefferson University, Philadelphia, PA, USA

^f Division of Pulmonary and Critical Care Medicine, University of Utah, Salt Lake City, UT, USA

ARTICLE INFO

Article history:

Received 4 January 2024

Received in revised form

1 February 2024

Accepted 10 February 2024

Available online xxx

Keywords:

Prosthetic joint infection

Total knee arthroplasty

Bacillus Calmette-Guérin (BCG)

BCGosis

Bladder cancer

ABSTRACT

Periprosthetic joint infection (PJI) can present challenges in diagnosis and treatment, particularly in the setting of atypical causative organisms such as fungi and mycobacteria. Herein, we present a case and provide a review of the diagnosis and treatment of an unusual PJI caused by bacillus Calmette-Guérin, administered during the treatment of bladder cancer 3 years prior to total knee arthroplasty and subsequent PJI. Although the patient's history of bladder cancer was known, neither his Bacillus Calmette-Guérin treatment nor its potential for distant site spread that could lead to PJI were appreciated, leading to a prolonged diagnostic evaluation and treatment course.

© 2024 The Authors. Published by Elsevier Inc. on behalf of The American Association of Hip and Knee Surgeons. This is an open access article under the CC BY-NC-ND license (<http://creativecommons.org/licenses/by-nc-nd/4.0/>).

Introduction

Periprosthetic joint infection (PJI), a potentially devastating complication of total knee arthroplasty (TKA), affects 0.5%–2.2% of primary TKAs and is associated with significant morbidity and mortality. Common PJI pathogens include *Staphylococcus aureus*, *Staphylococcus epidermidis*, streptococci, enterococci, and aerobic gram-negative bacilli [1–7]. Fungal and mycobacterial infections have been rarely reported to cause PJI [6,8–10].

Herein we present a case of a challenging workup, diagnosis, and treatment of a PJI due to *Bacillus Calmette-Guérin* (BCG), administered 3 years prior to TKA in the treatment of bladder cancer. A prior report has described a case of BCG, employed in the treatment of nonmuscle-invasive bladder cancer, which disseminated and led to PJI [11], though this has not been otherwise frequently described in the arthroplasty literature. The clinical

course, diagnostic, and treatment challenges in this case will inform surgeons and clinicians of this rare PJI etiology.

Case history

A 68-year-old man underwent right TKA for degenerative joint disease with a history, exam, and imaging consistent with primary osteoarthritis of the knee (Fig. 1). His medical history was remarkable for obesity, type 2 diabetes mellitus, gout, osteoarthritis, recurrent skin cancers, prostatism, and bladder cancer. He was successfully treated with intravesical BCG therapy 3 years earlier. His TKA surgery and postoperative recovery were initially uneventful, with pain relief and enhanced joint function.

Sixteen weeks after his TKA, joint swelling and pain with ambulation developed after a ground-level fall. Evaluation revealed disruption of the medial arthrotomy with preserved extensor mechanism but large diastasis of the medial arthrotomy below the skin, which remained intact without dehiscence or drainage. Radiographs showed lateral tilt and subluxation of the patella and a large effusion (Fig. 2). Because of the large defect, deep joint and implant palpable through the defect, along with patellar

* Corresponding author. Department of Orthopaedics, University of Utah, 590 Wakara Way, Salt Lake City, UT 84108, USA. Tel.: +1 801 587 7109.

E-mail address: chris.pelt@hsc.utah.edu

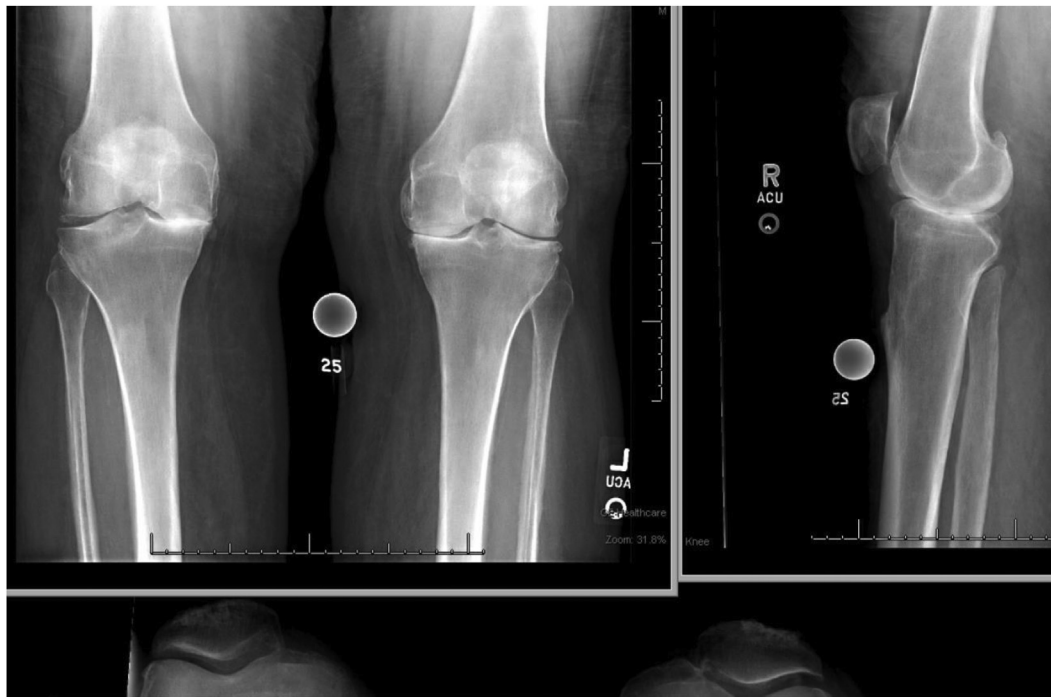


Figure 1. Preoperative x-rays demonstrating tricompartamental osteoarthritis more pronounced in the right knee than the left knee.

subluxation, surgical repair was indicated. Routine infectious labs were obtained. His white blood cell (WBC) was 10,100 cells/uL, erythrocyte sedimentation rate (ESR) was 0 mm/hr, and C-reactive protein (CRP) was 1.9 mg/dL. Synovial fluid alpha-defensin level was elevated, and the synovial fluid CRP was 4.4 mg/dL, concerning for infection. Synovial fluid cell count revealed 420,000 red blood cells/uL and 5931 WBCs/uL, with 59% polymorphonuclear cells (PMNs) and 41% mononuclear cells. Aerobic and anaerobic cultures from the synovial fluid were negative. Because of the traumatic

nature of the arthrotomy failure and a concerning but inconclusive infectious disease (ID) workup highlighted by a 2018 International Consensus Meeting (ICM) score of 9 but negative cultures, he underwent immediate surgery for irrigation and debridement, antibiotics and implant retention and medial arthrotomy repair. The joint fluid was turbid, and the gram stain showed 4+ PMNs and no organisms. Aerobic and anaerobic cultures, held for 14 days, and fungal tissue cultures were all negative. Mycobacterial cultures were not obtained per institutional protocols, given the lack of risk

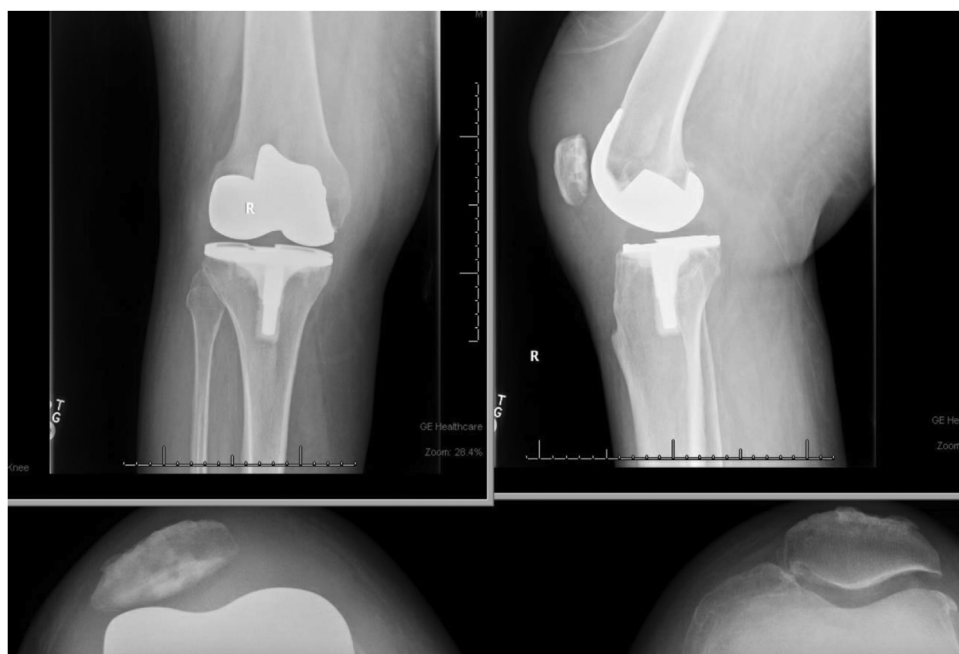


Figure 2. Post-TKA x-rays demonstrating a large joint effusion and lateral subluxation of the patella.

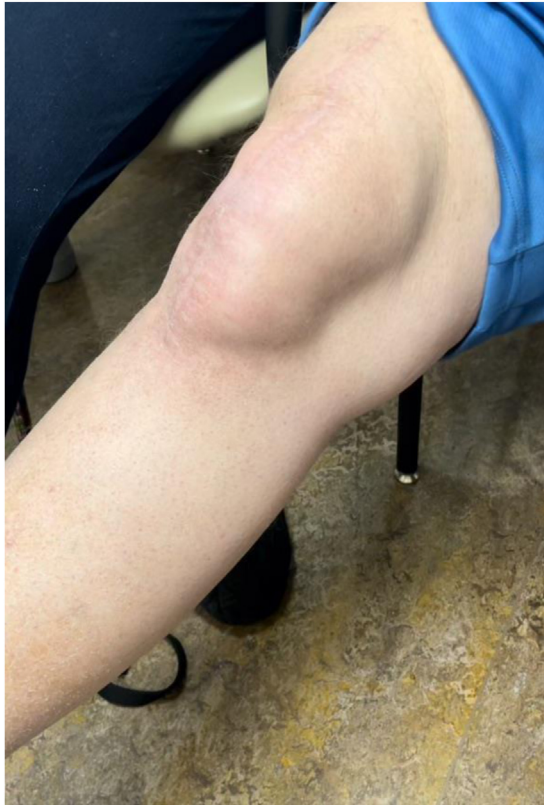

Figure 3. Tense, extraarticular right knee effusion extending caudally.

factors for tuberculosis. Postoperatively, the patient completed 6 weeks of empiric broad-spectrum antibiotics with vancomycin and cefepime.

At his 6-week follow-up clinic visit, examination and imaging studies revealed well-healed skin but a large effusion and recurrent medial arthrotomy dehiscence with lateral patellar subluxation and tilt once again. His WBC was 9700 cells/uL, ESR was 4 mm/hr, and CRP was 1.3 mg/dL. A second debridement and arthrotomy repair with vastus medialis advancement was performed. Upon incision of the skin, a large hematoma emerged. Complete disruption of the medial arthrotomy was seen. Implant fixation, rotation, and positioning appeared appropriate. A repeat debridement, antibiotics and implant retention procedure was performed, and the polyethylene was upsized from 12 to 15 mm. There were no obvious signs of infection. During both the first and second debridement surgeries, once the large effusion was decompressed, the patella was found to track centrally with a “no thumb” technique. The repairs were performed with local advancement of soft tissues and suture repair with #5 nonabsorbable braided suture. Tissue Gram stain showed 1+ PMNs with no organisms. Aerobic and anaerobic cultures, held for 14 days, and fungal cultures were again all negative. On recommendation of the ID consultant, the patient completed 6 weeks of levofloxacin therapy.

Following the second repair, joint pain and effusion once more recurred 12 weeks postoperatively. Evaluation once again suggested medial arthrotomy dehiscence, and radiographs revealed air or otherwise radiolucent areas within the infrapatellar fat pad. His WBC was 8700 cells/uL, ESR was 3 mm/hr, and CRP was 4.1 mg/dL. Synovial fluid aspirate showed 39,000 red blood cells/uL and 1302 WBC/uL, with 55% PMNs and 45% mononuclear cells, resulting in a 2018 ICM score of 2. Aerobic and anaerobic cultures, held for 14 days, and fungal cultures were all negative.

With repeated arthrotomy failures, recurrent subluxation and tilt of the patella, a large symptomatic effusion, and inconclusive data for a PJI diagnosis, the option of a single or 2-stage revision TKA was offered. Given the frustration of repeated surgeries and the lack of clinical improvement, the patient declined further surgery and opted to “live with it”.

He returned 1 year later with debilitating pain and immobility from a massive, dissecting extra-articular effusion that extended from the knee joint to the proximal third of the anterior thigh (Fig. 3). Magnetic resonance imaging and single-photon emission computed tomography were performed to investigate the underlying cause of the effusion. The implants appeared well positioned, without rotational errors to explain the recurrent arthrotomy failures and patellar subluxation. Single-photon emission computed tomography demonstrated no evidence of implant loosening. Implant position and rotation appeared appropriate. Magnetic resonance imaging confirmed a massive dissecting effusion extending up the thigh, connecting with a 3.3 cm defect in the quadriceps tendon and proximal arthrotomy (Fig. 4a and b).

A revision TKA was performed using a single-stage approach for PJI, with a definitive revision. TKA implants were reimplanted after radical debridement and thorough cleaning. A normal-appearing, stable prosthesis was removed, and a massive dissecting fluid collection that had eroded through the subcutaneous layer up to the proximal thigh was debrided. To enhance healing, doxycycline powder was added as a sclerosing agent along with multilayer suturing to close the dead space left in the thigh. A drain was left in the subcutaneous layer for an extended duration. A knee immobilizer was placed for 6 weeks of soft tissue rest. He completed postoperative rehabilitation with 6 weeks of partial weight bearing and then transitioned to weight bearing and motion as tolerated thereafter.

Histopathologic analysis of the joint tissue taken during the revision revealed chronic synovitis with nonnecrotizing granulomatous inflammation. With these histologic findings, ID consultation recommended an evaluation for tuberculosis. Synovial tissue polymerase chain reaction was positive for *Mycobacterium tuberculosis* (MTB) complex. Mycobacterial cultures subsequently grew MTB complex, identified by matrix-assisted laser desorption ionization-time-of-flight mass spectrometry as BCG.

The patient was treated with 9 months of isoniazid, rifampin, and ethambutol. At his 6- and 9-month follow-up visits, he had complete resolution of his joint effusion, 0–120 degrees of knee motion, a centrally tracking patella, and a fully healed arthrotomy. He continues to do well, now 16 months post-successful single-stage revision TKA (Fig. 5).

Discussion

The most common causative organisms in PJIs following total joint arthroplasty are bacterial, most commonly *Staphylococcus aureus* and coagulase-negative staphylococci, such as *Staphylococcus epidermidis*, as well as streptococci, enterococci, and aerobic gram-negative bacilli [6]. Mycobacterial PJI following total joint arthroplasty is uncommon and most commonly caused by MTB and nontuberculous mycobacterial species [12]. This case represents a rare case of mycobacterial PJI from BCG due to distant intravesical BCG administration for the treatment of bladder cancer.

BCG is a live, attenuated strain of *Mycobacterium bovis* developed by Albert Calmette and Camille Guérin in the early twentieth century as a potential tuberculosis (MTB) vaccine candidate. BCG belongs to the MTB complex, which is comprised of MTB, *M. africanum*, *M. microti*, *M. caprae*, *M. pinnipedii*, *M. canettii*, *M. bovis*, and BCG. The virulence of BCG was attenuated by growth under stringent conditions through more than 230 subcultures

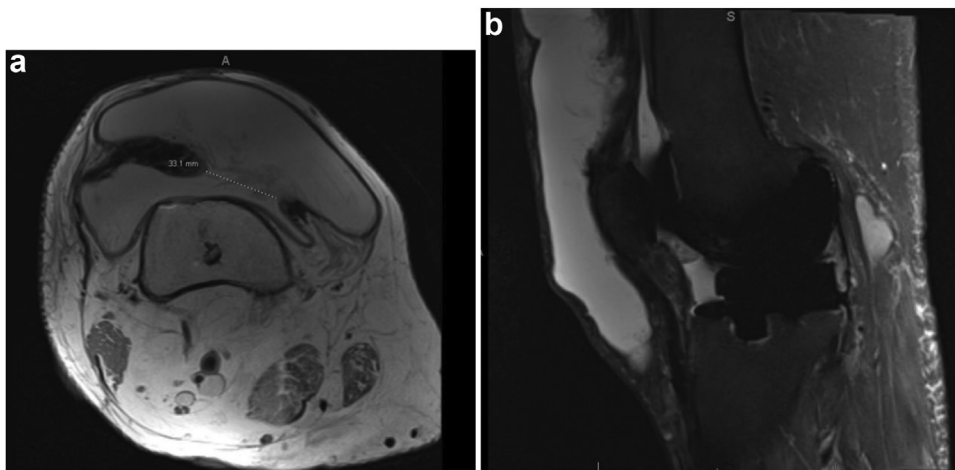


Figure 4. (a) Axial and (b) sagittal MRI images show a large knee joint effusion with communication to a large subcutaneous fluid collection overlying the right knee and extending superiorly through a large defect in the quadriceps repair. MRI, magnetic resonance imaging.

over a span of 13 years before it was deemed safe and introduced as a tuberculosis vaccine in 1921 [13]. Today, BCG is the most widely used vaccine in humans, routinely administered to children in areas of the world where MTB is endemic. BCG has also found a distinct role as a microbial immunomodulator in the treatment of high-risk, nonmuscle-invasive bladder cancer. The use of adjuvant BCG bladder washes is effective in reducing bladder cancer recurrence rates, inhibiting tumor progression, and improving recurrence free survival compared to surgery alone [13-15].

Both BCG immunization and intravesical BCG administration can rarely result in BCG bacteremia and seeding of distant sites, known as BCGosis. BCGosis has been reported in 1%-5% of bladder cancer patients following intravesical BCG administration. Such

infections are most often identified within 3 months of treatment, but delayed infections, manifesting even years later, have been reported. In approximately 20% of intravesical BCGosis cases, the infection will seed bone or muscle. Among these, approximately 7% present with infectious arthritis, while around 2% develop PJI [16-19].

Mycobacterial infections of bones and joints are rare and often go unrecognized, leading to delays in treatment and effective patient management. Such infections present unique diagnostic challenges due to their indolent course, delayed onset, and often subtle clinical presentation. Notably, mycobacterial cultures are not routinely included in the standard evaluation of PJI. Current guidelines recommend restricting mycobacterial and fungal

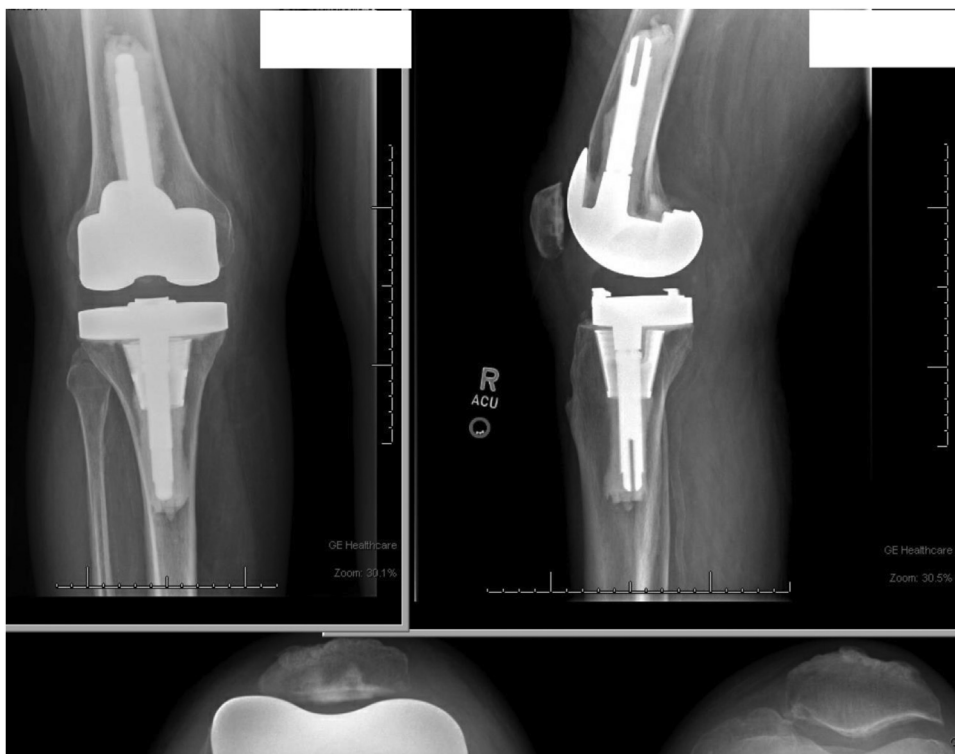

Figure 5. Postrevision x-rays demonstrating short, cemented stems and zone-2 tibial metaphysis cone with minimal effusion and a centrally tracking patella.

cultures to suspected PJI in immunocompromised hosts, those with a previous history of atypical infection, exposure to endemic atypical infections, or in the setting of culture-negative PJI [20–23].

The diagnosis of MTB-complex joint infections can be challenging, even when the diagnosis is considered. The diagnosis can be established by microscopic examination and culture of infected material. Smear microscopy utilizing acid-fast stains is a rapid method for identification of mycobacteria, and a positive smear result has a high predictive value for infection. However, smear microscopy lacks specificity for MTB, suffers from limited sensitivity, and requires a high bacterial burden for detection (5000–10,000 colony-forming units/mL). The sensitivity of acid-fast staining is further diminished, to 40% or less, in extrapulmonary specimens such as bone or joint, due to the often paucibacillary nature of these infections [24].

Culture is the gold standard for the diagnosis of MTB complex disease. MTB culture also requires ample specimen volume (minimum 5 mL) and extended incubation times (6–8 weeks) due to slow growth of the organism. Culture not only confirms the presence of the pathogen, but also provides an isolate for species-level identification and antimicrobial susceptibility testing. Positive cultures are identified to the species level with molecular tools such as 16S rRNA sequencing, matrix-assisted laser desorption/ionization-time-of-flight, or lateral flow assays [25].

Distinguishing BCG disease from other MTB complex organisms is crucial for appropriate treatment and for epidemiological purposes. However, in extrapulmonary infections, including bone and joint, culture sensitivity varies widely, ranging from 20% to 80% [24]. Due to the paucibacillary nature of MTB complex disease in PJI, culture sensitivity is reduced to approximately 60%–75%, with greater detection from synovial biopsies than synovial fluid aspiration [26]. In addition, co-existing bacterial infection may interfere with or obscure growth of MTB complex in culture, and as such, negative culture results do not rule out a diagnosis of MTB complex PJI.

Nucleic acid amplification testing (NAAT) has proven to be highly effective in detecting extrapulmonary MTB complex infections, with higher sensitivity compared to culture-based diagnostics [26–29]. The Xpert MTB/RIF assay has revolutionized tuberculosis diagnostics with rapid detection of MTB complex and the *rpoB* gene mutation that predicts rifampin resistance. In sputum specimens, the assay has a limit of detection of 131 colony-forming units/mL, with a sensitivity of 98% in smear-positive/culture-positive specimens and 72% in smear-negative/culture-positive specimens [30–32]. This assay is Food and Drug Administration-approved for sputum but not for other body fluids or tissue specimens. Though data for use of the Xpert MTB/RIF assay for synovial fluid and tissue specimens is scarce, studies have demonstrated effective identification of MTB complex and rifampin resistance [33–35]. A meta-analysis evaluating the accuracy of the Xpert MTB/RIF assay for bone and joint infections demonstrated pooled sensitivities of 81% and 96% and specificities of 99% and 85% compared to the composite reference standard and culture methods, respectively. Importantly, there was no significant difference in diagnostic accuracy among the types of specimens tested (with purulent fluid sensitivity at 82% and specificity at 99% compared to tissue sample sensitivity at 84% and specificity at 98%) [28]. Thus, rapid NAAT testing can be employed for the diagnosis of MTB complex in bone and joint specimens while culture results are pending.

Metagenomic next-generation sequencing (mNGS) is a relatively new technique for identifying pathogens and can be a powerful tool for culture-negative or polymicrobial infections. mNGS has the ability to diagnose, predict drug resistance, and identify members within the MTB complex accurately, directly from a patient specimen. Despite its potential, mNGS may have

reduced sensitivity in paucibacillary specimens, resulting in a low yield of genomic DNA available for sequencing. mNGS has demonstrated success in diagnosing MTB in various specimens, including pulmonary, cerebrospinal fluid, and other extrapulmonary specimens [36,37]. Huang *et al.* identified MTB complex using mNGS from a knee joint infection that was repeatedly culture-negative [38]. However, this technology is not yet widely available due to cost constraints and the need for trained personnel and laboratory infrastructure.

The diagnosis of PJI typically involves a comprehensive evaluation of clinical and laboratory parameters to determine the likelihood of infection [39]. The current standard of PJI diagnosis is based on the criteria developed at the 2018 ICM in Philadelphia. Clinical signs supporting a PJI diagnosis include positive cultures, a sinus tract, and other findings such as erythema, localized warmth, effusions, swelling, and tenderness, which heighten the clinical index of suspicion. Laboratory parameters include joint fluid analysis, serum inflammatory markers, and microbiological culture results. Elevated synovial WBC and a high PMN differential, along with an increased ESR, CRP, alpha-defensin, and D-dimer may further add to the ICM scoring criteria that provide a PJI likelihood score.

High-quality, evidence-based guidelines exist for the treatment of infections caused by the most common PJI pathogens: *Staphylococci*, *Streptococci*, *Enterococci*, and aerobic gram-negative bacilli [6]. However, there is little evidence to guide providers in the evaluation and treatment of culture negative PJI. As they wend their way to the clinical realm, NAAT and mNGS offer promising avenues for improving diagnosis, detecting drug resistance, and directing earlier, effective treatment in culture-negative PJI cases.

Our patient underwent TKA with a presumed diagnosis of primary osteoarthritis. Unbeknownst to the surgeon, the patient had likely seeded his native left knee when treated with intravesical BCG for bladder cancer 3 years before his TKA. Unfortunately, the infection went unnoticed. BCG lay dormant in his system until the time of his TKA. Surgical trauma presumably reactivated latent BCG disease in the surgical field. The repeated arthrotomy failures were believed to be related to the large, though yet, unexplained effusions, causing arthrotomy dehiscence. The diagnosis of BCG PJI was ultimately established when necrotizing granulomas were discovered on surgical pathology specimens from prosthetic joint tissue at the time of his TKA revision. Finding granulomatous inflammation on pathologic analysis prompted Xpert MTB/RIF assay testing of synovial tissue, which confirmed the presence of MTB complex. Mycobacterial cultures subsequently grew MTB complex, identified as BCG by molecular testing. The patient underwent single-staged revision TKA and was successfully medically treated with isoniazid, rifampin, and ethambutol.

Summary

BCG PJI is rare, and the diagnosis requires a high degree of clinical suspicion. BCG is used in the treatment of bladder cancer and, as shown in this case, may disseminate to distant sites, which could lead to PJI following arthroplasty procedures. Mycobacterial organisms, including BCG can be challenging to isolate and grow. Prolonged culture, specialized growth media, and molecular testing may be required to accurately diagnose infection and guide appropriate treatment. Currently, the diagnosis of PJI depends on a scoring system incorporating clinical, laboratory, and culture data, with cultures for mycobacteria and fungi rarely obtained. Molecular tools such as NAAT and mNGS, currently adjuncts in the traditional diagnosis of PJI, have the potential to improve the diagnostic yield and guide treatment in cases of culture-negative PJI. Our case highlights the critical importance of a comprehensive medical history, meticulous clinical evaluation, diagnostic workup, and

interdisciplinary collaboration in diagnosis and disease management of difficult to diagnose PJI's.

Conflicts of interest

C. Pelt receives royalties from Total Joint Orthopaedics and Smith and Nephew, is a speaker bureau of Total Joint Orthopaedics, is a paid consultant of 3M and Total Joint Orthopaedics, has stock options in Joint Development, LLC., receives research support from Zimmer Biomet, Peptilogics, and Smith and Nephew, and is a board or committee member of AAHKS and AAOS. All other authors declare no potential conflicts of interest.

For full disclosure statements refer to <https://doi.org/10.1016/j.artd.2024.101350>.

Informed patient consent

The author(s) confirm that written informed consent has been obtained from the involved patient(s) or if appropriate from the parent, guardian, power of attorney of the involved patient(s); and, they have given approval for this information to be published in this case report (series).

CRediT authorship contribution statement

Christopher E. Pelt: Writing – review & editing, Writing – original draft, Conceptualization. **Salika Shakir:** Writing – review & editing. **Michael J. Cahill:** Writing – review & editing. **Jakrapun Pupaibool:** Writing – review & editing. **Barbara C. Cahill:** Writing – review & editing, Writing – original draft, Visualization, Conceptualization.

References

- [1] Espindola R, Vella V, Benito N, Mur I, Tedeschi S, Zamparini E, et al. Incidence, associated burden of disease, and healthcare utilisation of prosthetic joint infections due to *Staphylococcus aureus* in European hospitals. The COMBACTE-NET ARTHR-IS multicentre study. *J Hosp Infect* 2023;111: 2177–203. <https://doi.org/10.1016/j.jhin.2023.09.012>.
- [2] Fischbacher A, Borens O. Prosthetic-joint infections: mortality over the last 10 years. *J Bone Jt Infect* 2019;4:198–202. <https://doi.org/10.7150/jbji.35428>.
- [3] Jansen E, Varonen M, Huhtala H, Lehto MU, Lumio J, Kontinen YT, et al. Incidence of prosthetic joint infections after primary knee arthroplasty. *J Arthroplasty* 2010;25:87–92. <https://doi.org/10.1016/j.arth.2008.10.013>.
- [4] Ong KL, Kurtz SM, Lau E, Bozic KJ, Berry DJ, Parvizi J. Prosthetic joint infection risk after total hip arthroplasty in the Medicare population. *J Arthroplasty* 2009;24:105–9. <https://doi.org/10.1016/j.arth.2009.04.027>.
- [5] Springer BD, Cahue S, Etkin CD, Lewallen DG, McGrory BJ. Infection burden in total hip and knee arthroplasties: an international registry-based perspective. *Arthroplast Today* 2017;3:137–40. <https://doi.org/10.1016/j.artd.2017.05.003>.
- [6] Tande AJ, Patel R. Prosthetic joint infection. *Clin Microbiol Rev* 2014;27: 302–45. <https://doi.org/10.1128/CMR.00111-13>.
- [7] Karunamoorthi K. Vector control: a cornerstone in the malaria elimination campaign. *Clin Microbiol Infect* 2011;17:1608–16. <https://doi.org/10.1111/j.1469-0691.2011.03664.x>.
- [8] Herndon CL, Rowe TM, Metcalf RW, Odum SM, Fehring TK, Springer BD, et al. Treatment outcomes of fungal periprosthetic joint infection. *J Arthroplasty* 2023;38:2436–2440.e1. <https://doi.org/10.1016/j.arth.2023.05.009>.
- [9] Hwang BH, Lee SC, Ong A, Ahn HS, Moon SH. Mycobacterial periprosthetic joint infection after primary total knee arthroplasty. *Int Orthop* 2021;45: 3055–62. <https://doi.org/10.1007/s00264-021-05029-x>.
- [10] Sambri A, Zunarelli R, Fiore M, Bortoli M, Paolucci A, Filippini M, et al. Epidemiology of fungal periprosthetic joint infection: a systematic review of the literature. *Microorganisms* 2022;11:84. <https://doi.org/10.3390/microorganisms11010084>.
- [11] Patel A, Elzweig J. *Mycobacterium bovis* prosthetic joint infection following intravesical instillation of BCG for bladder cancer. *BMJ Case Rep* 2019;12: e231830. <https://doi.org/10.1136/bcr-2019-231830>.
- [12] Maimaiti Z, Li Z, Xu C, Fu J, Hao L, Chen J, et al. Non-tuberculosis *Mycobacterium* periprosthetic joint infections following total hip and knee arthroplasty: case series and review of the literature. *Orthop Surg* 2023;15: 1488–97. <https://doi.org/10.1111/os.13661>.
- [13] Lange C, Aaby P, Behr MA, Donald PR, Kaufmann SHE, Netea MG, et al. 100 years of *Mycobacterium bovis* bacille Calmette-Guerin. *Lancet Infect Dis* 2022;22:e2–12. [https://doi.org/10.1016/S1473-3099\(21\)00403-5](https://doi.org/10.1016/S1473-3099(21)00403-5).
- [14] Herr HW, Morales A. History of bacillus Calmette-Guerin and bladder cancer: an immunotherapy success story. *J Urol* 2008;179:53–6. <https://doi.org/10.1016/j.juro.2007.08.122>.
- [15] Luca S, Mihaescu T. History of BCG vaccine. *Maedica (Bucur)* 2013;8:53–8.
- [16] Perez-Jacoiste Asin MA, Fernandez-Ruiz M, Lopez-Medrano F, Lumberras C, Tejido A, San Juan R, et al. Bacillus Calmette-Guerin (BCG) infection following intravesical BCG administration as adjunctive therapy for bladder cancer: incidence, risk factors, and outcome in a single-institution series and review of the literature. *Medicine (Baltim)* 2014;93:236–54. <https://doi.org/10.1097/MD.0000000000000119>.
- [17] Lamm DL, van der Meijden PM, Morales A, Brosman SA, Catalona WJ, Herr HW, et al. Incidence and treatment of complications of bacillus Calmette-Guerin intravesical therapy in superficial bladder cancer. *J Urol* 1992;147: 596–600. [https://doi.org/10.1016/s0022-5347\(17\)37316-0](https://doi.org/10.1016/s0022-5347(17)37316-0).
- [18] Gonzalez OY, Musher DM, Brar I, Fergusson S, Boktour MR, Septimus EJ, et al. Spectrum of bacille Calmette-Guerin (BCG) infection after intravesical BCG immunotherapy. *Clin Infect Dis* 2003;36:140–8. <https://doi.org/10.1086/344908>.
- [19] Lamm DL. Efficacy and safety of bacille Calmette-Guerin immunotherapy in superficial bladder cancer. *Clin Infect Dis* 2000;31:S86–90. <https://doi.org/10.1086/314064>.
- [20] Ascione T, Barrack R, Benito N, Blevins K, Brause B, Cornu O, et al. General assembly, diagnosis, pathogen isolation – culture matters: proceedings of international Consensus on orthopedic infections. *J Arthroplasty* 2019;34: S197–206. <https://doi.org/10.1016/j.arth.2018.09.071>.
- [21] Tai DBG, Wengenack NL, Patel R, Berbari EF, Abdel MP, Tande AJ. Fungal and mycobacterial cultures should not be routinely obtained for diagnostic work-up of patients with suspected periprosthetic joint infections. *Bone Joint J* 2022;104-B:53–8. <https://doi.org/10.1302/0301-620X.104B1.BJJ-2021-0876.R1>.
- [22] Tokarski AT, O'Neil J, Deirmengian CA, Ferguson J, Deirmengian GK. The routine use of atypical cultures in presumed aseptic revisions is unnecessary. *Clin Orthop Relat Res* 2013;471:3171–7. <https://doi.org/10.1007/s11999-013-2917-7>.
- [23] Wadey VM, Huddleston JI, Goodman SB, Schurman DJ, Maloney WJ, Baron EJ. Use and cost-effectiveness of intraoperative acid-fast bacilli and fungal cultures in assessing infection of joint arthroplasties. *J Arthroplasty* 2010;25: 1231–4. <https://doi.org/10.1016/j.arth.2009.08.018>.
- [24] Lewinsohn DM, Leonard MK, LoBue PA, Cohn DL, Daley CL, Desmond E, et al. Official American thoracic society/infectious diseases society of America/centers for disease control and prevention clinical practice guidelines: diagnosis of tuberculosis in adults and children. *Clin Infect Dis* 2017;64:111–5. <https://doi.org/10.1093/cid/ciw778>.
- [25] Forbes BA, Hall GS, Miller MB, Novak SM, Rowlinson MC, Salfinger M, et al. Practical guidance for clinical microbiology laboratories: mycobacteria. *Clin Microbiol Rev* 2018;31:e00038-17. <https://doi.org/10.1128/CMR.00038-17>.
- [26] Lo CKL, Chen L, Varma S, Wood GCA, Grant J, Wilson EW. Management of *Mycobacterium tuberculosis* prosthetic joint infection: 2 cases and literature review. *Open Forum Infect Dis* 2021;8:ofab451. <https://doi.org/10.1093/ofid/ofab451>.
- [27] Fujimoto N, Gemba K, Yao A, Ozaki S, Ono K, Wada S, et al. Tuberculosis diagnosed by PCR analysis of synovial fluid. *J Infect Chemother* 2010;16:53–5. <https://doi.org/10.1007/s10156-009-0010-7>.
- [28] Shen Y, Yu G, Zhong F, Kong X. Diagnostic accuracy of the Xpert MTB/RIF assay for bone and joint tuberculosis: a meta-analysis. *PLoS One* 2019;14:e0221427. <https://doi.org/10.1371/journal.pone.0221427>.
- [29] Wen H, Li P, Ma H, Lv G. Diagnostic accuracy of Xpert MTB/RIF assay for musculoskeletal tuberculosis: a meta-analysis. *Infect Drug Resist* 2017;10: 299–305. <https://doi.org/10.2147/IDR.S145843>.
- [30] Detjen AK, DiNardo AR, Leyden J, Steingart KR, Menzies D, Schiller I, et al. Xpert MTB/RIF assay for the diagnosis of pulmonary tuberculosis in children: a systematic review and meta-analysis. *Lancet Respir Med* 2015;3:451–61. [https://doi.org/10.1016/S2213-2600\(15\)00095-8](https://doi.org/10.1016/S2213-2600(15)00095-8).
- [31] Horne DJ, Kohli M, Zifodya JS, Schiller I, Dendukuri N, Tollefson D, et al. Xpert MTB/RIF and Xpert MTB/RIF Ultra for pulmonary tuberculosis and rifampicin resistance in adults. *Cochrane Database Syst Rev* 2019;6:CD009593. <https://doi.org/10.1002/14651858.CD009593.pub4>.
- [32] Marlowe EM, Novak-Weekley SM, Cumpio J, Sharp SE, Momeny MA, Babst A, et al. Evaluation of the Cepheid Xpert MTB/RIF assay for direct detection of *Mycobacterium tuberculosis* complex in respiratory specimens. *J Clin Microbiol* 2011;49:1621–3. <https://doi.org/10.1128/JCM.02214-10>.
- [33] Davis R, Higgins C, Cosgrove C, Shur J, Arkell P. Tuberculous arthritis: negative Xpert MTB/RIF assay does not rule out infection. *BMJ Case Rep* 2018;2018: bcr2018224288. <https://doi.org/10.1136/bcr-2018-224288>.
- [34] Gu Y, Wang G, Dong W, Li Y, Ma Y, Shang Y, et al. Xpert MTB/RIF and GenoType MTBDRplus assays for the rapid diagnosis of bone and joint tuberculosis. *Int J Infect Dis* 2015;36:27–30. <https://doi.org/10.1016/j.ijid.2015.05.014>.
- [35] Held M, Laubscher M, Mears S, Dix-Peek S, Workman L, Zar H, et al. Diagnostic accuracy of the Xpert MTB/RIF assay for extrapulmonary tuberculosis in children with musculoskeletal infections. *Pediatr Infect Dis J* 2016;35:1165–8. <https://doi.org/10.1097/INF.0000000000001271>.

- [36] Li Y, Jiao M, Liu Y, Ren Z, Li A. Application of metagenomic next-generation sequencing in *Mycobacterium tuberculosis* infection. *Front Med* 2022;9: 802719. <https://doi.org/10.3389/fmed.2022.802719>.
- [37] Sun W, Lu Z, Yan L. Clinical efficacy of metagenomic next-generation sequencing for rapid detection of *Mycobacterium tuberculosis* in smear-negative extrapulmonary specimens in a high tuberculosis burden area. *Int J Infect Dis* 2021;103:91–6. <https://doi.org/10.1016/j.ijid.2020.11.165>.
- [38] Huang Z, Zhang C, Hu D, Shi K, Li W, Zhang C, et al. Diagnosis of osteoarticular tuberculosis via metagenomic next-generation sequencing: a case report. *Exp Ther Med* 2019;18:1184–8. <https://doi.org/10.3892/etm.2019.7655>.
- [39] Parvizi J, Tan TL, Goswami K, Higuera C, Della Valle C, Chen AF, et al. The 2018 definition of periprosthetic hip and knee infection: an evidence-based and validated criteria. *J Arthroplasty* 2018;33:1309–13014.e2. <https://doi.org/10.1016/j.arth.2018.02.078>.