


Study of the utility and problems of common iliac artery balloon occlusion for placenta previa with accreta

Yoshihisa Ono¹ , Yoshihiko Murayama¹, Sumiko Era¹, Shigetaka Matsunaga¹, Tomonori Nagai¹, Hisato Osada², Yasushi Takai¹, Kazunori Baba¹, Satoru Takeda¹ and Hiroyuki Seki¹

¹Center for Maternal Fetal and Neonatal Medicine, Saitama Medical Center, Saitama Medical University and ²Department of Radiology, Saitama Medical Center, Saitama Medical University, Kawagoe, Japan

Abstract

Aims: We investigated whether common iliac artery balloon occlusion (CIABO) was effective for decreasing blood loss during cesarean hysterectomy (CH) in patients with placenta previa with accreta and was safe for mothers and fetuses.

Methods: Of the 67 patients who underwent CH for placenta previa with accreta at our facility from 1985 to 2014, 57 patients were eligible for the study. The amount of intraoperative bleeding during CH was compared between three groups: surgery without blood flow occlusion (13 patients), internal iliac artery ligation (15 patients) and CIABO (29 patients). Additionally, multivariate analysis was performed to assess risk factors for massive bleeding during CH.

Results: The mean blood loss in the CIABO group (2027 ± 1638 mL) was significantly lower than in the other two groups (3787 ± 2936 mL in the no occlusion, 4175 ± 1921 mL in the internal iliac artery ligation group; $P < 0.05$). Multivariate analysis showed that spontaneous placental detachment during surgery (odds ratio [OR] 49.174, 95% confidence interval [CI] 4.98–1763.67), a history of ≥ 2 cesarean sections (OR 9.226, 95% CI 1.07–231.15) and no use of CIABO (OR 26.403, 95% CI 3.20–645.17) were significantly related to massive bleeding during surgery. There was no case of necrosis resulting from ischemia. The mean radiation dose during balloon placement never exceeded the threshold value for fetal exposure.

Conclusion: Bleeding during CH for placenta previa with accreta can be decreased by CIABO. This study also confirmed the safety of CIABO in regard to maternal lower limb ischemia and fetal radiation exposure during balloon placement.

Key words: balloon occlusion, hysterectomy, iliac artery, placenta previa, risk factors.

Introduction

Placenta accreta is pathologically defined as a placenta in which the chorionic villi directly contact the muscle layer where the decidua is missing.¹ Known risk factors include placenta previa and past cesarean section.^{2,3} If placenta accreta is observed over a wide area, massive bleeding could occur during cesarean section. Therefore, placenta accreta is an

obstetric complication with a high risk of maternal death.

Techniques reported to be useful for reducing bleeding during cesarean section in placenta previa with accreta include conservative management and cesarean hysterectomy (CH). Conservative management is a method where, after delivery of the child, the surgery is ended with the placenta still inside the uterus; in recent years, many researchers have

Received: April 17 2017.

Accepted: October 8 2017.

Correspondence: Dr Yoshihisa Ono, Center for Maternal, Fetal and Neonatal Medicine, Saitama Medical Center, Saitama Medical University, 1981 Kamoda, Kawagoe, Saitama 350-8550, Japan. Email: yono_p@saitama-med.ac.jp

reported its effectiveness.⁴ The largest retrospective study demonstrated that it was reportedly possible to conserve the uterus in 78% of 167 cases of placenta previa with accreta where conservative management was attempted; however, 51% experienced postoperative bleeding and 22% required a total hysterectomy after surgery.⁵ It has also been reported that 58–60% of patients required a total hysterectomy for reasons such as bleeding, sepsis or disseminated intravascular coagulopathy after a cesarean section, thus a clear consensus has yet to be reached.^{6,7} Conservative management necessitates a long follow-up period with careful observation and indicated cases must be carefully considered because it is necessary to respond quickly to sudden changes. On the other hand, CH involves primary uterus removal after cesarean section, performed in combination with either internal iliac artery ligation (IIAL)⁸ or balloon occlusion catheter placement in the internal iliac artery (internal iliac artery balloon occlusion, IIABO).⁹ However, it has been reported that compared to IIAL, IIABO does not control bleeding during the perioperative period.^{10,11} We encountered 28 patients with placenta previa with accreta who were primarily treated with CH combined with IIAL. However, no significant difference was found upon comparison of the blood loss between the groups with or without IIAL. We believe this was because of the increased collateral circulation from the external iliac artery to the gravid uterus.¹²

In 2005, Shih *et al.* reported that intraoperative bleeding in patients with placenta previa with accreta could be reduced by placing a balloon occlusion catheter in the common iliac artery for temporary blood flow occlusion during CH.¹³ Therefore, since 2006, we have been performing balloon occlusion catheter placement in the common iliac artery (common iliac artery balloon occlusion, CIABO) in surgery for placenta previa with accreta. In the present study, we examined whether CIABO is useful for reducing the blood loss during CH compared to previous procedures and discuss its safety and limitations.

Methods

We retrospectively analyzed 67 patients who underwent CH for placenta previa with accreta at our facility between 1985 and 2014. The ethics committee of Saitama Medical Center/Saitama Medical University approved the study. The requirement for informed consent was waived because of the retrospective

nature. All methods were performed in accordance with the Ethical Guidelines for Medical and Health Research Involving Human Subjects issued by the Ministry of Education, Culture, Sports, Science and Technology and the Ministry of Health, Labour and Welfare of Japan (http://www.lifescience.mext.go.jp/files/pdf/n1500_01.pdf). Ten patients were excluded from the study for the following reasons: hysterectomy was performed in three patients who were transported by emergency means to our hospital from other facilities; delayed hysterectomy was attempted in two patients who had undergone cesarean delivery; the balloon broke during surgery in two patients; the balloon aberrantly entered the external iliac artery in one patient; the balloon was ineffective in one patient because of the wide diameter of the bilateral common iliac artery; and bleeding could not be measured in one patient due to bladder injury. The remaining 57 patients who underwent CH in our department were selected as the study subjects (Fig. 1).

A retrospective comparison of the amount of intraoperative blood loss was performed between the following groups: CH was performed between 1985 and 2000 without blood flow occlusion (no occlusion group: 13 patients), CH was performed using internal iliac artery ligation (IIAL) between 2001 and 2005 (IIAL group: 15 patients), and CH was performed in combination with CIABO between 2006 and 2014 (CIABO group: 29 patients).

The CH procedure with CIABO is as follows. Placement of a 6Fr. balloon catheter was performed under fluoroscopic guidance in the angiography room. When a balloon inserted from the inguinal region is placed in the common iliac artery on the same side, arterial blood flow could cause catheter folding, making it easy for the balloon to shift out of position after dilation. Considering this potential problem, we altered the procedure used by Shih *et al.*¹³ so that balloons were placed by crossing over to the common iliac artery on the opposite side; that is, a catheter inserted from the right femoral artery was used to place a balloon in the left common iliac artery, and a catheter inserted from the left femoral artery was used to place a balloon in the right common iliac artery (Fig. 2). Even when the balloon was dilated, its size was adjusted to decrease peripheral circulation in the common iliac artery, not to completely eliminate the blood flow (Fig. 3). Next, 5 mL of an iodinated contrast agent was infused, and approximately 1 mL of balloon dilation solution was used to adjust the balloon size to cause a three-fold delay to allow the

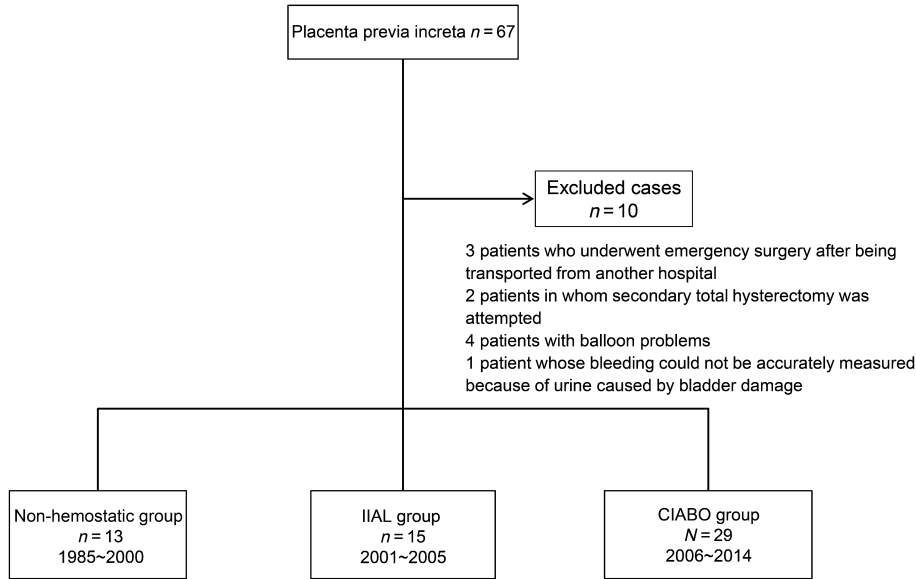


Figure 1 Breakdown of the study subjects. CIABO, common iliac artery balloon occlusion; IIAL, internal iliac artery ligation.

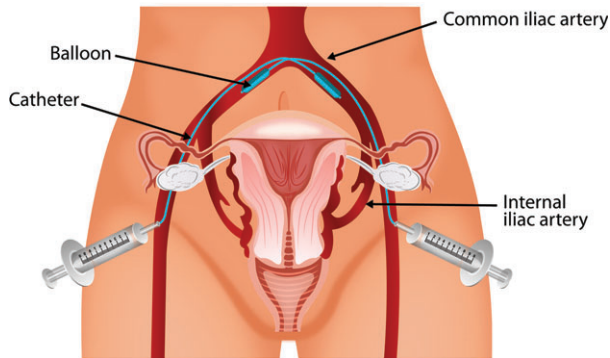


Figure 2 Diagram showing catheter being inserted in a crossover fashion.

contrast agent in the internal and external iliac arteries to dissolve. The patient was then moved to the operating room, and catheters were placed in bilateral ureters in order to prevent ureteral damage during the surgery. Immediately before the surgery

commenced, trial dilation of the balloons was performed to check that the pulse wave of the pulse oximeter attenuated but did not completely disappear (Fig. 4). The uterine incision was made superior to the placenta at some distance away to avoid causing spontaneous placental detachment. After the child was delivered, the umbilical cord was clamped and returned to the inside of the uterus and the uterine incision was sutured and closed. The balloons were dilated when intensive bleeding was observed or when the bladder was detached from the uterus. The balloons were deflated when closure of the vaginal stump was complete. Because of the concern of lower limb ischemia resulting from prolonged balloon dilation, the balloons were dilated for ≤ 60 min and pulse oximeters were worn on both halluces. To prevent thrombosis of the lower limbs, 3000 units of unfractionated heparin were intravenously infused immediately before balloon dilation, and after the balloons

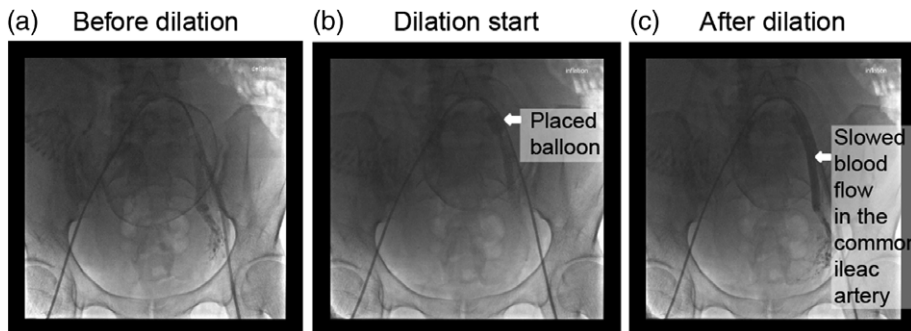


Figure 3 (a) Angiography during balloon placement. (b) Blood vessels are not clearly shown because the blood flow is too fast before balloon dilation. (c) Blood vessels are clearly shown because blood flow slows as the balloon is dilated.

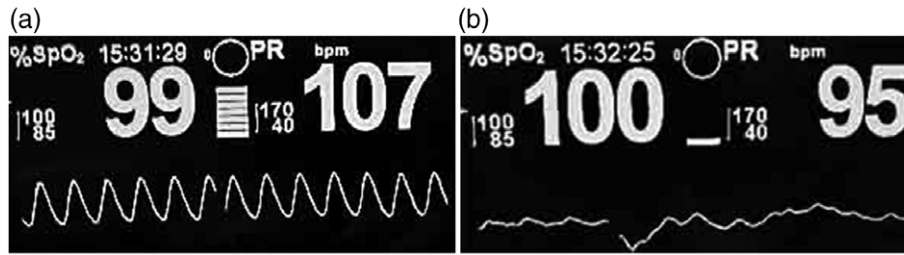


Figure 4 Pulse wave and oxygen saturation before and after balloon dilation. (a) Pulse oximeter worn on the lower limbs during the operation. (b) The pulse wave is shown attenuating but not disappearing after balloon dilation, and oxygen saturation is maintained at 100%.

were deflated the effects of the heparin were neutralized with 30 mg of protamine sulfate.

After the balloons were dilated during the surgery, blood from the dorsalis pedis artery was drawn, and arterial blood oxygen tension (PaO₂) and the serum potassium level were measured to check for effects of ischemia of the lower limbs of the mother. In addition, the cumulative radiation dose when the balloons were placed in the common iliac arteries was measured.

Statistical analysis software JMP version 10.0 was used. Tukey–Kramer honest significant difference tests were performed for group comparisons and multivariate analysis to assess risk factors for massive bleeding during CH. A significant difference was observed with $P < 0.05$.

Results

As shown in Table 1, no significant differences between the three groups were observed regarding

age, number of pregnancies, number of births, number of gestational weeks and operation duration. However, the amount of blood loss was significantly lower in the CIABO than in the no occlusion ($P < 0.05$) and IIAL ($P < 0.01$) groups (Table 1). In addition, multivariate analysis showed that spontaneous placental detachment, non-use of CIABO and a history of ≥ 2 cesarean sections were significantly associated with massive intraoperative bleeding (≥ 1500 mL). The odds ratio (OR) of massive bleeding when CIABO was not used was 26.403 (confidence interval [CI] 95% 3.20–645.17; $P = 0.005$) (Table 2).

The mean time of balloon dilation during the operation was 41.8 ± 15.0 min. Because of the concern of ischemic necrosis in the lower limbs as a result of balloon dilation, peripheral arterial blood was drawn every 10 min after dilation in 11 of the 29 CIABO group patients to measure oxygen tension (PaO₂) and serum potassium levels. The results showed that PaO₂ was maintained at 90 mmHg or higher, with no hyperkalemia. None of the 29 patients displayed

Table 1 Patient characteristics and perioperative results

Characteristic/Result	No occlusion group (<i>n</i> = 13)	IIAL group (<i>n</i> = 15)	CIABO group (<i>n</i> = 29)	<i>P</i>
	Mean \pm SD	Mean \pm SD	Mean \pm SD	
Age	34.0 \pm 3.9	34.9 \pm 3.4	33.7 \pm 3.8	NS
Gravida	2.7 \pm 1.1	2.5 \pm 1.5	2.6 \pm 1.6	
Parity	1.5 \pm 0.7	2.0 \pm 1.1	1.8 \pm 1.0	NS
Gestational weeks	35 \pm 2.2	34.1 \pm 2.5	34.8 \pm 1.5	NS
Spontaneous placental detachment	6	3	6	
Pathological findings of placenta				
Accreta	1	4	17	
Increta	6	8	7	
Percreta	6	3	5	
Operative time (min)	197.6 \pm 56.1	182.8 \pm 51.0	176.3 \pm 46.8	NS
Blood loss (mL)	3786.7 \pm 2936.1*	4175 \pm 1921.3**	2027.1 \pm 1637.6**,**	

* $P < 0.05$; ** $P < 0.01$. CIABO, common iliac artery balloon occlusion; IIAL, internal iliac artery ligation; NS, not significant; SD, standard deviation.

Table 2 Multivariate analysis showing risk factors related to massive bleeding (1500 mL or more)

Risk Factors	Odds ratio	95% CI	P
Spontaneous placental detachment	49.174	4.983–1763.666	0.0002
No use of CIABO	26.403	3.198–645.174	0.001
History of ≥ 2 cesarean sections	9.226	1.074–213.146	0.042
Pathological findings of placenta percreta	3.328	0.442–34.223	0.247

CI, confidence interval; CIABO, common iliac artery balloon occlusion.

symptoms of ischemia in the lower limbs after surgery (Fig. 5). The mean radiation dose during balloon placement in the bilateral common iliac arteries was 29.4 ± 25.0 mGy.

CIABO was not successful in four of the ineligible patients. The balloon broke in two patients, resulting in blood loss of 1400 mL as a result of unilateral balloon breakage and 2190 mL because of bilateral balloon breakage. The pulse wave of the oximeters worn on both halluces did not attenuate in one patient, even after the balloon was maximally inflated, resulting in 6000 mL of blood loss during surgery and completely disappeared in one patient after bilateral balloon dilation during surgery. This was attributed to the bilateral aberrant entry of the balloon into the external iliac arteries and resulted in 4000 mL of blood loss.

Discussion

Our results suggest that blood loss is significantly lower when CH is combined with CIABO than in either CH performed without blood flow occlusion or CH combined with IIAL. Multivariate analysis of risk

factors for blood loss during CH revealed that CIABO is an independent factor for reducing blood loss during CH in patients with placenta previa with accreta. Since Shih *et al.*'s study,¹³ a number of reports have demonstrated the efficacy of CIABO,^{14,15} while Sinan *et al.* reported that there was no significant difference in intraoperative blood loss or transfusion between 25 patients who underwent CH with and 27 who underwent CH without the use of CIABO for placenta previa with accreta.¹⁶ Because the numbers of patients were limited in these retrospective studies, a large-scale, multicenter prospective study needs to be performed.

Many studies have reported successful conservative management of placenta previa with accreta. Rauf *et al.* recently reported that hysterectomy was avoided in 32 patients with placenta previa with accreta by IIAL and endouterine hemostatic suture; however, hysterectomy was necessary in six patients.¹⁷ We have also had successful cases of conservative management, but the limitation of conservative management is that many cases are not validated by pathological findings. Therefore, in this study, we focused on cases that underwent CH.

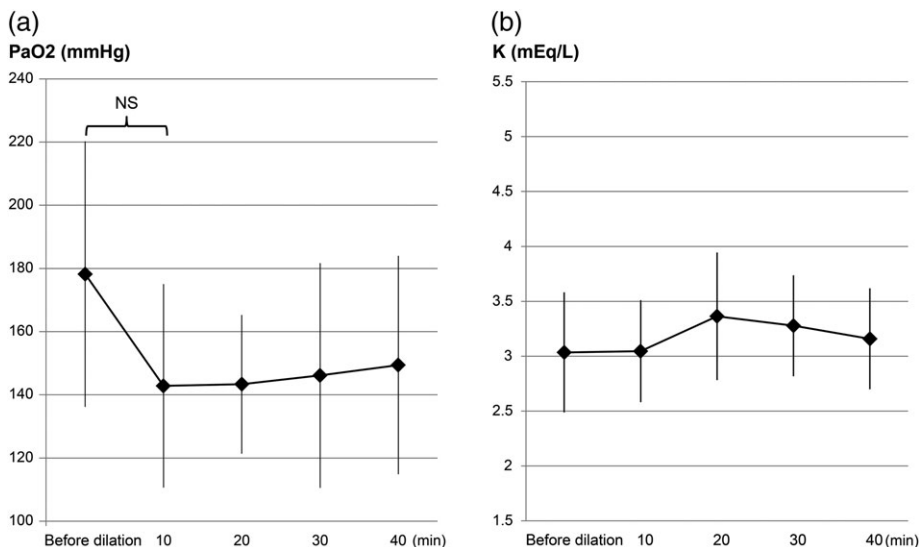


Figure 5 Partial pressure of (a) oxygen and (b) serum K concentration of the dorsalis pedis artery after dilation ($n = 11$).

Collateral circulation connecting the internal iliac artery with the external iliac artery, such as the gluteal, obturator and iliolumbar arteries is possible.^{18,19} Even if blood flow in the internal iliac artery is occluded, blood flow to the uterus is maintained via collateral circulation from the external iliac artery, thus bleeding is not sufficiently controlled by occluding the internal iliac artery only. It is believed that bleeding is controlled by blocking circulation in the common iliac artery in order to simultaneously block circulation in both the external and internal iliac arteries.

Reported methods of interruption of blood flow include total occlusion within 60 min¹⁴ and repeated inflation and deflation every 5 min,¹⁵ but we have used partial occlusion until the blood flow speed reaches 1/3. This method of blood flow interruption, even when performed for 40 min, does not reduce the partial oxygen pressure or increase the potassium levels of dorsalis pedis arterial blood, and no patients have experienced any complications, such as necrosis resulting from lower limb ischemia. A tourniquet used at the time of surgery for arms and legs can cause incomplete ischemia by using air pressure to block circulation, and according to a previous report, injury to the muscles can be minimized if the ejection time is within 90 min.²⁰ Therefore, surgery can be performed safely if incomplete ischemia from CIABO is within 60 min.

Radiation exposure of ≤ 100 mGy to the fetus during the latter period of pregnancy is believed to have a negligible effect.²¹ The mean radiation dose from angiography during balloon placement in our cohort was 29.4 ± 25.0 mGy, which did not exceed the threshold value. Thus, balloon placement can be performed without exposing the fetus to excessive radiation.

Thrombosis in the external iliac artery is reported as a complication of CIABO, but thrombosis did not occur in the 29 patients who underwent CH using CIABO in our study. While thrombosis was reported in cases in which heparin was not administered²² or periodic local infusion of heparinized saline solution was performed through the balloon catheter,¹⁴ in our department, 3000 units of unfractionated heparin is infused immediately before balloon dilation.

The four patients deemed ineligible for the study because of balloon problems are discussed further as follows. A latex balloon made by Selecon Company was used in the initial 10 patients, but the balloon broke in two. The balloon was subsequently switched

to a polyvinyl chloride balloon made by Clinical Supply Co and no breakage has since occurred. Although a balloon diameter of 1 cm is usually sufficient for use in CIABO, blood flow did not decrease when the balloon was dilated in one patient because of the wide internal diameter of the common iliac artery. In patients such as these, a balloon catheter with a larger diameter must be available.

In the initial cases, complete disappearance of pulse waves in pulse oximetry taken from both halluces occurred and was attributed to deflection of the catheter because of the blood flow, causing aberrant entry of the balloon into the external iliac artery. Aberrant balloon entry into the external iliac artery can not only cause crash syndrome because of complete ischemia, but also increased blood flow to the internal iliac artery and increased intraoperative blood loss. Therefore, in subsequent cases, the balloon was placed between the catheter insertion site and the contralateral common iliac artery in order to prevent deflection of the catheter, as shown in Figure 2. After checking attenuation of the pulse wave by the internal iliac artery or pulse oximetry at the hallux after balloon dilation once the patient had been placed in the surgical position, it was considered that surgery would never be performed with the balloon aberrantly entering the external iliac artery. If a balloon catheter could be placed under fluoroscopic guidance after the patient was transferred to the operating room and placed in the surgical position (which was impossible in the present study), displacement of the balloon as a result of patient transfer and positioning could be avoided.

Because this was a long-term retrospective study, it was limited a lack of sufficient information, such as the amount of blood transfusion, thus a learning bias cannot be ruled out. Future studies comparing the amount of transfused blood would provide stronger evidence of the efficacy of CIABO.

In conclusion, by combining CIABO with CH for placenta previa with accreta, perioperative blood loss could be reduced in most patients. No necrosis in the lower limbs of the mother occurred and the radiation dose to the fetus was negligible, suggesting that this procedure can be performed safely. It is important to place appropriately sized catheters by crossing them over each other. Also, to prevent performing hysterectomy with the aberrant balloon entry into the external iliac artery, it is important to check the attenuation of the external iliac artery pulse caused by the dilation of the balloons immediately before surgery.

Acknowledgments

The authors would like to thank all of the doctors in their department for their great contributions to patient management and the doctors in their district for their prompt referral and initial management.

Disclosure

No author has any potential conflict of interest.

Author contributions

Y.O. designed the study, and wrote the initial draft of the manuscript and revising the manuscript. S.M. and Y.T. contributed to analysis and interpretation of data. S.E. and H.O. contributed to the management of enrolled patient treatment. Y.M. assisted in the preparation of the manuscript. K.B., S.T and S.H. contributed to the study concept and design. All other authors critically reviewed the manuscript. All authors have read and approved the final version of the manuscript.

References

1. Benirschke K. Placentas, peccaries, and pathologists: Reminiscences of Kurt Benirschke on his career: An interview with Rebecca N. Baergen. *Int J Gynecol Pathol* 2002; **21**: 289–300.
2. Clark SL, Koonings PP, Phelan JP. Placenta previa/accreta and prior cesarean section. *Obstet Gynecol* 1985; **66**: 89–92.
3. Miller DA, Chollet JA, Goodwin TM. Clinical risk factors for placenta previa-placenta accreta. *Am J Obstet Gynecol* 1997; **177**: 210–214.
4. Sawada M, Matsuzaki S, Mimura K, Kumasawa K, Endo M, Kimura T. Successful conservative management of placenta percreta: Investigation by serial magnetic resonance imaging of the clinical course and a literature review. *J Obstet Gynaecol Res* 2016; **42**: 1858–1863.
5. Sentilhes L, Ambroselli C, Kayem G *et al.* Maternal outcome after conservative treatment of placenta accreta. *Obstet Gynecol* 2010; **115**: 526–534.
6. Clausen C, Lönn L, Langhoff-Roos J. Management of placenta percreta: A review of published cases. *Acta Obstet Gynecol Scand* 2014; **93**: 138–143.
7. Pather S, Strockyj S, Richards A, Campbell N, de Vries B, Ogle R. Maternal outcome after conservative management of placenta percreta at caesarean section: A report of three cases and a review of the literature. *Aust N Z J Obstet Gynaecol* 2014; **54**: 84–87.
8. Reich WJ, Nechtow MJ. Ligation of the internal iliac (hypogastric) arteries: A life-saving procedure for uncontrollable gynecologic and obstetric hemorrhage. *J Int Coll Surg* 1961; **36**: 157–168.
9. Dubois J, Garel L, Grignon A, Lemay M, Leduc L. Placenta percreta: Balloon occlusion and embolization of the internal iliac arteries to reduce intraoperative blood losses. *Am J Obstet Gynecol* 1997; **176**: 723–726.
10. Salim R, Chulski A, Romano S, Garmi G, Rudin M, Shalev E. Precesarean prophylactic balloon catheters for suspected placenta accreta: A randomized controlled trial. *Obstet Gynecol* 2015; **126**: 1022–1028.
11. Shrivastava V, Nageotte M, Major C, Haydon M, Wing D. Case-control comparison of cesarean hysterectomy with and without prophylactic placement of intravascular balloon catheters for placenta accreta. *Am J Obstet Gynecol* 2007; **197**: 402.e1–402.e5.
12. Iwata A, Murayama Y, Itakura A, Baba K, Seki H, Takeda S. Limitations of internal iliac artery ligation for the reduction of intraoperative hemorrhage during cesarean hysterectomy in cases of placenta previa accreta. *J Obstet Gynaecol Res* 2010; **36**: 254–259.
13. Shih JC, Liu KL, Shyu MK. Temporary balloon occlusion of the common iliac artery: New approach to bleeding control during cesarean hysterectomy for placenta percreta. *Am J Obstet Gynecol* 2005; **193**: 1756–1758.
14. Chou MM, Kung HF, Hwang JI, Chen WC, Tseng JJ. Temporary prophylactic intravascular balloon occlusion of the common iliac arteries before cesarean hysterectomy for controlling operative blood loss in abnormal placentation. *Taiwan J Obstet Gynecol* 2015; **54**: 493–498.
15. Minas V, Gul N, Shaw E, Mwenenchanya S. Prophylactic balloon occlusion of the common iliac arteries for the management of suspected placenta accreta/percreta: Conclusions from a short case series. *Arch Gynecol Obstet* 2015; **291**: 461–465.
16. Al-Hadethi S, Fernando S, Hughes S, Thakorlal A, Seruga A, Scurry B. Does temporary bilateral balloon occlusion of the common iliac arteries reduce the need for intra-operative blood transfusion in cases of placenta accretism? *J Med Imaging Radiat Oncol* 2017; **61**: 311–316.
17. Rauf M, Ebru C, Sevil E, Selim B. Conservative management of post-partum hemorrhage secondary to placenta previa-accreta with hypogastric artery ligation and endo-uterine hemostatic suture. *J Obstet Gynaecol Res* 2017; **43**: 265–271.
18. Chait A, Moltz A, Nelson JH Jr. The collateral arterial circulation in the pelvis. An angiographic study. *Am J Roentgenol Radium Ther Nucl Med* 1968; **102**: 392–400.
19. Clark SL, Phelan JP, Yeh SY, Bruce SR, Paul RH. Hypogastric artery ligation for obstetric hemorrhage. *Obstet Gynecol* 1985; **66**: 353–356.
20. Kam PC, Kavanagh R, Yoong FF. The arterial tourniquet: Pathophysiological consequences and anaesthetic implications. (Published erratum appears in *Anaesthesia* 2001; **56**: 821.) *Anaesthesia* 2001; **56**: 534–545.
21. Streffer C, Shore R, Konermann G *et al.* Biological Effects After Prenatal Irradiation (Embryo And Fetus). A Report Of The International Commission on Radiological Protection. *Ann ICRP* 2003; **33**: 5–206.
22. Matsueda S, Hidaka N, Kondo Y, Fujiwara A, Fukushima K, Kato K. External iliac artery thrombosis after common iliac artery balloon occlusion during cesarean hysterectomy for placenta accreta in cervico-isthmic pregnancy. *J Obstet Gynaecol Res* 2015; **41**: 1826–1830.