

Case Series

# Azathioprine Hypersensitivity Syndrome: Two Cases of Febrile Neutrophilic Dermatositis Induced by Azathioprine

Majed Aleissa<sup>a, b</sup> Perrine Nicol<sup>a, b</sup> Marion Godeau<sup>a, b</sup> Emilie Tournier<sup>a, c</sup>  
Frederic de Bellissen<sup>e</sup> Marie-Angèle Robic<sup>a, d</sup> Cristina Bulai Livideanu<sup>a, b</sup>  
Juliette Mazereeuw-Hautier<sup>a, b</sup> Carle Paul<sup>a, b</sup>

<sup>a</sup>Paul Sabatier University, University Hospitals of Toulouse, Toulouse, France;

<sup>b</sup>Department of Dermatology, University Hospitals of Toulouse, Toulouse, France;

<sup>c</sup>Department of Histopathology, University Hospitals of Toulouse, Toulouse, France;

<sup>d</sup>Department of Gastroenterology, University Hospitals of Toulouse, Toulouse, France;

<sup>e</sup>Cabinet De Bellisen Polyclinique, Carcassonne, France

## Keywords

Azathioprine · Azathioprine hypersensitivity syndrome · Drug reaction · Neutrophilic dermatosis · Sweet syndrome · Inflammatory bowel disease

## Abstract

**Background:** Azathioprine is an immunosuppressive agent used in the treatment of immune-mediated diseases. Azathioprine hypersensitivity syndrome is a rare adverse reaction occurring a few days to weeks after the administration of azathioprine. **Case 1:** A 36-year-old male with ulcerative colitis presented with erythematous plaques, pustules and erosions on the lower back, buttocks and thighs associated with high fever (39°C) 2 weeks after the initiation of azathioprine 100 mg/day. Additional findings included leukocytosis (18.6 g/L) with neutrophilia (11.1 g/L) and elevated C-reactive protein (128 mg/L). Histopathology showed a dense infiltrate of neutrophils in the hair follicles. We increased the dose of prednisone to 1 mg/kg/day (60 mg/day) and azathioprine was discontinued. He had marked improvement within 3 weeks and did not have any relapse with a 1-year follow-up. **Case 2:** A 57-year-old

male with ulcerative colitis presented with erythematous plaques and pustules on the lower limbs associated with high fever (40°C) 1 week after the initiation of azathioprine 75 mg/day. Leukocytosis with neutrophilia (13.6 g/L) and elevated C-reactive protein (344 mg/L) were among the laboratory findings. Histopathology showed a dense infiltrate of neutrophils in the hair follicles. The dose of prednisone was increased to 20 mg/day and azathioprine was discontinued, which led to complete remission within 7 days. He did not have any relapse with a 6-month follow-up. **Conclusion:** The development of acute neutrophilic dermatitis 2 weeks after the initiation of azathioprine and the complete resolution after its withdrawal were in favor of azathioprine hypersensitivity syndrome. It should not be confused with Sweet syndrome associated with inflammatory bowel disease, as maintenance of azathioprine treatment may lead to life-threatening reactions.

© 2017 The Author(s)  
Published by S. Karger AG, Basel

## Introduction

Azathioprine is an immunosuppressive agent used in the treatment of a variety of conditions, including inflammatory bowel diseases, connective tissue diseases, pemphigus, atopic dermatitis and neurological diseases. It inhibits DNA and RNA synthesis [1]. Azathioprine hypersensitivity syndrome is a rare adverse reaction occurring a few days to weeks after treatment introduction [1]. An acute febrile neutrophilic dermatosis is the most recognized clinical pattern [2]. A diagnosis of azathioprine hypersensitivity syndrome may be delayed as its findings can mimic systemic infection or neutrophilic dermatitis associated with an immunological condition, such as inflammatory bowel disease, for which azathioprine was initiated [1]. The cessation of azathioprine and the treatment with oral steroids led to a complete remission in all cases reported [1, 2]. Rechallenge with azathioprine is not recommended [3, 4]. We present here 2 cases of azathioprine hypersensitivity syndrome in patients with ulcerative colitis.

## Case 1

A 36-year-old male known to have ulcerative colitis, diagnosed in 2007 and previously treated with azathioprine and mesalazine, was seen at the gastroenterology department for a moderate exacerbation of his condition. Azathioprine 100 mg/day was initiated along with prednisone 40 mg/day. Of note, the patient's thiopurine methyltransferase (TPMT) activity was not measured. Two weeks later, he presented with a painful skin eruption on the back, buttocks and thighs associated with high fever (39°C). On examination, there were multiple tender erythematous plaques, pustules and erosions on the lower back, buttocks and thighs (Fig. 1). Laboratory evaluation was notable for leukocytosis (18.6 g/L) with neutrophilia (11.1 g/L) and elevated C-reactive protein (128 mg/L). Bacterial cultures were negative (a swab was taken from a pustular lesion). The histopathology findings showed a dense infiltrate of neutrophils in the hair follicles; no papillary dermal edema was found and no evidence of vasculitis (Fig. 2). We established the diagnosis of azathioprine hypersensitivity syndrome. We increased the dose of prednisone to 1 mg/kg/day (60 mg daily) and azathioprine was discontinued. The patient had marked improvement within 3 weeks with a complete regression of the lesions. Prednisone was tapered slowly over a few months. The patient did not have any relapse with a 1-year follow-up.

## Case 2

A 57-year-old male, diagnosed with ulcerative colitis in 2015, presented with a painful skin eruption associated with high fever (40°C) 1 week after the initiation of azathioprine 75 mg/day and prednisone 10 mg/day for a flare-up of his condition. Clinically, there were tender erythematous plaques and pustules on the lower limbs (Fig. 3). Leukocytosis with neutrophilia (13.6 g/L) and elevated C-reactive protein (344 mg/L) were among the laboratory findings. Bacterial cultures were negative. The histopathology findings showed a dense infiltrate of neutrophils in the hair follicles with no papillary dermal edema and no evidence of vasculitis. The dose of prednisone was increased to 20 mg/day and azathioprine was discontinued. This led to complete remission within 7 days. The patient did not have any relapse with a 6-month follow-up.

## Discussion

The association of neutrophilic dermatosis and inflammatory bowel diseases is well reported in the literature. However, in the 2 presented patients, the appearance of symptoms and signs within 2 weeks after the initiation of azathioprine and the complete resolution after its withdrawal were in favor of the diagnosis of azathioprine hypersensitivity syndrome.

Azathioprine is a purine antagonist. Its initial metabolism results in 6-mercaptopurine (6-MP) and the imidazole derivative (methyl nitroimidazole moiety) [5]. The metabolism of 6-MP by hypoxanthine phosphoribosyl transferase results in 6-thioguanine nucleotides, which are the active metabolites that disrupt the function of endogenous purines. They are responsible for the drug action and induce the dose-dependent side effects, such as myelosuppression, infection, nausea, vomiting and hepatotoxicity [2, 5]. Further metabolism of 6-MP by TPMT and xanthine oxidase yields inactive metabolites [5]. However, hypersensitivity reactions to azathioprine are dose independent, and they occur regardless of TPMT level [2, 3]. While the 6-MP moiety of azathioprine and its metabolites is thought to be responsible for most side effects, the imidazole component could be responsible for hypersensitivity reactions [2, 3]. The exact mechanism is still not clear.

In a literature review of 67 cases of azathioprine hypersensitivity syndrome [2], Sweet syndrome was the most frequently recognized dermatological clinical pattern with 12 cases. Other clinical patterns with cutaneous findings included erythema nodosum, small vessel vasculitis, acute generalized exanthematous pustulosis and nonspecific dermatosis. The majority of patients developed symptoms and signs 5–25 days after the initiation of azathioprine. Inflammatory bowel disease and neurological disease (multiple sclerosis) were the most common underlying diseases, comprising almost half of the patients. All cases reviewed showed either a normal TPMT level or did not report it [2].

In a recent article, 18 cases of neutrophilic dermatosis induced by azathioprine were reviewed [1]. Fever, painful erythematous plaques, leukocytosis, neutrophilia, elevated C-reactive protein and a histopathology of a dermal neutrophilic infiltrate with no evidence of vasculitis were among the most common findings. Of note, in 2 cases, neutrophilic infiltration into hair follicles, similar to the histopathology of our patients, was reported. Unlike our cases, the most common locations of lesions were the face, trunk, and upper extremities [1].

The Sweet-like clinical pattern of azathioprine hypersensitivity syndrome and the classic Sweet syndrome have a lot of similarities. However, in some cases [1], as in ours, the lack

of the massive papillary dermal edema and the hallmark dense dermal neutrophilic infiltrate in histopathology, as well as the lack of the classical sites of lesions usually seen in Sweet syndrome and the presence of polymorphic phenotypes of lesions, suggest that they should be regarded as 2 distinct entities.

### Conclusion

Azathioprine hypersensitivity syndrome may mimic an acute neutrophilic dermatosis. It is typically reversible on azathioprine cessation [1, 4], but subsequent avoidance is crucial as rechallenge can lead to a more severe adverse reaction and even death [1, 6]. Therefore, it requires prompt diagnosis and must be distinguished from neutrophilic dermatosis associated with inflammatory bowel disease.

### Statement of Ethics

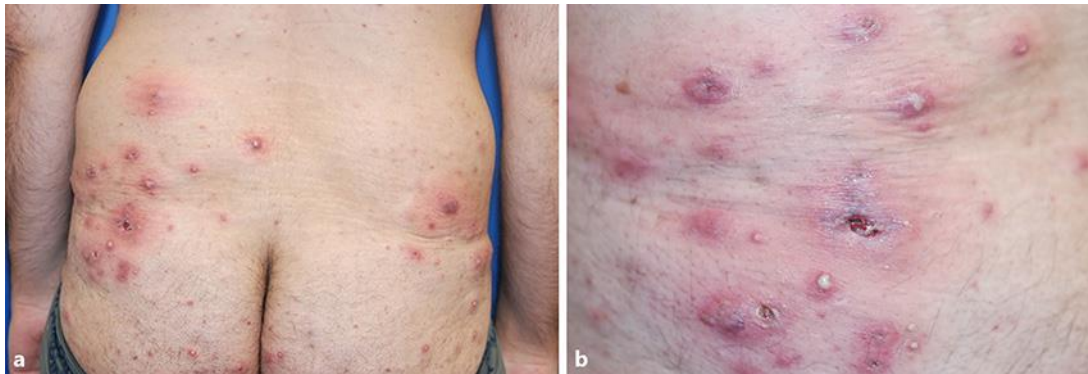
Ethical approval has been sought and obtained.

### Disclosure Statement

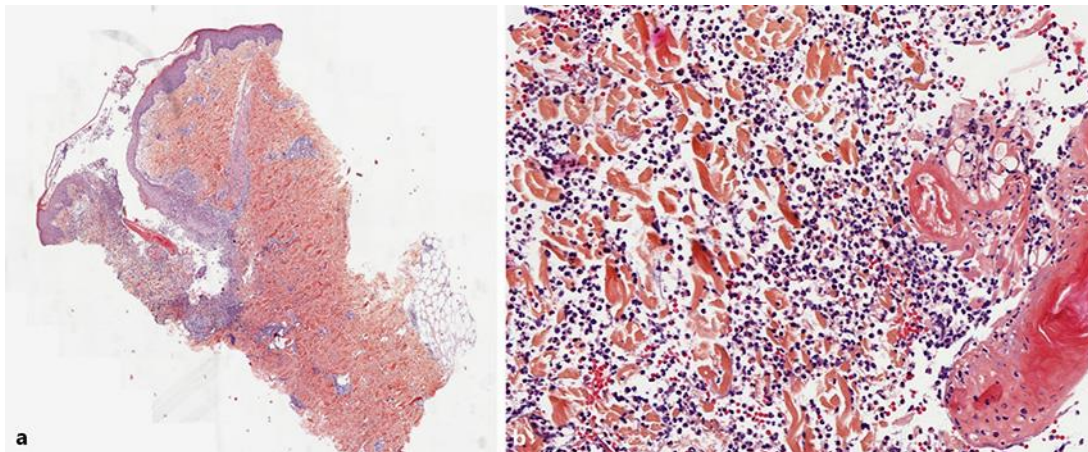
The authors have no conflicts of interest to disclose.

### References

- 1 Cyrus N, Stavert R, Mason AR, Ko CJ, Choi JN: Neutrophilic dermatosis after azathioprine exposure. *JAMA Dermatol* 2013;149:592–597.
- 2 Bidinger JJ, Sky K, Battafarano DF, Henning JS: The cutaneous and systemic manifestations of azathioprine hypersensitivity syndrome. *J Am Acad Dermatol* 2011;65:184–191.
- 3 Choonhakarn C, Chaowattanapanit S: Azathioprine-induced Sweet's syndrome and published work review. *J Dermatol* 2013;40:267–271.
- 4 Grelle JL, Halloush RA, Khasawneh FA: Azathioprine-induced acute febrile neutrophilic dermatosis (Sweet's syndrome). *BMJ Case Rep* 2013, DOI: 10.1136/bcr-2013-200405.
- 5 Patel AA, Swerlick RA, McCall CO: Azathioprine in dermatology: the past, the present, and the future. *J Am Acad Dermatol* 2006;55:369–389.
- 6 Olaiwan A, Wendling J, Pouzoulet J, Gaulier A, Ingen-Housz-Oro S, Sigal M: Manifestations cutanées d'un syndrome d'hypersensibilité à l'azathioprine chez un patient atteint d'une maladie de Crohn. *Gastroenterol Clin Biol* 2008;32:1075–1076.

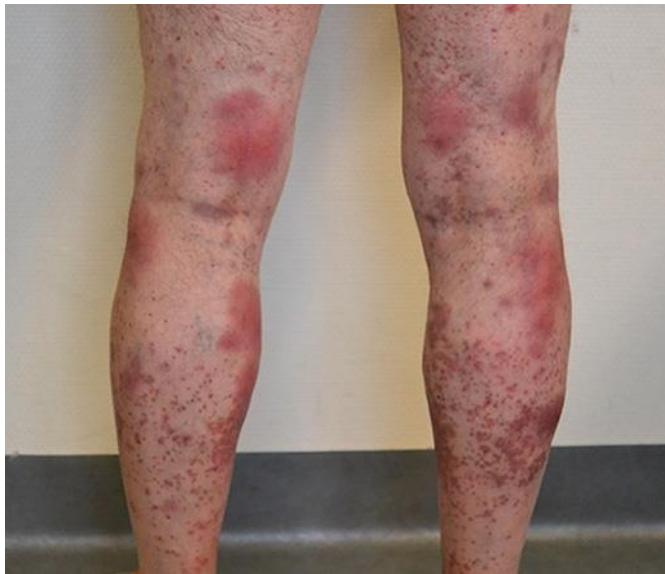

**Fig. 1.** Clinical presentation: tender erythematous papules and plaques (a) with pustules and erosions (b) over the lower back and buttocks.



**Fig. 2.** Histopathological features. **a** Lesion of acute folliculitis. Note the absence of the marked dermal edema and the hallmark diffuse neutrophilic dermal infiltration usually seen in classic Sweet syndrome. HE, original magnification  $\times 50$ . **b** Dense neutrophilic infiltrate in the hair follicle. HE, original magnification  $\times 200$ .





**Fig. 3.** Tender erythematous plaques over the lower limbs.