



Contents lists available at ScienceDirect

## International Journal of Surgery Case Reports

journal homepage: [www.casereports.com](http://www.casereports.com)

# Rectal free perforation after stapled hemorrhoidopexy: A case report of laparoscopic peritoneal lavage and repair without stoma<sup>☆</sup>

Seokyong Ryu<sup>a</sup>, Byung-Noe Bae<sup>b,\*</sup><sup>a</sup> Department of Emergency Medicine, Inje University Sanggye Paik Hospital, Seoul, Republic of Korea<sup>b</sup> Department of General Surgery, Inje University Sanggye Paik Hospital, Seoul, Republic of Korea

## ARTICLE INFO

## Article history:

Received 30 August 2016

Received in revised form

18 November 2016

Accepted 18 November 2016

Available online 21 November 2016

## Keywords:

Rectal perforation

Stapled hemorrhoidopexy

Laparoscopic surgery

Transanal rectal tube

Case report

## ABSTRACT

**INTRODUCTION:** Stapled hemorrhoidopexy is widely performed for treatment of prolapsed hemorrhoids because of advantages, including shorter hospital stay and less discomfort, compared with conventional hemorrhoidectomy. However, it can have severe adverse effects, such as rectal bleeding, perforation, and sepsis.

**PRESENTATION OF CASE:** We report the case of a healthy 28-year-old man who presented to the emergency department with sudden-onset diffuse abdominal pain and hematochezia. He had undergone stapled hemorrhoidopexy 5 days earlier and was discharged after an uneventful postoperative course. For the present condition, after immediate evaluation, we successfully performed emergency laparoscopic repair of the rectal perforation without any stoma. His postoperative course was uneventful, and he was discharged on postoperative day 16.

**DISCUSSION:** This is a rare case of rectal perforation after stapled hemorrhoidopexy in which the perforation was treated successfully by laparoscopic repair. In most cases of rectal perforation following stapled hemorrhoidopexy, surgeons perform open laparotomy and create diverting stoma. However, our patient underwent totally laparoscopic lavage and primary closure without diverting stoma. Multiple investigators have reported that laparoscopic lavage for perforated diverticulitis may be an appropriate treatment option. Factors favoring this approach include early surgery, young age, sufficient irrigation, and meticulous primary closure.

**CONCLUSION:** Stapled hemorrhoidopexy can have severe adverse effects, such as rectal bleeding, pelvic sepsis, and rectal perforation, which are potentially life-threatening. Laparoscopic lavage and primary repair without stoma can be performed successfully in select patients with rectal perforation following stapled hemorrhoidopexy.

© 2016 The Author(s). Published by Elsevier Ltd on behalf of IJS Publishing Group Ltd. This is an open access article under the CC BY-NC-ND license (<http://creativecommons.org/licenses/by-nc-nd/4.0/>).

## 1. Introduction

Most patients with hemorrhoidal disease are treated conservatively. Several surgical options also are available, including closed, open, and semiclosed hemorrhoidectomy; radiofrequency ablation; ligature or harmonic scalpel hemorrhoidectomy; stapled hemorrhoidopexy; and Doppler hemorrhoidal artery ligation [1]. Surgical stapling is a simple and effective treatment for third- and fourth-degree hemorrhoids. It has a shorter hospitalization period and causes less discomfort than conventional operations. However, this procedure is associated with severe adverse effects, such as rectal bleeding, pelvic sepsis, and rectal perforation, which can be

life-threatening [2–4]. Rectal free perforation after stapled hemorrhoidopexy is extremely rare, and most patients are treated with laparotomy and stoma formation for fecal diversion.

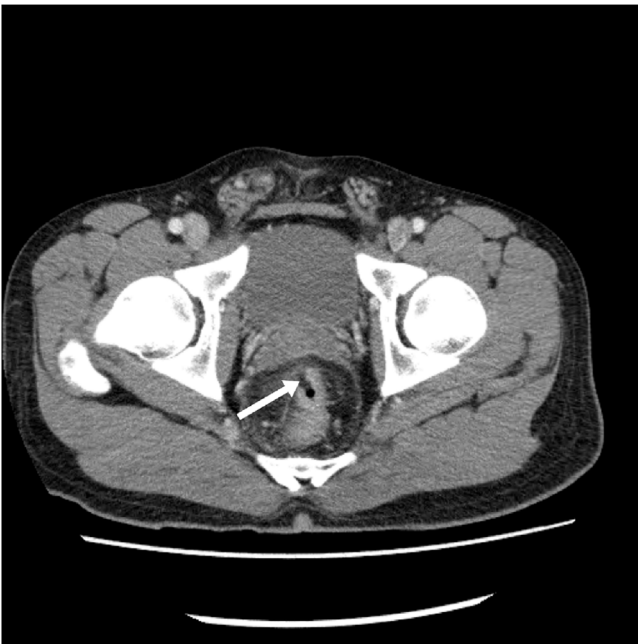## 2. Presentation of case

A previously healthy 28-year-old man presented to the emergency department with sudden-onset diffuse abdominal pain and hematochezia. He had undergone stapled hemorrhoidopexy 5 days earlier and was discharged after an uneventful postoperative course. At the recent presentation, he described the pain as continuous and 10/10 in severity. His medical history was noncontributory. His blood pressure was 148/79 mm Hg, heart rate was 79 beats/min, respiratory rate was 20 breaths/min, and temperature was 36.4 °C. His abdomen was rigid and diffusely tender. Cardiovascular examination was normal, with no murmurs detected. Electrocardiography showed sinus rhythm with a rate of 68 and no signs of ischemic changes. Digital rectal examination

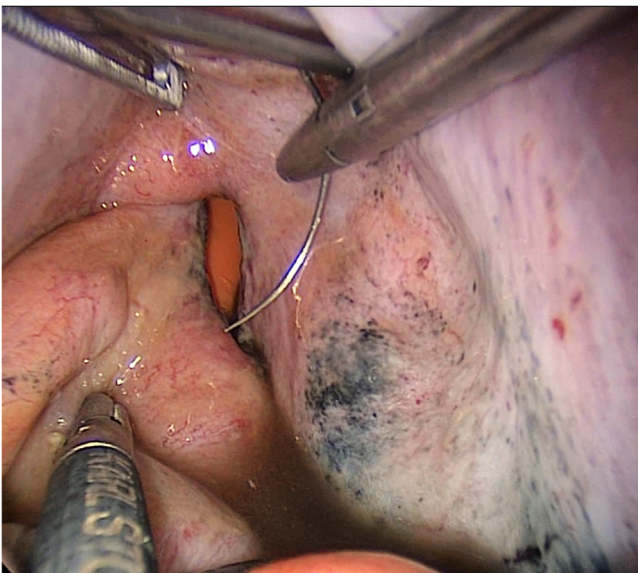
<sup>☆</sup> This work originated from the Inje University Sanggye Paik Hospital, Seoul, Republic of Korea.

\* Corresponding author at: Inje University Sanggye Paik Hospital, 1342, Donggil-ro, Wonon-gu, Seoul, Republic of Korea.

E-mail address: [bnbae@paik.ac.kr](mailto:bnbae@paik.ac.kr) (B.-N. Bae).



**Fig. 1.** Coronal computed tomography scan, showing focal disruption of the rectum (white arrow).



**Fig. 2.** Laparoscopic primary repair was performed successfully at the rectal perforation site.

revealed hematochezia but no other abnormal findings. Laboratory findings were unremarkable. Chest radiography showed free air in the right subdiaphragmatic area. Based on these findings, we suspected peritonitis due to bowel perforation. Abdominopelvic computed tomography revealed rectal perforation due to stapled hemorrhoidectomy dehiscence (Fig. 1). We immediately decided to perform emergency surgery.

Under general anesthesia, we gently inserted a transanal rectal tube. Laparoscopic examination using a 10-mm 30° scope and three 5-mm laparoscopic instruments revealed dirty fluid and some food material. After copious saline irrigation with various patient positions, including the Trendelenburg position and reverse position, the dehiscence was detected and sutured with the V-Loc absorbable wound closure device (Covidien, Minneapolis, MN, USA) (Fig. 2). The needle of the V-Loc unrolled to form a J-shape for the 5-mm

trocars. Laparoscopic primary repair was performed successfully, and one abdominal closed drain was placed in the peritoneal cavity. All procedures were performed using laparoscopic instruments. Instead of creating a protective stoma, the transanal rectal tube was kept in place for 7 days. The patient's postoperative course was uneventful, and he was discharged home on postoperative day 16.

### 3. Discussion

Stapled hemorrhoidopexy is a widely accepted surgical technique for prolapsed internal hemorrhoids because of advantages, including shorter hospital stay and less discomfort, compared with conventional hemorrhoidectomy [2,3]. However, this procedure for prolapsed hemorrhoids (PPH) is associated with adverse effects, collectively referred to as “PPH syndrome,” consisting of proctalgia, tenesmus, urgency, and rectovaginal fistula [1]. Furthermore, studies have reported major complications requiring fecal diversion, such as retroperitoneal sepsis and intraperitoneal rectal perforation, which are potentially life-threatening [4–7]. The most common early complication is rectal bleeding; its incidence ranges from 4% to 8%, and approximately 5% of minor rectal bleeding requires early reintervention [8].

Here, we reported a rare complication—rectal free perforation—that occurred after stapled hemorrhoidopexy. A 28-year-old man had fourth-degree hemorrhoids and intermittent anal bleeding. However, we could reduce most of the hemorrhoidal tissue preoperatively and performed stapled hemorrhoidopexy with a Chex CPH34 HV device (Frankenman Medical Equipment, Suzhou, China) in the lithotomy position. Neither bleeding nor hematoma was observed after firing, and the patient was discharged uneventfully. However, he revisited our emergency department on postoperative day 5 because of rectal free perforation. The plausible cause of perforation was determined as excessive tissue housing including the rectal muscle by using a high-volume device. After rectal repair, we re-examined the formalin-fixed specimen and found some smooth muscle tissue without the serosal layer. Thus, the purse-string suture was placed beyond the submucosa. However, we thought that the staple line was not too high. Thus, the reason for free perforation instead of retroperitoneal sepsis was presumed that the patient had a deep recto-vesical pouch. The surgeon who performed the stapled hemorrhoidopexy ruminated on this case. If the staple line is too high, the full-thickness anterior rectal wall can be easily excised. In addition, it is imperative that the purse-string suture be placed within the submucosal layer. Finally, internalization of the smooth muscle in the resected doughnut may cause life-threatening complications [4,9,10].

Faucheron et al. reviewed 29 articles regarding rectal perforation with severe peritonitis following stapled hemorrhoidopexy from 2000 to 2011 and analyzed the management and outcomes [10]. Most surgeons performed open laparotomy and created diverting stoma in cases of rectal perforation following stapled hemorrhoidopexy [10]. However, our patient underwent totally laparoscopic lavage and primary closure without diverting stoma. We believe that factors favoring this approach include early surgery, young age, sufficient irrigation, and meticulous primary closure. Nishigori et al. reported that placement of a transanal tube is effective in decreasing the rate of anastomotic leakage after anterior resection using the double-stapling technique [11]. The 16-day postoperative hospitalization period in the present case is not longer than that reported for patients who underwent open laparotomy with diverting stoma. Postoperative ileus might be influenced by the severity of preoperative peritonitis. Because of the absence of stoma, no further invasive procedure was required.

In the laparoscopic era, colorectal surgeons may agree to attempt laparoscopic management of colorectal perforation following colonoscopy, diverticulitis, and anastomotic leakage [12–15]. The SCANDIV trial showed that laparoscopic lavage for perforated diverticulitis is no better than conventional operations; laparoscopic lavage did not reduce morbidity and had worse outcomes, such as high reoperation rate and missing carcinoma [12]. Another randomized controlled trial, however, reported that laparoscopic lavage may be an appropriate treatment option, though the condition in question was different [13]. Lee et al. reported that laparoscopic reintervention for anastomotic leakage was associated with shorter hospitalization and fewer complications [15]. The choice of treatment should be determined after considering the state of the patient. Our patient was a young healthy man who was hemodynamically stable at the time and had laparoscopic findings of minimal rectal inflammatory changes, unlike diverticulitis. Thus, our decision of attempting laparoscopic surgery was fully reasonable. Based on the outcome of our patient, we believe that a laparoscopic approach without stoma could be a feasible treatment option in select patients.

#### 4. Conclusion

Stapled hemorrhoidopexy is widely used for treatment of prolapsed hemorrhoids because of certain advantages. However, it can have severe adverse effects, such as rectal bleeding, pelvic sepsis, and rectal perforation, which are potentially life-threatening. Unexpected abdominal pain after stapled hemorrhoidopexy can be due to associated rectal perforation; therefore, immediate evaluation should be performed. Laparoscopic primary repair without stoma can be performed successfully in select patients with rectal perforation following stapled hemorrhoidopexy. A transanal rectal tube kept in place for several days may be a substitute for diverting stoma.

#### Guarantor

Byung-Noe Bae is the guarantor of this paper.

#### Registration of research studies

This study is registered with the ResearchRegistry and the unique identifying number is: researchregistry1583.

#### Consent

Written informed consent was obtained from the patient for publication of this case report.

#### Author contribution

Seokyong Ryu, M.D., Ph.D.: conception and design, acquisition of data, drafting of the manuscript.

Byung-Noe Bae, M.D., Ph.D.: conception and design, drafting of the manuscript, critical review of the manuscript for intellectual content, supervision.

#### Funding

This research did not receive any specific grant from funding agencies in the public, commercial, or not-for-profit sectors.

#### Ethical approval

Ethical approval was not required for this case report. Patient's data were deidentified.

#### Conflict of interest

None of the authors have any conflict of interest.

#### References

- [1] A. Arezzo, V. Podzemny, M. Pescatori, Surgical management of hemorrhoids State of the art, *Ann. Ital. Chir.* 82 (2011) 163–172.
- [2] J.J. Tjandra, M.K. Chan, Systematic review on the procedure for prolapse and hemorrhoids (stapled hemorrhoidopexy), *Dis. Colon Rectum* 50 (2007) 878–892.
- [3] W. Safadi, A. Altshuler, S. Kiv, et al., Severe retroperitoneal and intra-abdominal bleeding after stapling procedure for prolapsed haemorrhoids (PPH); diagnosis, treatment and 6-year follow-up of the case, *BMJ Case Rep.* (2014) 2014.
- [4] Q. Wang, J. Du, C. Cai, et al., Severe intra-abdominal bleeding leading to hemorrhagic shock, rectal perforation, and bilateral hydrothorax after stapling procedure for prolapsed hemorrhoids (PPH): is the transanal drainage feasible in this situation?: Report of a case and a successful experience, *Int. J. Colorectal Dis.* 29 (2014) 541–542.
- [5] A. Al-Haddad, Severe intra-abdominal bleeding plus large pneumoperitoneum following procedure of prolapsed hemorrhoids (PPH), *Int. J. Colorectal Dis.* 27 (2012) 1541–1542.
- [6] V. Ripetti, M. Caricato, A. Arullani, Rectal perforation, retroperitoneum, and pneumomediastinum after stapling procedure for prolapsed hemorrhoids: report of a case and subsequent considerations, *Dis. Colon Rectum* 45 (2002) 268–270.
- [7] W.C. Cirocco, Life threatening sepsis and mortality following stapled hemorrhoidopexy, *Surgery* 143 (2008) 824–829.
- [8] G. Aumann, S. Petersen, T. Pollack, et al., Severe intra-abdominal bleeding following stapled mucosectomy due to enterocele: report of a case, *Tech. Coloproctol.* 8 (2004) 41–43.
- [9] K. Blouhos, K. Vasiliadis, K. Tsalis, et al., Uncontrollable intra-abdominal bleeding necessitating low anterior resection of the rectum after stapled hemorrhoidopexy: report of a case, *Surg. Today* 37 (2007) 254–257.
- [10] J.L. Faucheron, D. Voirin, J. Abba, Rectal perforation with life-threatening peritonitis following stapled haemorrhoidopexy, *Br. J. Surg.* 99 (2012) 746–753.
- [11] H. Nishigori, M. Ito, Y. Nishizawa, et al., Effectiveness of a transanal tube for the prevention of anastomotic leakage after rectal cancer surgery, *World J. Surg.* 38 (2014) 1843–1851.
- [12] C. Coimbra, L. Bouffieux, L. Kohnen, et al., Laparoscopic repair of colonoscopic perforation: a new standard, *Surg. Endosc.* 25 (2011) 1514–1517.
- [13] J.K. Schultz, S. Yaqub, C. Wallon, et al., Laparoscopic lavage vs primary resection for acute perforated diverticulitis: the SCANDIV randomized clinical trial, *JAMA* 314 (2015) 1364–1375.
- [14] A. Thornell, E. Angenete, T. Bisgaard, et al., Laparoscopic lavage for perforated diverticulitis with purulent peritonitis: a randomized trial, *Ann. Intern. Med.* 164 (2016) 137–145.
- [15] C.M. Lee, J.W. Huh, S.H. Yun, et al., Laparoscopic versus open reintervention for anastomotic leakage following minimally invasive colorectal surgery, *Surg. Endosc.* 29 (2015) 931–936.

#### Open Access

This article is published Open Access at [scimedirect.com](http://scimedirect.com). It is distributed under the [IJSCR Supplemental terms and conditions](#), which permits unrestricted non commercial use, distribution, and reproduction in any medium, provided the original authors and source are credited.