

Bone marrow pathologic abnormalities in familial platelet disorder with propensity for myeloid malignancy and germline *RUNX1* mutation

Rashmi Kanagal-Shamanna,^{1†} Sanam Loghavi,¹ Courtney D. DiNardo,² L. Jeffrey Medeiros,¹ Guillermo Garcia-Manero,² Elias Jabbour,² Mark J. Routbort,¹ Rajyalakshmi Luthra,¹ Carlos E. Bueso-Ramos¹ and Joseph D. Khoury^{1†}

¹Department of Hematopathology and ²Department of Leukemia, The University of Texas M.D. Anderson Cancer Center, Houston, TX, USA



Haematologica 2017
Volume 102(10):1661-1670

ABSTRACT

A subset of patients with familial platelet disorder with propensity to myeloid malignancy and germline *RUNX1* mutation develops hematological malignancies, often myelodysplastic syndrome/acute myeloid leukemia, currently recognized in the 2016 WHO classification. Patients who develop hematologic malignancies are typically young, respond poorly to conventional therapy, and need allogeneic stem cell transplant from non-familial donors. Understanding the spectrum of bone marrow morphologic and genetic findings in these patients is critical to ensure diagnostic accuracy and develop criteria to recognize the onset of hematologic malignancies, particularly myelodysplastic syndrome. However, bone marrow features remain poorly characterized. To address this knowledge gap, we analyzed the clinicopathologic and genetic findings of 11 patients from 7 pedigrees. Of these, 6 patients did not develop hematologic malignancies over a 22-month follow-up period; 5 patients developed hematologic malignancies (3 acute myeloid leukemia; 2 myelodysplastic syndrome). All patients had thrombocytopenia at initial presentation. All 6 patients who did not develop hematologic malignancies showed baseline bone marrow abnormalities: low-for-age cellularity (n=4), dysmegakaryopoiesis (n=5), megakaryocytic hypoplasia/hyperplasia (n=5), and eosinophilia (n=4). Two patients had multiple immunophenotypic alterations in CD34-positive myeloblasts; 1 patient had clonal hematopoiesis. In contrast, patients who developed hematologic malignancies had additional cytopenia(s) (n=4), abnormal platelet granulation (n=5), bone marrow hypercellularity (n=4), dysplasia in ≥ 2 lineages including megakaryocytes (n=3) and acquired clonal genetic aberrations (n=5). In conclusion, our study demonstrated that specific bone marrow abnormalities and acquired genetic alterations may be harbingers of progression to hematological malignancies in patients with familial platelet disorder with germline *RUNX1* mutation.

Introduction

The widespread use of next-generation sequencing (NGS)-based assays has facilitated an increased recognition of familial clustering of myelodysplastic syndrome (MDS) and acute myeloid leukemia (AML).¹ Familial syndromes in which MDS/AML is a primary feature include familial platelet disorder with predisposition to myeloid malignancy (FPDMM) associated with germline *RUNX1* mutations, *GATA2*-associated syndromes, familial AML with *CEBPA* mutation, and syndromes associated with germline mutations in *SRP72*, *ANKRD26*, *DDX41*, or *ETV6*.^{2,3} Accordingly, the 2016

Correspondence:

rkanagal@mdanderson.org or
jkhoury@mdanderson.org

Received: March 17, 2017.

Accepted: June 20, 2017.

Pre-published: June 28, 2017.

doi:10.3324/haematol.2017.167726

Check the online version for the most updated information on this article, online supplements, and information on authorship & disclosures: www.haematologica.org/content/102/10/1661

©2017 Ferrata Storti Foundation

Material published in *Haematologica* is covered by copyright. All rights are reserved to the Ferrata Storti Foundation. Use of published material is allowed under the following terms and conditions:

<https://creativecommons.org/licenses/by-nc/4.0/legalcode>.

Copies of published material are allowed for personal or internal use. Sharing published material for non-commercial purposes is subject to the following conditions:

<https://creativecommons.org/licenses/by-nc/4.0/legalcode>,

sect. 3. Reproducing and sharing published material for commercial purposes is not allowed without permission in writing from the publisher.



revision to the WHO classification system for myeloid neoplasms has incorporated a section on “myeloid neoplasms with germline predisposition”.⁴

FPDMM (OMIM #601399) is an autosomal-dominant

disorder with variable penetrance genetically defined by the presence of germline *RUNX1* mutation. *RUNX1* encodes one of the α subunits of a core-binding transcription factor and plays a critical role in hematopoiesis,

Table 1A. Clinical, laboratory and peripheral blood findings on FPDMM patients.

Pedigree	Age/sex	Family history	Diagnosis	Follow up	WBC	Hgb	MCV	PC	MPV
A II-3	46/M	+	FPDMM ^{HM+} MDS-MLD	A&W, 29 months	6.3	12.9	99	119	12.3
A III-1	7/F	+	FPDMM ^{HM+} MDS-EB-1	A&W, 27 months. 23 months post stem cell transplant	3.9	9.7	103	63	10.1
B II-1	53/F	+	FPDMM ^{HM+} AML MRC	Died; 56.1 months from HM diagnosis	4.9	9.3	83	20	9.1
C II-1	48/F	+	FPDMM ^{HM+} AML MRC, SM	Died, 54 months from HM diagnosis	3.2	11	100	69	9.3
C II-3	42/M	+	FPDMM ^{HM+} AML MRC	Died, 8 months from HM diagnosis	4	13	103	33	NA
A III-2	4/F	+	FPDMM ^{HM-}	A&W, 25 months	6.8	12.5	86	122	8.7
C I-1	70/F	+	FPDMM ^{HM-}	A&W, 8 months	5.5	13.1	95	134	9.9
D I-1	57/M	+	FPDMM ^{HM-}	A&W, 39 months	6.5	14	89	92	9.5
E II-1	39/M	+	FPDMM ^{HM-}	Lost for follow up	3.2	14.1	93	77	9.6
F I-1	27/M	+	FPDMM ^{HM-}	A&W, 15 months	4.5	14.4	93	99	7.2
G I-1	14/F	-	FPDMM ^{HM-}	A&W, 22 months	5.9	13.1	88	88	NA

WBC: white blood cell count; Hgb: hemoglobin; MCV: mean corpuscular volume; PC: platelet count; MPV: mean platelet volume. Cytopenia(s) defined by laboratory reference range (matched for age). A&W; alive and well; AML MRC: acute myeloid leukemia with myelodysplasia-related changes; FPDMM^{HM+}: FPDMM with hematological malignancy; FPDMM^{HM-}: FPDMM without hematological malignancy; MDS-MLD: myelodysplastic syndrome with multilineage dysplasia; MDS-EB-1: myelodysplastic syndrome with excess blasts-1; HM: hematological malignancies; ND: not done; NA: not available; SM: systemic mastocytosis.

Table 1B. Bone marrow morphologic and flow cytometry immunophenotypic findings on the FPDMM patients.

Pedigree	# of BM specimens	Bone marrow									Flow cytometry						Hematogones	
		Age-matched cellularity	Megakaryocyte number	Megakaryocyte dysplasia	Granulocytic dysplasia	Erythroid dysplasia	Eosinophilia	Fibrosis	Lymphoid aggregates	Ring sideroblasts (%)	CD34+ blasts (%)	CD13	CD33	CD34	CD38	CD117		CD123
A II-3	7	↑	↑	+	-	+	+	-	-	2	1.00	↓	+	+	↓	+	↑	+
A III-1	8	↓	↓	+	+	+	+	-	-	2	2.76	+	+	↑	↓	↑	+	-
B II-1	11	↑	↓	too few	too few	too few	-	-	-	1	83.00	↑	+	↑	+	↑	↑	
C II-1	13	↑	↓	too few	too few	-	-	-	-	0	93.00	+	+	+	+	+	+	
C II-3	5	↑	↓	+	+	+	-	-	-	<1	91.00	+	+	+	+	+	+	
A III-2	4	↓	↓	+	-	-	+	-	-	0	0.80	+	+	+	+	+	↑	+
C I-1	2	↑	↑	+	+	-	+	-	+	0	0.08	+	+	+	↓	+	+	+
D I-1	5	Adequate	↑	+	-	-	+	-	-	0	0.60	+	+	+	↓	↑	↑	-
E II-1	1	↓	↓	+	-	-	-	-	+	0	0.50	+	+	+	↓	+	↑	-
F I-1	1	↓	too few*	too few*	-	-	+	-	-	ND	ND	ND	ND	ND	ND	ND	ND	ND
G I-1	1	↓	↑	+	-	-	-	-	-	0	0.70	+	+	+	+	+	+	+

*Suboptimal quality bone marrow (insufficient number of megakaryocytes available for evaluation). Dysplasia defined as dysmorphic forms >10% of the megakaryocytes. ND: not done; BM: bone marrow.

myeloid differentiation and platelet function.⁵ FPDMM is characterized by abnormalities in platelet number and/or function, namely defective release of δ granules, and a propensity to develop early-onset MDS/AML or, rarely, T-lymphoblastic leukemia/ lymphoma.⁶ Until now, about 50 pedigrees with germline *RUNX1* mutations have been reported.⁶⁻¹⁵

A subset (median, 35%; range: 22-60%) of FPDMM patients undergoes transformation to hematological malignancies (HM), usually MDS or AML (FPDMM^{HM+}), associat-

ed with the acquisition of additional somatic genetic lesions.^{3,14,16} FPDMM^{HM+} respond poorly to conventional therapy and require unique management strategies such as allogeneic stem cell transplant (in all pediatric patients and in eligible adult patients during remission), genetic counseling and work-up and identification of family members with germline *RUNX1* mutation.^{1,3,13,17-19} In this setting, allogeneic stem cell transplant is generally from unrelated donors who need to be carefully screened for germline mutations. Close surveillance and prompt recognition of FPDMM^{HM+} facili-

Table 2. FPDMM pedigrees with cytogenetic results and somatic mutation analysis using a combination of next-generation based sequencing and conventional techniques.

Pedigree	Diagnosis	Genetic testing for germline			Somatic mutations*		Cytogenetic studies
		<i>RUNX1</i> Mutation	Exon	Somatic mutations by NGS	VAF (%)	Karyotype	FISH
A II-3	FPDMM ^{HM+} MDS-MLD	c.582A>C p.K194N	6	None		46,XY,del(11) (q13q23)[8]/46,XY[14]	Deletion of 1 copy of 11q23 (<i>MLL</i>)
A III-1	FPDMM ^{HM+} MDS-EB-1	c.582A>C p.K194N	6	None		46,XX,del(5)(q31q34) [18]/46,XX[2]	Deletion (5q)
B II-1	FPDMM ^{HM+} AML MRC	c.719delC p.Pro240Hisfs c.167T>T p.Leu56Ser (probably benign)	7	NM_001754.4(<i>RUNX1</i>): c.334_339del p.L112_P113del NM_004985.3(<i>KRAS</i>): c.101C>G p.P34R NM_005896.2(<i>IDH1</i>): c.394C>T p.R132C	29.9 20 2.5	46,XX,t(2;22)(p23;q13.1), del(7)(q22q32)[20]	t(2;22)(p23;q13.1) (wcp22+;wpc22+) Deletion 7q
C II-1	FPDMM ^{HM+} AML MRC, SM	Partial gene deletion (at least exons 1-6)	1 through 6	NM_000222.2(<i>KIT</i>): c.2447A>T p.D816V NM_001754.4(<i>RUNX1</i>): c.485G>A p.R162K NM_024426.4(<i>WT1</i>): c.1142dupC p.A382fs	31.9 30.6 22.4	46,XX[20]	ND
C II-3	FPDMM ^{HM+} AML MRC	Partial gene deletion (at least exons 1-6)	1 through 6	None		46,XY,del(7)(q22)[20]	ND
A III-2	FPDMM ^{HM-}	c.582A>C p.K194N	6	None		46,XX[20]	No trisomy 8, deletions of 5/5q or 7/7q and 11q23 (<i>MLL</i>)
C I-1	FPDMM ^{HM-}	Partial gene deletion (at least exons 1-6)	1 through 6	NM_022552.4(<i>DNMT3A</i>): c.1015-2A>G (splice site)	14.1	46,XX[20]	ND
D I-1	FPDMM ^{HM-}	c.836G>A p.W279*	8	None		46,XY[20]	ND
E II-1	FPDMM ^{HM-}	c.496C>T p.R166*	5	ND		46,XY,inv(9)(p12q13)[20]	ND
F I-1	FPDMM ^{HM-}	c.308dup p.T104fs	4	ND		46,XY[20]	ND
G I-1	FPDMM ^{HM-}	c.1098_1103dupCGGCAT p.I366_G367dup	9	None		46,XX,inv(9)(p12q13)[20]	ND

*NGS-based somatic gene mutation analysis using 28-gene myeloid panel, *FLT3* ITD and *CEBPA*. NGS: next-generation sequencing; FPDMM: familial platelet disorder with predisposition to myeloid malignancy; FISH: fluorescence *in situ* hybridization; AML MRC: acute myeloid leukemia with myelodysplasia-related changes; FPDMM^{HM+}: FPDMM with hematological malignancy; FPDMM^{HM-}: FPDMM without hematological malignancy; MDS-MLD: myelodysplastic syndrome with multilineage dysplasia; MDS-EB-1: myelodysplastic syndrome with excess blasts-1; ND: not done; SM: systemic mastocytosis; VAF: variant allele frequency.

tates planning and timely therapeutic interventions before or at the time of leukemic transformation.

The diagnosis of MDS in FPDMM is particularly challenging. Few reports have described dysplastic changes in megakaryocytes due to the underlying germline *RUNX1* mutation in asymptomatic FPDMM patients.^{6,20,21} Additionally, the frequency of clonal hematopoiesis in asymptomatic FPDMM patients below 50 years of age is significantly higher (~67%) compared to that of the healthy general population.^{2,22} Currently, there are no criteria or guidelines available in the literature for diagnosis, evaluation and monitoring for HM in these patients.⁴ On the other hand, due to the aggressive therapeutic interventions implicated by the diagnosis of a HM, diagnostic accuracy and avoidance of overcalling MDS is of critical importance. Thus, there is a need to determine the pathologic features associated with FPDMM and progression to MDS. To begin addressing these gaps in knowledge, a thorough understanding of the bone marrow (BM) features in FPDMM patients and the characteristics associated with progression to HM is required. It is our understanding that no other study has addressed this issue in a systematic manner and this much needed knowledge base is currently lacking for pathologists and the rest of the clinical diagnostic team who are required to diagnose and evaluate patients with FPDMM associated with *RUNX1* mutation.

In the study herein, we performed a systematic evaluation of BM morphologic, cytogenetic and molecular findings in 11 patients from 7 distinct FPDMM pedigrees at various stages of disease evolution. We show that baseline BM morphologic and immunophenotypic abnormalities are present in asymptomatic FPDMM patients without MDS/AML. Awareness of these changes is important in order to exert caution in establishing a diagnosis of MDS, an actionable event in this context. We also compared the clinical, morphologic, cytogenetic, immunophenotypic and genetic findings between patients with FPDMM^{HM-} and FPDMM^{HM+} who had been followed with serial BM examinations over a median interval of 27 months. We identified specific pathologic features and we propose criteria that can facilitate the recognition of MDS in this setting for timely

therapeutic interventions. These findings also highlight the need for baseline and serial BM examination with multimodal ancillary testing to monitor for development of MDS/AML.

Methods

Study Group

We selected pedigrees of FPDMM with germline *RUNX1* mutations that were evaluated at our institution. In some cases, the proband (defined here as the first diagnosed family member) was evaluated at an outside hospital or clinic, whereas other members were referred to our institution following the proband's diagnosis. This study was approved by the Institutional Review Board and informed consent was obtained from all patients in accordance with the Declaration of Helsinki.

Histopathologic Evaluation

Hematoxylin-eosin stained BM core biopsy and/or clot specimens and Wright-Giemsa-stained peripheral blood (PB) and BM aspirate smears and/or touch imprints at baseline and various time points were assessed using standard criteria.^{23,24} Cytopenia(s) were defined based on institutional laboratory reference ranges. For enumeration of megakaryocytes, we considered 2-6 megakaryocytes per high-power field as a criterion for normal range. Prussian blue staining was used for quantifying ring sideroblasts. In selected cases, immunohistochemistry studies for CD34 and CD61 were performed using standard techniques on automated stainers (Leica Biosystems, Buffalo Grove, IL, USA) using antibodies against CD34 (MY10, 1:40; BD Biosciences, Franklin Lakes, NJ, USA) and CD61 (2F2, 1:100; Cell Marque, Rocklin, CA, USA). The morphologic findings were independently reviewed by 2 independent hematopathologists (RK-S and JDK).

Multiparameter Flow Cytometry Analysis

Flow cytometry (FC) immunophenotypic analysis was performed on BM aspirates as described previously.^{25,26} Aberrancies in expression levels of CD13, CD33, CD34, CD38, CD117, CD123 and additional markers were assessed on CD34+/CD10-/CD19-myeloid precursors and hematogones were quantified.

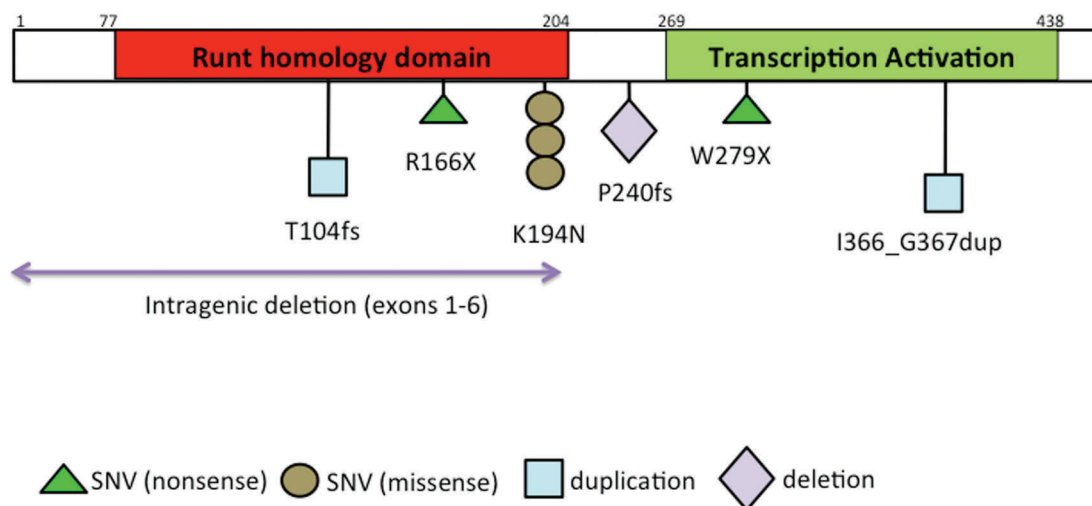


Figure 1. Representative image showing the location of the various types of exonic *RUNX1* mutations in this study group.

Abnormalities in myelomonocytic maturation were assessed as previously described.²⁶

Karyotyping and Fluorescence *in situ* Hybridization

Conventional G-band karyotype analysis and fluorescence *in situ* hybridization (FISH) on selected cases were performed using standard methods described previously.^{27,28} All results were reported according to the 2013 International System for Human Cytogenetic Nomenclature.²⁹

Gene Mutation Analysis

For germline *RUNX1* variant detection, we used genomic DNA extracted from disease-free whole blood/BM samples (in FPDMM^{H/M}) or cultured skin fibroblasts (in FPDMM^{H/M+}). For all pedigrees except C, *RUNX1* mutation was assessed by polymerase chain reaction (PCR) amplification followed by direct sequencing. NM_001754.3 was used as the reference sequence for the *RUNX1* gene for alignment. For pedigree C, amplicon-based exome sequencing that targeted the *ANKRD26*, *CEBPA*, *DDX41*, *ETV6*, *FLI1*, *GATA2*, *RUNX1*, *SRP72*, and *TP53* genes using the Illumina system was performed. The deletion was confirmed by exon-level oligo comparative genomic hybridization. Clinical interpretation was performed per published guidelines.³⁰

For assessment of somatic mutations, amplicon-based NGS-based analysis using a clinically-validated 28-gene myeloid panel

was performed on genomic DNA extracted from BM on a MiSeq sequencer (Illumina, San Diego, CA, USA) as described previously.^{31,32} *FLT3* internal tandem duplications and *CEBPA* mutations were assessed by well-established alternative methods.³¹

Results

Clinical characteristics

Our study cohort included 11 patients with FPDMM with germline *RUNX1* mutations from 7 unique pedigrees, labeled A through G. There were 6 females and 5 males with a median age of 42 years (range: 4-70) who were tested in various clinical settings and at different stages of clinical progression. The median age at time of diagnosis of MDS/AML in FPDMM^{H/M+} patients was 45 years (range: 7-53). The patients were either asymptomatic or had a long-standing propensity for bleeding that was often misdiagnosed as immune thrombocytopenic purpura. Upon evaluation, all patients had mild to moderate thrombocytopenia. The median platelet count was $88 \times 10^9/L$ (range: 20-134). The clinical characteristics are presented in Table 1. Six of 7 pedigrees had a family history of thrombocytopenia or leukemia; 1 patient had “sporadic” thrombocytopenia, however, details regarding the family history on the pater-

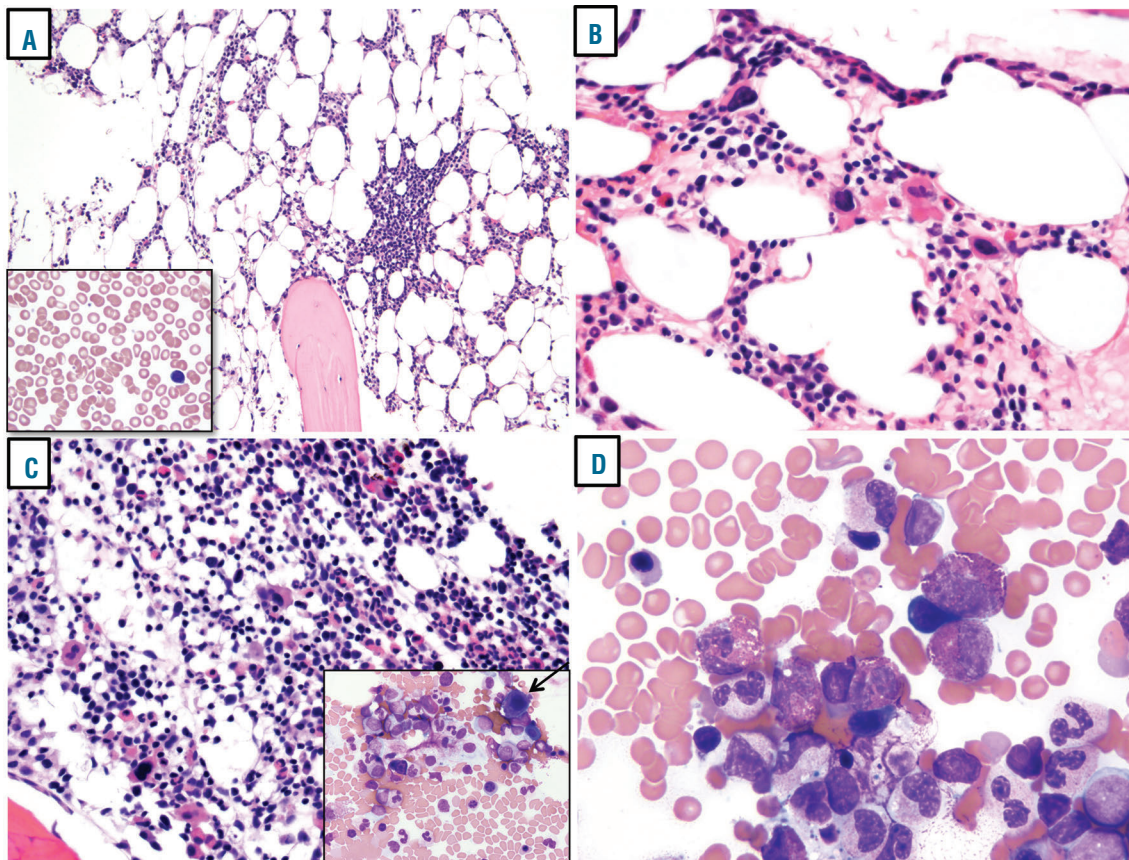


Figure 2. Representative images from the BM biopsy/ aspirate smears of the asymptomatic FPDMM patients from various pedigrees. (A) Pedigree E (II-1): hypocellular for age BM with decreased megakaryocytes that included >10% forms that were small in size with nuclear hypolobation and single lymphoid aggregate; inset, PB smear showing thrombocytopenia with normal sized platelets. (B) Pedigree G (I-1): slightly hypocellular for age BM with increased megakaryocytes, including small hypolobated forms; (C) 4-year old sister (III-2) showing a hypocellular for age marrow with frequent dysmorphic megakaryocytes; inset, aspirate smear arrow showing a small abnormal megakaryocyte. (D) Aspirate smear shows eosinophilia.

Table 3. Proposed criteria for diagnosing myelodysplastic syndrome in individuals with familial platelet disorder with propensity for myeloid malignancy and germline *RUNX1* mutations.**Major criteria**

1. Identification of germline *RUNX1* mutation
2. Cytopenia in ≥ 1 hematopoietic lineage, other than thrombocytopenia
3. Exclusion of non-neoplastic causes of cytopenias
4. Bone marrow and peripheral blood blasts $< 20\%$

Minor criteria

- A. Morphologic features of myelodysplasia in ≥ 2 hematopoietic lineages
- B. Acquired clonal cytogenetic or molecular genetic abnormality

All major criteria and one of the minor criteria are required to make a diagnosis of myelodysplastic syndrome.

nal side were not available for this latter patient. The reasons for germline *RUNX1* mutation testing included: evaluation for early-onset MDS, an extensive family history of MDS/AML, FPDMM diagnosis in a relative, and confirmation of a suspected germline mutation identified by NGS-based multi-gene somatic mutation profiling for thrombocytopenia in a patient with no known family history of bleeding or leukemia. The pedigree, diagnosis and genetic alterations, to various extents, in 4 of the 7 pedigrees have been reported previously.¹³ The detailed pedigrees for each of the families are provided in the *Online Supplementary Figures S1 and S2*.

Characteristics of germline *RUNX1* mutations

The types of germline *RUNX1* alterations observed in this study cohort included substitutions (1 missense, 2 nonsense), duplications (n=2) and deletions (n=2). The deletion in pedigree C was large and spanned exons 1 through 6. Four of the 7 *RUNX1* germline alterations involved the Runt1 homology domain (RHD); 3 involved the transactivation domain (TAD). Two cases that transformed to AML had additional somatic *RUNX1* mutations, both of which involved the Runt domain. The location and type of germline alterations identified in each of the pedigrees are depicted in Figure 1. Five of the detected *RUNX1* mutations have not been reported previously.

PB, BM histologic, immunophenotypic, cytogenetic and molecular findings

Within our study group, 6 of 11 patients with FPDMM had no evidence of MDS/AML (FPDMM^{HM-}), and 5 patients developed AML or MDS (FPDMM^{HM+}) over the follow-up time period. The 5 FPDMM^{HM+} patients included FPDMM with AML (n=3), and FPDMM with MDS (n=2). All 11 patients underwent BM examination; 7 patients (including 3 of 6 FPDMM^{HM-} patients) had BM evaluations performed at multiple time points.

PB findings

All 6 FPDMM^{HM-} patients had stable thrombocytopenia (median, $96 \times 10^3 / \mu\text{L}$, range: 77-134); 1 patient also had mild leukopenia (no decreased absolute neutrophil count) and no patients had anemia. Mean corpuscular volume (MCV) was within normal range in all patients. Absolute eosinophilia was noted in 3 out of 6 patients. PB smears showed normal sized platelets in all but 1 patient who had normal sized platelets with few large forms that were adequately granulated. In contrast, the median platelet count of

FPDMM^{HM+} patients was lower at 63 (range: 20-119). Contrary to FPDMM^{HM-}, all patients with FPDMM^{HM+} had 1 or more cytopenia(s) in addition to thrombocytopenia (anemia in 4 and leukopenia in 2 patients). In 1 patient, the platelet count decreased further at the time of development of MDS. Macrocytosis was present in 4 out of 5 patients. Absolute eosinophilia was noted in 1 out of 5 patients. PB smears showed platelets with anisocytosis and abnormalities in granulation (hypogranulation and agranulation). Two out of 4 patients showed dysplastic neutrophils that included cytoplasmic hypogranulation and abnormal nuclear segmentation.

BM histologic findings

BM from all 6 FPDMM^{HM-} patients showed baseline morphologic abnormalities. Age-matched BM cellularity was decreased in 4 patients, increased in 1 patient and adequate in 1 patient. Morphologic abnormalities were most apparent in the megakaryocytic lineage. The number of megakaryocytes was increased in 3 patients, decreased in 2 patients and could not be assessed in 1 patient. Megakaryocytes were dysmorphic, often small with scant cytoplasm and nuclear hypolobation, with asynchronous nuclear cytoplasmic maturation; the dysmorphic forms accounted for more than 10% of the megakaryocytes in 5 patients, barring 1 case in which megakaryocytic dysplasia could not be evaluated due to the poor quality of the specimen. In 1 case megakaryocytic dysplasia was associated with granulocytic dysplasia; however, a diagnosis of MDS was not established because the patient did not have unexplained cytopenia(s) other than mild and stable thrombocytopenia. None of the other patients showed dysplasia in the granulocytic or erythroid lineages. BM eosinophilia was present in 4 out of 6 patients. None of the patients had fibrosis. BM findings in representative FPDMM cases within pedigrees are presented in Figures 2 and 3.

BM samples from 4 out of 5 FPDMM^{HM+} patients showed increased BM cellularity for age compared to FPDMM^{HM-} patients (80% versus 17%, $P=0.08$, Fisher's exact test). The megakaryocytes were adequate in number in 1 patient, and decreased in 4 patients. Three patients had sufficient precursor cells for adequate morphologic evaluation. All patients had dysmegakaryopoiesis with dysplasia in an additional lineage (dyserythropoiesis and/or dysgranulopoiesis). Two FPDMM/AML patients had too few cells to assess for dysplasia due to the presence of many blasts. BM eosinophilia was present in 2 out of 5 patients. None of the 5 patients had BM fibrosis. The diagnoses on FPDMM^{HM+}

patients included: MDS with excess blasts (EB)-1 (n=1), MDS with multilineage dysplasia (n=1), and AML with myelodysplasia-related changes (MRC; n=3). AML-MRC was attributable to a history of MDS in 1 patient, morphologic dysplasia in >50% of precursors in at least 2 lineages in a second patient and del(7q) abnormality in a third patient; this patient also developed systemic mastocytosis during remission.

Immunophenotypic findings

The immunophenotype of CD34-positive myeloid blasts was analyzed by FC immunophenotyping in 5 FPDMM^{HM+} patients. CD34-positive myeloblasts showed immunophenotypic abnormalities similar to those observed in MDS or a stem cell neoplasm. These included CD13 increased (1/5), CD38 decreased (3/5), CD117 increased (1/5), and CD123 increased (3/5). Hematogones were absent in 2 cases. In 2 out of 5 FPDMM^{HM+} patients, multiple FC aberrations which are typical of MDS or a stem cell neoplasm were noted.

The immunophenotypic findings in the FPDMM^{HM+} patients showed aberrancies consistent with the diagnosis. The PB and BM findings are summarized in Table 1.

Somatic clonal cytogenetic and molecular aberrations

Karyotype data were available for all patients and NGS mutation data were available for 9 out of 11 patients. None of the 6 FPDMM^{HM+} patients had karyotypic abnormalities. Two out of 6 patients showed inv(9) chromosomal polymorphism. One out of 4 FPDMM^{HM+} patients who underwent NGS testing showed a somatic *DNMT3A* splice site mutation (allele frequency 14.1%). In the absence of cytopenia or hematologic malignancy, this finding was consistent with clonal hematopoiesis of indeterminate potential [pedigree C 1-1].

In contrast, all 5 FPDMM^{HM+} patients had acquired clonal cytogenetic abnormalities and/or somatic gene mutation(s) in addition to germline *RUNX1* mutation (4 with karyotype abnormality; 2 with somatic mutations and both of these cases also had a second *RUNX1* mutation). These results are summarized in Table 2.

Clinical course and outcome

Follow-up data were available for 10 out of 11 patients (Table 1). The median follow-up duration was 27.4 months (range: 8-56.1). The median follow up for FPDMM^{HM+} patients was 22.3 months. Five FPDMM^{HM+} patients with available follow-up data are alive without development of hematological malignancy. All 3 FPDMM^{HM+} patients with AML (B II-1, C II-1 and C II-3) died. The FPDMM^{HM+} patient with MDS-EB-1 (A III-1) underwent allogeneic stem cell transplant and is alive and well. The FPDMM^{HM+} patient (A II-3) who developed MDS with multilineage dysplasia is awaiting therapy with hypomethylating agents.

Using serial BM examinations and comparing certain specific parameters to the baseline BM, 1 patient progressed to overt MDS over a 29-month follow-up period. This asymptomatic patient (A II-3) was evaluated solely due to the diagnosis of FPDMM^{HM+} in the offspring. The platelet count was minimally decreased and perhaps present life-long, and attributable to germline *RUNX1* mutation. Mild anemia (Hgb, 12.9 g/dL) was noted at presentation, but the significance and duration were not clear. The initial baseline BM showed ~10% dysmorphic megakaryocytes without granulocytic or erythroid dysplasia. FC immunophenotypic findings showed aberrant CD34 positive myeloblasts with

decreased CD13 and CD38 expression and increased CD123 expression (Table 1). Conventional cytogenetic studies showed a low-level del(11)(q13q23) in 2 out of 30 metaphases, confirmed to involve *KMT2A/MLL* deletion by FISH in 9.5% of interphase nuclei. At this time, although del(11q) is an MDS-defining abnormality, due to the low-level of the del(11q) clone, in the absence of dysplasia in other lineage(s) other than megakaryocytes, and unclear etiology of anemia, a diagnosis of MDS was not made but a concern was raised. Therefore, the patient was monitored closely with BM exams every 6 months. Over a 23-month follow-up interval, the patient remained anemic and thrombocytopenic, and del(11q) persisted at a low level (1-2 of 20 metaphases). At the 29-month follow up, BM showed additional dysplasia involving the erythroid lineage that coincided with expansion of the del(11q) clone to 8 out of 20 metaphases. At this time, the patient was diagnosed with MDS. At last follow up, he was scheduled to start treatment with hypomethylating agents.

Discussion

We describe the spectrum of BM pathologic findings in 11 patients belonging to 7 unique FPDMM pedigrees identified in various clinical settings and at different stages of clinical progression. The findings in this study highlight the importance of initial and serial BM evaluation in FPDMM patients and underscore the need to establish specific criteria for the diagnosis of MDS in patients with a germline predisposition to MDS/AML.

Although few studies have described megakaryocytic abnormalities in BM aspirate smears,^{6,20,21} systematic analysis of BM morphologic, immunophenotypic, and genetic findings in FPDMM are rare. The only other study by Tsang *et al.* reported serial BM specimens of patients with various etiologies of congenital thrombocytopenia, including a case of FPDMM. The authors describe 3 morphologic patterns at initial presentation: (1) cases with myelodysplastic/ myeloproliferative features such as hypercellularity, myeloid predominance and numerous micromegakaryocytes, (2) cases with hypocellular marrow and small megakaryocytes, as noted in the case with FPDMM, paralleling the observations in our series, and (3) cases with normal morphology. Similar to the findings in our study group, disease progression in their series was also associated with the development of additional dysplasia in the erythroid and myeloid lineages as well as cytogenetic abnormalities.³³

In the study herein we show that FPDMM is characterized by baseline morphologic abnormalities that include low-for-age BM cellularity and dysplastic megakaryopoiesis in the absence of MDS/AML. A subset of these FPDMM^{HM+} patients also showed immunophenotypic aberrancies in CD34-positive myeloid blasts diagnostic of a stem cell neoplasm. However, these patients lacked unexplained cytopenia(s) other than thrombocytopenia, and have been followed up over a median of 22.3 months without development of MDS/AML. Awareness of these baseline BM abnormalities in FPDMM patients is important for diagnosticians not to overcall MDS in FPDMM patients. This is not simply an academic issue; the diagnosis of MDS in FPDMM patients has considerable treatment implications. MDS and AML arising in the context of FPDMM respond poorly to conventional therapy; therefore, aggressive interventions including allogeneic stem cell transplant from non-familial

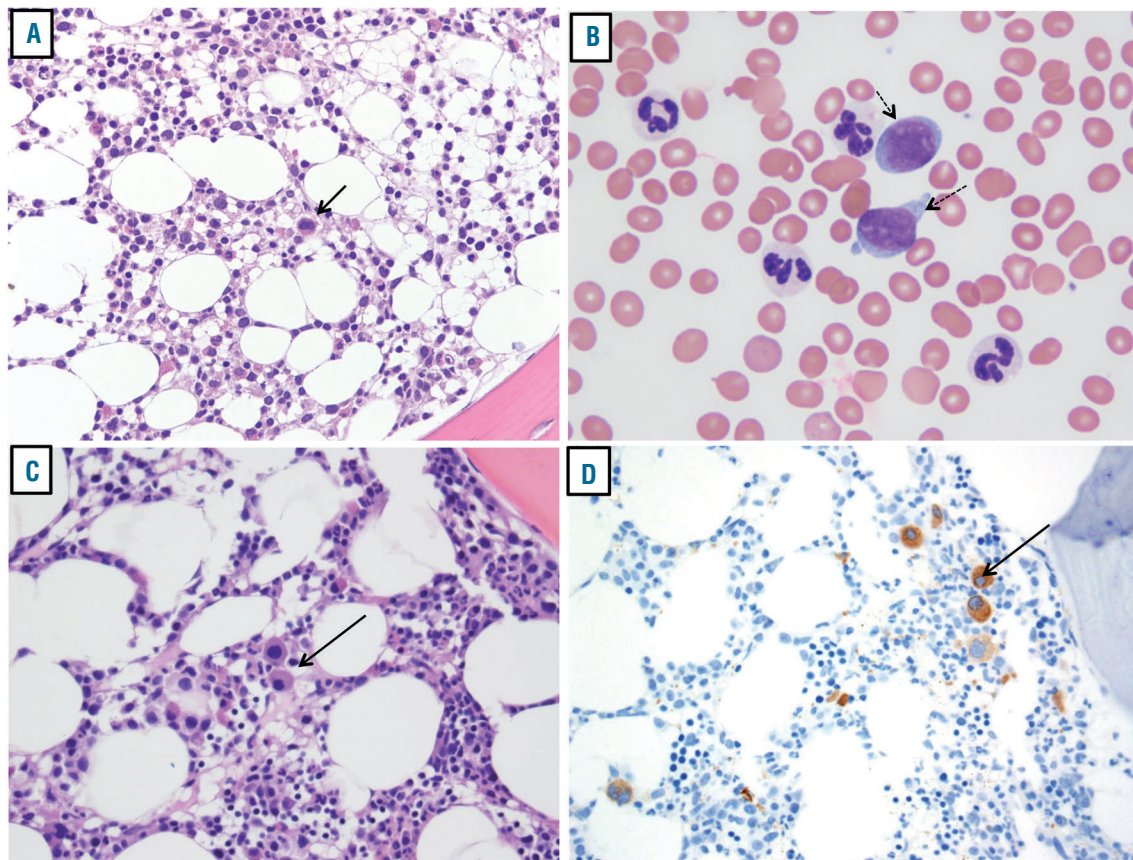


Figure 3. Representative images of the BM biopsy/ aspirate smears of FPDMM patients with MDS. (A) 7-year old girl diagnosed with MDS (proband, III-1); BM biopsy is hypocellular for age; (B) BM aspirate smears show increased blasts (dashed arrows) and severe neutrophilic hypogranulation; (C) father's (II-3) BM with frequent megakaryocytes that are small and hypolobated; (D) CD61 immunohistochemistry highlights dysmorphic megakaryocytes.

donors is required.

FPDMM patients showed an unusually high proportion of dysmorphic megakaryocytes which were small in size with scant basophilic cytoplasm and hypolobated nuclei. These abnormalities corroborate the results of published *in vitro* studies showing the critical role of *RUNX1* in terminal differentiation of megakaryocytes¹⁷ and the impact of *RUNX1* mutations on megakaryopoiesis.³⁴⁻³⁶ Bluteau *et al.* demonstrated, *in vitro*, morphologic abnormalities in megakaryocytes derived from CD34⁺ hematopoietic progenitors of FPDMM patients. These abnormalities were related to a block in maturation, manifested as small megakaryocytes with a high nucleus/cytoplasm ratio, and decreased ploidy or nuclear lobation.³⁴ Dysmegakaryopoiesis in the BM of FPDMM patients similar to those observed in our study have been described in a few reports.^{6,20,21,33} Bluteau *et al.* also demonstrated a 60-80% decrease in the total number of megakaryocytes derived from CD34⁺ hematopoietic progenitors of FPDMM patients. In contrast, a substantial percentage of patients showed increased numbers of megakaryocytes in the present case series. The variant findings may represent the phenotypic diversity of the various *RUNX1* mutations.³⁴

Another interesting finding was PB and BM eosinophilia that were noted in 4 out of 6 FPDMM^{HM+} patients in the study herein. Eosinophilia is characteristic of AML with *RUNX1* translocations, such as AML with *RUNX1-RUNX1T1* or AML with *RUNX1-CBFA2T3*.^{4,37} However, it

is unclear if eosinophilia in FPDMM is directly related to the *RUNX1* mutation or secondary to another etiology. One FPDMM patient (C II-1) who progressed to AML subsequently developed systemic mastocytosis with *KIT* D816V mutation during remission, suggesting an alternative explanation for eosinophilia in this patient. There was no increase in mast cells in the other family members in this pedigree who underwent evaluation (C II-3 and C I-1).

The findings in the study herein illustrate the unique challenges associated with the diagnosis of MDS in patients with FPDMM and the need for developing specific criteria for establishing the diagnosis of MDS in these patients. However, at this time, there are no guidelines available for this purpose. By comparing the clinicopathologic features of FPDMM^{HM+} and FPDMM^{HM+} patients in this study, we found certain consistent findings in all FPDMM patients with MDS/AML. These findings included: (1) presence of anemia and/or leukopenia in addition to thrombocytopenia, (2) multilineage dysplasia, and (3) presence of an additional clonal (somatic) event, either a cytogenetic or a molecular aberration. Based on these findings, we propose the following criteria as a helpful guide for the diagnosis of MDS in FPDMM patients (Table 3). However, the series is small, and the proposed criteria need validation in additional studies. The criteria should be used with appropriate clinico-pathologic correlation. The decision to treat MDS is very challenging as it must be tailored to the individual and as such requires input from both oncologists and pathologists.

Other studies have shown that leukemic transformation in FPDMM is always associated with an additional clonal (somatic) event.^{1,16,38-40} Acquired cytogenetic aberrations include del(5q), +8, del(7q), del(11q23), trisomy 12, and t(2;11)(q31;p15), and reported somatic gene mutations include a second *RUNX1* mutation,^{3,5,41} and mutations in *ASXL1*, *IDH1*, *TET2*, *CEBPA* and *CDC25C*.^{3,39,41-43} *CDC25C* mutations have not been confirmed by other studies.⁴⁰ However, acquisition of clonal somatic aberrations is not pathognomonic of leukemic transformation due to the high frequency of clonal hematopoiesis reported in FPDMM. Nevertheless, detection of a new clonal aberration warrants close follow up with comprehensive assessment of PB, BM morphology and cytogenetic and molecular markers and correlation of clinical findings. In the study herein, patient C I-1 had asymptomatic mild thrombocytopenia due to a germline *RUNX1* mutation. BM examination showed bilineage dysplasia and a diploid karyotype, and a *DNMT3A* splice site mutation was detected at 14.1% allelic frequency. In the absence of cytopenia and hematological malignancy, *DNMT3A* mutation may represent a coincidental clonal hematopoiesis of indeterminate potential. Repeat BM evaluation after 6 months showed persistent dysplasia with stable thrombocytopenia and no evidence of MDS; however, the follow up on this patient is short (~8 months).

The findings of recurrent BM morphologic, immunophenotypic and genetic abnormalities underscore the importance of initial baseline and serial BM evaluation in FPDMM patients. Identification of specific BM abnormalities in FPDMM^{HM-} patients can provide measurable parameters to assess progressive changes during serial follow up for monitoring for potential development of MDS/AML, illustrated by patient II-3 in pedigree A (see Results section).

Identification of the described BM findings can also facilitate the initial recognition of FPDMM. Although most FPDMM patients are identified after the diagnosis of MDS/AML in 1 or more family members, Latger-Cannard *et al.* have described dysmegakaryopoiesis in a subset of FPDMM^{HM-} patients and suggested that detection of small dysmorphic megakaryocytes in the right clinical context is a clue for early diagnosis of FPDMM.⁶²⁰ We believe that dysmegakaryopoiesis in a hypocellular BM with or without an abnormal immunophenotype of CD34-positive blasts should trigger evaluation for germline predisposition syndromes, especially in patients with long-standing thrombocytopenia and normal-sized platelets. This is particularly important in patients without a known family history. Since the disease has a variable age of presentation and broad spectrum of clinical manifestations, a high level of suspicion provides opportunities for early detection and appropriate genetic counseling for other family members. We also recommend NGS mutation analysis for the work-up of thrombocytopenia, illustrated by patient G I-1 who had no family history. In this patient, NGS-based somatic mutation analysis revealed a *RUNX1* variant suggestive of germline origin. Identification of a *RUNX1* variant with a near-heterozygous or homozygous allelic frequency, more than 1 *RUNX1* variant or biallelic variants, detection of a deleterious *RUNX1* variant, or a variant that has been previously reported in FPDMM should prompt evaluation for germline *RUNX1* mutation in the appropriate clinicopathologic setting.^{19,41} *RUNX1* and other genes such as *ETV6*, *ANKRD26*, *DDX41*, *CEBPA*, and *GATA2* should be incorpo-

rated in routine NGS panels to facilitate incidental detection of mutations in these genes.^{39,44} Specifically, germline mutations in *ETV6* and *ANKRD26* genes can also cause thrombocytopenia. Moreover, multi-gene mutation profiling in FPDMM patients can identify secondary somatic events. However, not all laboratories may have access to NGS. In this case, Sanger sequencing should be used for mutation analysis of these genes. *RUNX1* mutations encompass the whole coding region; hence conventional PCR techniques are not appropriate. However, gene mutation analysis on its own is not sufficient to exclude germline predisposition. Large deletions spanning numerous exons are frequent in FPDMM, and are often missed by clinical NGS-based somatic mutation analysis alone. This was apparent in pedigree C (Online Supplementary Figure S3). Exon-level oligo-array comparative gene hybridization/ single nucleotide polymorphism arrays or assessment of coverage using exome sequencing is essential.³⁹ In certain cases, identification of a novel variant of uncertain significance may require *in vitro* functional studies for implicating a diagnosis of FPDMM due to linkage disequilibrium. Pre- and post-test genetic counseling of individuals and family members should be available.

At this time, it is not possible to predict an individual FPDMM patient's risk of developing MDS/AML.^{3,14,16} FPDMM patients with BM morphologic and FC immunophenotypic abnormalities may have a higher risk of progression and need closer follow up. Large prospective studies are warranted to explore this issue further. Close follow up with a complete blood count (CBC) every 6 months and/or NGS-based mutation studies, if possible, is helpful for monitoring these patients, as there are no alternative criteria or biomarkers to predict the disease course at this time. We recommend an initial BM examination with comprehensive ancillary studies in all FPDMM patients to assess baseline pathologic changes and exclude occult malignancy. Ancillary testing should encompass FC, cytogenetic, and molecular analysis capable of detecting deletions, duplications and rearrangements. Following initial BM examination, patients must be closely monitored for progression to HM by regular BM examination if CBC or NGS studies show abnormalities. We also recommend NGS-based mutation profiling (which includes the *RUNX1* gene) for evaluation of patients with long-standing thrombocytopenia without a clear underlying etiology.

In summary, in the study herein we systematically evaluated the BM morphologic, immunophenotypic and genetic findings in a large single institution series of FPDMM patients. Comparison of clinicopathologic and genetic features between FPDMM^{HM+} and FPDMM^{HM-} patients with a median follow-up duration of over 2 years provided a set of criteria useful for establishing a diagnosis of MDS in these patients; the impact of making a diagnosis of MDS in FPDMM patients is underscored by the significant therapeutic implications including allogeneic stem cell transplantation. The role of precise diagnostic and monitoring criteria using a multimodal approach in the evaluation of patients with FPDMM cannot be overemphasized.

Funding

This work was partly supported by institutional startup funds awarded to R K-S, MD Anderson Cancer Center Leukemia SPORE CA 100632 and Charif Souki Cancer Research Fund.

References

- Nickels EM, Soodalter J, Churpek JE, Godley LA. Recognizing familial myeloid leukemia in adults. *Ther Adv Hematol*. 2013;4(4):254-269.
- Churpek JE, Fyrtel K, Kanchi KL, et al. Genomic analysis of germ line and somatic variants in familial myelodysplasia/acute myeloid leukemia. *Blood*. 2015;126(22):2484-2490.
- Babushok DV, Bessler M. Genetic predisposition syndromes: when should they be considered in the work-up of MDS? *Best Pract Res Clin Haematol*. 2015;28(1):55-68.
- Arber DA, Orazi A, Hasserjian R, et al. The 2016 revision to the World Health Organization classification of myeloid neoplasms and acute leukemia. *Blood*. 2016;127(20):2391-2405.
- Schmit JM, Turner DJ, Hromas RA, et al. Two novel RUNX1 mutations in a patient with congenital thrombocytopenia that evolved into a high grade myelodysplastic syndrome. *Leuk Res Rep*. 2015;4(1):24-27.
- Latger-Cannard V, Philippe C, Bouquet A, et al. Haematological spectrum and genotype-phenotype correlations in nine unrelated families with RUNX1 mutations from the French network on inherited platelet disorders. *Orphanet J Rare Dis*. 2016;11:49.
- Toya T, Yoshimi A, Morioka T, et al. Development of hairy cell leukemia in familial platelet disorder with predisposition to acute myeloid leukemia. *Platelets*. 2014;25(4):300-302.
- Sorrell A, Espenschied C, Wang W, et al. Hereditary leukemia due to rare RUNX1c splice variant (L472X) presents with eczematous phenotype. *Int J Clin Med*. 2012;3(7).
- Okada Y, Watanabe M, Nakai T, et al. RUNX1, but not its familial platelet disorder mutants, synergistically activates PF4 gene expression in combination with ETS family proteins. *J Thromb Haemost*. 2013;11(9):1742-1750.
- Liew E, Owen C. Familial myelodysplastic syndromes: a review of the literature. *Haematologica*. 2011;96(10):1536-1542.
- Kiraly PA, Kallay K, Marosvari D, et al. [Clinical and genetic background of familial myelodysplasia and acute myeloid leukemia]. *Orv Hetil*. 2016;157(8):283-289.
- Iizuka H, Kagoya Y, Kataoka K, et al. Targeted gene correction of RUNX1 in induced pluripotent stem cells derived from familial platelet disorder with propensity to myeloid malignancy restores normal megakaryopoiesis. *Exp Hematol*. 2015;43(10):849-857.
- DiNardo CD, Bannan SA, Routbort M, et al. Evaluation of patients and families with concern for predispositions to hematologic malignancies within the Hereditary Hematologic Malignancy Clinic (HHMC). *Clin Lymphoma Myeloma Leuk*. 2016;16(7):417-428 e412.
- Connelly JP, Kwon EM, Gao Y, et al. Targeted correction of RUNX1 mutation in FPD patient-specific induced pluripotent stem cells rescues megakaryopoietic defects. *Blood*. 2014;124(12):1926-1930.
- Luddy RE, Champion LA, Schwartz AD. A fatal myeloproliferative syndrome in a family with thrombocytopenia and platelet dysfunction. *Cancer*. 1978;41(5):1959-1963.
- Owen C, Barnett M, Fitzgibbon J. Familial myelodysplasia and acute myeloid leukaemia: a review. *Br J Haematol*. 2008;140(2):123-132.
- Owen CJ, Toze CL, Koochin A, et al. Five new pedigrees with inherited RUNX1 mutations causing familial platelet disorder with propensity to myeloid malignancy. *Blood*. 2008;112(12):4639-4645.
- Buijs A, Poddighe P, van Wijk R, et al. A novel CBFA2 single-nucleotide mutation in familial platelet disorder with propensity to develop myeloid malignancies. *Blood*. 2001;98(9):2856-2858.
- Churpek JE, Godley LA. How I diagnose and manage individuals at risk for inherited myeloid malignancies. *Blood*. 2016 Jul 28. [Epub ahead of print]
- Latger-Cannard V, Philippe C, Jonveaux P, Lecompte T, Favier R. Dysmegakaryopoiesis, a clue for an early diagnosis of familial platelet disorder with propensity to acute myeloid leukemia in case of unexplained inherited thrombocytopenia associated with normal-sized platelets. *J Pediatr Hematol Oncol*. 2011;33(7):e264-266.
- Walker LC, Stevens J, Campbell H, et al. A novel inherited mutation of the transcription factor RUNX1 causes thrombocytopenia and may predispose to acute myeloid leukaemia. *Br J Haematol*. 2002;117(4):878-881.
- Steensma DP, Bejar R, Jaiswal S, et al. Clonal hematopoiesis of indeterminate potential and its distinction from myelodysplastic syndromes. *Blood*. 2015;126(1):9-16.
- Thiele J, Kvasnicka HM, Facchetti F, et al. European consensus on grading bone marrow fibrosis and assessment of cellularity. *Haematologica*. 2005;90(8):1128-1132.
- Della Porta MG, Travaglino E, Boveri E, et al. Minimal morphological criteria for defining bone marrow dysplasia: a basis for clinical implementation of WHO classification of myelodysplastic syndromes. *Leukemia*. 2015;29(1):66-75.
- Ok CY, Leventaki V, Wang SA, et al. Detection of an abnormal myeloid clone by flow cytometry in familial platelet disorder with propensity to myeloid malignancy. *Am J Clin Pathol*. 2016;145(2):271-276.
- Tang G, Jorgensen LJ, Zhou Y, et al. Multicolor CD34(+) progenitor-focused flow cytometric assay in evaluation of myelodysplastic syndromes in patients with post cancer therapy cytopenia. *Leuk Res*. 2012;36(8):974-981.
- Khoury JD, Sen F, Abruzzo LV, et al. Cytogenetic findings in blastoid mantle cell lymphoma. *Hum Pathol*. 2003;34(10):1022-1029.
- Konoplev S, Medeiros LJ, Lennon PA, et al. Therapy may unmask hypoplastic myelodysplastic syndrome that mimics aplastic anemia. *Cancer*. 2007;110(7):1520-1526.
- Simons A, Shaffer LG, Hastings RJ. Cytogenetic nomenclature: changes in the ISCN 2013 compared to the 2009 edition. *Cytogenet Genome Res*. 2013;141(1):1-6.
- Richards CS, Bale S, Bellissimo DB, et al. ACMG recommendations for standards for interpretation and reporting of sequence variations: Revisions 2007. *Genet Med*. 2008;10(4):294-300.
- Kanagal-Shamanna R, Luthra R, Yin CC, et al. Myeloid neoplasms with isolated isochromosome 17q demonstrate a high frequency of mutations in SETBP1, SRSF2, ASXL1 and NRAS. *Oncotarget*. 2016;7(12):14251-14258.
- Luthra R, Patel KP, Reddy NG, et al. Next-generation sequencing-based multigene mutational screening for acute myeloid leukemia using MiSeq: applicability for diagnostics and disease monitoring. *Haematologica*. 2014;99(3):465-473.
- Tsang HC, Bussell JB, Mathew S, et al. Bone marrow morphology and disease progression in congenital thrombocytopenia: a detailed clinicopathologic and genetic study of eight cases. *Mod Pathol*. 2017;30(4):486-498.
- Bluteau D, Glembofsky AC, Raimbault A, et al. Dysmegakaryopoiesis of FPD/AML pedigrees with constitutional RUNX1 mutations is linked to myosin II deregulated expression. *Blood*. 2012;120(13):2708-2718.
- Song WJ, Sullivan MG, Legare RD, et al. Haploinsufficiency of CBFA2 causes familial thrombocytopenia with propensity to develop acute myelogenous leukaemia. *Nat Genet*. 1999;23(2):166-175.
- Ichikawa M, Asai T, Saito T, et al. AML-1 is required for megakaryocytic maturation and lymphocytic differentiation, but not for maintenance of hematopoietic stem cells in adult hematopoiesis. *Nat Med*. 2004;10(3):299-304.
- Park JJ, Park JE, Kim HJ, et al. Acute myeloid leukemia with t(16;21)(q24;q22) and eosinophilia: case report and review of the literature. *Cancer genetics and cytogenetics*. 2010;196(1):105-108.
- Ripperger T, Steinemann D, Gohring G, et al. A novel pedigree with heterozygous germline RUNX1 mutation causing familial MDS-related AML: can these families serve as a multistep model for leukemic transformation? *Leukemia*. 2009;23(7):1364-1366.
- Haslam K, Langabeer SE, Hayat A, Conneally E, Vandenberghe E. Targeted next-generation sequencing of familial platelet disorder with predisposition to acute myeloid leukaemia. *Br J Haematol*. 2016;175(1):161-163.
- Yoshimi A, Toya T, Nannya Y, et al. Spectrum of clinical and genetic features of patients with inherited platelet disorder with suspected predisposition to hematological malignancies: a nationwide survey in Japan. *Ann Oncol*. 2016;27(5):887-895.
- Antony-Debre I, Duployez N, Bucci M, et al. Somatic mutations associated with leukemic progression of familial platelet disorder with predisposition to acute myeloid leukemia. *Leukemia*. 2016;30(4):999-1002.
- Preudhomme C, Renneville A, Bourdon V, et al. High frequency of RUNX1 biallelic alteration in acute myeloid leukemia secondary to familial platelet disorder. *Blood*. 2009;113(22):5583-5587.
- Sakurai M, Kasahara H, Yoshida K, et al. Genetic basis of myeloid transformation in familial platelet disorder/acute myeloid leukemia patients with haploinsufficient RUNX1 allele. *Blood Cancer J*. 2016;6:e392.
- Kanagal-Shamanna R, Singh RR, Routbort MJ, et al. Principles of analytical validation of next-generation sequencing based mutational analysis for hematologic neoplasms in a CLIA-certified laboratory. *Expert Rev Mol Diagn*. 2016;16(4):461-472.