

Electrophysiological evidence of localized reentry as a trigger and driver of atrial fibrillation at the junction of the superior vena cava and right atrium



Atsuhiko Yagishita, MD,* Yasuteru Yamauchi, MD,* Takamichi Miyamoto, MD,*
Kenzo Hirao, MD[†]

From the *Department of Cardiology, Musashino Red Cross Hospital, Tokyo, Japan, and [†]Heart Rhythm Center, Tokyo Medical and Dental University, Tokyo, Japan.

Introduction

Localized reentry is one of the major sources maintaining organized atrial fibrillation (AF)¹ and atrial tachycardia (AT).^{2,3} The electrical activity circulating around a small area is usually represented by a temporal gradient of the

activation between the distal and proximal bipoles of the ablation catheter.¹ We present a case of a patient in whom the electrophysiological findings proved a temporal gradient of the activation at the junction of the superior vena cava (SVC) and right atrium (RA) as a localized reentry.

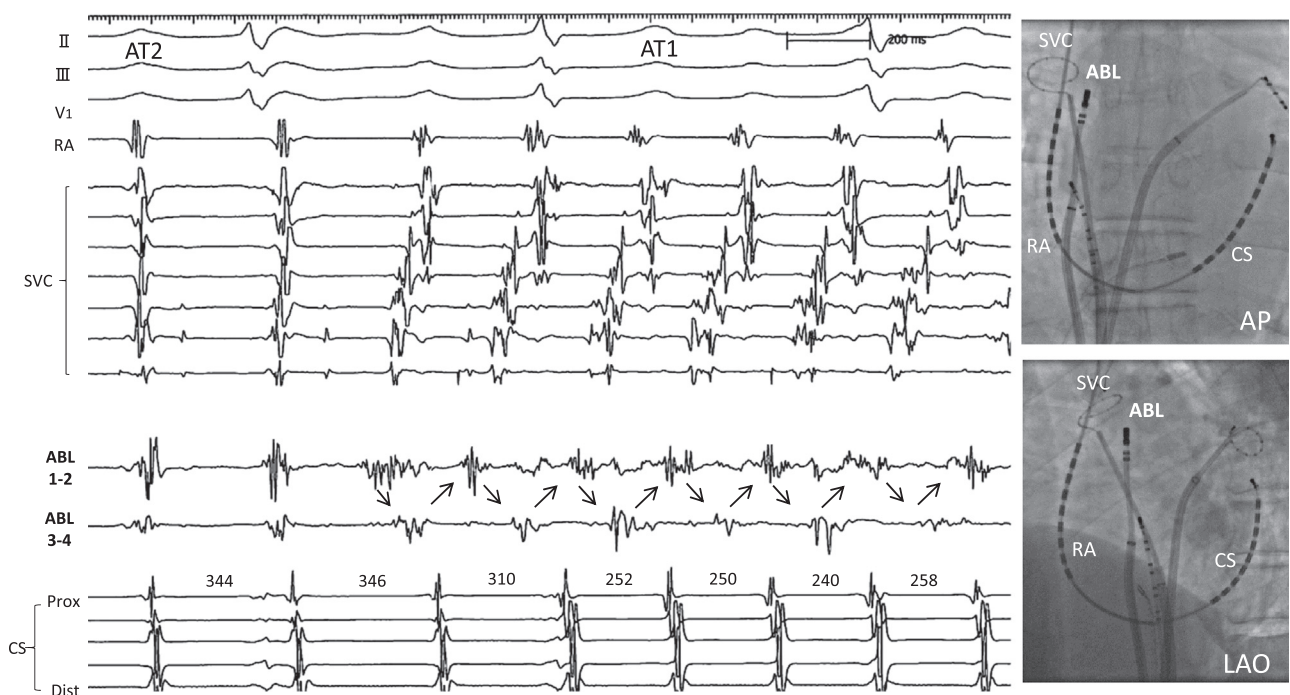


Figure 1 Intracardiac tracing during the alternation between the 2 atrial tachycardias (ATs). Note the conversion from AT2 to AT1 with the initiation of a temporal gradient of the activation between the distal and proximal bipoles of the ablation catheter (ABL) at the junction of the superior vena cava (SVC) and right atrium (RA). AP = anteroposterior; CS = coronary sinus; LAO = left anterior oblique.

KEYWORDS Atrial fibrillation; Atrial tachycardia; Pulmonary vein isolation; Catheter ablation; Superior vena cava; Localized reentry
(Heart Rhythm Case Reports 2017;3:164–166)

Address reprint requests and correspondence: Dr Atsuhiko Yagishita, Department of Cardiology, Musashino Red Cross Hospital, Tokyo, Kyonancho 1-26-1, Musashinoshi, Tokyo, Japan. E-mail address: atsuhikoyagishita@nifty.com.

KEY TEACHING POINTS

- Localized reentry, one of the major sources maintaining organized atrial fibrillation and atrial tachycardia, is usually represented by a temporal gradient of the activation between the distal and proximal bipoles of the ablation catheter.
- Focal activation conducting unidirectionally from the distal to proximal bipole may mimic temporal gradient of the activation.
- This was the first description that the electrophysiological findings during termination of a temporal gradient of the activation differentiated localized reentry from focal activation at the junction of the superior vena cava and right atrium.

Case report

A 68-year-old male patient with lone paroxysmal AF was referred to our institution for a recurrent AT 8 months after a catheter ablation. At the index procedure, a pulmonary vein (PV) isolation was solely performed with no additional ablation lesion sets including SVC isolation. During the repeat procedure, 2 ATs with alternating cycle lengths on the electrocardiogram were mutually noted (AT1: 220–250 ms, AT2: 320–350 ms). Fibrillatory activity was recorded on the circular catheter located in the SVC, and an intermittent

temporal gradient of the activation between the distal and proximal bipoles was recorded by the ablation catheter placed at the junction of the SVC and RA (Figure 1). AT1 transiently converted into AT2 with the termination of the temporal gradient and resumed with the initiation of the temporal gradient of the activation, suggesting that AT1 was an organized AF driven by localized reentry at the junction of the SVC and RA (Figure 2). During the radiofrequency (RF) application at the SVC-RA junction, AT1 converted into AT2 with persistent fibrillatory activity in the SVC. AT2 continued after the spontaneous termination of the fibrillatory activity in the SVC, which suggested the coexistence of AT2 and fibrillatory activity inside the isolated SVC. AT2 was a gap-related macroreentrant tachycardia associated with a prior right PV isolation, entering the right PV through a gap in the anterior part of the right PV with another gap on the roof of the right superior PV as an exit to the left atrium (LA). RF application in the anterior part of the right PV created conduction block from the LA to the right superior PV and terminated AT2. After an additional RF application for another gap on the roof of the right PV, no further AF or AT was initiated, and the patient has been free from AF and AT following the procedure.

Discussion

Localized reentry is one of the important sources as a driver of AF,¹ and it is associated with termination of AF by an RF application.⁴ Considering that it is predominantly found in

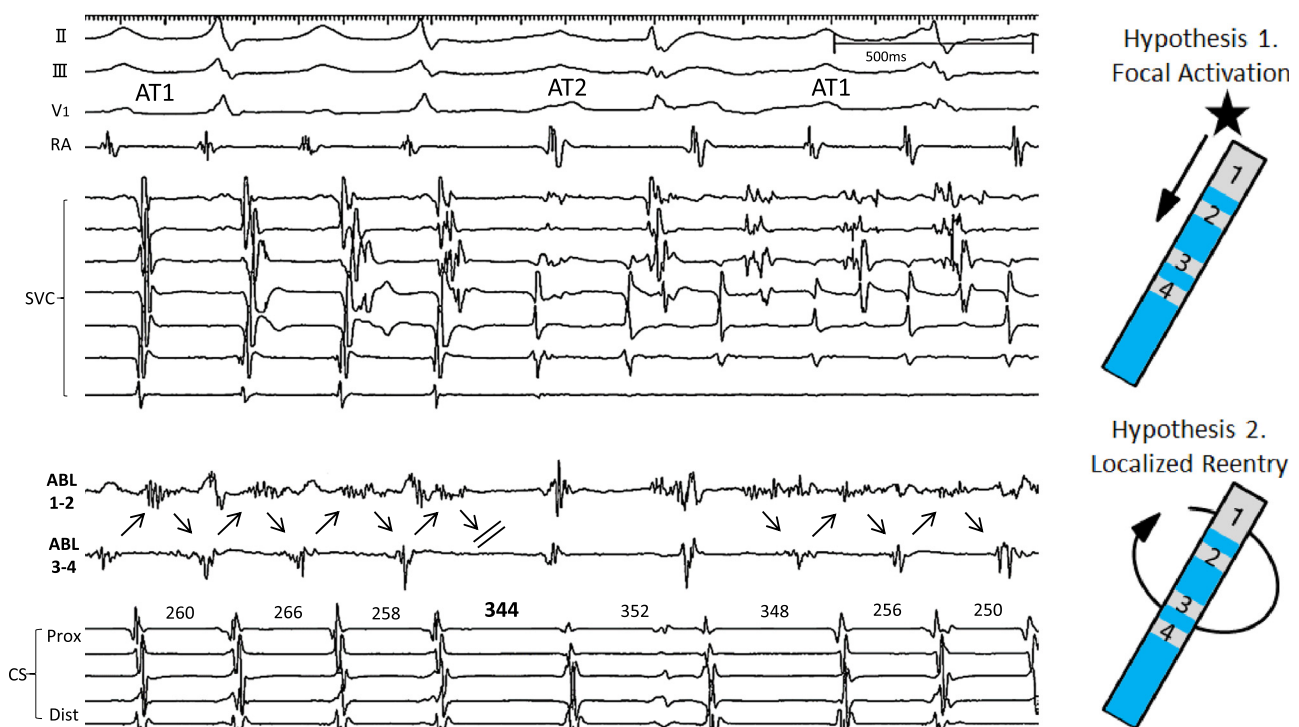


Figure 2 Atrial tachycardia (AT)1 converted into AT2 with the termination of the temporal gradient of the activation, and resumed after the initiation of the temporal gradient of the activation, while fibrillatory activity was seen in the superior vena cava (SVC). That suggested that AT1 was an organized atrial fibrillation driven by the localized reentry at the superior vena cava (SVC) – right atrium (RA) junction. Note the termination of the temporal gradient of the activation with conduction block from the distal (Dist) to proximal (Prox) bipole, suggesting a focal activation was unlikely (hypothesis 1). Abl = ablation catheter; CS = coronary sinus.

the LA, our case is unique in that the temporal gradient of the activation was recorded at the junction of the SVC and RA.¹ For deciphering the mechanism of the temporal gradient of the activation, 2 hypotheses were assumed (Figure 2): hypothesis 1, focal activation conducting unidirectionally from the distal to proximal bipole; and hypothesis 2, localized reentry circulating as a small reentry around the distal and proximal bipoles. During the termination of the activation, fragmented potentials were recorded on the distal bipole. It is unlikely that an abrupt conduction block from the distal and proximal bipole (hypothesis 1) would occur without a change in the frequency of the activation gradient. In contrast, termination of the rotational activation could be recorded on the distal bipole (hypothesis 2). Interestingly, for AT2 a gap-related macroreentrant tachycardia may have contributed as a trigger of the localized reentry, complementarily playing a role as a persistent driver for AT2, which culminated in an uninterrupted double tachycardia. Furthermore, the multiple activation patterns and persistent fibrillary

activity in the SVC following the termination of AT1 driven by the localized reentry at the SVC-RA junction suggested the presence of other drivers in the SVC, which became silent after the isolation of the SVC.

Acknowledgments

We thank John Martin for his help in the preparation of this article.

References

1. Haissaguerre M, Hocini M, Sanders P, et al. Localized sources maintaining atrial fibrillation organized by prior ablation. *Circulation* 2006;113:616–625.
2. Sanders P, Hocini M, Jais P, et al. Characterization of focal atrial tachycardia using high-density mapping. *J Am Coll Cardiol* 2005;46:2088–2099.
3. Maeda S, Yamauchi Y, Tao S, Okada H, Obayashi T, Hirao K. Small reentrant atrial tachycardia adjacent to left aortic sinus of valsalva. *Circ J* 2013;77:3054–3055.
4. Takahashi Y, O'Neill MD, Hocini M, et al. Characterization of electrograms associated with termination of chronic atrial fibrillation by catheter ablation. *J Am Coll Cardiol* 2008;51:1003–1010.