

Case report

Bouveret's syndrome complicated by distal gallstone ileus after laser lithotripsy using Holmium: YAG laser

Mohammad M Alsolaiman *, Christoph Reitz , Ali T Nawras ,
John B Rodgers and Benedict J Maliakkal

Address: Division of Gastroenterology, Department of Medicine, Albany Medical College and VA Stratton Hospital, Albany, New York, USA

E-mail: Mohammad M Alsolaiman* - modar9@hotmail.com; Christoph Reitz - luckyluko@mindspring.com;
Ali T Nawras - nawrasa@mail.amc.edu; John B Rodgers - RodgerJ@mail.amc.edu; Benedict J Maliakkal - MaliakB@mail.amc.edu

*Corresponding author

Published: 18 June 2002

Received: 18 April 2002

BMC Gastroenterology 2002, **2**:15

Accepted: 18 June 2002

This article is available from: <http://www.biomedcentral.com/1471-230X/2/15>

© 2002 Alsolaiman et al; licensee BioMed Central Ltd. Verbatim copying and redistribution of this article are permitted in any medium for any purpose, provided this notice is preserved along with the article's original URL.

Abstract

Background: Bouveret's syndrome is an unusual presentation of duodenal obstruction caused by the passage of a large gallstone through a cholecystoduodenal fistula. Endoscopic therapy has been used as first-line treatment, especially in patients with high surgical risk.

Case presentation: We report a 67-year-old woman who underwent an endoscopic attempt to fragment and retrieve a duodenal stone using a Holmium: Yttrium-Aluminum-Garnet Laser (Ho:YAG) which resulted in small bowel obstruction. The patient successfully underwent enterolithotomy without cholecystectomy or closure of the fistula.

Conclusion: We conclude that, distal gallstone obstruction, due to migration of partially fragmented stones, can occur as a possible complication of laser lithotripsy treatment of Bouveret's syndrome and might require urgent enterolithotomy.

Background

Gastric outlet obstruction caused by a gallstone in the duodenum or pylorus (Bouveret's syndrome) is a very rare complication of gallstone disease. This type of gallstone ileus can be diagnosed and treated endoscopically. Endoscopic stone removal is especially indicated in poor risk patients. A dislodged impacted stone can migrate distally and cause small bowel mechanical obstruction that might require urgent enterolithotomy.

Case report

A 67-year-old Caucasian female presented with 4 days of vomiting associated with coffee ground materials, loss of appetite, and new onset of occasional heartburn. She denied any abdominal pain. The physical exam was perti-

nent for severe obesity with Body-Mass-Index of 52 and frequent desaturations on room air from 90 to 84%. The patient was lethargic, with clear lungs and a 2/6 systolic murmur over the base. Her abdomen was non-distended and non-tender with normal bowel sounds. Significant bilateral lower extremity edema was noticed. Her liver tests were all within normal limits. Initial chest and abdominal radiographs were normal. An esophagogastroduodenoscopy was performed using a GIF-1T 140 (Olympus, Melville, NY), which has 10.9 mm diameter and single channel 3.7 mm. In the duodenum just beyond the bulb, very large gallstone was obstructing the lumen measuring about 4 cm × 2 cm (Figure 1). The adjacent duodenal walls appeared ulcerated and friable. Computed tomography of the abdomen showed pneumobilia, distended

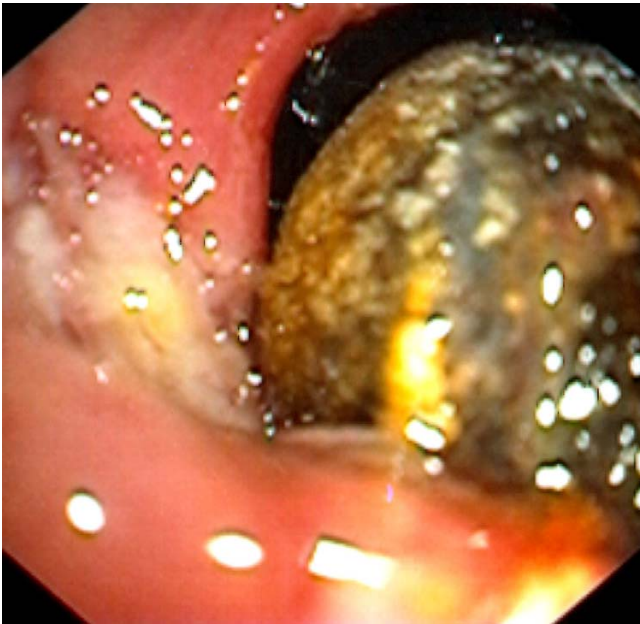

Figure 1
Large obstructing gallstone just beyond the duodenal bulb with ulcerated duodenal wall.

stomach and a 4 cm mass with calcified rim in the duodenum. The gallbladder was adjacent to the mass and contained an air fluid level (Figure 2). Because of the patient's high surgical risk, secondary to obstructive sleep apnea with pulmonary hypertension, severe aortic stenosis and morbid obesity, treatment with endoscopic laser lithotripsy followed by endoscopic removal of the fragments was planned.

A holmium: yttrium-aluminum-garnet laser (Ho:YAG) was used via a flexible fiber through the biopsy channel of the GIF-2T 160 endoscope which has 12.6 mm diameter and dual channel (2.8 mm, 3.7 mm). Olympus dedicated flushing pump was used for fluid irrigation and cleaning the debris using sterile water. Initially a 0.55 mm, then a 1 mm fiber was used. The laser pulse energy and rate settings were 0.5 J and 5 HZ respectively. Higher settings were avoided because of the severe ulceration of the duodenal wall and the fear of perforation. The shell of the gallstone was easily penetrated by the laser, but large cracks were not produced. Two sets of endoscopic therapy with laser application resulted in partial fragmentation of the gallstone, but it still could not be retrieved from the duodenum (Figure 3). Each session continued for about one hour. Considering the general status of the patient and the presence of multiple comorbidities, further attempts to break down and retrieve the stone were postponed for further sessions. After the second session the patient had several episodes of abdominal pain and vom-

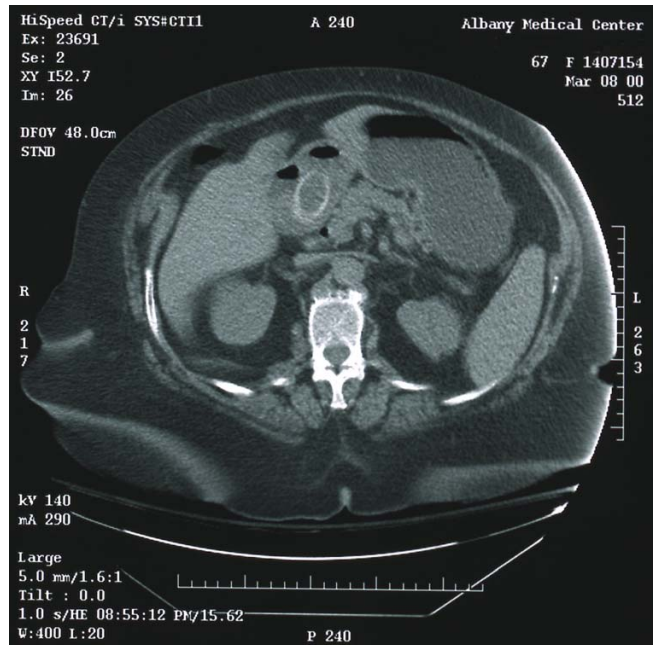


Figure 2
4 cm mass within the duodenum (gallstone) and adjacent gallbladder with air fluid level.

iting. A third session of laser lithotripsy was planned but the EGD revealed that the gallstone was no longer in the duodenum. No fistula was noticed.

A repeat computed tomography showed the gallstone in the distal ileum (Figure 4). The patient underwent surgery with an enterotomy, which revealed a 4.5×3.5×2.5 cm gallstone in the terminal ileum. The patient recovered well without repair of the cholecystoduodenal fistula and had no biliary problems at two years follow up.

Discussion

Bouveret's syndrome is a rare complication of cholelithiasis with gastric outlet obstruction caused by a gallstone migrating through a cholecystoduodenal fistula [1,2]. Alternatives to surgical lithotomy are attractive, as this syndrome affects mostly elderly patients and involves operating in an ulcerated duodenum. Furthermore, if the stone is removed by endoscopy, a repair of the cholecystoduodenal fistula is in most cases not necessary [1].

Simple endoscopic lithotomy might not be possible, as the impacted gallstones tend to be very large [2]. In these cases mechanical fragmentation of the stone at the site of impaction has been attempted. If unsuccessful, alternative methods of lithotripsy by laser or extracorporeal shock-wave lithotripsy (ESWL) have been tried [3,4]. In the here-reported case, ESWL was thought to be difficult because of massive obesity. Percutaneous laser lithotripsy has been

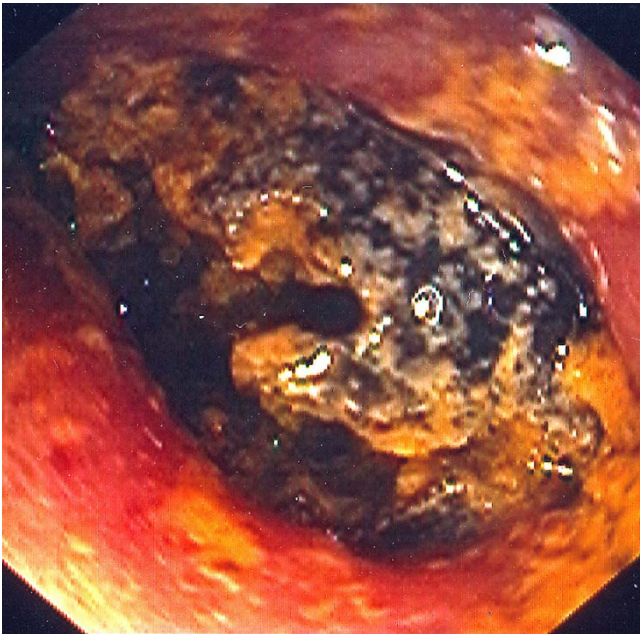


Figure 3
Gallstone in the duodenum with holes and partial fragmentation after two sessions of laser lithotripsy.

used for choledocholithiasis, and three reports of treatment of Bouveret's syndrome have been published [5–7]. Two of the reported cases resulted in successful endoscopic treatment without need for surgery; the third reported patient went to surgery because of the inability to fragment the stone [7]. We did chose the infrared Holmium: YAG laser because of its previous use in choledocholithiasis [8,9] and the deployment via a flexible optical fiber. This allowed us to work with the laser through the working channel of the endoscope. The direct visual control of the laser application makes the treatment technically easy and safe.

The two previously reported successful laser lithotripsies required more than one session of treatment to achieve success. Maiss et al [5] used first a rhodamine-6 G dye laser system in eight sessions, resulting only in partial fragmentation; completed fragmentation was achieved by a ninth session with a frequency-doubled double-pulse Nd:Yag laser. Langhorst et al [6] reported the need for two sessions with a rhodamine-6 G dye laser to achieve sufficient fragmentation to enable endoscopic lithotomy. We too found that the destruction of the stone to be a slow process not sufficiently completed after two esophagogastroduodenoscopies and more than two hours of total endoscopy time needed. Technical reasons for this seem to be: the rather small laser fibers of 1 mm diameter; the resulting debris requiring frequent lavage and the stone which had a very hard outer shell with a soft core. The

shell was easily penetrated by the laser. The damage to the stone was limited to the direct treatment site and no cracks around the circumference of the shell were observed. As only the visible proximal aspect of the stone was approachable with the laser, a stable distal sphere in the duodenum remained. Further treatment sessions would have been necessary to reach the distal part of the stone.

Nevertheless, the treatment in our case caused a dislocation of the stone between treatments and resulted a distal gallstone ileus. A similar problem was observed in other reported cases when Bouveret's syndrome which was treated with endoscopic lithotomy or extracorporeal shock wave lithotripsy [3,4,10]. Despite the failure to endoscopically removal the stone from the duodenum, it was felt in the here-presented case, that the resulting ileal enterostomy carried much less risk tolerated than an initial gastroduodeostom especially considering the patients general poor condition.

As laser lithotripsy has been used successfully and safely in Bouveret's syndrome, it seems to be a reasonable alternative to immediate surgery in patients with poor surgical risk. One needs to be prepared for prolonged and repeated treatment sessions. Different laser systems might offer faster results, but systematic study of this is complicated by the rarity of Bouveret's syndrome.

The following observations might improve the efficiency and the success rate of endoscopic laser lithotripsy in Bouveret's syndrome: First, using monitored anesthesia care (MAC) instead of endoscopist controlled conscious sedation for our high-risk patient enabled us to extend the endoscopy and laser application time, second, increasing the power of maintaining the same power with usage of smaller fiber might increase the ablation efficacy as the concern about perforation is moot, sinse photoacoustic effects from the holmium: YAG laser are minimal, as opposed to the lasers with short pulse durations. The most efficient settings for holmium: YAG lithotripsy appear to be 1 J at 10 Hz for stone compositions [11]. In most urologic applications, the proper use of holmium: YAG power settings and optical fibers should yield stone-free results in more then 85% of cases in one setting, including stones as large as 6 cm [12], third, using a longer endoscope than the standard length endoscope, which proved to be too short for efficient use because of the gastric distention present in our patient, and finally, using the therapeutic two-channel endoscope enabled efficient lavage and suction of the stone debris generated during laser use.

Conclusions

We think Endoscopic treatment of Bouveret's syndrome offers advantages over gastroduodeostomy, especially in

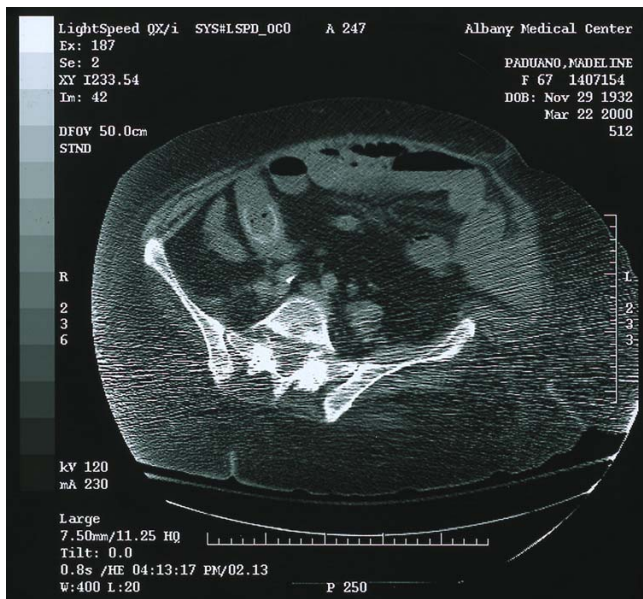


Figure 4
Gallstone in the distal ileum with air in the center and partial destruction of the stone shell.

high-risk patients. After failure of endoscopic lithotomy of the complete stone and failure of mechanical lithotripsy, laserlithotripsy is a reasonable option, as it was shown to be completely or partially successful in 3 of 4-reported cases. No procedure-related complications or overall adverse outcomes were reported in these 4 cases. But there is a considerable risk in these cases to convert a proximal gallstone ileus into a distal gallstone ileus as the result of partial fragmentation and manipulation of the stone. We conclude that, Laserlithotripsy with the Holmium: YAG laser through the endoscope, which is used in our patient, is technically easy and safe.

Competing interests

None declared.

Authors' contributions

All the authors contributed significantly to the manuscript. All of the authors took care of the patient during the hospital stay and there after. All of them contributed to the manuscript by writing part of it and revising it. All the authors read and approved the final manuscript.

Acknowledgments

Written consent was not able to be obtained from the patient or his/her relatives. Many attempts to locate the patient or his/her relatives (using the phone, the mail system, and internet) were not successful. No photographs that can identify the patient were included in the manuscript.

This paper was supported in part by the Albert M. Yunich, M.D scholarship fund.

These materials presented in part as a poster in the American College of Gastroenterology meeting NY, 2000.

References

- Rodriguez-Sanjuan JC, Casado F, Fernandez MJ, Morales DJ, Naranjo A: **Cholecystectomy and fistula closure versus enterolithotomy alone in gallstone ileus.** *Br J Surg* 1997, **84**:634-637
- Van Dam J, Steiger E, Sivak MV: **Giant Duodenal gallstone presenting as gastric outlet obstruction Bouveret's syndrome.** *J Clin Gastroenterol* 1992, **15**:150-153
- Ondreika P: **Bouveret's syndrome treated by a combination of extracorporeal shock wave lithotripsy (ESWL) and surgical intervention,** *Endoscopy* 1999, **31**:834
- Dumonceau JM: **Endoscopic treatment of gastric outlet obstruction caused by a gallstone (Bouveret's syndrome) after extacorporeal shockwave lithotripsy.** *Endoscopy* 1997, **29**:319-321
- Maiss J: **Successful treatment of Bouveret's syndrome by endoscopic laserlithotripsy.** *Endoscopy* 1999, **31**:S4-5
- Langhorst J, Schumacher B, Deselaers T, Neuhaus H: **Successful endoscopic therapy of a gastric outlet obstruction due to gallstone with intracorporeal laser lithotripsy: a case of Bouveret's syndrome.** *Gastrointest. Endosc* 2000, **5**:209-213
- Kasano Y, Tanimura H, Yamaue H, Uchiyama K, Hayashido M, Hama T: **Duodenal obstruction by gallstone: case report of Bouveret's syndrome.** *Nippon Geka Hokan* 1997, **66**:111-115
- Teichman JM, Schwesinger WH, Lackner J, Cossman Holmium RM: **YAG laser lithotripsy for gallstones.** *Surg Endosc* 2001, **15**:1034-1037
- Weickert U, Muhlen E, Janssen J, Johanns W, Greiner L: **The holmium-YAG laser: a suitable instrument for stone fragmentation in choledocholithiasis. The assessment of the results of its use under babyscopic control.** *Dtsch Med Wochenschr* 1999, **30**:514-518
- luchtman M, Sternberg A, Alffici R, Sternberg E, Fireman T: **Iatrogenic gallstone ileus as a new complication of Bouveret's syndrome.** *Harefuah* 1999, **136**:122-124
- Spore SS, Teichman JM, Corbin NS, Champion PC, Williamson EA, Glickman RD: **Holmium: YAG lithotripsy: optimal power setting.** *J Endourol* 1999, **13**:559-566
- Teichman JM, Rogenes VJ, McIyer BJ, Harris JM: **Holmium: YAG cystolithotripsy of large bladder calculi.** 1997, **50**:44-8

Pre-publication history

The pre-publication history for this paper can be accessed here:

<http://www.biomedcentral.com/1471-230X/2/15/pre-pub>

Publish with **BioMed Central** and every scientist can read your work free of charge

"BioMedCentral will be the most significant development for disseminating the results of biomedical research in our lifetime."

Paul Nurse, Director-General, Imperial Cancer Research Fund

Publish with **BMC** and your research papers will be:

- available free of charge to the entire biomedical community
- peer reviewed and published immediately upon acceptance
- cited in PubMed and archived on PubMed Central
- yours - you keep the copyright

Submit your manuscript here:

<http://www.biomedcentral.com/manuscript/>

 **BioMedCentral.com**

editorial@biomedcentral.com