

Case Report

An ocular lesion of unknown aetiology

A 61-year-old Caucasian female patient presented to her general practitioner complaining of progressive diminished visual acuity, narrowed visual field and blurred vision in her right eye. She had a history of hepatic steatosis, arterial hypertension and bronchial asthma in childhood. She reported no alcohol abuse and was a former smoker (1 pack-year history of smoking, with more than 30 years smoke-free).

Because of her vision problems, she was referred to an ophthalmologist. On examination, she was already blind in the right eye (3 months after symptom onset). The ophthalmologist performed

a comprehensive ophthalmic exam, including a funduscopy (figure 1a) and ultrasound of the eye (figure 1b). Fundoscopy and ultrasonography of the right eye showed pathological findings in the choroid.

Cite as: Drosslerova M, Cernovska M, Vasakova M, *et al.* An ocular lesion of unknown aetiology. *Breathe* 2021; 17: 200164.

Task 1

What is/are your differential diagnoses?

- a) Choroidal melanoma
- b) Choroidal haemangioma
- c) Choroidal metastasis
- d) Choroidal granuloma

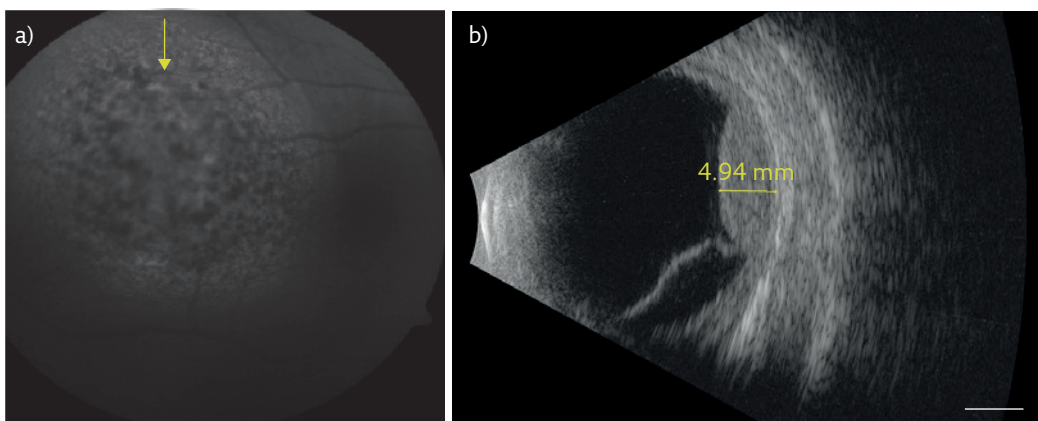


Figure 1 a) Red-free funduscopy of the right eye. The arrow indicates pathological findings in the choroid. b) Ultrasonography of the right eye, showing measurement of the choroidal mass. Scale bar=5 mm. Images from April 2018, courtesy of Z. Hendrickson, Clinic of Ophthalmology, 1st Medical Faculty of Charles University and General University Hospital, Prague, Czech Republic.

@ERSpublications

Can you diagnose this patient with vision problems? <https://bit.ly/3vGe5qy>



© ERS 2021

Answer 1

a, b, c and d. The differential diagnosis for a choroid lesion includes a diverse array of clinical features ranging from life-threatening malignant melanomas and metastases to a granuloma or haemangioma. Due to the abundant vascular supply of the choroid, it is the most common ocular site for metastasis of systemic neoplasms.

The final ophthalmic exam, including ultrasound, found a solitary choroidal metastasis in the right eye.

Approximately 1 week after the ophthalmic exam, the patient experienced mild shortness of breath, dry cough, chest pain and weakness. Furthermore, there was an unintentional weight loss of ~5 kg over 3 months.

A solitary choroidal metastasis was diagnosed. Thus, a further clinical examination was started immediately. Physical examination findings, including auscultation of the lung, and blood tests (blood chemistry tests, complete blood count) were normal except for an elevated C-reactive protein (CRP) level of $25 \text{ mg}\cdot\text{L}^{-1}$ (normal values $0.0\text{--}5.0 \text{ mg}\cdot\text{L}^{-1}$). Blood oxygen saturation was 96% on room air. The patient had no paraneoplastic signs.

Task 2

What would you order next? More than one answer may be appropriate.

- a) Brain magnetic resonance imaging (MRI)
- b) Whole-body ^{18}F -2-fluoro-2-deoxy-D-glucose positron emission tomography (FDG-PET)/ computed tomography (CT)
- c) Chest CT
- d) Abdominal CT
- e) Chest radiography

Answer 2

a and b. The international standard is PET/CT and brain MRI. A whole-body FDG-PET/CT is used to assess tumour spread in the rest of the body, but not the brain. Increased glucose metabolism, indicated by an increased FDG uptake, is usually seen in proliferative tumours. A physiologically high FDG uptake in healthy brains hampers the delineation of brain tumours or metastases. The gold standard for diagnosing brain metastases remains MRI. In some countries, PET/CT or brain MRI is not feasible due to financial constraints or availability. Alternatively, it is possible to run CT of the brain, chest and abdomen.

The patient's chest radiograph (figure 2a) and CT (figure 2b) showed a tumour mass in the upper lobe of the left lung. The abdominal CT detected multiple hepatic metastases (figure 2c). A brain MRI failed to show other lesions, except for the solitary choroidal metastasis.

Bronchoscopy was performed; however, the tumour was difficult to reach. The endobronchial findings were normal and a transbronchial biopsy failed to find any sign of malignancy. Based on these results, a CT-navigated liver biopsy of metastases was performed. The biopsy showed non-small cell lung cancer (NSCLC) metastases, more specifically adenocarcinoma that was positive for thyroid transcription factor-1 (TTF-1) and cytokeratin 7 (CK7).

Task 3

What is the next step?

- a) Molecular testing
- b) Immediately start treatment

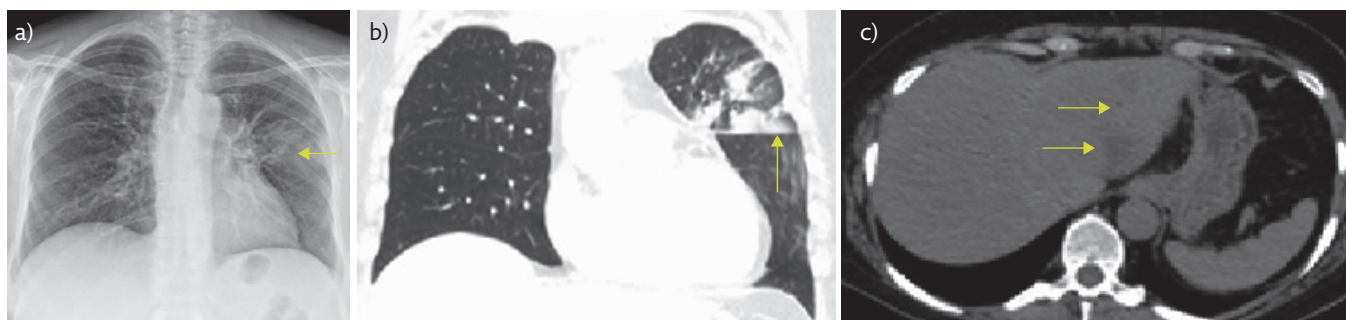


Figure 2 a) Chest radiography and b) chest CT showed a tumour mass (arrows). c) Abdominal CT, without contrast because the patient got an allergic rash after a chest CT, so next CTs were with pre-medication. Arrows indicate multiple hepatic metastases. Images from April 2018.

Answer 3

a. It is essential to test patients with newly diagnosed advanced NSCLC for molecular abnormalities prior to treatment initiation. It is important to identify patients who may benefit from targeted therapies.

A molecular investigation revealed epidermal growth factor receptor (EGFR) and ROS1 negativity, anaplastic lymphoma kinase (ALK) positivity, and programmed death-ligand 1 (PD-L1) expression of 10%. ALK was tested using immunohistochemistry D5F3 anti-ALK antibody. The immunostaining score was reported to be 3+.

Task 4

Which method(s) can be used to detect ALK gene rearrangement?

- a) Immunohistochemistry
- b) Next-generation sequencing (NGS)
- c) Fluorescence *in situ* hybridisation (FISH)
- d) Plasma-based cell-free DNA (cfDNA) techniques or “liquid biopsy”

Answer 4

a, b, c and d. All these options are possible. Different methods can be used to detect ALK rearrangement; routinely, FISH or immunohistochemistry are used. NGS can identify ALK-acquired resistance mutations outside of gene fusions. Plasma-based cfDNA techniques or “liquid biopsy” is a minimally invasive and rapid method for detecting ALK mutations. The cfDNA method is based on detection and quantitation of the fusion product in plasma cfDNA. cfDNA can be analysed using different PCR assays.

The final diagnosis was made on 25 May 2018: NSCLC, left upper lobe, adenocarcinoma, T3N2M1c (according to the 8th edition of the TNM classification), stage IVB, EGFR-negative, ALK-positive, ROS1-negative, PD-L1 10%.

After establishment of stage IV lung cancer disease, the patient was living with her husband, self-supplying. Palliative support was not necessary. For the ocular lesion, systemic treatment was recommended by the ophthalmologist because the metastasis was beyond the scope of local therapy.

Task 5

What is/are the recommended first-line treatment(s) for the patient, based on guidelines?

- a) Chemotherapy
- b) Immunotherapy
- c) Chemotherapy plus immunotherapy
- d) Targeted biological therapy (*i.e.* an ALK inhibitor)

Answer 5

d. ALK inhibitors are the standard of care for patients with ALK-positive metastatic NSCLC. They offer better progression-free and overall survival, and a better toxicity profile. Second-generation ALK tyrosine kinase inhibitors (TKIs) (such as alectinib, ceritinib and brigatinib) are now the first-line treatment for advanced ALK-positive NSCLC. In the case of ALK-rearranged NSCLC, other agents are currently under investigation.

Due to regulatory obstacles present in 2018, ALK-positive patients were given chemotherapy as first-line treatment in the Czech Republic. The patient was scheduled to receive chemotherapy (carboplatin and vinorelbine), given 3 weeks apart (June–July 2018). After two cycles, the patient developed severe chemotherapy-induced anaemia, and clinical tolerance was poor (*i.e.* nausea, vomiting).

During this period, the patient experienced acute dyspnoea, suggestive of pulmonary embolism. Arterial blood gas analysis was as follows: pH 7.52, arterial oxygen tension 6.6 kPa, arterial carbon dioxide tension 4.1 kPa, HCO_3^- level $24 \text{ mmol}\cdot\text{L}^{-1}$, oxygen saturation 86%. She was referred to the emergency department and underwent CT angiography of the pulmonary arteries, at which time a pulmonary embolism was diagnosed. Due to the recent pulmonary embolism and poor tolerance of chemotherapy, the patient's performance status was Eastern Cooperative Oncology Group (ECOG) 2–3; chemotherapy was stopped.

A control CT (figure 3) showed progression of the primary tumour and the hepatic metastases; nonetheless, the patient showed significant improvement. The pulmonary embolism was treated with low-molecular-weight heparin and the tumour treatment was re-evaluated.

The patient was started on the ALK TKI crizotinib, as a second-line treatment. She received crizotinib 250 mg twice daily starting at the end of August 2018. Monthly follow-ups included radiography and complete blood tests. Crizotinib tolerance

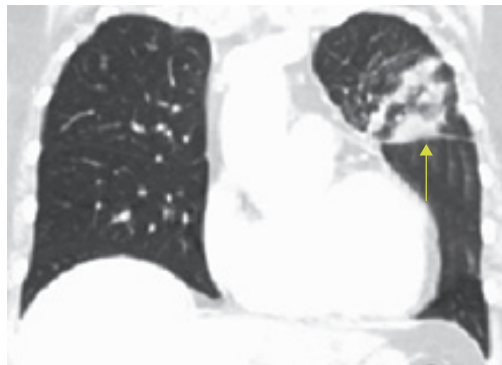


Figure 3 CT after two cycles of chemotherapy. The arrow indicates the primary tumour. Image from August 2018.

was excellent; her performance status improved to ECOG 1.

There was a clear regression of the choroid metastasis (figure 4a), and regression of the primary lung tumour on chest radiography (figure 4b). The patient had partial recovery of visual function in the right eye. Breathing problems partially resolved, and the blood oxygen saturation was 93%.

After 6 months of treatment, blood tests revealed an elevation of aspartate transaminase (AST) and alanine transaminase (ALT) (grade 1). The follow-up CT showed progression of the liver metastases as well as new bone metastases. The patient continued on crizotinib until the beginning of March 2019.

Because of disease progression, she was switched to third-line treatment with a second-generation ALK inhibitor, alectinib, at a dose of 600 mg twice daily, starting in March 2019. Initially, and for 2 months, the patient had excellent alectinib tolerance. After 2 months, there was an enormous spike in liver enzymes and bilirubin (grade 4); creatinine was $220 \text{ mmol}\cdot\text{L}^{-1}$ (normal values $45\text{--}84 \text{ mmol}\cdot\text{L}^{-1}$). The patient's performance status dropped to ECOG 3. An abdominal ultrasound found diffuse liver metastases

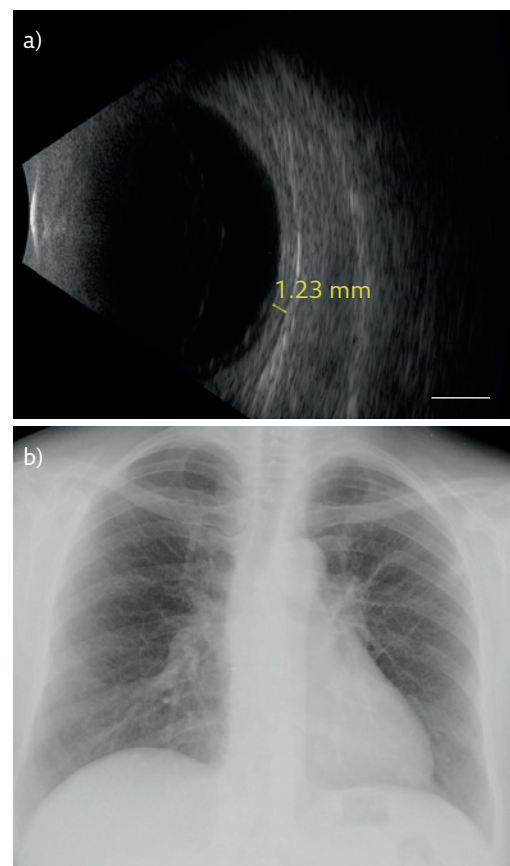


Figure 4 a) Ultrasound of the right eye after 5 months of crizotinib, with measurement showing regression of the choroidal metastasis. Scale bar=5 mm. Image from January 2019, courtesy of Z. Hendrickson, Clinic of Ophthalmology, 1st Medical Faculty of Charles University and General University Hospital, Prague, Czech Republic. b) Chest radiograph showing regression of the primary lung tumour after 4 months of crizotinib. Image from December 2018.

and ascites. Alectinib was stopped and symptomatic treatment was started. The patient died 1 month later.

Discussion

Our educational aims were to increase awareness about ALK-positive NSCLC, including diagnostic procedures and treatment. We wanted to draw attention to possible uncharacteristic symptoms, such as visual problems or blindness caused by choroidal metastasis. We also aimed to emphasise a high tendency of ALK-positive NSCLC to metastatic spread.

The ALK gene is located on the short arm of chromosome 2 (2p23) and encodes the transmembrane ALK protein with tyrosine kinase activity. It has an extracellular domain, a transmembrane segment and a cytoplasmic receptor kinase segment [1]. ALK is expressed during neonatal development of the nervous system; however, more is known about its pathological roles [2]. There are three types of ALK gene mutations: translocation, amplification and point mutation. Most mutations of the ALK gene are in the form of a translocation with another partner gene, leading to a fusion oncogene [3]. This translocation results in uncontrolled cellular proliferation and survival.

ALK-positive NSCLC represents approximately 4–5% of lung adenocarcinomas [4]. The most common type of translocation in NSCLC is EML4-ALK, which was first described in 2007 [5]. Patients with ALK-positive tumours tend to be younger and more likely to have never smoked or to have been light smokers [6].

Tissue-based ALK rearrangement can be detected using FISH or immunohistochemistry. NGS can identify ALK-acquired resistance mutations outside of gene fusions. Plasma-based cfDNA techniques or “liquid biopsy” can also be used to detect ALK mutations and is a minimally invasive and rapid method [7]. Based on previous studies, immunohistochemistry scores 0 and 3+ were nearly 100% concordant with FISH-negative and FISH-positive status, respectively. Immunohistochemistry scores 1+ and 2+ might require further confirmatory testing by FISH assay. Immunohistochemistry assay using D5F3 and 5A4 antibodies reliably detect NSCLC with ALK rearrangement [8].

In our case, because the intensity of immunohistochemical staining by D5F3 anti-ALK antibody was 3+, FISH was not performed. If the intensity of immunohistochemical staining had been 2+ or 1+, we would have sent the sample to be confirmed using FISH.

ALK-positive NSCLC patients have a higher risk of developing brain metastases than patients with other NSCLC subtypes [9]. Due to the abundant vascular supply of the choroid, it is the most common ocular site for metastasis of a systemic neoplasm [10]. The first case of choroidal metastasis was documented by PERLS [11] in 1872. Symptomatic choroidal

metastasis is a rare presenting manifestation of lung cancer [12]. Distinct features on ophthalmoscopy and various imaging modalities can distinguish choroidal metastases from other choroidal lesions [10]. Fundoscopy, ultrasonography and fluorescein angiography are complemented by indocyanine green angiography and optical coherence tomography [13]. Choroidal metastases usually appear as creamy white or pale yellow masses associated with the subretinal fluid. Their appearance can be flat or plateaued or sometimes mushroom-shaped. The most common associated feature of choroidal metastases is subretinal fluid [14]. Ultrasound of the eye helps distinguish choroidal metastasis from other choroidal lesions based on its different histoarchitecture. Choroidal tumour biopsy may help to confirm the metastatic nature and determine the site of the primary tumour [13].

In our case, a choroidal lesion biopsy was not performed. The outcomes of the imaging modalities were consistent with metastasis, and we expected metastases based on the patient’s subsequent breathing problems.

Proper staging is crucial, and MRI has exquisite sensitivity for the detection of brain tumours or metastases and remains the modality of choice to determine metastatic spread to the brain [15]. We ordered a brain MRI and CT of the chest and abdomen for staging, because there was a 1-month waiting time to get PET/CT. A bone scintigram was not performed to assess for bone metastases because main skeletal metastases can be detected during staging scans with CT, a bone scintigram was quite expensive, and it would not change the staging.

Second-generation ALK TKIs (such as alectinib, ceritinib and brigatinib) are standard-of-care first-line treatment of advanced ALK-positive NSCLC; however, crizotinib remains the standard-of-care first-line treatment in several countries [7]. In the head-to-head comparative ALEX trial (ClinicalTrials.gov identifier NCT02075840), a study comparing alectinib with crizotinib in treatment-naïve ALK-positive advanced NSCLC participants, alectinib showed superiority to crizotinib in progression-free survival (34.8 *versus* 10.9 months; hazard ratio 0.43), overall response rate (82.9% *versus* 75.5%, $p=0.09$) and toxicity profile [16, 17]. Additionally, alectinib is associated with a significant reduction in the incidence of brain metastases compared with crizotinib [18]. Additional exploratory overall survival analyses from the PROFILE 1014 trial (ClinicalTrials.gov identifier NCT01154140), a study comparing first-line crizotinib *versus* chemotherapy in ALK-positive NSCLC, showed that chemotherapy followed by ALK TKI in any line of subsequent treatment is associated with worse overall survival (median 49.5 months, 95% CI 41.0 months to not reached) compared to crizotinib followed by ALK TKI in any line of subsequent treatment (median overall survival not reached, 95% CI not reached to not reached) [19].

Unfortunately, due to regulatory obstacles, our patient had chemotherapy as a first-line treatment (carboplatin with vinorelbine). The treatment was started by a less experienced doctor. Cisplatin with pemetrexed would have been more suitable because of the adenocarcinoma histology. Bevacizumab was not added, as the doctor was afraid of an increased risk of choroidal haemorrhage. After failure of chemotherapy, our patient received crizotinib, a first-generation ALK TKI, as second-line treatment. Our patient's vision improved with crizotinib. There is no doubt that the best option for first-line treatment would have been a second-generation ALK TKI. This is an example of how regional regulatory authorities may negatively influence a patient's prognosis. The situation has changed. A second-generation ALK TKI (alectinib) is currently the standard for first-line treatment in the Czech Republic.

Nonetheless, sooner or later, acquired resistance to ALK TKIs often develops and leads to clinical relapse. If there is suspicion of progression during treatment with a first-generation or second-generation ALK TKI, a liquid biopsy or tissue re-biopsy should be performed [7]. We did not perform liquid biopsy to analyse resistance mutation because the method was not available at that time.

Lorlatinib is a third-generation oral ALK TKI. Lorlatinib was designed to overcome known secondary resistance mutations in the ALK tyrosine

kinase domain and is a very promising drug for ALK-positive patients [20].

Because our patient's performance status was ECOG 3 and because of the enormous rise in liver enzymes, bilirubin and creatinine, we did not perform a re-biopsy and symptomatic treatment was the only remaining option. An abdominal ultrasound found diffuse liver metastases and ascites. An abdominal CT is not comparable with ultrasound. However, the ultrasound was favoured over abdominal CT because the patient's performance status dropped to ECOG 3, there was an enormous spike in liver enzymes and bilirubin, creatinine was $220 \text{ mmol}\cdot\text{L}^{-1}$ and we also considered biliary obstruction; ultrasound was quick.

Conclusion

Although an ocular metastasis from the lung is unusual, it needs to be considered. In other words, we must always be aware that ALK-positive NSCLC has a high tendency to undergo metastatic spread. Any new symptom, even uncharacteristic ones, should raise suspicion of metastases and should be assessed accordingly. Even highly symptomatic ALK-positive patients might profit from ALK TKI treatment because of the high overall response rate and good tolerability.

Affiliations

Marie Drosslerova, Marketa Cernovska, Martina Vasakova, Libor Havel

Dept of Respiratory Medicine, 1st Medical Faculty of Charles University and Thomayer Hospital, Prague, Czech Republic.

Acknowledgements

The authors wish to thank Tom Secrest (Dept of Languages, 3rd Medical Faculty of Charles University, Prague, Czech Republic) for revisions on the English version of this article.

Conflict of interest

None declared.

References

1. Duyster J, Bai RY, Morris SW. Translocations involving anaplastic lymphoma kinase (ALK). *Oncogene* 2001; 20: 5623–5637.
2. Iwahara T, Fujimoto J, Wen D, *et al.* Molecular characterization of ALK, a receptor tyrosine kinase expressed specifically in the nervous system. *Oncogene* 1997; 14: 439–449.
3. Du X, Shao Y, Qin HF, *et al.* ALK-rearrangement in non-small-cell lung cancer (NSCLC). *Thorac Cancer* 2018; 9: 423–430.
4. Chia PL, Mitchell P, Dobrovic A, *et al.* Prevalence and natural history of ALK positive non-small-cell lung cancer and the clinical impact of targeted therapy with ALK inhibitors. *Clin Epidemiol* 2014; 6: 423–432.
5. Soda M, Choi YL, Enomoto M, *et al.* Identification of the transforming EML4-ALK fusion gene in non-small-cell lung cancer. *Nature* 2007; 448: 561–566.
6. Arbour KC, Riely GJ. Diagnosis and treatment of anaplastic lymphoma kinase-positive non-small cell lung cancer. *Hematol Oncol Clin North Am* 2017; 31: 101–111.
7. McCusker MG, Russo A, Scilla KA, *et al.* How I treat ALK-positive non-small cell lung cancer. *ESMO Open* 2019; 4: Suppl. 2, e000524.
8. Jiang L, Yang H, He P, *et al.* Improving selection criteria for ALK inhibitor therapy in non-small cell lung cancer: a pooled-data analysis on diagnostic operating characteristics of immunohistochemistry. *Am J Surg Pathol* 2016; 40: 697–703.
9. Petrelli F, Lazzari C, Ardito R, *et al.* Efficacy of ALK inhibitors on NSCLC brain metastases: a systematic review and pooled analysis of 21 studies. *PLoS One* 2018; 13: e0201425.

10. Arepalli S, Kaliki S, Shields CL. Choroidal metastases: origin, features, and therapy. *Indian J Ophthalmol* 2015; 63: 122-127.
11. Perls M. Beiträge zur Geschwulstlehre [Contributions to pathology of tumors]. *Virchows Arch Pathol Anat* 1872; 56: 437-467.
12. Singh N, Kulkarni P, Aggarwal AN, *et al.* Choroidal metastasis as a presenting manifestation of lung cancer: a report of 3 cases and systematic review of the literature. *Medicine (Baltimore)* 2012; 91: 179-194.
13. Mathis T, Jardel P, Loria O, *et al.* New concepts in the diagnosis and management of choroidal metastases. *Prog Retin Eye Res* 2019; 68: 144-176.
14. Konstantinidis L, Rospond-Kubiak I, Zeolite I, *et al.* Management of patients with uveal metastases at the Liverpool Ocular Oncology Centre. *Br J Ophthalmol* 2014; 98: 92-98.
15. Pope WB. Brain metastases: neuroimaging. *Handb Clin Neurol* 2018; 149: 89-112.
16. Peters S, Camidge DR, Shaw AT, *et al.* Alectinib versus crizotinib in untreated ALK-positive non-small-cell lung cancer. *N Engl J Med* 2017; 377: 829-838.
17. Camidge DR, Dziadziuszko R, Peters S, *et al.* Updated efficacy and safety data and impact of the EML4-ALK fusion variant on the efficacy of alectinib in untreated ALK-positive advanced non-small cell lung cancer in the global phase III ALEX study. *J Thorac Oncol* 2019; 14: 1233-1243.
18. Gadgeel S, Peters S, Mok T, *et al.* Alectinib versus crizotinib in treatment-naive anaplastic lymphoma kinase-positive (ALK+) non-small-cell lung cancer: CNS efficacy results from the ALEX study. *Ann Oncol* 2018; 29: 2214-2222.
19. Solomon BJ, Kim DW, Wu YL, *et al.* Final overall survival analysis from a study comparing first-line crizotinib versus chemotherapy in ALK-mutation-positive non-small-cell lung cancer. *J Clin Oncol* 2018; 36: 2251-2258.
20. Shaw AT, Solomon BJ, Besse B, *et al.* ALK resistance mutations and efficacy of lorlatinib in advanced anaplastic lymphoma kinase-positive non-small-cell lung cancer. *J Clin Oncol* 2019; 37: 1370-1379.