




Scaphoid Nonunions Treated with Nonvascularized Bone Grafting and Screw Fixation

Robert L. Zondervan, DO, PhD^{1,2,3}  Jessica R. Childe, DO, MS⁴ Robin Kustasz, OTRL¹
Erich E. Hornbach, MD²

¹McLaren Greater Lansing Hospital, Department of Orthopedics, Lansing, Michigan

²Sparrow Hospital, Lansing, Department of Orthopedics, Michigan

³Michigan State University, College of Osteopathic Medicine, East Lansing, Michigan

⁴Tulsa Bone and Joint, Tulsa, Oklahoma

Address for correspondence Robert L. Zondervan, DO, PhD, McLaren Greater Lansing Hospital, 2900 Collins Road, Lansing, MI 48910 (e-mail: rlz@msu.edu).

J Wrist Surg 2024;13:24–30.

Abstract

Background Vascularized bone grafting with screw fixation is currently considered the treatment of choice for scaphoid nonunions with avascular necrosis (AVN) of the proximal pole. A viable alternative to using vascularized bone grafts for scaphoid nonunions with AVN is nonvascularized bone grafting with screw fixation.

Question What are the functional outcomes of patients with scaphoid nonunions and associated proximal pole AVN who are treated with nonvascularized distal radius bone grafting and screw fixation?

Patients and Methods Eight scaphoid nonunions with AVN, which received nonvascularized distal radius bone graft and screw fixation, underwent a retrospective review. Range of motion, strength, and Disabilities of the Arm, Shoulder, and Hand (DASH) scores were obtained. Follow-up X-rays were compared with immediate postoperative X-rays.

Results At a mean follow-up of 88.9 months, thumb palmar abduction and radial abduction were significantly higher on the operative side ($p = 0.28$ and 0.49 , respectively). Extension/flexion arc was significantly lower in the operative wrist ($p = 0.148$). There was no significant difference between the operative and nonoperative sides with regard to strength. The median postoperative DASH score was 2.9 (interquartile range [IQR]: 8.3). There was no progression of osteoarthritis when immediate postoperative and follow-up X-rays were compared. Radiographic union was observed in six of the seven (85.7%) patients who were able to return to the office for follow-up radiographs. The mean scapholunate and radioscapoid angles measured on X-rays were within normal anatomic range postoperatively.

Conclusions Using nonvascularized distal radius bone graft and screw fixation in the treatment of scaphoid nonunions with associated AVN has favorable radiologic and functional outcomes and should be considered a viable treatment option for this difficult problem.

Keywords

- ▶ scaphoid
- ▶ fracture
- ▶ AVN
- ▶ avascular necrosis
- ▶ wrist
- ▶ graft

received
August 11, 2022
accepted
March 6, 2023
article published online
April 12, 2023

DOI <https://doi.org/10.1055/s-0043-1768236>
ISSN 2163-3916.

© 2023. The Author(s).

This is an open access article published by Thieme under the terms of the Creative Commons Attribution-NonDerivative-NonCommercial-License, permitting copying and reproduction so long as the original work is given appropriate credit. Contents may not be used for commercial purposes, or adapted, remixed, transformed or built upon. (<https://creativecommons.org/licenses/by-nc-nd/4.0/>)

Thieme Medical Publishers, Inc., 333 Seventh Avenue, 18th Floor, New York, NY 10001, USA

The rate of scaphoid fracture nonunion varies widely in the literature with estimates between 5 and 55%.^{1,2} Additionally, avascular necrosis (AVN) is seen in up to 50% of scaphoid fractures with the majority occurring in fractures of the proximal pole.^{2,3} Vascularized bone grafting with screw fixation has been argued to be the treatment of choice for scaphoid nonunions with AVN of the proximal pole; however, review of the literature does not support vascularized over nonvascularized techniques.⁴⁻⁶ The reported union rates after vascularized bone grafting and internal fixation are highly variable and ranges between 27 and 100%.⁷⁻¹³ Some of this variation may be due to the length of the procedure and its steep learning curve. A viable alternative to using vascularized bone grafts for scaphoid nonunions with AVN is nonvascularized bone grafting with screw fixation. Benefits of this procedure include shorter operative time, less demanding surgical technique, and ability to use vascularized grafting as a salvage procedure. In addition to the benefits of using nonvascularized grafts, the fracture healing potential of this technique is also promising, with a union rate of 78 to 92%.^{7,8,14} Despite the use of nonvascularized bone grafting with screw fixation for scaphoid nonunions with AVN, there have been no studies reporting functional outcomes.

The purpose of this study is to investigate the functional outcome of patients with scaphoid nonunions and associated proximal pole AVN who were treated with nonvascularized cancellous distal radius bone grafting and screw fixation.

Patients and Methods

This study was HIPAA (Health Insurance Portability and Accountability Act of 1996) compliant and approved by the institutional review board of the hospital where the procedures were performed (IRB number: 2013-00229). Informed consent was obtained from all patients for being included in the study. The study population consisted of patients between the ages of 16 and 28 years who underwent surgery for scaphoid waist or proximal pole nonunions and associated AVN of the proximal pole using nonvascularized bone graft with screw fixation. The medical records of one surgeon (E.E.H.) during a 5-year period (2004-2009) were reviewed. In all, 17 patients were identified who met the initial criteria. Patients were then contacted, and informed consent was obtained prior to the start of the study.

To be included in the study, evidence of patients' scaphoid nonunion and proximal pole AVN had to be demonstrated by computed tomography (CT) and magnetic resonance imaging (MRI), respectively. Evidence of nonunion was demonstrated on CT by lack of bridging callus formation as seen on longitudinal sections of the scaphoid perpendicular to the fracture plane at least 6 months from the time of injury. Evidence of proximal pole AVN was confirmed on MRI using the technique described by Trumble¹⁵ and Perlik and Guilford,¹⁶ in which areas of ischemic bone demonstrated low signal on T1-weighted images and iso- or hyperintense signal on T2-weighted images compared with adjacent carpal

Table 1 Patient characteristics (n = 8)

Mean age (y)	20 (range: 16-28)
Gender	
Male	8 (100%)
Female	0 (0%)
Fracture location	
Proximal pole of scaphoid	7 (87.5%)
Scaphoid waist	1 (12.5%)
Extremity injured	
Dominant	5 (63%)
Nondominant	3 (38%)
Time from injury to surgery (mo)	13 (range: 1-36)
Time from surgery to follow-up (mo)	88.9 (range: 58-124)

bones. Patients were excluded if the iliac crest bone graft was used (6 patients), or they were lost to follow-up (3 patients). **Table 1** lists the patients' demographics. Seven patients had no previous treatment of their unrecognized injury and one patient failed nonoperative treatment at an outside institution.

Of the initial 17 patients who were identified, 9 patients did not meet the inclusion criteria and were thus removed from the study. The remaining eight patients were asked to return to the surgeon's office for a final follow-up appointment to obtain an updated history and physical examination, X-rays, range of motion testing, strength testing, and to fill out a Disabilities of the Arm, Shoulder, and Hand (DASH) questionnaire. The average time from surgery to their final follow-up was 88.9 months (range: 58-124 months). Of note, one patient was incarcerated at the time of the final follow-up, so only updated history and DASH score were obtained.

A certified hand therapist measured the postoperative range of motion, wrist strength, and pinch and grip strength using a Jamar dynamometer (J.P. Marsh, Skokie, IL). Functional outcome was measured using the DASH score.

Preoperative and current X-rays were evaluated for the presence of radioscaphoid osteoarthritis and graded on a scale of 0 to 3, with grade 0 having no radioscaphoid arthritis, grade 1 having mild beaking of the radius with involvement of the radioscaphoid joint, grade 2 having narrowing of the radioscaphoid joint, and grade 3 having loss of the radioscaphoid joint. The scapholunate and radiolunate angles were measured on the preoperative and current X-rays.

All patients had CT confirmation of a scaphoid waist or proximal pole nonunion and pre-op MRI documentation of AVN of the proximal pole of the scaphoid was confirmed during surgery with the absence of punctate bleeding, which is the gold standard for diagnosis.¹⁷ One exception was a patient with a scaphoid fracture with suspected AVN 1 month after sustaining the fracture. Despite this fracture being too early to classify as a nonunion, there was AVN on presentation and this was felt to go onto nonunion without treatment so they were included in the study.

Surgical Technique

A dorsal approach was used to expose the scaphoid nonunion. The absence of punctate bleeding of the proximal pole confirmed AVN. Attention was then directed toward obtaining the bone graft from the distal radius. The graft was harvested by osteotome just proximal to Lister's tubercle. The void was filled with Osteoset (Wright Medical, Memphis, TN). The posterior interosseous nerve was located in the floor of the fourth dorsal compartment and a 1-cm section was removed.

The nonunion was then debrided of fibrous tissue and small holes were drilled in the distal portion with a K-wire to increase the potential of vascular channels. After thorough debridement, cancellous distal radius bone graft was packed into the nonunion site and any surrounding cysts. The fracture was reduced under fluoroscopy and the appropriate length Acutrak (Acumed, Beaverton, OR) screw was placed. Wrist range of motion was performed under fluoroscopy to ensure stability of the fracture site. The wound was thoroughly irrigated and closed, and sterile dressing was applied.

Postoperatively patients were placed in a plaster thumb spica splint immediately post-op. While in the splint, patients were also instructed to use a bone stimulator (OrthoPak, Biomet, Warsaw, IN) for 10 hours per day for the first 8 weeks. The stimulator generates an electrical field that applies a sinusoidal wave of 3 to 6 V, 60 kHz, and 5 to 10 mA to stimulate bone growth in nonunions. The capacitive coupling bone stimulator leads were placed on the dorsal surface of the carpus through a window made in the splint with leads ulnar and radial to the scaphoid. The splint was removed 7 to 10 days post-op and the sutures were removed.

The patients were then placed in a thumb spica cast for 8 weeks. After 8 weeks, the cast was removed, and the patients wore a removable thumb spica splint. The splint was worn full time for an additional 4 to 8 weeks depending on radiographic appearance of the healing, and then was weaned off. Physical therapy was initiated at 12 weeks.

Statistical Analysis

Study data are presented as values and percentages for categorical variables. Continuous variables were tested for normalcy using the Shapiro–Wilk normality test. Continuous variables with normal distribution are presented as mean values \pm standard deviation and non-normal are presented as median and interquartile range (IQR). Comparison of pre- and postoperative X-rays were made using the Wilcoxon signed-rank test. Pre- and postoperative scapholunate and radiolunate angles were compared using paired Student's *t*-test. Descriptive statistics were calculated for clinical assessment values (range of motion, strength, and Jamar grip strength) as well as functional outcome scores (DASH, work, and sports). Comparisons of clinical assessment were made between operative and nonoperative side using Student's *t*-test. For all statistical tests, the level of significance was set at $p < 0.05$. Statistical analyses were performed using the open-source R environment (3.1.0).

Results

Radiographs

There was no significant difference ($p = 0.356$) with osteoarthritis grades between the pre- and postoperative X-ray

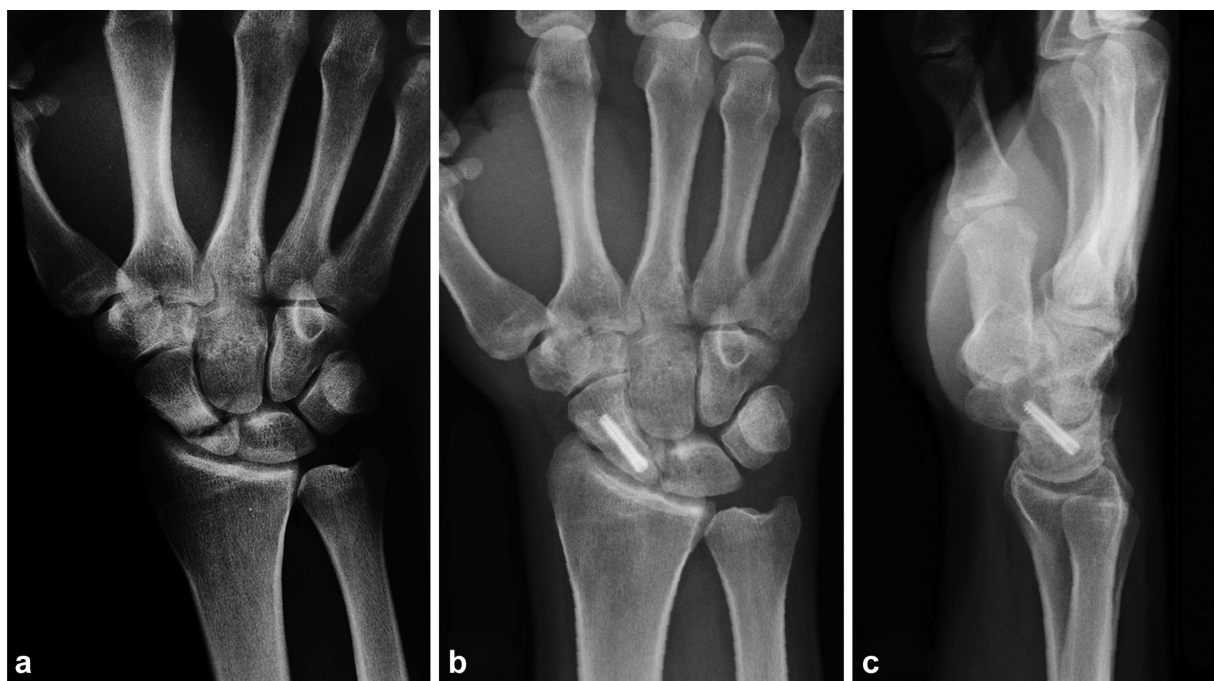


Fig. 1 Pre- and postoperative radiographs of a scaphoid nonunion with avascular necrosis. (a) Preoperative posteroanterior radiograph of a proximal pole scaphoid nonunion with avascular necrosis. Postoperative (b) posteroanterior and (c) lateral radiographs of a healed scaphoid nonunion with avascular necrosis fixed with nonvascularized bone graft and screw fixation.

Table 2 Radiographic assessment ($n = 7$)

	Preoperative		Postoperative		Significant	p value	Test
Median OA score	0	(IQR: 0.5)	0	(IQR: 1)	No	0.356	WCSRT
Mean scapholunate angle (degrees)	63.57	(SD: ± 9.86)	54.43	(SD: ± 13.75)	No	0.101	T
Mean radiolunate angle (degrees)	13.43	(SD: ± 10.23)	8.43	(SD: ± 11.60)	No	0.258	T

Abbreviations: IQR, interquartile range; OA, osteoarthritis; SD, standard deviation; WCSRT, Wilcoxon signed-rank test.

assessment (\rightarrow Fig. 1), with median scores of 0 (IQR: 0.5) and 0 (IQR: 0), respectively (\rightarrow Table 2). There was evidence of bony union, demonstrated by bridging callus of >3 cortices, at 12 weeks in six of the seven (85.7%) patients who were able to return to the office for follow-up radiographs.

Postoperatively, the mean scapholunate and radiolunate angles were 54.43 ± 13.75 and 8.43 ± 11.60 , respectively, and within normal anatomic limits (scapholunate: 36–66; radiolunate: -10 to 12).¹⁸ While there was a slight improvement in scapholunate and radiolunate angles between the preoperative and postoperative radiographs, differences were not significant. The mean differences in angle for scapholunate and radiolunate angles were 9.12 ± 12.5 ($p = 0.10$) and 5 ± 10.60 ($p = 0.26$), respectively.

Range of Motion

Range of motion assessment is presented in \rightarrow Table 3. Thumb palmar abduction and thumb radial abduction were significantly higher on the operative side compared with the nonoperative side ($p = 0.028$ and 0.049 , respectively). Wrist flexion/extension was significantly greater in the nonoperative side ($p = 0.0148$). In all other range of motion assess-

ments, there was no significant difference between the operative and nonoperative sides ($p > 0.05$).

Strength

Key and tip strength postoperatively were not significantly different between the operative and nonoperative sides ($p > 0.05$). The postoperative grip strength for the right and left wrist flexion, extension, radial deviation, and ulnar deviation was 5 out of 5 for all patients except for the operative side ulnar deviation in which one patient (14.3%) scored a 4 out of 5.

There was no significant difference ($p > 0.05$) in Jamar grip strength between the operative and nonoperative sides (\rightarrow Fig. 2). The average maximum grip strength for both operative and nonoperative hands was measured at Jamar level 2.

Functional Outcome

The median postoperative functional scores for DASH, work, and sports were 2.915 (IQR: 8.33), 0 (IQR: 17.19), and 0 (IQR: 1.56), respectively. Of the eight patients scored, only two had nonzero sport scores (75 and 6.25) and three had nonzero work scores (43.75, 12.5, and 31.25).

Table 3 Postoperative clinical evaluation ($n = 7$)

	Operative	Nonoperative	Significant	p value	Normal ⁷
Mean strength (lb)					
Key	22.7 (SD: ± 3.2)	22.3 (SD: ± 5.1)	No	0.702	19.9
Tip	22.0 (SD: ± 2.4)	21.6 (SD: ± 4.3)	No	0.764	13.9
Mean range of motion (degrees)					
<i>Thumb IP</i>					
Flexion/extension arc	95.0 (SD: ± 17.6)	96.6 (SD: ± 21.4)	No	0.787	95
<i>Thumb MP</i>					
Flexion/extension arc	74.3 (SD: ± 19.4)	78.1 (SD: ± 11.1)	No	0.462	65
<i>Thumb</i>					
Palmar abduction	64.4 (SD: ± 12.9)	52.0 (SD: ± 7.3)	Yes	0.028	45
Radial abduction	57.0 (SD: ± 19.6)	50.4 (SD: ± 15.1)	Yes	0.049	60
<i>Wrist</i>					
Flexion/extension arc	143.7 (SD: ± 13.9)	157.3 (SD: ± 7.7)	Yes	0.015	145
Radial deviation	19.1 (SD: ± 6.1)	21.7 (SD: ± 3.2)	No	0.274	20
Ulnar deviation	39.6 (SD: ± 5.8)	43.3 (SD: ± 6.9)	No	0.103	35

Abbreviations: IP, interphalangeal joint; MP, metacarpophalangeal joint; SD, standard deviation.

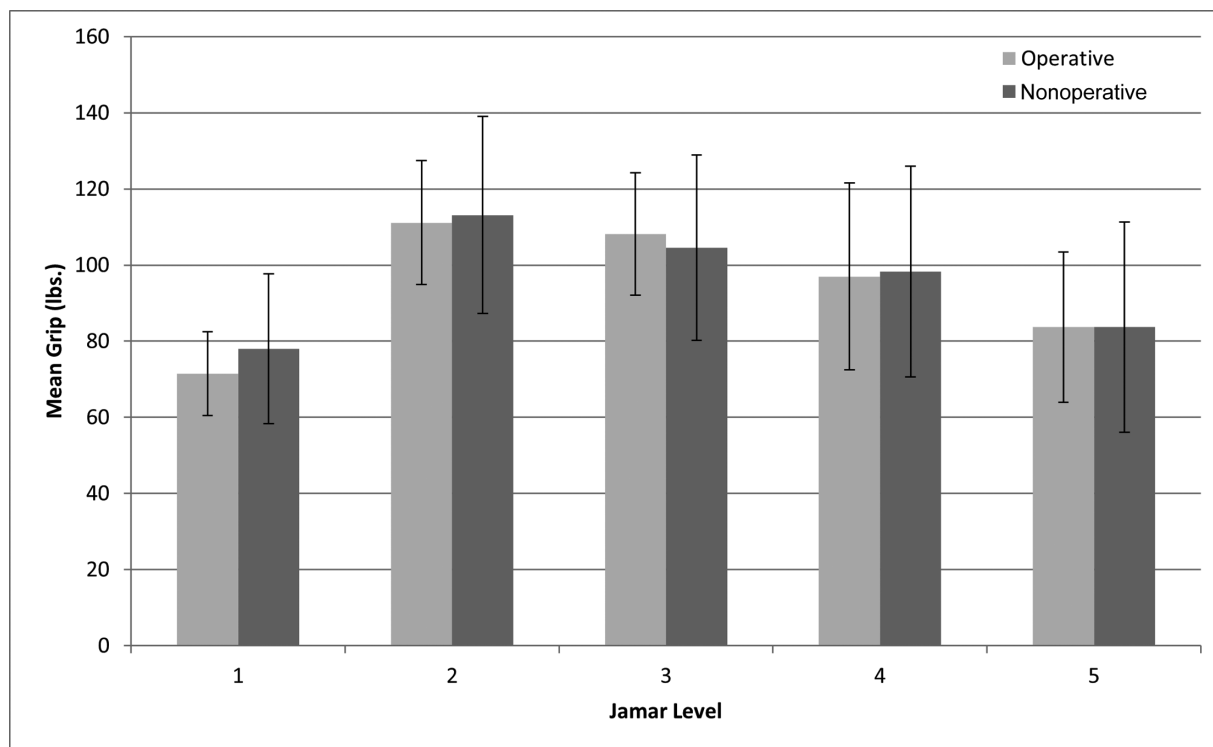


Fig. 2 Jamar hand grip strength. Jamar strength profile in operative and nonoperative hands. No significant difference was seen between hands.

Discussion

Due to tenuous blood supply, scaphoid nonunions are a challenge to treat.^{17,19} An essential component of managing these fractures is the accurate detection and diagnosis of AVN. The gold standard for diagnosis of AVN is intraoperative punctate bleeding at the proximal pole of the scaphoid; unfortunately, the process is invasive and not practical or feasible in the clinical setting. An additional limitation to the intraoperative assessment is that the absence of punctate bleeding does not always correlate with histologic loss of viable osteocytes.²⁰ Radiographs often show sclerosis at the scaphoid fracture site, which may indicate AVN; however, this is a nonspecific finding and may also represent early bone healing or bone compaction secondary to the fracture. While CT scans have high special resolution and can accurately image bony bridging and fracture morphology, Ber-vian et al²¹ found no correlation between CT findings and proximal fragment necrosis. Currently, MRI remains the best option for noninvasive diagnosis of scaphoid AVN with reported sensitivities and specificities of up to 72 and 100%, respectively.²¹ The hallmark features of AVN on MRI are osseous regions of hypointensity seen on T1- and T2-weighted sequences and lack of enhancement on fat-suppressed T1-weighted postgadolinium sequences.

Despite advancements in imaging to diagnose scaphoid nonunion with AVN, there is no clear consensus on optimal treatment strategy. The concern with treating nonunions using nonvascularized bone grafting is the risk of a persistent nonunion with AVN and lower union rates with subsequent procedures. However, reports of failed unions due to non-

vascularized and vascularized grafts have been inconsistent. Boyer et al¹³ had four failures after 1,2 intercompartmental supraretinacular artery (1,2-ICSRA) vascularized bone grafting in which all four patients had failed prior surgery with nonvascularized bone grafting. On the other hand, a 2009 study by Waitayawinyu et al²² demonstrated a 93% (28 of 30 patients) union rate after vascularized bone grafting of scaphoid nonunions with proximal pole AVN. The two patients in their study who did not heal after the index procedure went on to heal after nonvascularized bone grafting, indicating this is a viable treatment option as well as salvage procedure for this problem. Conversely, other studies have reported a 100% union rate with 1,2-ICSRA vascularized bone grafting after failed nonvascularized bone grafting.⁴ Schuind et al reported that fracture location, proximal pole osteonecrosis, failed prior surgical attempts, and type of surgical procedure did not significantly affect the healing rates of nonunions treated with nonvascular bone grafting.²³ However, Rancy et al⁶ question the clinical relevance of all these studies and argue that investigating vascularized and nonvascularized grafts for scaphoid nonunions is limited due to a lack of accurate and reliable modalities to diagnose AVN. Without a validated noninvasive tool that can accurately report bone vascular status, it is difficult to assess if a surgical treatment strategy was successful let alone compared between strategies. Intraoperatively, Rancy et al⁶ support collecting proximal and distal samples for histologic and immunohistological analysis, which can be correlated with CT assessment of the trabecular structure.

A strength of this study is the prolonged follow-up window of 88.9 months (range: 58–124 months). This time

frame is adequate to show long-term potential issues that may arise postoperatively. At the patients' final clinic visit, X-rays of all wrists showed no progression in radioscaphoid arthritis when compared with their preoperative X-rays. Postoperative range of motion in the operative extremity was better or at the most 3 degrees less than the listed normal values.²⁴ Jamar grip strength values followed the standard curve with level 2 demonstrating the highest values, and this showed very little difference between the operative and nonoperative extremities.

The DASH scores were low overall with a median of 2.94 (range: 0–100). One patient stated he was diagnosed with psoriatic arthritis approximately 1 year after his scaphoid surgery, which could explain their higher DASH score of 26.67. He had received treatment for the psoriatic arthritis shortly after diagnosis and reported significant improvement in his pain with treatment. Unfortunately, due to cost of this treatment, at his most recent follow-up appointment he was not receiving treatment for his psoriatic arthritis and did admit to continued pain he attributed to his condition and not his prior scaphoid injury. This may have skewed some of our results and the patient did feel he was functionally limited due to untreated symptoms from this condition.

One patient in our study had a symptomatic persistent nonunion that was confirmed by CT scan. He failed to heal after undergoing the procedure described in this study. After his persistent nonunion was diagnosed ~8 months later, he was given the option of referral for second opinion, repeat nonvascularized bone grafting with screw fixation, or removal of screw with additional bone grafting. He decided on the latter as he wanted to go back to work quickly despite the low risk of success. He was seen 13 months after the second procedure with a persistent nonunion, but continued to work and only reported mild pain. He was not interested in pursuing further surgical treatment at that time.

Limitations to our study include not obtaining intraoperative histologic samples or postoperative CT scans to confirm bony healing of the nonunions. Studies have shown that serial radiographs have poor interobserver agreement in assessing scaphoid fracture union 12 weeks postsurgery.²⁵ Despite this, radiographs continue to be the modality of choice to assess union, which is defined as "the restoration of bony architecture across the fracture site."²⁶ The authors felt that it was adequate to call a nonunion healed if bony bridging could be seen on three cortices in radiographs, there was an absence of sclerosis, and the clinical examination was negative for instability and pain on palpation of the scaphoid.

Another limitation was the small patient sample. Scaphoid nonunions with proximal pole AVN are an uncommon diagnosis, especially when only reviewing one surgeon's medical records. Because of the small sample size, some of the statistics were underpowered and might have shown significance with more patients included. Finally, the design of our study is retrospective, and we do not have preoperative range of motion, strength, or DASH scores to compare our postoperative results to. We can assume that the values

would likely have been much lower preoperatively as almost all patients in our study were seeking treatment for a disabling problem they did not have a previous diagnosis for.

There have been several studies reporting the union rates of scaphoid nonunions with ANV treated with nonvascularized and vascularized bone grafting procedures; however, there has been very limited research on patient outcomes. The findings from our study supports nonvascularized distal radius bone grafting with screw fixation as a viable treatment option for scaphoid nonunions with proximal pole AVN.

Ethical Review Committee Statement

Informed consent was obtained from all patients for being included in the study. All procedures followed were in accordance with the ethical standards of the responsible committee on human experimentation (McLaren Healthcare IRB, Lansing, MI, USA) and with the Helsinki Declaration of 1975, as revised in 2008 (5).

IRB Number: 2013–00229.

Conflict of Interest

None declared.

References

- Kuschner SH, Lane CS, Brien WW, Gellman H. Scaphoid fractures and scaphoid nonunion. Diagnosis and treatment. *Orthop Rev* 1994;23(11):861–871
- Szabo RM, Manske D. Displaced fractures of the scaphoid. *Clin Orthop Relat Res* 1988;(230):30–38
- Steinmann SP, Adams JE. Scaphoid fractures and nonunions: diagnosis and treatment. *J Orthop Sci* 2006;11(04):424–431
- Zaidenberg C, Siebert JW, Angrigiani C. A new vascularized bone graft for scaphoid nonunion. *J Hand Surg Am* 1991;16(03):474–478
- Steinmann SP, Bishop AT, Berger RA. Use of the 1,2 intercompartmental supraretinacular artery as a vascularized pedicle bone graft for difficult scaphoid nonunion. *J Hand Surg Am* 2002;27(03):391–401
- Rancy SK, Schmidle G, Wolfe SW. Does Anyone Need a Vascularized Graft? *Hand Clin* 2019;35(03):323–344
- Munk B, Larsen CF. Bone grafting the scaphoid nonunion: a systematic review of 147 publications including 5,246 cases of scaphoid nonunion. *Acta Orthop Scand* 2004;75(05):618–629
- Kim J, Park JW, Chung J, Jeong Bae K, Gong HS, Baek GH. Nonvascularized iliac bone grafting for scaphoid nonunion with avascular necrosis. *J Hand Surg Eur Vol* 2018;43(01):24–31
- Straw RG, Davis TRC, Dias JJ. Scaphoid nonunion: treatment with a pedicled vascularized bone graft based on the 1,2 intercompartmental supraretinacular branch of the radial artery. *J Hand Surg [Br]* 2002;27(05):413
- Tsai TT, Chao EK, Tu YK, Chen ACY, Lee MSS, Ueng SWN. Management of scaphoid nonunion with avascular necrosis using 1, 2 intercompartmental supraretinacular arterial bone grafts. *Chang Gung Med J* 2002;25(05):321–328
- Malizos KN, Dailiana ZH, Kirou M, Vragalas V, Xenakis TA, Soucacos PN. Longstanding nonunions of scaphoid fractures with bone loss: successful reconstruction with vascularized bone grafts. *J Hand Surg [Br]* 2001;26(04):330–334
- Uerpaiojkit C, Leechavengvongs S, Witoonchart K. Primary vascularized distal radius bone graft for nonunion of the scaphoid. *J Hand Surg [Br]* 2000;25(03):266–270

- 13 Boyer MI, von Schroeder HP, Axelrod TS. Scaphoid nonunion with avascular necrosis of the proximal pole. Treatment with a vascularized bone graft from the dorsum of the distal radius. *J Hand Surg [Br]* 1998;23(05):686–690
- 14 Luchetti TJ, Rao AJ, Fernandez JJ, Cohen MS, Wysocki RW. Fixation of proximal pole scaphoid nonunion with non-vascularized cancellous autograft. *J Hand Surg Eur Vol* 2018;43(01):66–72
- 15 Trumble TE. Avascular necrosis after scaphoid fracture: a correlation of magnetic resonance imaging and histology. *J Hand Surg Am* 1990;15(04):557–564
- 16 Perlik PC, Guilford WB. Magnetic resonance imaging to assess vascularity of scaphoid nonunions. *J Hand Surg Am* 1991;16(03):479–484
- 17 Büchler U, Nagy L. The issue of vascularity in fractures and nonunion of the scaphoid. *J Hand Surg [Br]* 1995;20(06):726–735
- 18 Larsen CF, Mathiesen FK, Lindequist S. Measurements of carpal bone angles on lateral wrist radiographs. *J Hand Surg Am* 1991;16(05):888–893
- 19 Taleisnik J, Kelly PJ. The extraosseous and intraosseous blood supply of the scaphoid bone. *J Bone Joint Surg Am* 1966;48(06):1125–1137
- 20 Green DP. The effect of avascular necrosis on Russe bone grafting for scaphoid nonunion. *J Hand Surg Am* 1985;10(05):597–605
- 21 Bervian MR, Ribak S, Livani B. Scaphoid fracture nonunion: correlation of radiographic imaging, proximal fragment histologic viability evaluation, and estimation of viability at surgery: diagnosis of scaphoid pseudarthrosis. *Int Orthop* 2015;39(01):67–72
- 22 Waitayawinyu T, McCallister WV, Katolik LI, Schlenker JD, Trumble TE. Outcome after vascularized bone grafting of scaphoid nonunions with avascular necrosis. *J Hand Surg Am* 2009;34(03):387–394
- 23 Schuind F, Haentjens P, Van Innis F, Vander Maren C, Garcia-Elias M, Sennwald G. Prognostic factors in the treatment of carpal scaphoid nonunions. *J Hand Surg Am* 1999;24(04):761–776
- 24 Mathiowetz V, Kashman N, Volland G, Weber K, Dowe M, Rogers S. Grip and pinch strength: normative data for adults. *Arch Phys Med Rehabil* 1985;66(02):69–74
- 25 Dias JJ, Taylor M, Thompson J, Brenkel JJ, Gregg PJ. Radiographic signs of union of scaphoid fractures. An analysis of inter-observer agreement and reproducibility. *J Bone Joint Surg Br* 1988;70(02):299–301
- 26 Dias JJ. Definition of union after acute fracture and surgery for fracture nonunion of the scaphoid. *J Hand Surg [Br]* 2001;26(04):321–325