

Endorectal fusion imaging: A description of a new technique

Andre Ignee, Yi Dong, Gudrun Schuessler, Ulrich Baum¹, Christoph F. Dietrich

Medical Department 2, Caritas-Krankenhaus Bad Mergentheim, ¹Department of Radiology, Caritas-Krankenhaus Bad Mergentheim, Germany

ABSTRACT

Background: Fusion imaging is an accepted method in abdominal imaging allowing a simultaneous display of reference imaging with a live ultrasound (US) investigation. For prostate cancer, promising results have been published for endorectal US (ERUS)-guided biopsy of suspicious lesions in magnetic resonance imaging (MRI). To our knowledge, no other indication for the fusion of ERUS with MRI has been reported so far. **Methods:** We report on three patients scheduled for ERUS due to anorectal fistulae after treatment ($n = 2$) or rectal carcinoma ($n = 1$), which were scheduled for real-time virtual sonography (RVS), a method for the fusion of MRI imaging with US. **Results:** In all patients, RVS was successful. The course of the fistulae could be defined and the success of the treatment could be confirmed. In the patient with rectal carcinoma, the lymph nodes suspicious in MRI could be identified. **Conclusions:** MRI/ERUS fusion has the potential for follow-up of anorectal fistulae and abscesses, and staging of anal and rectal tumors.

Key words: Biopsy, endorectal, fusion imaging, magnetic resonance imaging, ultrasound

INTRODUCTION

Real-time virtual sonography (RVS) is a navigation tool that merges the corresponding computed tomography (CT) or magnetic resonance imaging (MRI) volume data with a live ultrasound (US) examination and allows for high spatial resolution and real-time imaging. The technique has been first described in 2004.^[1]

All investigators performing imaging will consider all available data from the former investigations. In the case of focal findings, further investigations are performed:

To perform follow-up

- To characterize lesions if it was not sufficiently possible in the previous method
- To perform an intervention.

Cognitive fusion (in the investigator's mind) is always performed since the former investigation (the reference method) is recognized, and the current method is planned and controlled relying on this information.

This is an open access article distributed under the terms of the Creative Commons Attribution-NonCommercial-ShareAlike 3.0 License, which allows others to remix, tweak, and build upon the work non-commercially, as long as the author is credited and the new creations are licensed under the identical terms.

For reprints contact: reprints@medknow.com

How to cite this article: Ignee A, Dong Y, Schuessler G, Baum U, Dietrich CF. Endorectal fusion imaging: A description of a new technique. *Endosc Ultrasound* 2017;6:241-4.

Access this article online

Quick Response Code:



Website:

www.eusjournal.com

DOI:

10.4103/2303-9027.209868

Address for correspondence

Dr. Christoph F. Dietrich, Medical Department 2, Caritas-Krankenhaus Bad Mergentheim, Germany. E-mail: christoph.dietrich@ckbm.de

Received: 2016-03-20; **Accepted:** 2016-06-11

Technical fusion using RVS theoretically enables higher reliability displaying the reference and current method simultaneously. Forensic considerations could be taken into account.

Endorectal or endoanal US (ERUS) is used in anorectal diseases such as staging of rectal carcinoma,^[2] evaluation of fistula^[3] as well as in the evaluation of the anal sphincter in patients with incontinence^[4,5] and other diseases of the female and male genital tract.^[6-8] Fusion imaging of suspicious prostate lesions on MRI then biopsied under ERUS guidance is currently the only reported application of ERUS fusion.^[9] Comparison of cognitive fusion with technical fusion has been shown to be useful; direct comparative studies provide conflicting results in only few patients. Specialists believe cognitive fusion to be equivalent with technical fusion in expert hands, but consider the latter to be beneficial for general urologists.^[10,11]

MRI-US fusion-targeted biopsy was able to detect some clinically significant cancers that would have been missed using only standard biopsy. Using this method, the investigators were able to detect more clinically the significant disease than visually targeted biopsy in the only study reporting on this outcome (20.3% vs. 15.1%).^[12]

We report on the first application of fusion imaging for anorectal diseases with ERUS using MRI as the reference method [Figure 1].

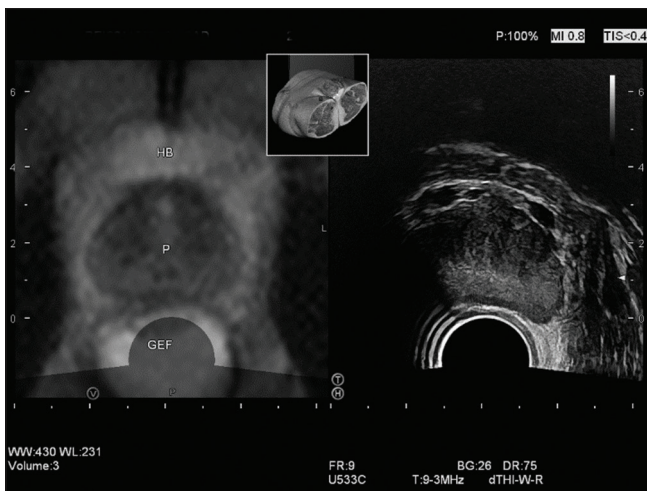


Figure 1. Fusion of pelvic imaging using magnetic resonance imaging and endorectal ultrasound. The prostate gland was displayed transversally, in contrast to magnetic resonance imaging, identical rectal filling was not possible; P: Prostate; HB: Urine bladder; RW: Rectal wall

MATERIALS AND METHODS

Three consecutive patients with inflammatory bowel disease suffering from anorectal fistula and a patient with rectal carcinoma were analyzed for RVS. The patients gave informed consent to participate in the approved study. Before launching the study, Institutional Review Board approval was obtained.

The first patient (male, 28-year-old) had anorectal fistula due to Crohn's disease and was investigated using MRI prior to surgical intervention. RVS was performed after Seton therapy [Figure 2]. In this image, the advantage of MRI concerning overview can be seen. The high focal resolution of ERUS displays the inner structure of the rectal wall. The second patient (female, 31-year-old) had Crohn's disease as well as a complex fistula system after surgical therapy. This patient had MRI before and after surgical therapy, the postinterventional imaging was chosen for fusion. The third patient (female, 65-year-old) had colorectal carcinoma prior to therapy. Staging MRI had been performed 2 days before RVS and showed a tumor with complete mural invasion as well as suspicious peritumoral lymph nodes.

ERUS was performed as usual after an enema. A Hitachi HI VISION Ascendus platform with the EUP-U533 transrectal transducer enabling transversal and sagittal sections was used, a magnetic sensor attached to the transducer to detect the position and motion of the probe during real-time scanning. A magnetic field generator was placed in close proximity to the area of examination.

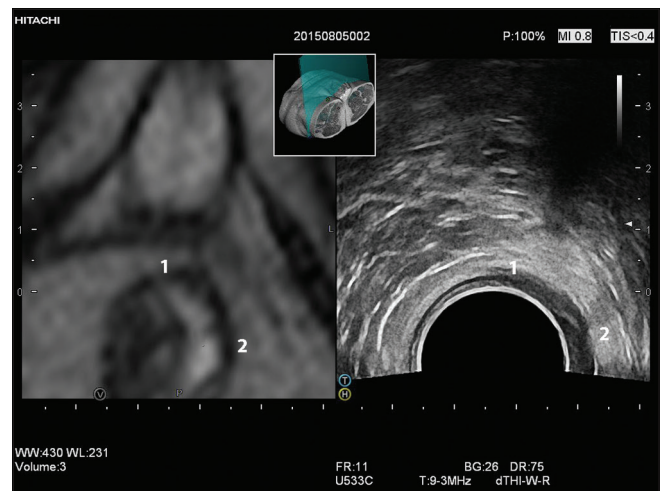


Figure 2. Fusion of magnetic resonance imaging and endorectal ultrasound in a patient with anal fistula. Corresponding points are marked at the 12 and 3 h position (1 and 2, respectively)

The reference method images were transferred as DICOM volume dataset. A selected plane from the virtual dataset was registered with the same anatomical plane in the real-time US using anatomical markers. Typically, both methods were correlated using one plane and two reference points rather than three reference points, which is also possible.

RESULTS

In all patients, RVS correlation could be acquired (technical success rate of 100%). A sagittal median plane demonstrating the internal orifice of the urethra proved to be sufficient as the starting reference point in all patients. Due to the limited number of patients, further reference points were chosen on an individual basis and could not be statistically analyzed. To align the plane of US with that of MRI, many planes were tested until the most suitable plane was chosen, taking into account the amount of rectal filling and the placement of a balloon. The procedure took 5–10 min.

In patients with anorectal fistula, demonstration of successful therapy as well as comparison of the former fistula courses were possible. In all patients, there were significant improvements. Abscesses could be excluded.

In patients with rectal carcinoma, we could compare suspicious lymph nodes on MRI, potentially enabling the investigator to perform endorectal biopsy.

CONCLUSIONS

Real-time fusion imaging has not been widely implemented in the daily routine until now, but several applications can be found in literature. It is currently used in radiofrequency ablation of hepatocellular carcinomas and of renal cell carcinoma,^[13] as well as in the diagnosis of breast cancer^[14] and for targeting the biopsy of prostate gland lesions.^[15] MRI as well as CT can be used. MRI/ERUS fusion in anorectal diseases has not been described so far. Challenges of RVS cover fusion prerequisites, the patients' position, rectal filling, and the influence of the ERUS probe.

Considering the orientation, it must be taken into account that US delivers no overview in the pelvis. The sagittal plane is helpful as a starting plane since it reveals the best overview. Any shift of anatomical landmarks can be detected more easily and thus can be avoided in this plane.

In addition, the fusion landmarks play an important role. Only relatively coarse landmarks are needed which can be defined accurately without disturbance. Such landmarks for “conventional” abdominal fusion can be well-defined retroperitoneal structures, for example, sections of the celiac trunk or the bifurcation of the aorta. Those structures should be found close to the actual region of interest. For prostate lesions, the internal orifice of the urethra is typically chosen. Other landmarks are more difficult to standardize.

The supine position used in MRI and the so-called Sim's position or left lateral position with angulated hip and knee in ERUS are prone to anatomical differences. The different positions may cause changes in the anorectal and rectosigmoidal angulus implying fusion problems. Filling of the rectum is standard in MRI, but it is not consequently used in ERUS, and due to the movement of the probe in the anal canal, it is not possible in a standardized manner. The same is true for excessive balloon filling.

The influences on the complex structures of the pelvis have been investigated. The prostate, on the other hand, is a near spherical gland with a relatively constant position in the pelvis. We could demonstrate that several maneuvers of the probe in the rectum influence on the topographic relation of the rectal wall and perirectal structures.

Perspectives

We have described our experience of possible applications of RVS using an anorectal approach. In the majority of patients in clinical practice, in comparison to the regular ERUS, this method is time-consuming and not necessary. However, in selected cases, the benefits can be weighed against the effort required by the method. For example, for patients in whom the correct interpretation is crucial for determination of additional therapy, we find the potential effort to be acceptable.

Promising indications are as follows:

- Follow-up of anorectal fistulae and abscess fusion, especially if the course has been difficult to define after therapy
- Staging of anal and rectal tumors can be promising, since ERUS and MRI cover different advantages, the former for low and the latter for high T-stages. Suspicious but inconclusive lymph nodes in MRI can be targeted and biopsied using ERUS.

Challenges are anatomical alterations during investigations that lead to differences in imaging. These occur during positioning, rectal filling, and the influence of the probe.

Financial support and sponsorship

Nil.

Conflicts of interest

There are no conflicts of interest.

REFERENCES

- Iwasaki T, Mitake E, Shimosegawa T. Real-time virtual sonography: A novel navigation tool in percutaneous radiofrequency ablation of hepatocellular carcinomas (abstract). In: Radiological Society of North America Scientific Assembly and Annual Meeting Program. Oak Brook, IL: Radiological Society of North America; 2004.
- Pox C, Aretz S, Bischoff SC, et al. S3-guideline colorectal cancer version 1.0. *Z Gastroenterol* 2013;51:753-854.
- Sneider EB, Maykel JA. Anal abscess and fistula. *Gastroenterol Clin North Am* 2013;42:773-84.
- Allgayer H, Ignee A, Zipse S, et al. Endorectal ultrasound and real-time elastography in patients with fecal incontinence following anorectal surgery: A prospective comparison evaluating short- and long-term outcomes in irradiated and non-irradiated patients. *Z Gastroenterol* 2012;50:1281-6.
- Allgayer H, Ignee A, Dietrich CF. Endosonographic elastography of the anal sphincter in patients with fecal incontinence. *Scand J Gastroenterol* 2010;45:30-8.
- García-Montes MJ, Argüelles-Arias F, Jiménez-Contreras S, et al. Should anorectal ultrasonography be included as a diagnostic tool for chronic anal pain? *Rev Esp Enferm Dig* 2010;102:7-14.
- Delpy R, Barthet M, Gasmi M, et al. Value of endorectal ultrasonography for diagnosing rectovaginal septal endometriosis infiltrating the rectum. *Endoscopy* 2005;37:357-61.
- Giovannini M, Bardou VJ, Barclay R, et al. Anal carcinoma: Prognostic value of endorectal ultrasound (ERUS). Results of a prospective multicenter study. *Endoscopy* 2001;33:231-6.
- Durmus T, Stephan C, Grigoryev M, et al. Detection of prostate cancer by real-time MR/ultrasound fusion-guided biopsy: 3T MRI and state of the art sonography. *Rofo* 2013;185:428-33.
- Sonn GA, Margolis DJ, Marks LS. Target detection: Magnetic resonance imaging-ultrasound fusion-guided prostate biopsy. *Urol Oncol* 2014;32:903-11.
- Vourganti S, Rastinehad A, Yerram NK, et al. Multiparametric magnetic resonance imaging and ultrasound fusion biopsy detect prostate cancer in patients with prior negative transrectal ultrasound biopsies. *J Urol* 2012;188:2152-7.
- Valerio M, Donaldson I, Emberton M, et al. Detection of clinically significant prostate cancer using magnetic resonance imaging-ultrasound fusion targeted biopsy: A systematic review. *Eur Urol* 2015;68:8-19.
- Ukimura O, Mitterberger M, Okihara K, et al. Real-time virtual ultrasonographic radiofrequency ablation of renal cell carcinoma. *BJU Int* 2008;101:707-11.
- Nakano S, Yoshida M, Fujii K, et al. Fusion of MRI and sonography image for breast cancer evaluation using real-time virtual sonography with magnetic navigation: First experience. *Jpn J Clin Oncol* 2009;39:552-9.
- Brock M, Löttenberg B, Roghmann F, et al. Impact of real-time elastography on magnetic resonance imaging/ultrasound fusion guided biopsy in patients with prior negative prostate biopsies. *J Urol* 2015;193:1191-7.