



Suprameatal extension of retrosigmoid approach for microvascular decompression of trigeminal nerve: Case report



Juan Carlos Moreira-Holguin*, Rogelio Revuelta-Gutierrez, Alejandro Monroy-Sosa, Samuel Almeida-Navarro

Neurosurgery Service, Instituto Nacional de Neurología y Neurocirugía "Manuel Velasco Suárez", Mexico

ARTICLE INFO

Article history:

Received 16 March 2015
Received in revised form 9 August 2015
Accepted 9 August 2015
Available online 13 August 2015

Keywords:

Retrosigmoid approach
Suprameatal extension
Trigeminal neuralgia

ABSTRACT

INTRODUCTION: Trigeminal neuralgia is produced in a significant number of cases by vascular compression at the level of cisternal segment of the nerve at the entry of the pons. It is common to find superior cerebellar artery (SCA) responsible for this compression. The retrosigmoid approach (RA), with asterional craniectomy, clearly exposes the cisternal portion of the trigeminal nerve (TN).

PRESENTATION OF CASE: We describe in this case report how vessels at the trigeminal pore level known as "Meckel's segment" can compress the TN. This situation is unusual. One of the reasons why the compression of this Meckel's segment level could be overlooked is a suprameatal tubercle (ST) prominence that would prevent trigeminal pore visualization through retrosigmoid approach.

DISCUSSION: The suprameatal extension of this approach has been described for other purposes, especially in tumors invading Meckel's cave resection. We could not find publications for the use of the resection of the suprameatal tubercle in the retrosigmoid approach for microvascular decompression of the trigeminal neuralgia.

CONCLUSION: Microvascular decompression of the TN is an effective treatment for trigeminal neuralgia, however in some cases, in which vascular compression is not evident when exploring the cerebellopontine angle, it is important to note that association of a prominent ST can hide a vascular compression of the nerve in this region.

© 2015 The Authors. Published by Elsevier Ltd. on behalf of Surgical Associates Ltd. This is an open access article under the CC BY-NC-ND license (<http://creativecommons.org/licenses/by-nc-nd/4.0/>).

1. Introduction

Based on the hypothesis that vascular compression is the cause of most primary TN [1], the microvascular decompression has been widely accepted as a reliable method for the treatment of trigeminal neuralgia [2]. Even atypical clinical cases of TN can benefit from microvascular decompression [2,3].

It is very important to consider the intraoperative findings. The existence of a strong root compression correlates with a high cure rate [4,5]. A slight compression or the presence of arachnoiditis have a negative prognosis in pain control [2].

Sometimes, it is not possible to observe the closeness of vascular structures with the cisternal segment of the trigeminal root, especially when MRI studies are not the most optimal [6,7].

However, exploration of the neurosurgical cisternal portion of the TN can demonstrate vascular compression in most cases [8]. Therefore it is of utmost importance to observe all the cisternal

extension of the trigeminal nerve without causing tractions to adjacent structures.

Afterwards, we reported a case where a prominent ST prevented cisternal observation of the TN's whole extension, so the suprameatal extension of retrosigmoid approach (SERA) allowed a cisternal adequate vascular scan and find the nerves' compression.

2. Clinical case

Forty two aged female, resident of Mexico City, professional psychologist, with family history of systemic arterial hypertension and breast cancer. The patient has a history of arterial hypertension with three years diagnosis, controlled with 50 mg/day of losartan. Her condition began four years ago with left facial pain, sudden onset of severe intensity in the left trigeminal maxillary branch territory. The painful crisis lasted a few seconds and was repeated with a frequency of about once a month to three or more times per week in recent months. She was treated with carbamazepine without success, and then with gabapentin, amitriptyline and phenytoin. An MRI (1.5T) was performed with special emphasis on the posterior fossa which did not show a vascular compression at the cisternal segment level of the left TN. We proposed the patient to undergo

* Corresponding author at: Instituto Nacional de Neurología y Neurocirugía "Manuel Velasco Suárez", Neurosurgery Service, Av. Insurgentes Sur No. 3877. Col. La Fama, Del. Tlalpan, Tel. 5606 3822. Ciudad de México, Distrito Federal. México.

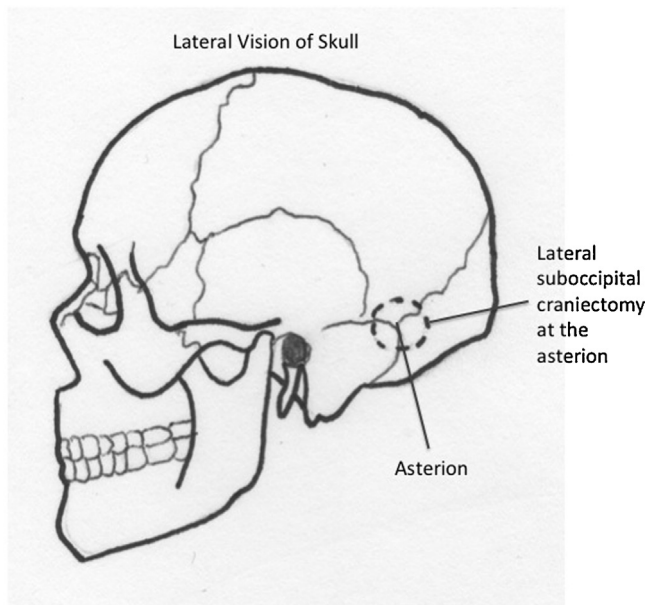


Fig. 1. Asterional diagram where craniectomy approach to the retrosigmoid shown.

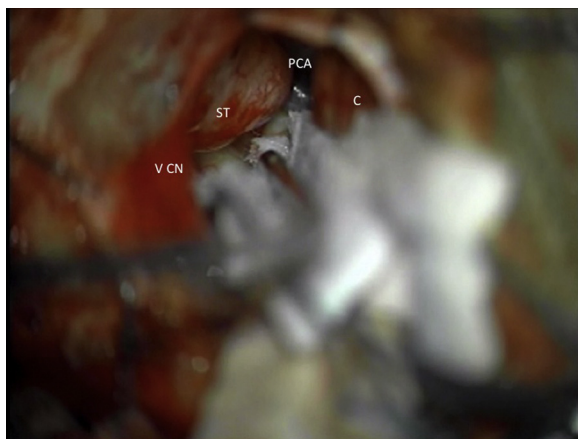


Fig. 2. Intraoperative picture with the surgical microscope at the level of the left cerebellopontine angle (CPA), where a prominent suprameatal tubercle (ST) is observed at the level of the posterior surface of the rock. Cerebellum (C).

a surgical exploration of the cisternal segment of nerve, through retrosigmoid approach, see Fig. 1.

During the exploration of cerebellopontine angle, no vascular compression was found in the entrance to the TN pons and cisternal segment level. However, a prominent ST prevented proper observation of all the cisternal segment of the trigeminal nerve, see Fig. 2. It was decided to drill the ST, see Fig. 3. Once the drill was performed and the ST was removed, Meckel's segment of the trigeminal nerve was found. The vascular compression of the nerve was observed in such segment caused by a branch of the superior cerebellar artery located behind the trigeminal pore, see Fig. 4. The vessel was cautiously separated from the nerve and placed a piece of Teflon® between them, see Fig. 5.

Reconstruction of the bone defect when removing the ST was performed with fat obtained from the abdominal wall of the patient and we further added 3 ml of fibrinogen concentrate, trying carefully not to spill it into the subarachnoid space, to prevent cerebrospinal fluid leakage, see Fig. 6.

The patient did not present facial pain crisis after surgery, however, developed a transnasal cerebrospinal fluid leakage on the

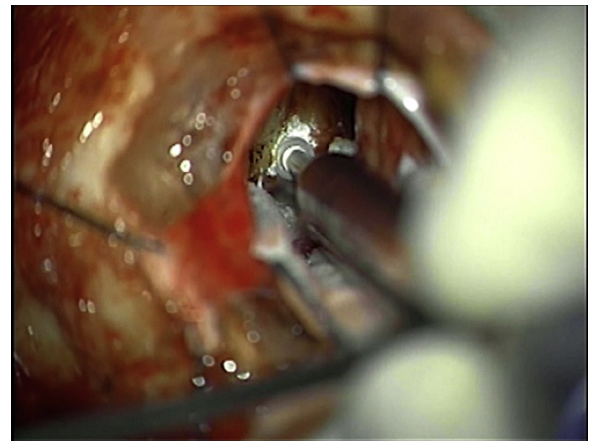


Fig. 3. Intraoperative picture with the surgical microscope, where the removal of the suprameatal tubercle.

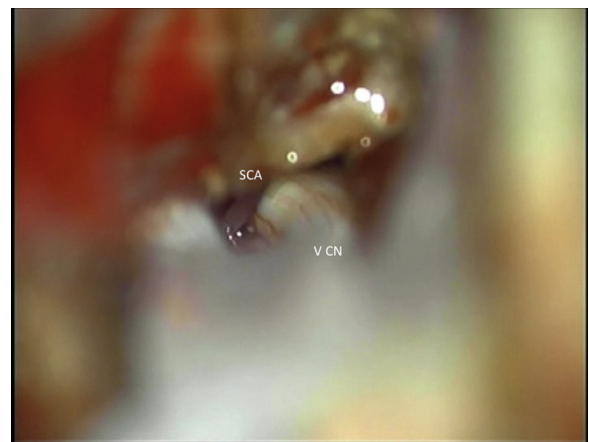


Fig. 4. Intraoperative picture with the surgical microscope, where it already has resected the suprameatal tubercle—Suprameatal extension of retrosigmoidoideo approach; here the vascular compression of the trigeminal nerve (CN V) is observed Meckel's level segment. The vessel that is committed is a branch of the superior cerebellar artery (SCA).

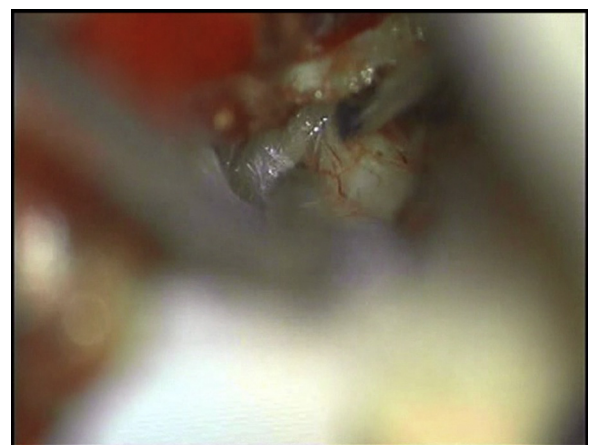


Fig. 5. Intraoperative picture with the surgical microscope, where as a piece of Teflon® between the trigeminal nerve and the vessel is placed.

second day, which we attributed to the removal of ST. It was decided to place a subarachnoid drainage for five days. The patient no longer developed posterior fistula with this handling. At this time, after a two year follow-up the patient, she has not presented painful crisis.

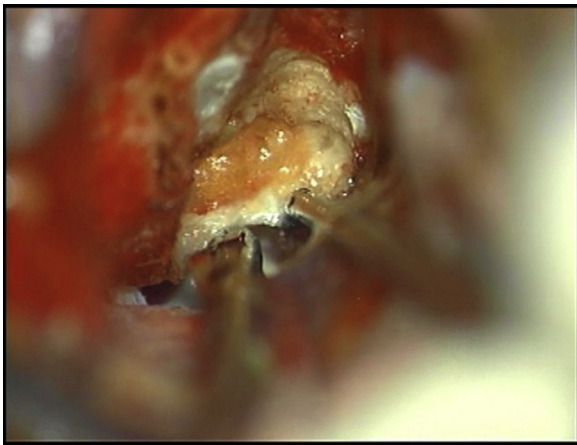


Fig. 6. Intraoperative surgical microscope photo with, where subsequent reconstruction of a bone defect removal suprameatal tubercle shown.

3. Discussion

The portion of the nerve located before the trigeminal ganglion is called “posterior trigeminal portion”, which has a cisternal segment passing through the subarachnoid space and a second segment which extends from the trigeminal pore Meckel’s cave to the lateral edge of the trigeminal ganglion, called “Meckel’s segment” [9],

see Fig. 7. In this case, the Meckel’s segment where the vessel was found is unusual.

As we know, all the cisternal segments of the trigeminal nerve are located in the upper part of the neurovascular complex, described by Rothon [10], so it is important to perform a delicate exploration, avoiding traction, trying to fully observe the TN.

The indication to explore this patient without concrete evidence can be criticized, however, it is feasible that in the case of trigeminal neuralgia refractory to medical treatment can be subject to surgery to explore cisternal TN [11,12].

Dandy and Jannetta proposed that trigeminal neuralgia is often associated with vascular compression of the SCA and it is less frequent in the anterior inferior cerebellar artery. In our case, there was a compression of the SCA. Arterial compression is more common in the – 84% of cases –, with respect to the venous compression – 14% – [13], and although occasionally larger vessels cannot be involved, the arterial source compression is characteristic. In rare cases there may be a vascular contact, without any distortion of the TN, which was reported widely by Jannetta [14].

Rothon reported that TN compression by SCA usually occurs close to the sensory root with the pons [10]. This is something that did not happen in the case reported as nerve compression, it occurred in proximity to the trigeminal pore.

This rare vascular location contact associated with a prominent tubercle, can cause a malfunction of the exploration of cisternal TN. Although we have not found reports in the literature of this difficulty, it is important to consider the drill of prominent ST that increases the exposure of the TN cisternal [15].

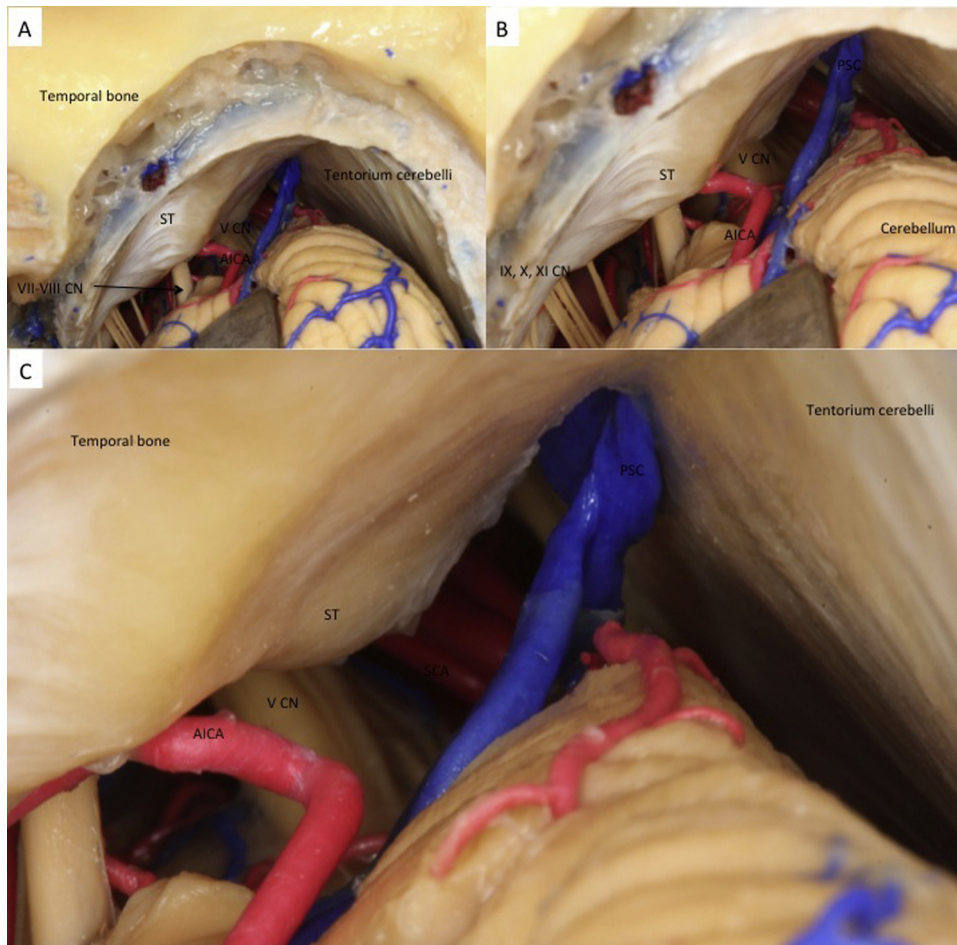


Fig. 7. Anatomical pictures of cerebellopontine angle (A–C) where the cerebellopontine angle is shown with the vestibulocochlear complex–facial (CN VII–VIII), the anterior inferior cerebellar artery (AICA), superior cerebellar artery (SCA), cranial nerves (V, VIII–VII, IX–X–XI CN), suprameatal tubercle (ST), tentorium, temporal bone and cerebellum. From the collection of Dr. Alejandro Monroy.

Seone and Rhoton reported an increase in TN exposure in 10.3 mm with a range between 8 and 13 mm [16], and Chanda and Nanda reported an increase of 10.7 mm with a range between 9 and 13 mm, when drilling the suprameatal tubercle, which is called SERA [17]. The ST drilled is comparable with the drilling of the Kawase's triangle [18]. Sammi et al. were the first to describe the technique and the results of the suprameatal extension when treating petroclival tumors invading the middle fossa, especially in the case of petroclival meningiomas and trigeminal schwannomas [19].

A common cross represents structures which is made up by the superior semicircular canal and the posterior semicircular canal which are at risk when ST removal is performed, injuring the labyrinth. It is estimated that the angulation of 60° drilling is sure to prevent this damage, however it does not allow complete exposure [15].

Prominent ST can block access to: the lateral margin cisternal trigeminal nerve, the trigeminal pore, and the top of the petroclival region. Their removal increases in short space of this region and improves visualization of the upper neurovascular complex. The suprameatal extension of this approach has been described for other purposes, especially in the resection of tumors invading the Meckel's cave, as noted.

4. Conclusion

The exploration of the cisternal segment of the TN, in trigeminal neuralgia, must be performed safely, trying to be established with regard to the pursuit of vascular compression. It is not uncommon to find some prominent STs, however, it has not caused an obstacle when we found the vascular compression near the entrance to the pons TN, but in this case, when the compression was near the trigeminal pore, the prominence of the TC meant an obstacle for the surgeon's view.

It is important to know the ability in the drilling of the ST to avoid causing traction of neuronal elements and vascular structures in an effort to achieve optimal exploration. It is also important to make a correct reconstruction of the bone defect, to avoid the production of a CSF leak.

Conflict of interest

Any authors have conflicts of interest.

Funding

Study funding is personal.

Ethical approval

The name of the ethics committee is "collegial session neurosurgery", with number 212345, of the Neurology and Neurosurgery National Institute.

Consent

Written informed consent was obtained from the patient for publication of this case report and accompanying images. A copy of the written consent is available for review by the Editor-in-Chief of this journal on request.

Open Access

This article is published Open Access at sciedirect.com. It is distributed under the [IJSCR Supplemental terms and conditions](#), which permits unrestricted non commercial use, distribution, and reproduction in any medium, provided the original authors and source are credited.

Author contributions

Moreira-Holguín Juan Carlos: data collection and writing the paper.

Revuelta-Gutierrez Rogelio: concept of paper and interpretation.

Almeida-Navarro José: traducing.

Monroy-Sosa Alejandro: graphic and photos; concept of paper.

Guarantor

Moreira-Holguín Juan Carlos.

References

- [1] P.J. Jannetta, Arterial compression of the trigeminal nerve at the pons in patients with trigeminal neuralgia, *J. Neurosurg.* 26 (1967) 159–162.
- [2] M. Sindou, J. Leston, E. Decullier, et al., Microvascular decompression for primary trigeminal neuralgia: long-term effectiveness and prognostic factors in a series of 362 consecutive patients with clear-cut neurovascular of 362 consecutive patients with clear-cut neurovascular conflicts who underwent pure decompression, *J. Neurosurg.* 107 (6) (2007) 1144–1153.
- [3] M. Sindou, J. Leston, E. Decullier, F. Chapuis, Micro-vascular decompression for primary trigeminal neuralgia (typical or atypical). Long-term effectiveness on pain; prospective study with survival analysis in a consecutive series of 362 patients, *Acta Neurochir. (Wien)* 148 (2006) 1235–1245.
- [4] R. Revuelta-Gutierrez, M.A. López-González, J.L. Soto-Hernández, Surgical treatment of trigeminal neuralgia without vascular compression: 20 years experience, *Surg. Neurol.* 66 (2006) 32–36.
- [5] M.P. Sindou, M. Chiha, P. Mertens, Anatomical findings observed during microsurgical approaches of the cerebellopontine angle for vascular decompression in trigeminal neuralgia (350 cases), *Stereotact. Funct. Neurosurg.* 63 (1994) 203–207.
- [6] R. Revuelta-Gutierrez, J. Martínez-Anda, J. Barges, et al., Efficacy and safety of root compression of trigeminal nerve for trigeminal neuralgia without evidence of vascular compression, *World Neurosurg.* 80 (3–4) (2013) 385–389.
- [7] P.R. Leal, M. Hermier, M. Sindou, et al., Preoperative demonstration of the neurovascular compression characteristics with special emphasis on the degree of compression, using high-resolution magnetic resonance imaging: a prospective study, with comparison to surgical findings, in 100 consecutive patients who underwent microvascular decompression for trigeminal neuralgia, *Acta Neurochir. (Wien)* 152 (2010) 817–825.
- [8] M. Sindou, T. Howeidly, G. Acevedo, Anatomical observations during microvascular decompression for idiopathic trigeminal neuralgia. Prospective study in a series of 579 patients, *Acta Neurochir. (Wien)* 144 (2002) 1–13.
- [9] J. Diaz, K. Jordi, F. Takanori, et al., Microsurgical anatomy of the inner surface of the petrous bone: neuroradiological and morphometric analysis as an adjunct to the retrosigmoid transmeatal approach, *Neurosurgery* 34 (1994) 1003–1008.
- [10] A.L. Rhoton Jr., The cerebellopontine angle and posterior fossa cranial nerves by the retrosigmoid approach, *Neurosurgery* 53 (2003) 525–560.
- [11] B.E. Mostafa, M. Sharnoubi, A.M. Youssef, The keyhole retrosigmoid approach to the cerebello-pontine Angle: indications, technical modifications, and results, *Skull Base* 18 (2008) 371–376.
- [12] W.E. Dandy, Removal of cerebellopontine tumors through a unilateral approach, *Arch. Surg.* 29 (1934) 337–344.
- [13] S.J. Haines, P.J. Jannetta, Microvascular relations of the trigeminal nerve. An anatomical study with clinical correlation, *J. Neurosurg.* 42 (1980) 381–386.
- [14] P.J. Jannetta, Outcome after microvascular decompression for typical trigeminal neuralgia, hemifacial spasm, tinnitus, disabling positional vertigo, and glossopharyngeal neuralgia, *Clin. Neurosurg.* 44 (1996) 331–383.
- [15] P. Pillai, S. Sammet, M. Ammirati, et al., Image-guided, endoscopic-assisted drilling and exposure of the whole length of the internal auditory canal and its fundus with preservation of the integrity of the labyrinth using a retrosigmoid approach: a laboratory investigation, *Operat. Neurosurg.* 65 (2009) 53–59.
- [16] E. Seoane, A. Rhoton, Suprameatal extension of the retrosigmoid approach: microsurgical anatomy, *Neurosurgery* 44 (1999) 553–560.
- [17] A. Chanda, A. Nanda, Retrosigmoid intradural suprameatal approach: advantages and disadvantages from an anatomical perspective, *Operat. Neurosurg.* 59 (2006) 1–6.
- [18] S.W. Chang, A. Wu, P. Gore, et al., Quantitative comparison of Kawase's approach versus the retrosigmoid approach: implications for tumors involving both middle and posterior fossa, *Neurosurgery* 64 (2009) 44–51.
- [19] M. Sammi, M. Tatagiba, G. Carvalho, et al., Retrosigmoid intradural suprameatal approach to Meckel's cave and the middle fossa: surgical technique and outcome, *J. Neurosurg.* 92 (2000) 235–241.