

Case Report

Yanmei Zhu^{*#}, Li Chen[#], Jia He, Yan Chen, Haiyan Gou, Long Ma, Youyang Qu, Yu Liu, Di Wang, Yulan Zhu

Study of Seizure-Manifested Hartnup Disorder Case Induced by Novel Mutations in *SLC6A19*

<https://doi.org/10.1515/biol-2018-0003>

Received July 6, 2017; accepted January 8, 2018

Abstract: Aim. The aim of the study is to investigate a variation in the gene *SLC6A19* in a female patient with Hartnup disorder manifested only by seizure. Methods. DNA samples collected from the patient and her parents were analyzed and twelve exons of the *SLC6A19* gene were amplified and sequenced. Results. We found c.47C>T and c.1522G>A mutations in the gene *SLC6A19* belonging to the patient, which are missense mutations inherited from her parents. The c.47C>T mutation is from her father and c.1522G>A is inherited from her mother. The parents are both heterozygous healthy carriers. Conclusion. Two novel mutations of the *SLC6A19* gene are revealed in the female patient with Hartnup disorder, exhibiting no typical dermatologic problems, but having dramatic neurological symptoms.

Keywords: Hartnup disease; *SLC6A19* gene mutations; seizure

1 Introduction

Hartnup disorder is an autosomal-recessive disorder. The basic pathology of the disease is the dysfunction of the neutral amino acid transporter in the brush border membrane of the intestines and proximal tubules of the kidney [1]. The prominent clinical features of the disorder

include skin rash, cerebellar ataxia, and mental symptoms [2]. The causative gene was identified as *SLC6A19*, which is located on chromosome 5p15.33 [3]. *SLC6A19* encodes the amino acid transporter BOAT1, which transports a large amount of neutral amino acids [4].

Nearly 20 mutations in *SLC6A19*, have been previously reported [3,5-7]. Detailed information regarding these mutations is listed in table 1. Some mutations in exon 1, exon 6 and exon 12 may significantly affect the function of the transporter BOAT1 and result in evident clinical manifestations, while the others may result in the generation of an aminoaciduric urine without any symptoms [8].

Table 1. Mutations in *SLC6A19* associated with Hartnup disorder

mRNA	Exon	Origin	Reported year	Reference
IVS8+2T>G	IVS8	UK	1956	5
340delC	2	Japan	2001	6
682-683AC>TA	5	Japan	2001	6
C884-885delTG	6	Japan	2004	5
169C>T	1	Japan	2004	5
D173N	4	Australia	2004	6
R240X	5	Australia	2004	6
L242P	5	Australia	2004	6
E501K	10	Australia	2004	6
IVS8+ 2T > G	8	Australia	2004	6
IVS11+ 1G > A	11	Australia	2004	6
908C>T		Korean	2010	7
1787_1788insG		Korean	2010	7
850G>A	6	China	2016	3

The patient in this case demonstrated uncommon manifestations of this disease, which is mainly manifested by different types of seizures. This hindered a definite diagnosis, which was finally achieved by gene analysis. Two novel mutations of the *SLC6A19* gene of the female patient with Hartnup disorder were revealed. Clinical manifestations may also be modified by some environmental factors including nutrition. Nevertheless, the nutrition of this patient was normal.

***Corresponding author: Yanmei Zhu**, Department of Neurology, Second Affiliated Hospital of Harbin Medical University, Harbin, China, E-mail: zhuyanmei_maggie@163.com

Li Chen, Jia He, Yan Chen, Haiyan Gou, Youyang Qu, Yu Liu, Di Wang, Yulan Zhu, Department of Neurology, Second Affiliated Hospital of Harbin Medical University, Harbin, China

Long Ma, Second Department of Internal Medicine, Second Hospital of Heilongjiang Province, Harbin, China

[#]equal contribution

2 Data and methods

2.1 Case Study

The patient is a 16-year-old girl of non-consanguineous parents. She was admitted to hospital with 11 years of history of seizure attacks, accompanied with polycystic ovarian syndrome. The patient experienced frequent episodes of seizures of different types, which included generalized tonic-clonic seizures and complex partial ones. There was no positive sign in the neurologic examination.

In the first ten years of the course of the disease, the patient had infrequent episodes of involuntary jerking movements in the upper and lower limbs, accompanied with the loss of consciousness. Both eyeballs rotated upwards and the patient's jaw was tightly locked. The bilateral upper limbs were flexed and the lower limbs were stretched. Each attack continued for about one or two minutes. Later the patient was unable to recollect anything about the seizure episode. During the episodes, the patient used to bite her tongue and had several instances of urinary incontinence. These types of attacks can be defined as generalized tonic-clonic seizures, which occurred once or twice per year.

The patient began to take valproic acid as the anticonvulsant drug since 2012. Her weight increased gradually and the pattern of her menstruation became irregular. It is worth noting that the female patient under study had an abnormal amenorrhea for about one year and the level of testosterone in her serum was higher than normal. She also had hyperinsulinemia, with a polycystic change in her bilateral ovaries. Altogether, the patient was diagnosed with polycystic ovarian syndrome [9], which implies ovarian dysfunction with principal features of hyperandrogenism and polycystic ovary morphology [10]. A large number of studies conducted on this topic have suggested a possible role of anticonvulsants, particularly valproic acid, in the pathogenesis or risk factors associated with polycystic ovarian syndrome [11]. In view of this, the potential cause may be associated with the antiepileptic valproic acid, which had been taken by the patient for almost four years before admission to our hospital.

Since the spring of 2015, the patient had numerous attacks manifested by swinging of limbs with open eyes, hip twisting, and uncontrolled cries. Such attacks always occurred during sleep, and the frequency of the attacks increased up to several times per night. The patient maintained consciousness in the very beginning of the seizure. During the following period of the attack, the patient was unconscious until the end of seizures.

According to the specific features of the episodes, they can be classified as complex partial seizures.

Informed consent: Informed consent has been obtained from all individuals included in this study.

Ethical approval: The research related to human use has been complied with all the relevant national regulations, institutional policies and in accordance the tenets of the Helsinki Declaration, and has been approved by the institutional review board or equivalent committee.

2.2 Laboratory investigations

The qualitative analysis of protein in urine was positive (normal value: negative); the concentration of albumin in the blood of the patient was 30 g/L (normal range: 35-55 g/L).

The results of Serum biochemical examinations are tabulated in Table 2. The level of testosterone in serum was higher than normal and the patient had a hyperinsulinemia. Liver and kidney function was normal.

The patient intelligence score, ECG, and heart ultrasound readings were all normal with no abnormalities found in the MRI scan of the brain and pituitary body.

The EEG records displayed several short-term or "sharp" waves in the frontal and temporal lobes. During the monitoring period, the patient had numerous of attacks of the above-mentioned pattern, which might be symptoms of a complex partial seizure. All the attacks occurred during sleep. At the very beginning of the attack, several atypical "sharp" waves were observed in the left frontal lobe (red arrow), while after the attack, several long-term or "slow" waves appeared in the graph (Fig.1).

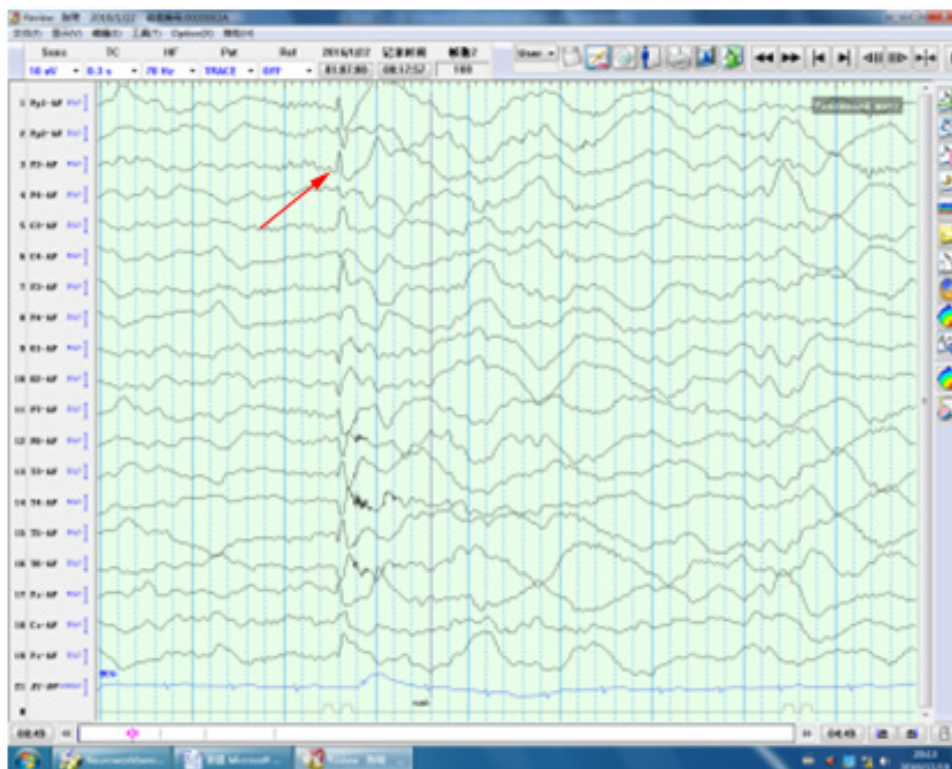
2.3 Mutation detection in the *SLC6A19* gene

The peripheral blood of the patient and her parents were obtained and DNA samples were isolated and amplified by polymerase chain reaction (PCR). Twelve pairs of primers were designed and 12 exons of the *SLC6A19* gene were amplified. The following primers were used to amplify exon 1, which includes 404-bp. The sense primer was 5'-CTGACGACTGGCTCCGTCTCT and the antisense primer was 5'-CTGCGTGTGTCTGTGCTTCC. The primers used to amplify exon 10, which contains 382-bp, were listed in the following. The sense primer was 5'-TACTGGCTCTCCCTGCTGGA and the antisense primer was 5'-CTCGAGCTCTGGCTCTCTGC. The PCR mixture was composed of Goldstar 12.5ul, ddH₂O 9.5ul, Primer 2ul,

Table 2. Results of Serum Biochemical Examination

Measured parameter and units	Time after taking 75 g glucose (min)	Measurement data	Reference range
Serum glucose, mmol/L	30	8.45	3.5-7.8
Serum glucose, mmol/L	60	8.12	3.5-7.8
Insulin, uU/ml	30	106.5	19-73
Insulin, uU/ml	60	113	8-68
Insulin, uU/ml	120	106.4	9-53
C peptide, ng/ml	30	9.6	3.1-8.2
C peptide, ng/ml	60	11.3	3.9-9.3
FSH, mIU/ml	N/A	5.05	25.8-134.8
LH, mIU/ml	N/A	12.83	7.7-58.5
E2, pmol/ L	N/A	171.7	18.4-201
PROG, nmol/L	N/A	1.68	0.3-2.5
PRL, mIU/L	N/A	379.3	102-494
TESTO, ng/ml	N/A	0.61	0.08-0.48
ALT, U/L	N/A	16	0-40
AST, U/L	N/A	34	0-40
Crea, umol/L	N/A	54	44-110
BUN, mmol/L	N/A	3.78	2.3-7.2
Alkaline phosphatase, U/L	N/A	84	35-150

Note: "N/A" – means "not applicable"

**Fig.1.** Screenshot of the EEG records of the female patient with Hartnup disorder

Template DNA 1ul in the total volume of 25µL. The cycling conditions were as follows: 95°C for 30s, 60°C for 30s, and 72°C for 45s for 35 cycles. The PCR products were sequenced by an ABI 3730 sequencer.

3 Results

Analysis of the PCR products from the patient has revealed c.47C>T and c.1522G>A mutations in the *SLC6A19* gene, which are missense mutations. The mutations result in the transformation of amino acid 16 from Pro to Leu and amino acid 508 from Val to Met. These mutations lead to an amino acid replacement of P16L and V508M in the transmembrane domain of *SLC6A19* (Figs. 2a and 3a). The patient's parents were heterozygous for these mutations. The data on the patient and her parents are illustrated by Figs. 2 and 3. The causative gene mutations in this patient with Hartnup disease, which is an autosomal recessive disorder, were separately inherited from her parents. The mutation of c.47C>T is from her father and c.1522G>A is from her mother. The parents are both heterozygous healthy carriers.

4 Discussion

The most common clinical features in patients with Hartnup disorder consist of pellagra-like rash, cerebellar ataxia and psychiatric signs. Among the manifestations mentioned above, skin rash is the most frequent symptom. It was reported that 28 of the 43 patients studied with Hartnup disorder manifest a rash [12]. Notably, in seven of the cases patients developed the rash as early as one year old. However, in the case under study, no rashes have been observed in the 16 years-old female patient until present.

The neurological damage of Hartnup disorder can vary and includes cerebellar ataxia, behavioral disorders, and mental retardation. In this case, the neurological examinations revealed no abnormality. The patient gait and emotions were stable, with no indication of any behavioral and mental disturbances.

As a rare symptom of such patients, seizure was reported only for a single patient in Korea in 2010 [8]. The patient, in this case, exhibited frequent attacks of seizures of different types, which included the generalized tonic-clonic and complex partial seizures.

The underlying pathogenesis for these seizures may be related to the abnormal metabolism of neutral amino acids. Failed uptake from the intestines and kidneys can lead to a decrease in the concentration of tryptophan,

which causes the lack of neurotransmitters such as serotonin. Furthermore, the bacterial degradation of tryptophan in the intestines can harm the nervous system. Altogether, these phenomena may cause the neurologic symptoms of Hartnup disorder. Alternatively, some patients with Hartnup disorder have structural abnormalities in the brain, which can provide a partial explanation for the seizures. For example, in the Korean patient reported in 2010, there was an abnormal peritrigonal T2 hyper intensity, with a volume loss and diffuse atrophy in the body and splenium of the corpus callosum, revealed by a magnetic resonance imaging of the brain[8].

In the present patient, two novel missense mutations, viz c.47C > T and c.1522G > A were found in the *SLC6A19* gene. These mutations result in the change of amino acid 16 from Pro to Leu and amino 508 from Val to Met. Although the precise function of these novel mutations was not well understood, we can imagine that the mutations might cause some abnormalities to the function of the proteins. The compound heterozygous mutations are found to be inherited, with each parent carrying one heterozygous mutation.

According to the reference sequence of the *SLC6A19* transporter molecule, the mutation which located in the transmembrane domain, can cause the dysfunction of the *SLC6A19* transporter, and then lead to the prominent amino aciduria, skin problems, and neurologic symptoms. While the mutation located outside the membrane can only partially affect the function of the transporter. The precise locations of the two novel mutations found in this case should be confirmed before the fundamental mechanisms are well understood. There are several medical strategies used to treat Hartnup disorder. For example, nicotinamide can be helpful to relieve skin problems. Tryptophan can improve neurologic injuries and neomycin can prevent the bacterial degradation of tryptophan in the intestines [13]. To cease seizure attacks, lamotrigine and levetiracetam were administered to the patient. Since the described medications failed to provide the expected improvement of patient health, a niacinamide therapy is presently prescribed.

Neutral amino aciduria is another diagnostic feature of Hartnup disorder, which is caused by the absorption disturbance of multiple neutral amino acids in the proximal tubules of the kidney. The concentration of protein in urine was higher than normal, while that of albumin in the blood was lower than normal, which can be an indirect indication of the increased urinary excretion of the neutral amino acids. However, the respective measurements of urinary amino acids, which

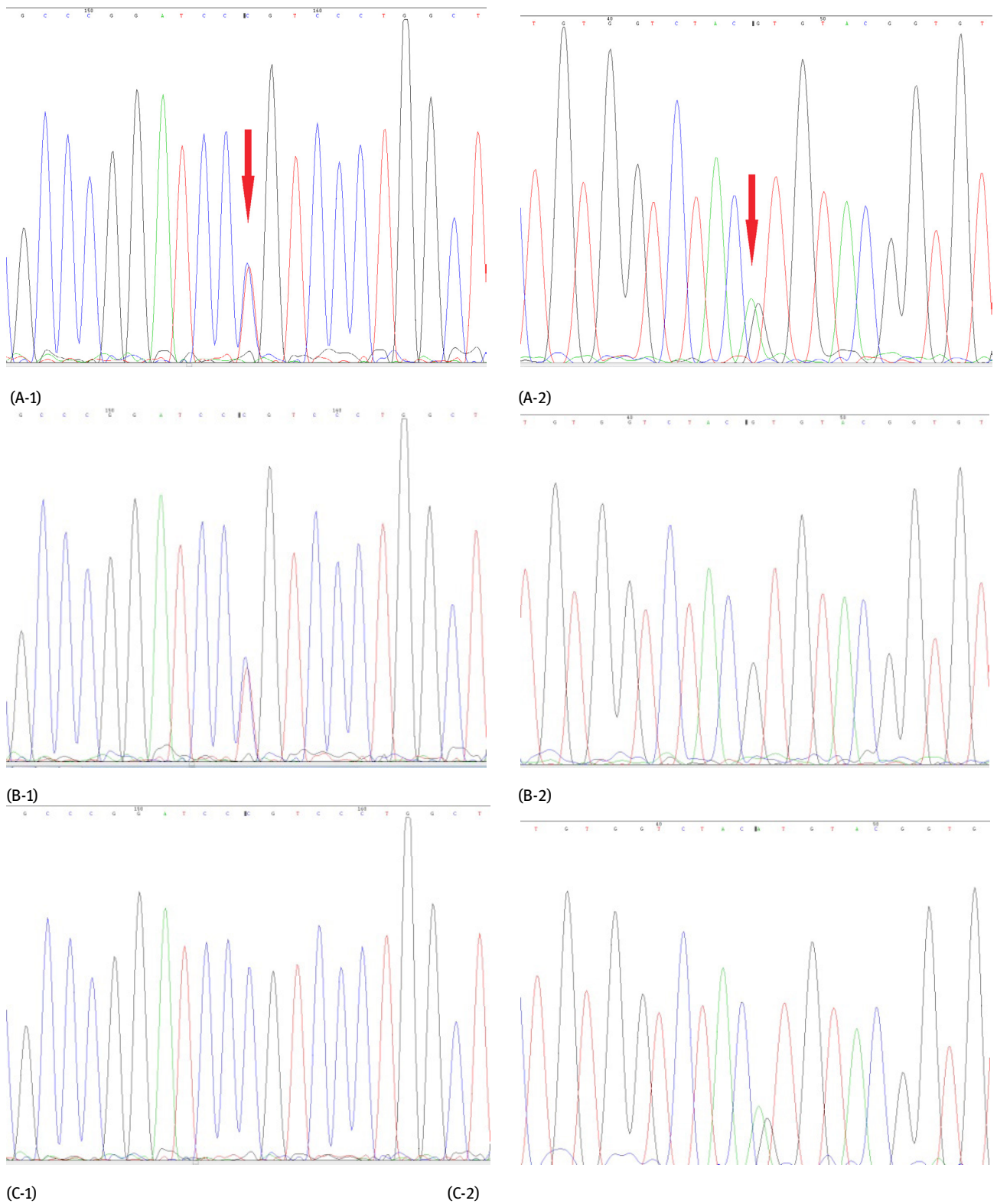


Fig.2. Family pedigree sequencing results of PCR products amplified from exon 1(-1) and 10(-2) of *SLC6A19* (the patient: A with red arrow; the father: B; the mother: C).

would support or disprove this hypothesis, have not yet been performed and are planned in the further study of this case.

This study has revealed a new case of Hartnup disorder, with seizure as the main symptom, which is an uncommon manifestation of this disease. Thus, whenever we encounter a patient with an unexplained seizure, Hartnup disorder should be considered as a differential diagnosis. In view of its phenotypic heterogeneity and the importance of early intervention, gene analysis susceptible patients should be done as early as possible.

5 Conclusion

In this study, we reported a Chinese female patient with Hartnup disorder manifested by seizure. Two novel mutations in the patient were identified. This work is an important complement to improve the understanding of Seizure-Manifested Hartnup disorder.

ACKNOWLEDGMENTS: This study was funded by the Youth Natural Science Foundation of Heilongjiang Province (QC2013C110) and Doctor Science Foundation of the Second Affiliated Hospital of Harbin Medical University (BS2011-15).

Conflict of interest: Authors state no conflict of interest.

References

- [1] Azmanov DN., Kowalczyk S., Rodgers H., et al., Further evidence for allelic heterogeneity in Hartnup disorder, *J. Hum Mutat.*, 2008, 29, 1217-1221.
- [2] Orbak Z., Ertekin V., Selimoglu A., et al., Hartnup disease masked by kwashiorkor, *J. Health Popul Nutr.*, 2010, 28, 413-415.
- [3] Zheng Y., Zhou C., Huang Y., et al., A novel missense mutation in the *SLC6A19* gene in a Chinese family with Hartnup disorder, *J. Int J Dermatol*, 2009, 48, 388-392.
- [4] Bröer S., The role of the neutral amino acid transporter *BOAT1(SLC6A19)* in Hartnup disorder and protein nutrition, *J. IUBMB Life*, 2009, 61, 591-599.
- [5] Kleta R., Romeo E., Ristic Z., et al., Mutations in *SLC6A19*, encoding *BOAT1*, cause Hartnup disorder, *J. Nat Genet.*, 2004, 36, 999-1002.
- [6] Seow HF., Bröer S., Bröer A., et al., Hartnup disorder is caused by mutations in the gene encoding the neutral amino acid transporter *SLC6A19*, *J. Nat Genet.*, 2004, 36, 1003-1007.
- [7] Cheon CK., Lee BH., Ko JM., et al., Novel Mutation in *SLC6A19* Causing Late-Onset Seizures in Hartnup Disorder, *J. Pediatr Neurol.*, 2010, 42, 369-371.
- [8] Junichi N., Miwako D., Toshihiro O., et al., Homozygosity Mapping to Chromosome 5p15 of a Gene Responsible for Hartnup Disorder, *J. Biochem Bioph Res Co.*, 2001, 284, 255-260.
- [9] Ambroziak U1., Kuryłowicz A., Kępczyńska N., et al., Total testosterone to dihydrotestosterone ratio assessed by LC-MS/MS predicts a worse metabolic profile not only in PCOS patients, *Ginek Pol.*, 2017, 88, 5-8.
- [10] McIntyre RS., Mancini DA., Mccann S., et al., Valproate, bipolar disorder and polycystic ovarian syndrome, *Bipolar Dis.*, 2015, 5, 28-35.
- [11] Verrotti A., Mencaroni E., Cofini M., Valproic acid metabolism and its consequences on sexual functions, *Curr Drug Metab*, 2016, 17, 573-581.
- [12] Wilcken B., Yu JS., Brown DA., Natural history of Hartnup disease, *Arch Dis Child*, 1977, 52, 38-40.
- [13] Ciecieręga T., Dweikat I., Awar M., et al., Severe persistent unremitting dermatitis, chronic diarrhea and hypoalbuminemia in a child, Hartnup disease in setting of celiac disease, *BMC Pediatr.*, 2014, 14, 311.