

## ORIGINAL ARTICLE

# Chemotherapy with gemcitabine plus cisplatin in patients with advanced thymic squamous cell carcinoma: Evaluation of efficacy and toxicity

Yang Luo<sup>1</sup>, Jun-ling Li<sup>1</sup>, Lin Yang<sup>2</sup> & Wen Zhang<sup>1</sup>

<sup>1</sup> Department of Medical Oncology, Cancer Institute/Hospital, Peking Union Medical College & Chinese Academy of Medical Sciences, Beijing, China

<sup>2</sup> Department of Pathology, Cancer Institute/Hospital, Peking Union Medical College & Chinese Academy of Medical Sciences, Beijing, China

## Keywords

Cisplatin; gemcitabine; squamous cell carcinoma; thymic carcinoma.

## Correspondence

Jun-ling Li, Department of Medical Oncology, Cancer Institute/Hospital, Peking Union Medical College & Chinese Academy of Medical Sciences, 17 Panjiayuan Nanli, Chaoyang District, Beijing 100021, China.  
Tel.: +86 10 87788119  
Fax: +86 10 67734107  
Email: drlijunling@vip.163.com

Received: 22 May 2015;  
Accepted: 29 June 2015.

doi: 10.1111/1759-7714.12300

Thoracic Cancer 7 (2016) 167–172

## Abstract

**Background:** Squamous cell carcinoma of the thymus is a rare thymic epithelial neoplasm that tends to widely metastasize at initial presentation. Because of its rarity, the optimal chemotherapeutic regimen remains uncertain. A gemcitabine and cisplatin regimen has shown promising efficacy in the treatment of other squamous cell carcinomas. We assessed the efficacy and toxicity of this regimen in patients with advanced thymic squamous cell carcinoma.

**Methods:** Between January 2003 and December 2012, 13 patients with untreated or unresectable recurrent thymic squamous cell carcinomas, who were treated with gemcitabine and cisplatin, were retrospectively analyzed. The endpoints in this study were clinical response rate, disease control rate, progression-free survival, and overall survival. Significant hematological and non-hematological toxicities were also assessed.

**Results:** Three patients were in Masaoka stage IVa and 10 were in stage IVb. The median number of treatment cycles for the present chemotherapy regimen was four. The clinical response and disease control rates were 61.5% and 92.3%, respectively. The median progression-free and median overall survival rates were 14.5 months (95% confidence interval, 9.2–19.8 months) and 50.7 months (95% confidence interval, 24.9–76.5 months), respectively. Grade 3/4 hematological toxicities were observed in seven (53.8%) patients, and non-hematological toxicities were mild.

**Conclusion:** This retrospective analysis demonstrated that gemcitabine plus cisplatin was active against advanced thymic squamous cell carcinoma with manageable toxicity. Gemcitabine may be a novel and alternative agent for advanced thymic squamous cell carcinoma.

## Introduction

Thymic carcinoma is a rare thymic epithelial neoplasm with malignant cytologic features. According to the 2004 World Health Organization classification, the term “thymic carcinoma” was defined as all non-organotypic malignant epithelial neoplasms other than germ cell tumors, which could be further classified into 13 distinct histological subtypes.<sup>1</sup> Squamous cell carcinoma is the most common subtype, comprising more than 70% of all cases. It has an aggressive clinical course, tends to invade surrounding tissues, and metastasizes at an early stage.<sup>2–4</sup> Therefore, systemic chemotherapy is critically important in the treatment of this disease. However,

because this malignancy occurs infrequently, the optimal regimen has not been established. A few studies have reported promising results with anthracycline and cisplatin-based chemotherapies.<sup>5–7</sup> However, as anthracyclines are associated with severe myelosuppression and cardiac toxicity, investigation of less toxic non-anthracycline regimens is needed.

With this in mind, we selected the combination of gemcitabine and cisplatin (GP) because gemcitabine has a mechanism of action that differs from older agents and this combination has a relatively low toxic profile. In addition, GP has shown promising efficacy in the treatment of other squamous cell carcinomas.<sup>8–12</sup> The objective of this study was to retrospectively evaluate the efficacy and toxicity of the GP

combination as first-line chemotherapy against advanced thymic squamous cell carcinoma.

## Methods

### Patient population

Between January 2003 and December 2012, 13 patients with previously untreated or unresectable recurrent thymic squamous cell carcinomas were analyzed. Written informed consent was obtained from all patients.

The pathological diagnosis of thymic squamous cell carcinoma was established according to histopathological criteria proposed by 2004 World Health Organization histologic classification and a pathologist reviewed and confirmed the diagnoses of all squamous cell carcinomas for this study.<sup>1</sup> Histological samples were obtained by percutaneous computed tomography (CT)-guided biopsy, video-assisted thoracic surgery, cervical lymph node biopsy, or thymectomy. Patients' histologic materials were, subsequently, reviewed by the same pathologist. Pretreatment evaluations consisted of medical histories, physical examinations, complete blood cell counts, biochemical examinations, thoracic and abdominal CT scans, and bone scans. Clinical stage was assessed according to criteria proposed by Masaoka *et al.*: stage IVa, pleural or pericardial dissemination; stage IVb, lymphogenous or hematogenous metastases.<sup>13</sup> Performance status was assessed using Eastern Cooperative Oncology Group scales.

### Treatment

All patients were intravenously treated with a combination of gemcitabine (1000 mg/m<sup>2</sup>, days 1 and 8) and cisplatin (75 mg/m<sup>2</sup>, administered over 3 continuous days) every three weeks, for at least two cycles. Dose reductions and dose inter-

ruptions were allowed as a result of toxicity. All patients were evaluated radiographically every two chemotherapy cycles to confirm treatment effectiveness or disease progression.

### Evaluation of efficacy and study end points

The response to treatment was reassessed using Response Evaluation Criteria in Solid Tumors version 1.0. Overall survival (OS) was defined from the chemotherapy start date to death as a result of any cause. Progression-free survival (PFS) was defined from the chemotherapy start date to first documented progression or death. Patients without documented progression were censored at the time of last disease assessment.

### Safety profile

Hematological and non-hematological toxicities related to chemotherapy were graded according to Common Terminology Criteria for Adverse Events version 3.0.

### Statistical methods

Statistical analysis was performed using SPSS Version 19.0 (IBM Corp., Armonk, NY, USA). The Kaplan–Meier method was used to estimate median PFS, median OS, and one, three, and five-year survival rates.

## Results

### Patient characteristics

The characteristics of the 13 patients are summarized in Table 1. Seven patients were male, and six were female, with a median age of 53 years. The thymic lesions varied from

**Table 1** Clinical findings in 13 cases of thymic squamous cell carcinoma

Case	Age (year)/gender	Stage	Timing of CT	No. of cycles	Response	PFS (months)	Outcomes (months)
1	23/F	IVb	Untreated	4	PR	11.9	66.7, died
2	58/M	IVb	Untreated	4	SD	14.5	56.1, died
3	33/F	IVa	Untreated	5	PR	38.9	38.9, alive
4	60/F	IVb	Untreated	3	SD	45.7	63.4, alive
5	62/M	IVb	Untreated	4	PR	11.3	32.6, died
6	48/F	IVb	Untreated	8	PR	20.3	50.7, died
7	59/F	IVb	Untreated	8	PR	17.1	27.2, died
8	56/M	IVb	Untreated	4	SD	5.5	5.5, died of CHD
9	41/M	IVa	Recurrence	2	PD	1.8	9.8, died
10	46/M	IVb	Recurrence	4	PR	7.3	39.8, alive
11	59/M	IVb	Recurrence	4	PR	7.7	25.4, alive
12	37/F	IVa	Untreated	4	PR	20.7	21.9, alive
13	53/M	IVb	Recurrence	6	SD	8.0	26.2, alive

CHD, coronary heart disease; CT, chemotherapy; PD, progressive disease; PFS, progression-free survival; PR, partial response; SD, stable disease.

roughly 3.0–10.5 cm at their greatest dimension, with an average size of 5.9 cm. Symptoms at diagnosis were cough, chest pain, shortness of breath, chest discomfort, and fatigue. Four patients were asymptomatic. No cases of myasthenia gravis or other associated symptomatic paraneoplastic syndromes were observed. All patients showed a good performance status of 0 or 1. According to the Masaoka staging system, three patients were in stage IVa and 10 were in stage IVb. The metastatic sites, in sequence, were the lungs, pleura, lymph nodes (diaphragm and supraclavicular), bones, and liver. Nine patients were untreated; four had unresectable recurrent disease after prior surgery and radiotherapy, and two of these patients had received prior adjuvant chemotherapy (taxanes plus platinum regimen).

### Treatment efficacy

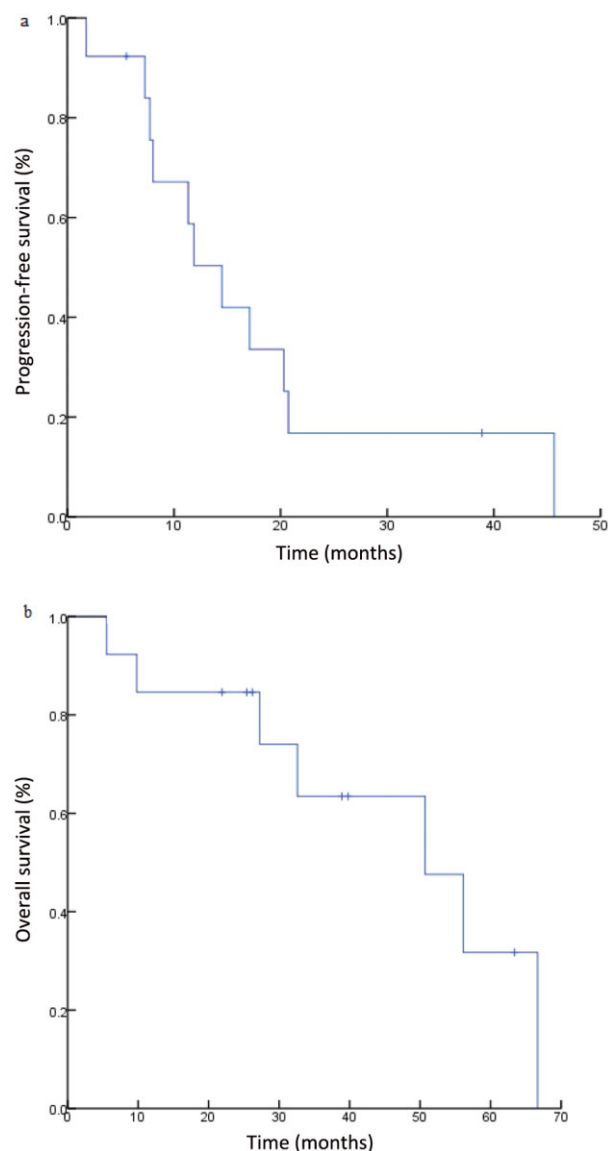
A total of 60 cycles were administered, with a median number of four cycles per patient. One patient had a dose reduction, while in another carboplatin was substituted for cisplatin as a result of Grade 3 vomiting.

There were no complete responders. Eight patients achieved a partial response, four patients had stable disease, and one had progressive disease (PD). The overall response rate (ORR) and disease control rate (DCR) were 61.5% and 92.3%, respectively. En bloc extended total thymectomy was performed in the three patients with stage IVa disease after chemotherapy. Thoracic radiotherapy was carried out before disease progression in six patients with a total dose of 50Gy–64Gy. Only one patient remained disease-free for 39 months. One patient died of coronary heart disease without tumor progression. The other 11 patients received second-line chemotherapy when their disease progressed, including seven patients who received further lines of chemotherapy. Chemotherapeutic drugs included carboplatin, paclitaxel, S-1, nedaplatin, irinotecan, nab-paclitaxel, docetaxel, and ifosfamide and bevacizumab, used alone or in combination.

Six patients died of the disease and one non-thymic carcinoma-related death was observed. The median PFS was 14.5 months (95% confidence interval [CI], 9.2–19.8 months) and the median OS was 50.7 months (95% CI, 24.9–76.5 months). The PFS and OS curves are shown in Figure 1. The one, three and five-year survival rates were 84.6%, 63.5%, and 31.7%, respectively.

### Safety profile

The main chemotherapy toxicities of the 13 patients are summarized in Table 2. The principal toxicity was hematological. Grade 4 thrombocytopenia and neutropenia were observed in one and two patients, respectively. None of the patients developed febrile neutropenia. Only one patient required



**Figure 1** (a) Progression-free survival curve for 13 patients with advanced thymic squamous cell carcinoma. (b) Overall survival curve for 13 patients with advanced thymic squamous cell carcinoma.

platelet transfusions. In addition, Grade 3 thrombocytopenia was observed in one patient, anemia in one, and neutropenia in four patients. Six patients required granulocyte colony stimulating factor support. Non-hematological toxicities included vomiting, elevated alanine aminotransferase, sensory neuropathy, rash, and fever, but were generally low and tolerable. There was no occurrence of nephrotoxicity or toxic death.

### Discussion

Thymic carcinoma represents a heterogeneous group of tumors with a wide morphologic and behavioral spectrum.

**Table 2** Hematological and non-hematological toxicities

n=13	Grade≤2	Grade≥3
Hematological		
Leukocytopenia	9 (69.2%)	4 (30.8%)
Neutropenia	5 (38.5%)	6 (46.2%)
Anemia	4 (30.8%)	1 (7.7%)
Thrombocytopenia	3 (23.1%)	2 (15.4%)
Non-hematological		
Fever	3 (23.1%)	0 (0%)
Vomiting	9 (69.2%)	1 (7.7%)
ALT increased	3 (23.1%)	0 (0%)
Sensory neuropathy	9 (69.2%)	0 (0%)
Rash	3 (23.1%)	0 (0%)

ALT, alanine aminotransferase.

Most of the previous studies have included all of the subtypes, obscuring distinct clinicopathological features and confusing treatment results; therefore, we solely addressed thymic squamous cell carcinoma. Our results indicate that thymic squamous cell carcinoma diagnosis occurs at a peak age of 50–60, with a slight male predominance. The median size of tumors in this study was 5.9 cm, and most of the patients presented symptoms. Our findings are similar to those of Zhao *et al.*<sup>14</sup> None of the patients in our study experienced symptoms of myasthenia gravis or other associated symptomatic paraneoplastic syndromes. Previous studies have reported that thymic squamous cell carcinoma rarely occurs with myasthenia gravis.<sup>15,16</sup>

Chemotherapy is commonly administered to patients with unresectable and/or metastatic thymic squamous cell carcinoma. Standard systemic chemotherapy for advanced thymic carcinoma has not been determined because of its rarity. In general, the combination chemotherapy regimens most widely evaluated have combined platinum analogs, anthracyclines and other agents (Table 3). For first-line regimens, response rates range from 22–75% with median OS

ranging from 19–49 months. Anthracycline-based regimens, such as CODE (cisplatin, vincristine, doxorubicin, etoposide) and ADOC (cisplatin, doxorubicin, vincristine and cyclophosphamide), have, to date, been widely used; however, as toxicity is associated with their use, an alternative treatment needs to be found. Platinum-based chemotherapy is another choice for advanced thymic carcinoma. Despite the relatively short median PFS/time to progression reported, there is a frustrating lack of data to guide use of second-line cytotoxic therapies for treatment of patients with thymic carcinoma. Okuma *et al.* reported ORRs of first, second, third, and fourth-line chemotherapy of 60.9%, 39.1%, 23.1%, and 25.0%, respectively.<sup>25</sup> Although the role of salvage chemotherapy remains uncertain in thymic carcinoma, we consider that beneficial salvage chemotherapy may contribute to better outcomes in certain patients.

Gemcitabine and cisplatin chemotherapy is one of many standard regimens for several malignancies and has prominent efficacy, especially in patients with squamous cell cancers.<sup>8–12</sup> Compared with pemetrexed plus cisplatin, GP showed even better efficacy in patients with squamous cell lung cancer.<sup>12</sup> Thus, we speculate that GP may be a potential regimen in advanced thymic squamous cell carcinoma.

In this trial, the GP regimen resulted in an ORR of 61.5% and DCR of 92.3% in patients with untreated or recurrent advanced thymic squamous cell carcinoma. Median PFS and median OS were 14.5 (95% CI, 9.2–19.8 months) and 50.7 months (95% CI, 24.9–76.5 months), respectively. Our results are similar to those observed with previously reported cisplatin and/or doxorubicin-based regimens, and better than those observed with a paclitaxel and carboplatin regimen, while our PFS and OS rates were superior.<sup>6,7,17–22</sup> This may be explained, at least in part, by the relatively slow growth characteristics of thymic squamous cell carcinoma.<sup>14</sup> It may also be attributable to the local therapies administered before progression, and the fact that all of the patients

**Table 3** Series of patients with thymic carcinoma treated with cytotoxic chemotherapy

Chemotherapeutic regimen	Years	Treatment line	Prospective or retrospective	No. of patients	ORR%	Median PFS/TTP (months)	Median OS (months)
ADOC <sup>6</sup>	2002	First	P	8	75%	NA	19
CODE <sup>17</sup>	2003	First	R	12	42%	6	46
VIP <sup>18</sup>	2008	First	R	9	44%	NA	20
PC <sup>19</sup>	2010	First	P	11	36%	8	23
PC <sup>20</sup>	2011	First	P	23	22%	5	20
ADOC/ADOCb <sup>7</sup>	2011	First	R	34	50%	8	21
IP <sup>21</sup>	2011	First	R	9	56%	8	34
PC <sup>22</sup>	2011	First	R	16	38%	9	49
IP <sup>23</sup>	2007	Second	R	7	29%	NA	18
PC <sup>24</sup>	2014	Second	R	12	25%	3.5	24

ADOC, doxorubicin, cyclophosphamide, vincristine, cisplatin; ADOCb, doxorubicin, cyclophosphamide, vincristine, carboplatin; CODE, cisplatin, vincristine, doxorubicin, etoposide; IP, irinotecan, cisplatin; NA, not available; OS, overall survival; PC, paclitaxel, carboplatin; PFS, progression-free survival; TTP, time to progression; VIP, etoposide, ifosfamide, cisplatin.

received subsequent chemotherapy when their disease progressed.

As we perform routine blood tests in our clinical practice, relatively complete evaluations of hematological toxicity incidences were recorded. Grade 3/4 myelosuppression was seen in seven (53.8%) patients. However, because of the retrospective design of this study, non-hematological toxicity data, especially for low-grade toxicities, could not be completely evaluated. Despite the existence of one patient with grade 3 chemotherapy-induced vomiting, the incidence of high grade vomiting and nephrotoxicity may be lower in our study than in previous reports.<sup>8,9,12</sup> The differences in gastrointestinal toxicities might be a result of the use of cisplatin, which is usually given over three continuous days in Asia in order to decrease nephrotoxicity and vomiting. In this study, although myelosuppression was the most common adverse event, there was no febrile neutropenia, only one patient needed platelet transfusions, and there were no treatment-related deaths. This combination chemotherapy, thus, provided acceptable results with respect to toxicity.

Limitations of the present study include its retrospective nature and the small sample size, but it is difficult to develop a large, prospective clinical study for such a rare malignancy.

## Conclusion

Our treatment results suggest that gemcitabine may be a novel and reasonable alternative agent for advanced thymic squamous cell carcinoma, especially in patients who cannot tolerate anthracyclines. GP is active against advanced thymic squamous cell carcinoma, with manageable toxicity.

## Disclosure

No authors report any conflict of interest.

## References

- Marx A, Strobel P, Zettl A *et al.* Thymomas. In: Travis WD, Brambilla E, Müller-Hermelink HK, Harris CC (eds). *Pathology and Genetics: Tumours of the Lung, Thymus and Heart*, Vol. 7. IARC Press, Lyon 2004; 145–245.
- Kondo K, Monden Y. Therapy for thymic epithelial tumors: A clinical study of 1,320 patients from Japan. *Ann Thorac Surg* 2003; **76**: 878–84.
- Lee CY, Bae MK, Park IK, Kim DJ, Lee JG, Chung KY. Early Masaoka stage and complete resection is important for prognosis of thymic carcinoma: A 20-year experience at a single institution. *Eur J Cardiothorac Surg* 2009; **36**: 159–62
- Ogawa K, Toita T, Uno T *et al.* Treatment and prognosis of thymic carcinoma: A retrospective analysis of 40 cases. *Cancer* 2002; **94**: 3115–9.
- Nakamura Y, Kunitoh H, Kubota K *et al.* Platinum-based chemotherapy with or without thoracic radiation therapy in patients with unresectable thymic carcinoma. *Jpn J Clin Oncol* 2000; **30**: 385–8.
- Koizumi T, Takabayashi Y, Yamagishi S *et al.* Chemotherapy for advanced thymic carcinoma: Clinical response to cisplatin, doxorubicin, vincristine, and cyclophosphamide (ADOC chemotherapy). *Am J Clin Oncol* 2002; **25**: 266–8.
- Agatsuma T, Koizumi T, Kanda S *et al.* Combination chemotherapy with doxorubicin, vincristine, cyclophosphamide, and platinum compounds for advanced thymic carcinoma. *J Thorac Oncol* 2011; **6**: 2130–4.
- Schiller JH, Harrington D, Belani CP *et al.* Comparison of four chemotherapy regimens for advanced non-small-cell lung cancer. *N Engl J Med* 2002; **346**: 92–8.
- Valle J, Wasan H, Palmer DH *et al.* Cisplatin plus gemcitabine versus gemcitabine for biliary tract cancer. *N Engl J Med* 2010; **362**: 1273–81.
- Hashemi FA, Akbari EH, Kalaghchi B, Esmati E. Concurrent chemoradiation with weekly gemcitabine and cisplatin for locally advanced cervical cancer. *Asian Pac J Cancer Prev* 2013; **14**: 5385–9.
- El Deen DA, Toson EA, El Morsy SM. Gemcitabine-based induction chemotherapy and concurrent with radiation in advanced head and neck cancer. *Med Oncol* 2012; **29**: 3367–73.
- Scagliotti GV, Parikh P, von Pawel J *et al.* Phase III study comparing cisplatin plus gemcitabine with cisplatin plus pemetrexed in chemotherapy-naïve patients with advanced-stage non-small-cell lung cancer. *J Clin Oncol* 2008; **26**: 3543–51.
- Masaoka A, Monden Y, Nakahara K, Tanioka T. Follow-up study of thymomas with special reference to their clinical stages. *Cancer* 1981; **48**: 2485–92.
- Zhao Y, Zhao H, Hu D, Fan L, Shi J, Fang W. Surgical treatment and prognosis of thymic squamous cell carcinoma: A retrospective analysis of 105 cases. *Ann Thorac Surg* 2013; **96**: 1019–24.
- Blumberg D, Burt ME, Bains MS *et al.* Thymic carcinoma: Current staging does not predict prognosis. *J Thorac Cardiovasc Surg* 1998; **115**: 303–8.
- Liu HC, Hsu WH, Chen YJ *et al.* Primary thymic carcinoma. *Ann Thorac Surg* 2002; **73**: 1076–81.
- Yoh K, Goto K, Ishii G *et al.* Weekly chemotherapy with cisplatin, vincristine, doxorubicin, and etoposide is an effective treatment for advanced thymic carcinoma. *Cancer* 2003; **98**: 926–31.
- Magois E, Guigay J, Blancard PS *et al.* Multimodal treatment of thymic carcinoma: Report of nine cases. *Lung Cancer* 2008; **59**: 126–32.
- Igawa S, Murakami H, Takahashi T *et al.* Efficacy of chemotherapy with carboplatin and paclitaxel for unresectable thymic carcinoma. *Lung Cancer* 2010; **67**: 194–7.

- 20 Lemma GL, Lee JW, Aisner SC *et al.* Phase II study of carboplatin and paclitaxel in advanced thymoma and thymic carcinoma. *J Clin Oncol* 2011; **29**: 2060–5.
- 21 Okuma Y, Hosomi Y, Takagi Y, Iquchi M, Okamura T, Shibuya M. Cisplatin and irinotecan combination chemotherapy for advanced thymic carcinoma: Evaluation of efficacy and toxicity. *Lung Cancer* 2011; **74**: 492–6.
- 22 Furugen M, Sekine I, Tsuta K *et al.* Combination chemotherapy with carboplatin and paclitaxel for advanced thymic cancer. *Jpn J Clin Oncol* 2011; **41**: 1013–6.
- 23 Kanda S, Koizumi T, Komatsu Y *et al.* Second-line chemotherapy of platinum compound plus CPT-11 following ADOC chemotherapy in advanced thymic carcinoma: Analysis of seven cases. *Anticancer Res* 2007; **27**: 3005–8.
- 24 Song Z. Chemotherapy with paclitaxel plus carboplatin for relapsed advanced thymic carcinoma. *J Thorac Dis* 2014; **6**: 1808–12.
- 25 Okuma Y, Hosomi Y, Takahashi S, Maeda Y, Okamura T, Hishima T. Response to cytotoxic chemotherapy in patients previously treated with palliative-intent chemotherapy for advanced thymic carcinoma. *Clin Lung Cancer* 2015; **16**: 221–7.