

# Outcome of single maxillary complete dentures opposing mandibular teeth: A need to introspect on the prosthodontic treatment protocol

Sudhir Bhandari

Unit of Prosthodontics, Oral Health Sciences Centre, PGIMER, Chandigarh, India

## Abstract

**Introduction:** In the era of implant supported restorations, conventional complete denture (CD) for isolated edentulous maxilla still remains the first choice of treatment despite being its frequent mechanical failures.

**Statement of Problem:** Edentulous maxillary arch restored with polymethyl methacrylate (PMMA) based CDs when opposed by natural and/or restored dentition is biomechanically and functionally a compromised rehabilitation.

**Materials and Methods:** Seven patients (4 males, 3 females) in the age range of 55–75 years were treated for their frequent fracture of the single maxillary denture. They were asked to rate their prosthodontic experience on a scale of 1–10. They were further inquired about the awareness of their clinical condition and knowledge on the alternative treatment options available to them, number of different dentists they have been treated by and frequency of their re-visits to the dental office after being edentulous.

**Results:** Removable PMMA based CD in maxilla was the first choice of treatment for all the restorative dentists who treated these patients. No attempt was ever made to treat the opposing dentition in any of the seven patients. Despite being under regular prosthodontic care for fabrication and repairs by as many as 23 dentists, none of the patients was aware of their clinical situation and the alternative treatment options available.

**Conclusion:** It is imperative that the restorative dentist be aware of the perils of such inter-arch relationships. Appropriate treatment done on time may avert a situation where the oral conditions become incompatible for the longevity of treatment done even with the aid of dental implants.

**Key Words:** Complete denture, dental implants, denture base, edentulous maxilla, metal denture base, midline fracture

## Address for correspondence:

Dr. Sudhir Bhandari, Unit of Prosthodontics, Oral Health Sciences Centre, PGIMER, Chandigarh, India. E-mail: drsudhirbhandari@yahoo.co.in

**Received:** 31<sup>st</sup> July 2015, **Accepted:** 8<sup>th</sup> September, 2015

## INTRODUCTION

Accurate prosthetic treatment planning and its precise execution impact the optimal outcome of prosthetic rehabilitation in clinical situations where force factors are beyond the

operator's control. Such is a situation of isolated edentulous maxilla opposed by mandibular dentition. Presence of unmodified opposing dentition prevents occlusal balance during function thereby, compromising stability and retention

Access this article online	
Quick Response Code:	Website: www.j-ips.org
	DOI: 10.4103/0972-4052.167941

This is an open access article distributed under the terms of the Creative Commons Attribution-NonCommercial-ShareAlike 3.0 License, which allows others to remix, tweak, and build upon the work non-commercially, as long as the author is credited and the new creations are licensed under the identical terms.

**For reprints contact:** reprints@medknow.com

**How to cite this article:** Bhandari S. Outcome of single maxillary complete dentures opposing mandibular teeth: A need to introspect on the prosthodontic treatment protocol. J Indian Prosthodont Soc 2016;16:15-9.

and eventually leading to frequent mechanical failures of the prosthesis.

Any factor that exacerbates the deformation of the base or alters its stress distribution may predispose the polymethyl methacrylate denture to fracture.<sup>[1]</sup> The mechanical failure of such dentures under functional masticatory forces, especially in the presence of opposing dentition, is a persistent problem and its prevention is still a challenge for the clinician. Denture fractures cause functional insufficiency, compromised esthetic and financial burden on its users for its repair or refabrication.<sup>[2-4]</sup> Further, the repaired denture bases become more prone to subsequent fractures if the root cause(s) is not addressed to.<sup>[5,6]</sup>

Focus of prosthodontic treatment has always been on finding the antidote for the problems concurrent with respect to the rehabilitation of the edentulous mandibular arch. In addition, subjective satisfaction with maxillary denture, relatively low success rate of dental implants in maxilla,<sup>[7]</sup> lack of awareness and consent from the patients for the correction of misaligned opposing dentition worsens the situation with every passing year.

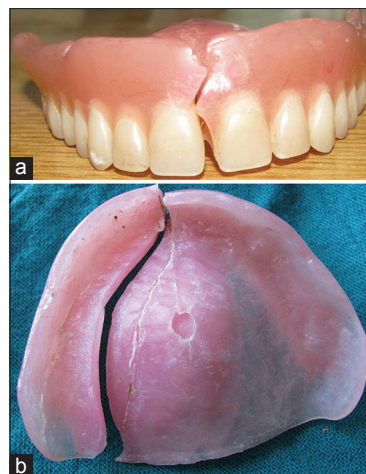
The purpose of this article is to re-emphasize the importance basic prosthodontic principle of preservation of the remaining, which is largely been, ignored in patients of the single maxillary complete denture (CD) opposing natural teeth.

### Patients presentation

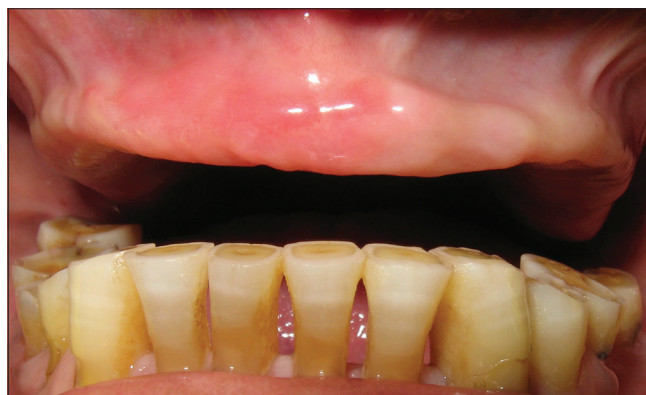Seven patients (4 males, 3 females) in the age range of 55–77 years with edentulous maxillary arch and opposing mandibular natural and/or restored teeth were treated for complaints related to the their broken maxillary dentures [Figure 1a and b]. They all presented with an overlapping history of frequent maxillary denture fracture, corresponding repairs, and subsequently multiple new dentures. All of them lost maxillary teeth due to the periodontal breakdown of the supporting structures.

Critical clinical evaluation revealed amalgamation of following factors which lead to repeated fracture of the denture base in these patients:

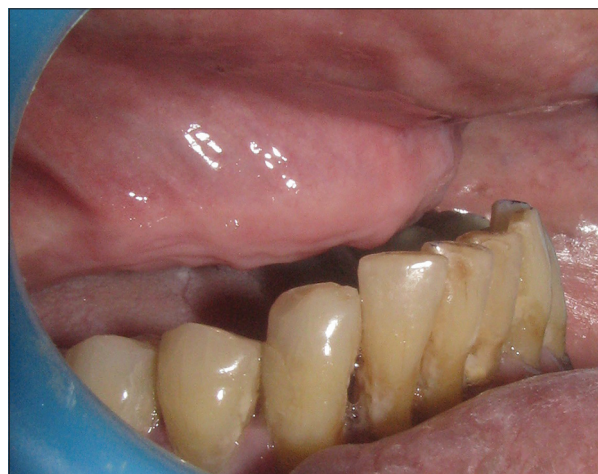- i. Completely edentulous and resorbed maxillary alveolar ridge [Figure 2]
- ii. The defective plane of occlusion either due to supraeruption, wear or defective full coverage restorations of mandibular teeth
- iii. Supra-erupted and labial proclination of mandibular anterior teeth creating a pseudo class III malocclusion which further lead to an inadequate thickness of denture base resin in the anterior palatal area [Figure 3]



**Figure 1:** (a) Typical presentation of fractures in maxillary dentures. When a notch and/or diastema were present in the maxillary complete denture, they were involved in the fracture line. (b) Fracture pathway on the intaglio surface of maxillary denture



**Figure 2:** Severely resorbed edentulous maxillary arch and status of opposing dentition showing worn teeth, leading to defective plane of occlusion



**Figure 3:** Pseudo class III profile in long standing maxillary edentulism due to the supraeruption and proclination of mandibular anteriors

- iv. Multiple fractures and corresponding repairs of maxillary denture at various sites.

## Proposed treatment

Foremost concern was to educate the patient regarding their oral conditions and factors responsible for the frequent fracture of their maxillary dentures. Emphasis was given to begin the treatment by correcting the defective mandibular plane of occlusion by modifying shape and size of existing teeth and/or restorations. Finally, rehabilitation of maxilla by implant supported prosthesis with bone augmentation procedure, if deemed necessary.

## MATERIALS AND METHODS

Their detailed history was recorded citing their problems and prosthodontic experience after becoming edentulous in the maxilla. The severity of their problems was scored on the scale of 1–10, with lower scores corresponding to a positive response. They were further asked to record the number of different dentists they have visited after being edentulous, number of CD they have worn during this time and number of times they revisited the dental office for the repair of the prosthesis. Their respective awareness of oral condition, treatment options available to them and their reasons for refusing implant related treatment was also ascertained.

## RESULTS

All patients had a difficult prosthodontic experience and were, in general, unsatisfied with regard to their CD [Table 1]. Except for one patient, all other patients were edentulous for

over 6 years and had changed their dentists at least twice for a better prosthetic care. These patients went on numerous occasions to the dental office for denture repairs but could not recollect precisely the number and frequency of their visits. During all these years and visiting 23 dentists, they were never educated by any of the restorative dentists about their oral situation and therefore, none of them were aware of the same [Table 2]. Implant related treatment was proposed to only one them but was never initiated.

Due to their age, time involved in overall management, need for the correction of opposing dentition, preprosthetic surgical procedures to improve upon bony foundation and economic constraints four patients did not agree to dental implant related treatment [Table 3]. Three patients accepted implant related treatment but without any additional surgical procedures and alteration in the opposing teeth. In due course, only one patient underwent implant surgery with modification of the lower teeth. For remaining six patients, change of denture base material to cast base metal alloy was proposed and was well accepted by them.

## DISCUSSION

Fracture of maxillary CD is a common complaint in the presence of mandibular teeth and is probably an acceptable problem. The mode of failure is flexural fatigue failures caused

**Table 1: The intensity of problems in patients with isolated maxillary denture at presentation**

	Patient 1	Patient 2	Patient 3	Patient 4	Patient 5	Patient 6	Patient 7
Age and sex	70/male	65/male	77/female	68/male	58/male	55/female	68/female
Type of maxillary denture	CD	CD	CD	CD	CD	CD	CD
Loose	3	7	9	7	4	3	6
Unstable or rocking	2	6	10	9	8	1	5
Chewing efficiency	4	3	10	6	4	4	8
Unesthetic	1	1	5	3	1	1	1
Frequent fractures	8	7	10	8	8	9	9
Painful chewing	1	1	9	1	1	1	1
Taste perception	2	3	8	6	2	4	2
Speech	1	4	8	6	3	1	1
Want a permanent solution	Yes	Yes	Yes	Yes	Yes	Yes	Yes
Just that it is old	No	No	No	No	No	No	No

Patients were asked to rate their perceptions on present prosthesis and complaints with respect to their previous rehabilitation on the scale of 1-10, corroborating with their subjective feedback. Positive 1-4, Borderline 5-7, Negative 8-10. Low scores correspond to an acceptable experience, whereas high score signifies problems requiring immediate attention and need for a new prosthetic solution. CD: Complete dentures

**Table 2: Patient awareness questionnaire**

	Patient 1	Patient 2	Patient 3	Patient 4	Patient 5	Patient 6	Patient 7
Years of edentulism	8	6	15	7	10	0.6	10
Are you aware of your clinical condition?	No	No	No	No	No	No	No
How many dentists have treated you?	3	2	5	4	4	2	3
Approximately how many times did you visit dental office for repairs	Many	Cannot recollect	Do not remember	Cannot say	Many	Twice	Do not remember
Has your treating dentist educated you on this?	No	No	No	No	No	No	No
Number of dentures you have worn after being edentulous?	5	4	8	2	2	1	4
Has anyone suggested you an implant supported prosthesis?	No	No	No	No	Yes	No	No
Are you aware of dental Implants as a treatment option?	No	No	No	No	Yes	No	No

The level of awareness in patients with respect to their clinical condition and reasons for their frequent problems

**Table 3: Factors influencing the decision to opt out for the implant related treatment**

	Patient 1	Patient 2	Patient 3	Patient 4	Patient 5	Patient 6	Patient 7
Age	Yes	Yes	Yes	Yes	No	No	Yes
Financial constraints	Yes	Yes	Yes	Yes	No	No	Yes
Time involved	Yes	Yes	Yes	No	Yes	No	No
Additional surgical procedure	Yes	Yes	Yes	Yes	No	Yes	Yes
Probability of future complications	Yes	Yes	Yes	No	No	Yes	Yes
Need for the correction of mandibular teeth	Yes	Yes	Yes	Yes	No	Yes	Yes

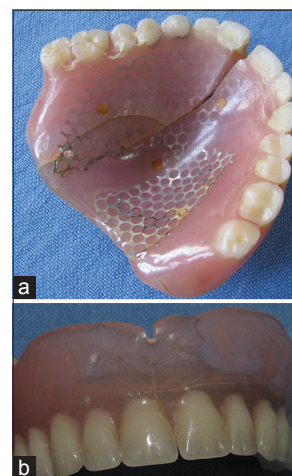
by cyclic deformation due to masticatory forces. The reported incidence of fracture of the maxillary CDs is twice that of the mandibular CDs and the typical fatigue failure of maxillary CDs is evidenced by its midline fracture.<sup>[8]</sup> Initiation and propagation of the cracks in a maxillary denture are relatively quick due to high tensile principal stress and a high maximum shear stress.<sup>[9]</sup>

In the current scenario, when the number of implant related treatments is exponentially increasing, rehabilitation of patients with isolated maxillary edentulism with implants is rather ignored. Plausible reasons for this line of thinking seems to be a higher failure rate of implants in maxilla due to poorer bone quality in comparison to mandible, higher treatment cost as well as further expectancy of higher failure rate in patients presenting with opposing teeth. The negative effect of antagonist occlusion on the maxillary implant supported prosthesis can be gauged by only 22.2% survival rate of implant overdenture and 6 out of 8 implants failure in patients with opposing natural dentition.<sup>[10,11]</sup>

These patients in concern have been edentulous for a long time and were regularly visiting their restorative dentists for denture repairs and prospects of a better treatment option. When given the alternative treatment options, patient's age, time required for rehabilitation, economic status and fear for extensive surgical procedures for improving the bony foundation and associated morbidity preclude them for giving consent for the implant supported treatment.

Despite desiring for a solution to their persistent problems, six patients were not taken up for implant related treatment. Therefore, the only option remained was to offer them a strong denture base with a harmonious occlusal relationship between both the arches. Since force factors were left unmodified, the longevity of this treatment provided also remains doubtful as the fracture of reinforced CD was also experienced [Figure 4a and b].

Even though, this study involved less number of the patients; results do suggest a general tendency to restore the edentulous maxilla with conventional CD irrespective of the status of the mandibular arch. Considering the time involved and money spent on frequent visits for denture repairs and for achieving



**Figure 4:** (a) Fracture of denture even when metal strengtheners have been incorporated into the design. (b) Fracture line visible in midline of maxillary denture with metal denture base

optimal general and oral health, this group of patients should routinely be treatment planned for fixed implant supported prosthesis unless indicated otherwise. The much needed correction of mandibular teeth should be part of treatment planning and its correction should be the foremost concern before initiating treatment for edentulous maxilla. Early initiation of the treatment will preserve the remaining hard and soft tissues and provide the patient with an appropriate prosthesis, leading to their improved oral health related quality of life.

## CONCLUSION

Comprehensive treatment planning for holistic oral care and its timely execution may avert known potential complications in restoring isolated edentulous maxilla. Implant supported prosthesis should be the treatment of choice over conventional CD and in other patients, providing a strong maxillary denture base with correction of the dentition in the opposing arch seems to be a prudent solution to the frequent mechanical complexities.

## Financial support and sponsorship

Nil.

## Conflicts of interest

There are no conflicts of interest.

## REFERENCES

1. Beyli MS, von Fraunhofer JA. An analysis of causes of fracture of acrylic resin dentures. *J Prosthet Dent* 1981;46:238-41.
2. Vallittu PK, Lassila VP, Lappalainen R. Evaluation of damage to removable dentures in two cities in Finland. *Acta Odontol Scand* 1993;51:363-9.
3. Smith DC. The acrylic denture: Mechanical evaluation midline fracture. *Br Dent J* 1961;110:257-67.
4. Darbar UR, Huggett R, Harrison A. Denture fracture – A survey. *Br Dent J* 1994;176:342-5.
5. Vallittu PK, Lassila VP, Lappalainen Niom R. The effect of notch shape and self-cured acrylic resin repair on the fatigue resistance of an acrylic resin denture base. *J Oral Rehabil* 1996;23:108-13.
6. Rawls HR. Dental polymers. In: Anusavice KJ, editor. *Phillips Science of Dental Materials*. St. Louis, Missouri: Saunders; 2003. p. 166.
7. Slot W, Raghoobar GM, Vissink A, Huddleston Slater JJ, Meijer HJ. A systematic review of implant-supported maxillary overdentures after a mean observation period of at least 1 year. *J Clin Periodontol* 2010;37:98-110.
8. Yli-Urpo A, Lappalainen R, Huuskonen O. Frequency of damage to and need for repairs of removable dentures. *Proc Finn Dent Soc* 1985;81:151-5.
9. Prombonas AE, Vlissidis DS. Comparison of the midline stress fields in maxillary and mandibular complete dentures: A pilot study. *J Prosthet Dent* 2006;95:63-70.
10. Becktor JP, Eckert SE, Isaksson S, Keller EE. The influence of mandibular dentition on implant failures in bone-grafted edentulous maxillae. *Int J Oral Maxillofac Implants* 2002;17:69-77.
11. Ohkubo C, Baek KW. Does the presence of antagonist remaining teeth affect implant overdenture success? A systematic review. *J Oral Rehabil* 2010;37:306-12.

### Author Help: Reference checking facility

The manuscript system ([www.journalonweb.com](http://www.journalonweb.com)) allows the authors to check and verify the accuracy and style of references. The tool checks the references with PubMed as per a predefined style. Authors are encouraged to use this facility, before submitting articles to the journal.

- The style as well as bibliographic elements should be 100% accurate, to help get the references verified from the system. Even a single spelling error or addition of issue number/month of publication will lead to an error when verifying the reference.
- Example of a correct style  
Sheahan P, O'leary G, Lee G, Fitzgibbon J. Cystic cervical metastases: Incidence and diagnosis using fine needle aspiration biopsy. *Otolaryngol Head Neck Surg* 2002;127:294-8.
- Only the references from journals indexed in PubMed will be checked.
- Enter each reference in new line, without a serial number.
- Add up to a maximum of 15 references at a time.
- If the reference is correct for its bibliographic elements and punctuations, it will be shown as CORRECT and a link to the correct article in PubMed will be given.
- If any of the bibliographic elements are missing, incorrect or extra (such as issue number), it will be shown as INCORRECT and link to possible articles in PubMed will be given.