



Bioabsorbable implants in forefoot surgery: a review of materials, possibilities and disadvantages

Lorenz Pisecky
Matthias Luger
Antonio Klasan
Tobias Gotterbarm
Matthias C. Klotz
Rainer Hochgatterer

- Bioabsorbable and biodegradable implants offer new possibilities in orthopaedic and trauma surgery. As soon as the initial stability of the degradable implants has reached the qualities of conventional materials, new devices may find usage in younger and more demanding patients. Residual conventional osteosynthetic material or the necessity to remove metal increasingly seems to be more of an adverse event than daily practice in forefoot surgery. Nevertheless, some drawbacks need to be discussed.
- Recent literature screened for the use of bioabsorbable and biodegradable materials in forefoot surgery, available implants and indications in forefoot surgery were analysed and summarized. Apart from common indications in forefoot surgery, points of interest were the type of biomaterial, the process of biodegradation and biointegration, and possible adverse events. Materials were comprehensively discussed for each indication based on the available literature.
- Polylactide, polyglycoside and polydioxanone are considered safe and sufficiently stable for use in forefoot surgery. Low complication rates (e.g. 0.7% for pin fixation in hallux deformities) are given.
- Magnesium implants suffered from an extensive corrosive process in the first generation but now seem to be safe in forefoot surgery and offer good options compared with conventional titanium screws, especially in procedures of the first ray.
- Allograft bone has proven feasibility in small case series, but still lacks larger or randomized clinical trials. The first results are promising.
- Bioresorbable and osseointegrating devices offer attractive new possibilities for surgeons and patients. Despite all the known advantages, the difficulties and possible complications must not be forgotten, such as soft tissue reactions, unwanted osteolysis and a lower primary mechanical load capacity.

Keywords: biodegradable; bioresorbable; forefoot surgery; implant; osseointegration

Cite this article: *EFORT Open Rev* 2021;6:1132-1139.
DOI: 10.1302/2058-5241.6.200157

Background

The bioabsorbable screw is a commonly used technique nowadays in orthopaedic surgery and a viable alternative to well-established osteosynthetic devices, such as K-wires and titanium screws. Although metallic implants provide more than enough stability, they have two major drawbacks: their persistence in otherwise healthy bone and the need for surgical explantation. Since the introduction of polylactide plates for mandibular fractures, bioabsorbable materials have been used to treat fractures in adults and children and in elective orthopaedic surgery.¹⁻⁵ In recent years, the market for bioabsorbable materials has increased, and their field of application has grown. Although the popularity of bioabsorbable implants has grown in recent years due to several favourable factors for patients and surgeons, these devices can also give rise to complications that the surgeon should be aware of. These vary from mild inflammation to severe tissue-destructive reactions.

The number of published studies about these devices is relatively small compared to other orthopaedic disciplines. A comprehensive collection of known adverse events is also missing. This review article therefore has two aims. First, it will describe the extensive possibilities for using biodegradable materials in modern forefoot surgery. Second, it will shed light on the possible adverse effects that surgeons should consider.

Methods

A structured literature search was conducted using the PubMed database up to 30 November 2020 with the search terms “bioresorbable forefoot surgery” and “bio/absorbable forefoot surgery”. Relevant criteria used during the search were: published between 2003 and 2020, and articles in the English language. Titles, abstracts, and articles were reviewed, and data concerning patient demographics, study design and pre- and postoperative findings were extracted.

The PRISMA (Preferred Reporting Items for Systematic Reviews and Meta-Analyses) guidelines were followed. We were able to include 14 case series. All included articles were evaluated according to the Coleman Methodological Score (CMS).⁶ The Score consists of 10 criteria, split up into two parts (part A: seven criteria, part B: three criteria). This results in a total score ranging between 0 (lowest possible study design) and 100 (part A: 0–60 points, part B: 0–40 points). A Coleman Score of 85–100 points is considered excellent, 70–84 good, 50–69 moderate and 0–49 poor. We were able to include six prospective and six retrospective case series and two technical notes. One of the case series was rated as Level II, 10 of them were rated as Level III and one as Level IV.

Apart from common indications in forefoot surgery, points of interest were the type of biomaterial, the process of biodegradation and biointegration and possible adverse events. The biomaterials were comprehensively discussed for each indication based on the available literature.

Results

Possible applications in forefoot surgery

Biologically degradable osteosynthesis materials are becoming increasingly popular because they remove the need for a second operation, especially in the field of forefoot surgery. Conventional metal implants, typically used to fix an osteotomy or a fracture, are rigid constructs that tend to create stress shielding due to their unphysiological force application, resulting in osteolytic zones and ultimately leading to the implant removal.⁷ Bioabsorbable materials provide an increasingly physiological application of force into the osseous structure during the course of their degradation process, thereby avoiding the need for a second intervention while at the same time becoming more physiologic as they decompose. Materials used for this purpose are polylactides, polyglycosides, polydioxanones, magnesium and human bone.⁸ Just like the material, the shape can vary as well. Nearly all (orthopaedic) imaginable forms of surgical materials are offered for use: plates, screws, pins, suture anchors and staples are intended to cover the market for a wide range of applications. In modern forefoot surgery, biodegradable

materials are mostly used in pin- or screw-like shapes, as seen in recent literature. Pins and screws are widely used by orthopaedic surgeons to hold the reduction of the osteotomy in hallux valgus, hammer toe, claw toe, metatarsalgia and digitus quintus varus deformities. Due to their similarity with conventional titanium screws and larger diameter, bioabsorbable screws made from either magnesium or human cortical bone are mostly used in surgical procedures of the larger first metatarsal bone. Magnesium-based implants, in particular, have started to replace conventional titanium screws in correction osteotomies of the hallux valgus deformity because of their higher load capacity compared to polylactide pins.⁹ More slender pins and pin-like devices are used in procedures of the lesser toes. Biodegradable plates, as used in orthognathic surgery, have not made their way into literature related to forefoot surgery.

Disadvantages and adverse events

Despite all the mentioned advantages (biological force application, resorbability, lack of secondary procedures, wide range of applications), the materials used also have disadvantages that need to be pointed out: they are generally not as mechanically loadable as their metal counterparts, they are more expensive and, in some cases, they have undesirable biological effects (Table 1). It can now be assumed that the mechanical load capacity of bioresorbable implants, with careful planning of the application and an appropriate surgical technique, is sufficient to maintain stability in the bone for a sufficient timespan until biological healing has occurred.^{10,11} However, if a foreign body reaction, such as described for all artificial bioresorbable materials, appears, the hoped-for advantages may be nullified. For polylactides, polyglycosides and polydioxanones, reactions ranging from fluid collection, fistula formation to sustained soft tissue damage have been described.¹² The frequency (3% for severe to 47% for mild side effects in general use)^{13,14} and time of occurrence (60 days for fluid collection to 9.5 years for foreign body reaction in general use) were not consistent (Table 2).^{14,15}

Although most bioabsorbable materials are based on polymeric structures, biodegradable magnesium-based implants have made their way into operating rooms. The extensive corrosive process of first-generation, magnesium-based implants seems to be under control so that even intravascular implants are used.¹⁶

Magnesium implants are mainly used in orthopaedic forefoot surgery in the form of screws. Due to their appearance and material, they do not seem to differ significantly from conventional titanium screws, which may subsequently become a fallacy if they are handled in an improper manner. Due to their lower Young's modulus of elasticity compared to conventional titanium screws, they

Table 1. Possible adverse events of biodegradable devices

Author, year	Title	Study type	CMS	Pathology	Technique	Implant	Patients/toes treated with absorbable device	Clinical outcome
Choo et al, 2019 ²⁷	Magnesium-based bioabsorbable screw fixation for hallux valgus surgery: a suitable alternative to metallic implants	Prospective	69	Hallux valgus	Scarf	Magnesium	24	Significant improvement of PROMs
Kim, Cho et al, 2016 ⁴⁷	Effectiveness of headless bioabsorbable screws for fixation of the scarf osteotomy	Retrospective	56	Hallux valgus	Scarf	Poly lactide	115	111 patients (97%) satisfied
Atkinson et al, 2019 ¹⁷	Hallux valgus correction utilising a modified short scarf osteotomy with a magnesium biodegradable or titanium compression screws: a comparative study of clinical outcomes	Retrospective	62	Hallux valgus	Scarf	Magnesium vs. titanium	11	Significant improvement of PROMs, magnesium equivalent to titanium
Windhagen et al, 2013 ²²	Biodegradable magnesium-based screw clinically equivalent to titanium screw in hallux valgus surgery: short term results for the first prospective, randomized, controlled clinical pilot study	Prospective	68	Hallux valgus	Chevron	Magnesium vs. titanium	13	Significant improvement of PROMs, magnesium equivalent to titanium
Wendelstein et al, 2017 ³¹	Bioabsorbable fixation screw for proximal interphalangeal arthrodesis of lesser toe deformities	Retrospective	56	Hammer toe	Arthrodesis	Poly lactide	24/26	20 patients (86%) satisfied
Konkel et al, 2011 ³⁰	Hammer toe correction using an absorbable pin	Prospective	66	Hammer toe	Arthrodesis	Poly lactide	29/47	28 patients (96%) satisfied
Konkel et al, 2007 ²⁹	Hammer toe correction using an absorbable intramedullary pin	Prospective	72	Hammer toe	Arthrodesis	Polydioxanone	35/48	32 patients (91%) satisfied
Pietrzak et al, 2006 ²⁸	A bioabsorbable fixation implant for use in proximal interphalangeal joint (hammer toe) arthrodesis: biomechanical testing in a synthetic bone substrate	Technical note	n.a.	Hammer toe	Arthrodesis	Poly lactide	Synthetic bone	Technical outcome comparable to 1.57 mm K-wire
Morandi et al, 2009 ³⁴	Results of distal metatarsal osteotomy using absorbable pin fixation	Retrospective	56	Metatarsalgia	Weil	Poly lactide	62/66	62 patients (100%) satisfied
Alcelik et al, 2009 ²⁶	Bioabsorbable fixation for Mitchell's bunionectomy osteotomy	Retrospective	41	Hallux valgus	Mitchell	Polydioxanone	52/78	No loss of correction, no PROMs given
Plaass et al, 2018 ²⁴	Bioabsorbable magnesium versus standard titanium compression screws for fixation of distal metatarsal osteotomies: 3 year results of a randomized clinical trial	Prospective	67	Hallux valgus	Chevron	Magnesium vs. titanium	26	Significant improvement of PROMs, magnesium equivalent to titanium
Morandi et al, 2013 ²¹	Chevron osteotomy of the first metatarsal stabilized with an absorbable pin: our 5-year experience	Prospective	58	Hallux valgus	Chevron	Poly lactide	255	255 patients (100%) satisfied
Boyer et al, 2003 ³⁵	Bunionette deformity correction with distal chevron osteotomy and single absorbable pin fixation	Retrospective	62	Digitus quintus varus	Chevron	Polydioxanone	10/12	10 patients (100%) satisfied
Brook et al, 2015 ³⁶	Stabilization of fifth digit derotation arthroplasty with an absorbable fixation pin	Technical note	n.a.	Hammer toe	Arthrodesis	Poly lactide		Feasible device for fifth digit derotation

Note. CMS, Coleman Methodological Score; PROMs, patient-reported outcome measures.

Table 2. Recent literature for biodegradable implants in forefoot surgery

	Implant failure on implantation	Fluid collection	Gas collection	Fistula	Soft tissue damage	Osteolysis
Magnesium	X		X		X	X
Poly lactide	X	X		X	X	
Polyglycoside	X	X		X	X	
Polydioxanone	X	X		X	X	
Human cortical bone	X					

do not offer the user as much resistance and stability and can break off.¹⁷ However, when used deliberately with less maximum torque than with conventional steel or titanium screws, magnesium screws are safe to use. These screw systems are very popular since the handling of the screw, when a conscious reduction of the maximum torque is applied, differs only slightly from the usual titanium screw (Table 1).

Human cortical bone for the production of fixation materials, especially screws, has been used for more than two decades.⁸ Sterilized human bone tissue should provide the patient's own osteoblasts with a guiding structure through the biological bone structure to bridge a fracture or osteotomy gap. In contrast to purely cancellous bone grafts for bridging defects, which primarily have to be fixed in position by conventional procedures, the cortical screw is both a fixation material and a guiding structure at the same time. This guiding structure is not resorbed, remains in place, and is colonized by osteoblasts and subsequently, osseointegrated. This distinguishes the cortical screw (Shark Screw, Surgebright GmbH, Lichtenberg bei Linz, Austria) from the bioresorbable fixation materials described above.

The cortical screw is to be used in different sizes, depending on the indication and localization. It is not self-drilling and not self-tapping and should be used in the largest possible diameter to achieve the highest possible primary stability. The main known adverse event is the lower load capacity compared to metallic implants.

The screw head should be shortened or ground down to bone level after implantation.

Discussion

Our review of recent literature shows that currently available biodegradable materials provide enough primary stability for proper usage in forefoot surgery. Despite their adequacy in fixation of small bones, they still have the potential risk of possible adverse effects. However, these adverse effects seem to be less relevant than they were before the introduction of biodegradable materials. None of the articles screened for this review reported serious adverse events caused by biodegradation. The exact course of the degradation process of bioresorbable implants is generally difficult to predict due to various

factors. Consequently, a general risk of foreign body reactions caused by biodegradable implants in forefoot surgery cannot be stated. The only exception is the osteogenic Shark Screw, for which those disadvantages have not yet been described.

Interventions suitable for biodegradable implants in forefoot surgery

Hallux valgus

The distal V-shaped osteotomy of the first metatarsal was originally described by Austin with only manual compression of the distal fragment proximally, without the use of fixation materials.¹⁸ However, to increase primary stability it is now commonly fixed by using metal screws or pins.¹⁹ A proximal protruding pin facilitates its removal under local anaesthesia, a well-countersunk screw can be left in situ. Since both variants have disadvantages, the use of bioresorbable or biointegratable osteosynthesis materials is particularly suitable in this case. Accordingly, the available data are also abundant.

In 1991, Hirvensalo et al reported on the performance of chevron osteotomy using resorbable polyglycoside pins. In this observational cohort of 78 osteotomies, no complications in the osseous healing process were observed. Clinically, postoperative findings were reported as excellent or good in 75% of patients.²⁰

Poly lactide pins were described by the large study group of Morandi et al. In 439 feet, resorbable poly lactide pins were used as the primary support for the osteotomy in chevron osteotomy, with a total complication rate of 0.7%.²¹

There is just as much data available for the use of magnesium screws. In a prospective randomized clinical trial conducted in 2013, Windhagen et al were able to show radiological and clinical equivalence in 26 patients treated with chevron osteotomy and resorbable magnesium or standard titanium screw.²² This result (magnesium vs. titanium) was confirmed by Acar et al in 2018, but this also pointed out the observed resorption effects of the magnesium screw, which should not be interpreted as lysis in the sense of loosening or infection.²³

In a prospective randomized clinical trial in 2018, Plaass et al found no statistically significant difference between bioresorbable magnesium and conventional titanium fixation in distal metatarsal osteotomy, with the advantage of

better compatibility in magnetic resonance imaging (MRI) for magnesium implants in terms of artifact formation.²⁴ Polydioxanone pins were considered safe and sufficiently stable for Mitchell osteotomy by Nikolaou et al²⁵ and Alcelik et al²⁶ in a total of 111 patients. The diaphyseal scarf osteotomy can be safely fitted with resorbable magnesium screws, according to the results of the study groups around Atkinson et al¹⁷ and Choo et al.²⁷

The osseointegrating Shark Screw is also suitable for proximal (Lapidus) and distal (Chevron/Austin) hallux procedures. Due to its osteoconductive and osteoinductive properties, this implant would be particularly suitable for patients suffering from osteoporosis or in case of revision (possible blood circulation, no foreign bodies, no resorption effects). Up to now, there are no reliable follow-up data available for this type of implant.

Hammer toe deformity

Hammer toe deformity can be treated in contract situations by resection arthroplasty or fusion of the proximal interphalangeal joint. The technique of PIP (proximal interphalangeal) fusion has been extensively described using bioresorbable materials. Conventionally, the fusion is usually held in place by a Kirschner wire that extends distally over the tip of the toe and is removed after the fusion has clinically healed (4–6 weeks). The use of bioresorbable osteosyntheses has been extensively described for this purpose.

In a biomechanical study, Pietrzak et al were able to show that a copolymer of polylactide and polyglycoside has an equivalent stability compared to the 1.57 mm Kirschner wire, which did not decrease over the test period of six weeks.²⁸ In 2007, Konkell et al presented a study group with 48 toes which were successfully treated with absorbable pins.²⁹ In 2011, the same group of authors showed a superiority of the stiffer polylactide pins over the polydioxanone pins, since angulation deviations could be avoided by the stiffer material (47 toes).³⁰ Wendelstein et al presented their own cohort with a polylactide screw in 2017 in 34 patients and concluded that the results were comparable with conventional fixation methods.³¹

Claw toe deformity

Claw toe deformities with (sub)luxation in the metatarsophalangeal joint are addressed via the retraction osteotomy of the metatarsal joint named after Weil.³² Weil's shortening osteotomy is also used in the treatment of metatarsalgia to restore a balanced alignment according to Pisani.³³

Conventional titanium screws are used to hold the osteotomy. However, these remain in situ and do not cause any significant discomfort as long as the screws do not protrude plantarily. Bioresorbable fixation material was

also described here by Morandi et al in 2009 with good results in 66 pin-fixed osteotomies performed.³⁴

Cases dealing with the successful use of the bio-integrable Shark Screw have been orally reported.

Digitus quintus varus

The Austin-V (or Chevronette) osteotomy is held conventionally, as on the first ray, by metal pins or screws. Bioresorbable materials have their place here as well, and corresponding data are available. In 2003, Boyer et al provided data on Chevron-V surgery with polydioxanone pin fixation and very good clinical results in 12 toes.³⁵ In 2015, Brook et al showed a technique of fixation with bioresorbable polylactide pins.³⁶

Decompensated rheumatic forefoot

Metatarsal head resections as the ultima ratio for correcting the decompensated rheumatically altered forefoot should be used with caution, as they lead to permanent destruction of the metatarsophalangeal joint's function. Kirschner wires are routinely used for stabilization until a sufficiently resilient scar plate has formed around the resected joint.

In 2004, Tanaka et al prospectively randomized 87 forefeet and demonstrated safe and good results with the alternative use of polylactide pins.³⁷ In 2010, Tiihonen et al were unable to find a statistically significant difference between the groups of conventional care and those with polylactide pins one year postoperatively in a population of 35 patients.³⁸

Materials, modes of degradation and their influence on adverse events

Polylactide, polyglycoside, polydioxanone

The course of degradation of the classical bioresorbable implant is significantly influenced by the implant type, manufacturing mode, sterilization method and localization.¹² Low vascularization at the treated localization, quinone dyes of the implant and a large implant surface (threaded screws) are likely to be associated with an increased risk of foreign body reactions. The cause is assumed to be either the inflammatory triggered reaction to foreign body particles during early degradation or the increasingly acidic environment during the advanced degradation process (Fig. 1).³⁹

Polyglycoside implants have been resorbed in animal models after about 3–9 months. According to available data, an accumulation of foreign body reactions is observed in these cases after about three months.^{40,41} Corresponding models in animals showed a resorption period of about 24 months for polylactides.⁴² According to current literature, no clear peak of the occurrence of foreign reactions is discernible in the case of polylactide

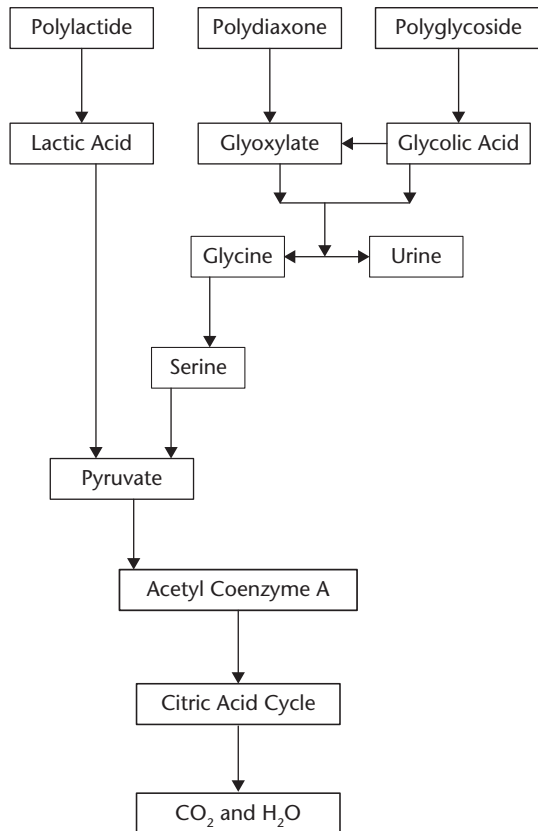


Fig. 1 Degradation of bioabsorbable materials.

implants. Reactions did not occur before the first year after implantation.¹²

Even if the rate of adverse reactions seems to be very high with conventional bioabsorbable implants, these reactions are rarely responsible for an adverse outcome or a second intervention. In contrast to metal implants, the structure of these artificially produced polymers can be adapted to current needs, so that further developments can be expected in this area. A reduction of the crystalloid foreign body formation or a controlled change of the acidic environment during the degradation process are possible starting points to prevent negative effects of bioabsorbable implants.

Magnesium

Magnesium-based implants are degraded by corrosion, the formation of highly soluble magnesium chloride, hydrogen gas and therefore a relevant change in the environment of the surrounding tissue. The corrosion reduces the local inflammatory reaction in the bone as well as the irritation in the surrounding tissue and therefore leads to less osteolysis. Gas bubbles may be responsible for separation of tissue layers and subcutaneous irritation but disappear within weeks after initial surgery.⁴³ A model study showed complete resorption after 12 months with normal

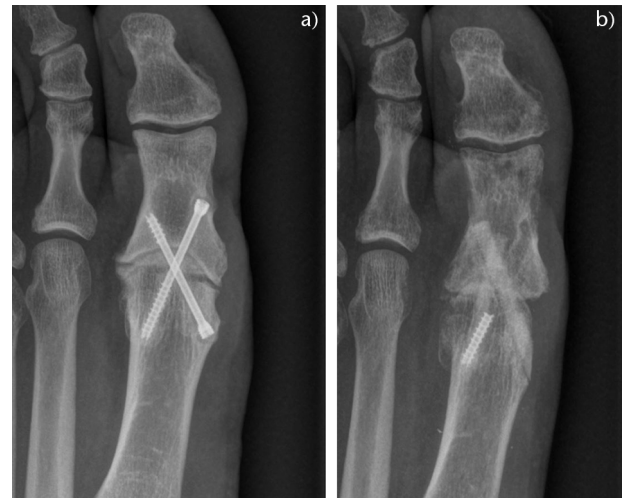

Fig. 2 Pseudarthrosis in a 48-year-old male five years after MTP-1 (first metatarsal-phalangeal) arthrodesis with a titanium screw (a, left). Solution with two cortical screws three months after revision surgery (b, right).

bone architecture.⁴⁴ In humans, complete resorption is expected after 2–3 years.⁴⁵ Full stability of the implant can be expected for up to 12 weeks.⁴⁶ The hydrogen produced by the magnesium implant's corrosion can be deposited in the surrounding bone and soft tissue and cause a temporary radiolucency or soft tissue reaction, which, according to available literature, has no consequences.⁴⁴

Allograft bones

Since the Shark Screw is not subject to resorption per se but to osseointegration, extensive lytic processes are not expected here. Long-term data are still needed in this respect.

Homologous cortical screws provide the bone with a biological lead structure for osteoblasts to bridge the defect of the osteotomy after osteosynthesis. The presence of Haversian channels leads to vascularization, colonization and revitalization of the sterilized and freeze-dried implant and osseointegration. According to current clinical and radiological knowledge, the bone screw is identifiable after six weeks, but after one year, it is expected to be no longer visible on a plain X-ray. Due to the lack of dissolution processes and the resulting absence of degradation products, no tissue reactions caused by this implant are to be expected and neither have these been described (Fig. 2).

Conclusion

Bioresorbable and osseointegrating materials offer considerable advantages for the patient and the treating surgeon. Besides economic aspects, such as the elimination of a second operation to remove fixation materials and

difficulties caused by material residues during a second operation, there are also health aspects, such as the avoidance of foreign body reactions, a feeling of alienation and the avoidance of pseudoarthrosis and adverse reactions to metal and metal debris. However, despite all of the advantages mentioned, the possible difficulties and known complications must not be forgotten. These include granulomas, soft tissue damage, osteolysis and a reduced primary mechanical load capacity. Whether the advantages outweigh the disadvantages in a case of forefoot surgery should be determined by high-quality research, which is currently still missing.

AUTHOR INFORMATION

Department for Orthopaedics and Traumatology, Kepler University Hospital GmbH, Johannes Kepler University Linz, Linz, Austria.

Correspondence should be sent to: Dr. Lorenz Pisecky, Johannes Kepler University Linz, Kepler University Hospital GmbH, Department for Orthopedics and Traumatology, Altenberger Strasse 96, 4040 Linz and Krankenhausstraße 9, 4020 Linz, Austria.

Email: Lorenz.pisecky@kepleruniklinikum.at

ACKNOWLEDGEMENT

Supported by Johannes Kepler Open Access Publishing Fund

ICMJE CONFLICT OF INTEREST STATEMENT

The authors declare no conflict of interest relevant to this work.

FUNDING STATEMENT

No benefits in any form have been received or will be received from a commercial party related directly or indirectly to the subject of this article.

OPEN ACCESS

© 2021 The author(s)

This article is distributed under the terms of the Creative Commons Attribution-Non Commercial 4.0 International (CC BY-NC 4.0) licence (<https://creativecommons.org/licenses/by-nc/4.0/>) which permits non-commercial use, reproduction and distribution of the work without further permission provided the original work is attributed.

REFERENCES

1. Mäkelä EA, Böstman O, Kekomäki M, et al. Biodegradable fixation of distal humeral physeal fractures. *Clin Orthop Relat Res* 1992;283:237–243.
2. Juutilainen T, Pätäilä H, Rokkanen P, Törmälä P. Biodegradable wire fixation in olecranon and patella fractures combined with biodegradable screws or plugs and compared with metallic fixation. *Arch Orthop Trauma Surg* 1995;114:319–323.
3. Stroud CC. Absorbable implants in fracture management. *Foot Ankle Clin* 2002;7:495–499.
4. Illi OE, Weigum H, Misteli F. Biodegradable implant materials in fracture fixation. *Clin Mater* 1992;10:69–73.
5. Kulkarni RK, Moore EG, Hegyeli AF, Leonard F. Biodegradable poly(lactic acid) polymers. *J Biomed Mater Res* 1971;5:169–181.
6. Coleman BD, Khan KM, Maffulli N, Cook JL, Wark JD; Victorian Institute of Sport Tendon Study Group. Studies of surgical outcome after patellar tendinopathy: clinical significance of methodological deficiencies and guidelines for future studies. *Scand J Med Sci Sports* 2000;10:2–11.
7. Macdonald P, Arneja S. Biodegradable screw presents as a loose intra-articular body after anterior cruciate ligament reconstruction. *Arthroscopy* 2003;19:E22–E24.
8. Obwegeser JA. Bioconvertible screws made of allogenic cortical bone for osteosynthesis following sagittal split ramus osteotomy without postoperative immobilisation. *J Craniomaxillofac Surg* 1994;22:63–75.
9. Wagner FC, Polossek L, Yilmaz T, et al. Biodegradable magnesium vs. polylactide pins for radial head fracture stabilization: a biomechanical study. *J Shoulder Elbow Surg* 2021;30:365–372.
10. Kilicoglu O, Demirhan M, Akman S, Atalar AC, Ozsoy S, Ince U. Failure strength of bioabsorbable interference screws: effects of in vivo degradation for 12 weeks. *Knee Surg Sports Traumatol Arthrosc* 2003;11:228–234.
11. Ezechieli M, Ettinger M, König C, et al. Biomechanical characteristics of bioabsorbable magnesium-based (MgYREzr-alloy) interference screws with different threads. *Knee Surg Sports Traumatol Arthrosc* 2016;24:3976–3981.
12. Ambrose CG, Clanton TO. Bioabsorbable implants: review of clinical experience in orthopedic surgery. *Ann Biomed Eng* 2004;32:171–177.
13. Casteleyn PP, Handelberg F, Haentjens P. Biodegradable rods versus Kirschner wire fixation of wrist fractures: a randomised trial. *J Bone Joint Surg [Br]* 1992;74-B:858–861.
14. Tuompo P, Paritio EK, Pätäilä H, Jukkala-Partio K, Hirvensalo E, Rokkanen P. Causes of the clinical tissue response to polyglycolide and polylactide implants with an emphasis on the knee. *Arch Orthop Trauma Surg* 2001;121:261–264.
15. Böstman O, Hirvensalo E, Vainionpää S, et al. Ankle fractures treated using biodegradable internal fixation. *Clin Orthop Relat Res* 1989;238:195–203.
16. Böse D, Eggebrecht H, Haude M, Schmermund A, Erbel R. First absorbable metal stent implantation in human coronary arteries. *Am Heart Hosp J* 2006;4:128–130.
17. Atkinson HD, Khan S, Lashgari Y, Ziegler A. Hallux valgus correction utilising a modified short scarf osteotomy with a magnesium biodegradable or titanium compression screws: a comparative study of clinical outcomes. *BMC Musculoskelet Disord* 2019;20:334.
18. Austin DW, Leventen EO. A new osteotomy for hallux valgus: a horizontally directed 'V' displacement osteotomy of the metatarsal head for hallux valgus and primus varus. *Clin Orthop Relat Res* 1981;157:25–30.
19. Galois L. History of surgical treatments for hallux valgus. *Eur J Orthop Surg Traumatol* 2018;28:1633–1639.
20. Hirvensalo E, Böstman O, Törmälä P, Vainionpää S, Rokkanen P. Chevron osteotomy fixed with absorbable polyglycolide pins. *Foot Ankle* 1991;11:212–218.
21. Morandi A, Ungaro E, Fraccia A, Sansone V. Chevron osteotomy of the first metatarsal stabilized with an absorbable pin: our 5-year experience. *Foot Ankle Int* 2013;34:380–385.
22. Windhagen H, Radtke K, Weizbauer A, et al. Biodegradable magnesium-based screw clinically equivalent to titanium screw in hallux valgus surgery: short term results of the first prospective, randomized, controlled clinical pilot study. *Biomed Eng Online* 2013;12:62.
23. Acar B, Kose O, Turan A, Unal M, Kati YA, Guler F. Comparison of bioabsorbable magnesium versus titanium screw fixation for modified distal chevron osteotomy in hallux valgus. *BioMed Res Int* 2018;2018:5242806.

24. **Plaass C, von Falck C, Ettinger S, et al.** Bioabsorbable magnesium versus standard titanium compression screws for fixation of distal metatarsal osteotomies: 3 year results of a randomized clinical trial. *J Orthop Sci* 2018;23:321–327.
25. **Nikolaou VS, Korres D, Xypnitos F, et al.** Fixation of Mitchell's osteotomy with bioabsorbable pins for treatment of hallux valgus deformity. *Int Orthop* 2009;33:701–706.
26. **Alcelik I, Alnaib M, Pollock R, Marsh DJ, Tulloch CJ.** Bioabsorbable fixation for Mitchell's bunionectomy osteotomy. *J Foot Ankle Surg* 2009;48:9–14.
27. **Choo JT, Lai SHS, Tang CQY, Thevendran G.** Magnesium-based bioabsorbable screw fixation for hallux valgus surgery: a suitable alternative to metallic implants. *Foot Ankle Surg* 2019;25:727–732.
28. **Pietrzak WS, Lessek TP, Perns SV.** A bioabsorbable fixation implant for use in proximal interphalangeal joint (hammer toe) arthrodesis: biomechanical testing in a synthetic bone substrate. *J Foot Ankle Surg* 2006;45:288–294.
29. **Konkel KF, Menger AG, Retzlaff SA.** Hammer toe correction using an absorbable intramedullary pin. *Foot Ankle Int* 2007;28:916–920.
30. **Konkel KF, Sover ER, Menger AG, Halberg JM.** Hammer toe correction using an absorbable pin. *Foot Ankle Int* 2011;32:973–978.
31. **Wendelstein JA, Goger P, Bock P, Schuh R, Doz P, Trnka HJ.** Bioabsorbable fixation screw for proximal interphalangeal arthrodesis of lesser toe deformities. *Foot Ankle Int* 2017;38:1020–1025.
32. **Barouk P, Bohay DR, Trnka HJ, Weil LS Sr, Weil L Jr.** Lesser metatarsal surgery. *Foot Ankle Spec* 2010;3:356–360.
33. **Pisani G.** *Trattato di chirurgia del piede.* Torino: Edizione Minerva Medica, 1993.
34. **Morandi A, Duplicato P, Sansone V.** Results of distal metatarsal osteotomy using absorbable pin fixation. *Foot Ankle Int* 2009;30:34–38.
35. **Boyer ML, Deorio JK.** Bunionette deformity correction with distal chevron osteotomy and single absorbable pin fixation. *Foot Ankle Int* 2003;24:834–837.
36. **Brook JW, Drake MJ.** Stabilization of fifth digit derotation arthroplasty with an absorbable fixation pin. *J Foot Ankle Surg* 2015;54:1116–1118.
37. **Tanaka N, Hirose K, Sakahashi H, Ishima T, Ishii S.** Usefulness of bioabsorbable thread pins after resection arthroplasty for rheumatoid forefoot reconstruction. *Foot Ankle Int* 2004;25:496–502.
38. **Tiihonen R, Skyttä ET, Ikävalko M, Kaarela K, Belt E.** Comparison of bioresorbable interposition arthroplasty with metatarsal head resection of the rheumatoid forefoot. *Foot Ankle Int* 2010;31:505–510.
39. **Ciccione WJ II, Motz C, Bentley C, Tasto JP.** Bioabsorbable implants in orthopaedics: new developments and clinical applications. *J Am Acad Orthop Surg* 2001;9:280–288.
40. **Päivärinta U, Böstman O, Majola A, Toivonen T, Törmälä P, Rokkanen P.** Intraosseous cellular response to biodegradable fracture fixation screws made of polyglycolide or polylactide. *Arch Orthop Trauma Surg* 1993;112:71–74.
41. **Peltoniemi H, Ashammakhi N, Kontio R, et al.** The use of bioabsorbable osteofixation devices in craniomaxillofacial surgery. *Oral Surg Oral Med Oral Pathol Oral Radiol Endod* 2002;94:5–14.
42. **Weiler A, Hoffmann RF, Bail HJ, Rehm O, Südkamp NP.** Tendon healing in a bone tunnel. Part II: histologic analysis after biodegradable interference fit fixation in a model of anterior cruciate ligament reconstruction in sheep. *Arthroscopy* 2002;18:124–135.
43. **Chakraborty Banerjee P, Al-Saadi S, Choudhary L, Harandi SE, Singh R.** Magnesium implants: prospects and challenges. *Materials (Basel)* 2019;12:E136.
44. **Waizy H, Diekmann J, Weizbauer A, et al.** In vivo study of a biodegradable orthopedic screw (MgYREZr-alloy) in a rabbit model for up to 12 months. *J Biomater Appl* 2014;28:667–675.
45. **Witte F, Kaese V, Haferkamp H, et al.** In vivo corrosion of four magnesium alloys and the associated bone response. *Biomaterials* 2005;26:3557–3563.
46. **Biber R, Pauser J, Geblein M, Bail HJ.** Magnesium-based absorbable metal screws for intra-articular fracture fixation. *Case Rep Orthop* 2016;2016:9673174.
47. **Kim JS, Cho HK, Young KW, Lee SY, Kim JS, Lee K.** Effectiveness of Headless Bioabsorbable Screws for Fixation of the Scarf Osteotomy. *Foot Ankle Int.* 2016;37:1189–1196