

Mucormycosis of Pouch of Douglas in a Diabetic Woman

Palash K Mondal, Santosh K Mondal, Tanmoy K Mondal¹, Puranjay Saha²

Department of Pathology, Medical College, Kolkata, ¹Department of Gynecology and Obstetrics, Burdwan Medical College, ²Department of Microbiology, Medical College, Kolkata, West Bengal, India

ABSTRACT

Mucormycosis is a severe fungal infection which is rare in clinical practice. This infection is usually acquired by inhalation; other portals of entry are ingestion and traumatic implantation, especially in immuno-compromised patients. Here, we present a case of mucormycosis in a 44-year-old diabetic woman. The patient had collection of fluid in the Pouch of Douglas (POD) and history of bleeding per vagina. Hysterectomy was done which showed a blackish serosal surface of the posterior uterus. Subsequent investigations revealed mucormycosis caused by *Rhizopus oryzae* (*R. arrhizus*) affecting the POD. Patient was treated with liposomal amphotericin B and is now keeping well.

Key words: Diabetes mellitus, Mucormycosis, Pouch of Douglas

INTRODUCTION

Mucormycosis is an uncommon, opportunistic fungal infection caused by Mucorales containing the genera *Rhizopus*, *Mucor*, and *Rhizomucor*, among others. It usually affects immunocompromised persons.^[1] Risk factors for acquiring this infection include uncontrolled diabetes mellitus, hematologic disorder, hematopoietic, or solid organ stem cell transplantation, surgery/trauma, burn wounds, corticosteroid therapy, autoimmune disorder, and HIV infection. Mucormycosis is certainly less common than candidiasis or aspergillosis. In a population based study in the United States, the incidence of mucormycosis is found to be 1.7 cases per million people per year. The death rate of mucormycosis from autopsy series has been found to be 1-5 cases/10 000 autopsies which is 10 to 50-fold less common than invasive *Candida* or *Aspergillus* infections. But in patients with higher risks such as diabetes, allogenic bone marrow transplantation etc. the prevalence of mucormycosis is found to be as high as 2-3%.^[2] Recent studies have shown an increase in the incidence of this infection in the United States of America and Europe. The rise may be due to better diagnostic facilities, increase

in the incidence of diabetes mellitus, and HIV infection; and also the use of immunosuppressive drugs in modern therapeutics.

CASE REPORT

A 44-year-old woman presented with abdominal pain and fever for the last 3 months and irregular bleeding per vagina for 3 years. The lady was a known diabetic for 12 years. Routine examination revealed hemoglobin 9.1 gm/dl, total white blood cell count 11 200/mm³ with neutrophil 77%, lymphocyte 18%, eosinophil 4%, and monocyte 1%. Platelet was adequate (2.7 lacs/mm³). Fasting blood sugar was 170 mg/dl and post prandial blood sugar was 230 mg/dl. HbA1C was 9.7 on admission. The patient did not take any antibiotic or antifungal therapy during this period. Physical examination revealed pallor and rise in temperature. Chest was clear and liver and spleen were not palpable. Per vaginal examination revealed bulging and tender Pouch of Douglas. (POD) Ultrasonography (USG) showed fluid collection (30 ml) in the POD, and thickened peritoneal covering over the posterior aspect of uterus. No organomegaly or other abnormality was found during whole abdominal USG examination. Colposcopic examination was done and fluid from POD was taken out for cytologic examination and to rule out malignancy.

Cytologic smears revealed inflammatory cells with a predominance of lymphocytes. No malignant cell was

Access this article online

Quick Response Code:



Website:
www.jgid.org

DOI:
10.4103/0974-777X.100577

Address for correspondence:

Dr. Santosh K Mondal, E-mail: dr_santoshkumar@hotmail.com

detected. Broad spectrum antibiotics were given to the patient but of no avail. A decision of hysterectomy was taken as the patient was suffering from dysfunctional uterine bleeding for a long time (3 years) and her family was complete. Grossly, the uterus measured $9.5 \times 6 \times 4.5$ cm³. Posterior outer surface was blackish with variegated appearance [Figure 1]. Tissue taken from that blackish area was sent for culture examination and remaining tissue was fixed in formalin and sent for histopathologic examination. Microscopical examination revealed fungal elements (hyphae?) in the myometrium and predominantly in the serosal layer in hematoxylin and eosin stain. No granuloma was detected. Special stain like methanamine silver stain (Grocott) was done which showed broad aseptate, right angle branching, ribbon like hyphae of mucormycosis [Figure 2]. Culture of the tissue on Sabouraud dextrose agar showed fluffy white growth and the organism was identified as *Rhizopus oryzae* (*R. arrhizus*). In our case the patient was given liposomal amphotericin B 5 mg/kg/day for 1 month along with a broad-spectrum antibiotic meropenem 1 gm q 8 h for 2 weeks. At the same time, she was given insulin to control diabetes. After treatment the patient recovered well and now is doing routine work.

DISCUSSION

Mucorales, the infective agent causing mucormycosis are present in soil, decaying material, bread, fruit, and usually non-infective to normal human beings. They attack the immunocompromised persons.^[3] Invasive mucormycosis is classified into six different clinical syndromes depending on the anatomic location of the disease. These are: rhino-cerebral, pulmonary, gastrointestinal, cutaneous, disseminated, and miscellaneous.^[4] Rhinocerebral is the most common form, followed by pulmonary infection.

Mucormycosis of the POD is extremely rare and we did not find any such case in English literature till date.

Intact mucosa and endothelium in normal persons act as barrier to this infection and prevent tissue invasion and angioinvasion. Likewise, mucormycosis is rarely seen in patients who have apparently normal skin. Primary cutaneous mucormycosis (zygomycosis) is seen when skin is disrupted (like burns, soft tissue trauma, etc.) in immunocompromised persons and in premature neonates. Disseminated mucormycosis has the worst prognosis and mortality rate approaches 100%.^[4] Mucormycosis can infect any part of the body and cases have been reported in parotid gland, ear, spinal cord, knee joint, urinary tract, genital organs, and the pelvic floor.^[5] In our case, the patient was diabetic, which is a known major risk factor for mucormycosis. Instrumental trauma (during fluid collection laparoscopic/colposcopic) might predispose the diabetic patient to acquire this infection. A high percentage (45%) of co-infection with *Aspergillus* species has been reported.^[6] But in our case, no such co-infection has been found. Moreover, epithelioid granulomas in mucormycosis as reported by others were also absent in this case.^[4] In our case the patient had uncontrolled diabetes (Hb A_{1c} 9.7, fasting sugar 170 mg/dl, and PP blood sugar 230 mg/dl) which might be a risk factor to acquire this fungal infection. But a decreasing number of published mucormycosis since 1990 in patients with diabetes mellitus was reported by some authors. This might be due to better glycemic control and decreasing rates of diabetic ketoacidosis and widespread use of statins.^[7] However, diabetes mellitus and hematologic disorder/malignancy remain major risk factors for mucormycosis.^[8]

Diagnosis of mucormycosis is a challenging job as clinical manifestations are extremely variable. In the

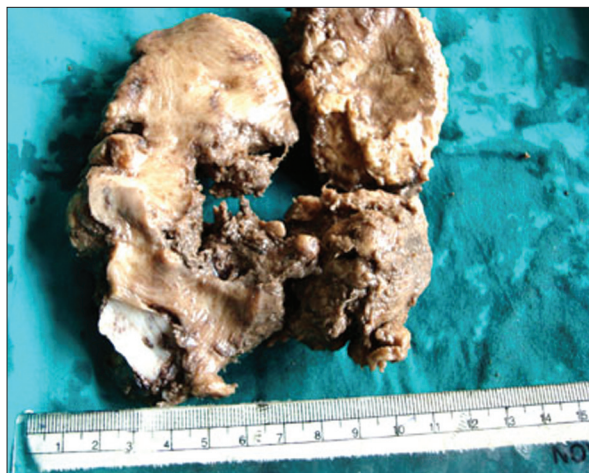


Figure 1: Gross photograph of uterus showing blackish variegated posterior/serosal surface

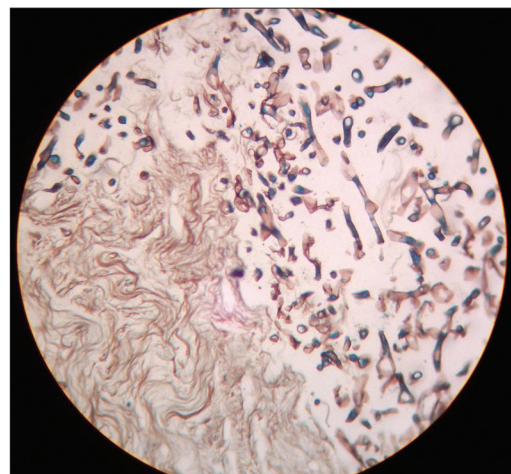


Figure 2: Photomicrograph showing broad aseptate, ribbon like hyphae of mucormycosis. (Grocott silver methanamine stain, x400)

early stage, the infection is undiagnosed most of the time due to clinical non-suspicion of this rare disease. Routine hematologic findings are non-specific such as leukocytosis, acidosis, or hyperglycemia. Serological tests are of no use. Blood culture reports are usually negative though rarely fungal growth in the blood (fungaemia) has been reported. Obtaining tissue biopsy from the affected area is important to diagnose these cases. Special stains (silver stain, periodic, acid Schiff) are used to confirm the fungal elements.

Medical textbooks and literature highlight three important aspects regarding treatment of mucormycosis. These are (1) reversal of risk factors/underlying conditions, (2) medical therapy, and (3) surgical debridement.^[9] Both conventional and liposomal amphotericin B are effective against Mucor, but the liposomal form offers less infusion site side effects and less nephrotoxicity. The duration of therapy varies from weeks to months.^[9,10] In our case the patient was given liposomal amphotericin B 5 mg/kg/day for 1 month along with a broadspectrum antibiotic meropenem 1 gm q 8 h for 2 weeks.

CONCLUSION

Invasive mucormycosis is gaining more grounds and commonly seen in immunocompromised persons. Early tissue diagnosis along with culture is an important part of diagnostic work up. Adequate resection/debridement of infected tissue and rapid initiation of a systemic antifungal

therapy should be started immediately as mortality rate of this infection is very high.

REFERENCES

1. Sugar AM. Agents of mucormycosis and related species. In: Mandell GL, Bennett GL, Bennett JE, Dolin R. editors. Mandell, Douglas and Bennett's principles and practice of infectious diseases. 5th ed. Philadelphia: Churchill Livingstone; 2000. p. 2685-95.
2. Spellberg B, Edwards J Jr, Ibrahim A. Novel Perspectives on Mucormycosis: Pathophysiology, Presentation and Management. Clin Microbiol Rev 2005;18:556-69.
3. Lo OS, Law WL. Ileocolonic mucormycosis in adult immunocompromised patients: A surgeon's perspective. World J Gastroenterol 2010;16:1165-70.
4. Waness A, Dawsari GA, Jahdali HA. The rise of an opportunistic infection called "Invasive Zygomycosis". J Glob Infect Dis 2009;1:131-8.
5. Williams JC, Schned AR, Richardson JR, Heaney JA, Curtis MR, Rupp IP, *et al.* Fatal genitourinary mucormycosis in a patient with diagnosed diabetes. Clin Infect Dis 1995;21:682-4.
6. Sageman V, Maertens J, Meersseman W, Spriet I, Verbeken E, Lagrou K. Increasing incidence of mucormycosis in University Hospital, Belgium. Emerg Infect Dis 2010;16:1456-58.
7. Kontoyiannis DP. Decrease in the number of reported cases of zygomycosis among patients with diabetes mellitus: A hypothesis. Clin Infect Dis 2007;44:1089-90.
8. Roden MM, Zaoutis TE, Buchanan WL, Knudson TA, Sarkisova TA, Schaufele RL, *et al.* Epidemiology and outcome of zygomycosis: A review of 929 reported cases. Clin Infect Dis 2005;41:634-53.
9. Rogers TR. Treatment of zygomycosis: Current and new options. J Antimicrob Chemother 2008;61:35-40.
10. Konotoyiannis DP, Lewis RE. Invasive zygomycosis: Update on pathogenesis, clinical manifestations and management. Infect Dis Clin North Am 2006;20:581-607.

How to cite this article: Mondal PK, Mondal SK, Mondal TK, Saha P. Mucormycosis of Pouch of Douglas in a diabetic woman. J Global Infect Dis 2012;4:172-4.

Source of Support: Nil. **Conflict of Interest:** None declared.

Author Help: Reference checking facility

The manuscript system (www.journalonweb.com) allows the authors to check and verify the accuracy and style of references. The tool checks the references with PubMed as per a predefined style. Authors are encouraged to use this facility, before submitting articles to the journal.

- The style as well as bibliographic elements should be 100% accurate, to help get the references verified from the system. Even a single spelling error or addition of issue number/month of publication will lead to an error when verifying the reference.
- Example of a correct style
Sheahan P, O'leary G, Lee G, Fitzgibbon J. Cystic cervical metastases: Incidence and diagnosis using fine needle aspiration biopsy. Otolaryngol Head Neck Surg 2002;127:294-8.
- Only the references from journals indexed in PubMed will be checked.
- Enter each reference in new line, without a serial number.
- Add up to a maximum of 15 references at a time.
- If the reference is correct for its bibliographic elements and punctuations, it will be shown as CORRECT and a link to the correct article in PubMed will be given.
- If any of the bibliographic elements are missing, incorrect or extra (such as issue number), it will be shown as INCORRECT and link to possible articles in PubMed will be given.