

Characteristic Linear and Zigzag Purpuric Lesions in a Patient with Long-term and Repeated Exposure to Bedbug Bites

Akihiro ORITA, Toshinari MIYAUCHI*, Inkin UJIIE and Hideyuki UJIIE

Department of Dermatology, Faculty of Medicine and Graduate School of Medicine, Hokkaido University, N15W7, Kita-Ku, Sapporo, 060-8638, Japan. *E-mail: miyauchi@med.hokudai.ac.jp

Accepted Feb 23, 2022; Epub ahead of print Feb 23, 2022

Acta Derm Venereol 2022; 102: adv00661. DOI: 10.2340/actadv.v102.753

Bedbugs are bloodsucking arthropods of the order Hemiptera and family Cimicidae (1, 2). *Cimex lectularius*, which has a cosmopolitan distribution, and *Cimex hemipterus*, the tropical bedbug, are the 2 main species that most often bite humans (1, 2). Reactions to bedbug bites are varied, but the most common manifestations are erythematous papules or wheals on the exposed areas (1–4). Histopathological findings, which are also non-specific, are usually perivascular inflammatory infiltrates with lymphocytes and numerous eosinophils in the dermis (1). We report here a case with atypical clinicopathological reactions which may have been due to long-term and repeated exposure to bedbug bites against the backdrop of the patient's mental health disorder.

CASE REPORT

A 57-year-old man was referred to our department with a 5-year history of disseminated purpura characterized by exacerbations in summer and remissions in winter. He has schizophrenia and had been taking antipsychotics for many years. Physical examination revealed barely palpable and slightly itchy purpura disseminated over the trunk and extremities. Some of the purpura were in 2–4 lesion clusters and distributed in linear or zigzag patterns (Fig. 1a–c). Histological findings from a lesion showed leukocytoclastic vasculitis with perivascular neutrophils, eosinophil infiltration, and red blood cell extravasation (Fig. 1d). Although

IgA vasculitis was suspected as a differential diagnosis, direct immunofluorescence was negative for immunoglobulin (Ig)A, IgG, IgM and C3. The next time he came to our hospital, he brought a few bugs from his room, which we identified as bedbugs. As a visit to his home revealed a major infestation of bedbugs (Fig. 2), we requested experts to exterminate them. After that, all eruptions regressed and have not recurred. Based on this clinical course, we diagnosed the patient with bedbug bites.

DISCUSSION

Although erythematous papules or wheals are typical presentations of bedbug bites, most of this patient's lesions were purpura. Lundin et al. (5) reported a case of bedbug bites showing petechial rash in a patient taking aspirin, clopidogrel and warfarin. Clinical presentation of that case was very similar to ours, and was concluded to be due to hundreds of bedbug bites exacerbated by the patient's triple antiplatelet/anticoagulation therapy. However, these types of agents had not been used in our case. According to our patient, eruptions were slightly more pruritic around 5 years ago when the symptoms first appeared. It is only a matter of speculation, but the repeated exposure to bedbug bites over several years may have desensitized the patient to allergic reactions and made him less likely to develop general reactions. As there is little information available on desensitisation

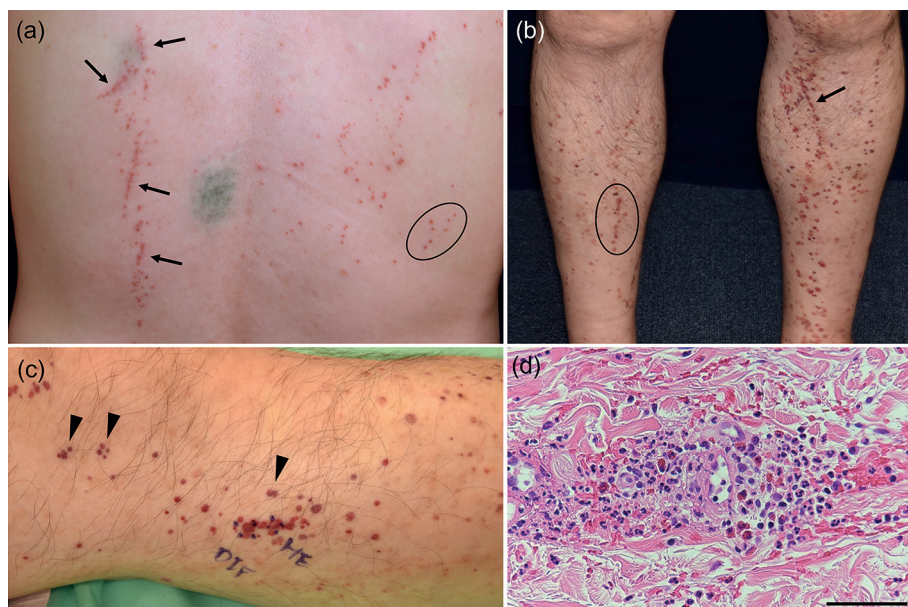


Fig. 1. (a–c) Barely palpable and slightly itchy purpura on (a) the back and (b, c) lower legs. These lesions were arranged in linear (arrows) and zigzag patterns (circles). And some were in 2–4 lesions clusters (arrowheads). (d) Pathological findings of leukocytoclastic vasculitis were observed (haematoxylin and eosin staining, scale bar = 50 μm).




Fig. 2. (a) Male and female adult bedbugs, *Cimex lectularius*, sampled from the patient's room. (b–d) A large number of bedbugs, eggs, and dark faecal spots were found (b) around the patient's bed and (c, d) on the adjacent wall.

to bedbug bites (6), this remains a matter for debate and further study. The manifestations observed in this case can be identified as a result of long-term exposure to bedbug bites. However, this kind of clinical course is generally very rare, as sufferers usually receive assessment and treatment from dermatologists at an early stage. In this context, the presence of schizophrenia and other mental health disorders in a patient's medical history is especially important. In fact, some previous papers have reported that patients with bedbug infestations were more likely to have schizophrenia (7). Our patient was aware of the presence of bedbugs, but could not acknowledge that they were the cause of his symptoms.

Although the clinical presentation of purpura made the diagnosis very challenging in this case, it also drew our attention to a characteristic indicator referred to as the “breakfast, lunch, and dinner” sign (3, 4, 8, 9), an important factor to consider when suspecting the involvement of bloodsucking arthropods. These findings are not always present and often unclear due to the surrounding erythematous changes or scratch marks. Despite

the presence of this sign, it is highly unlikely that we would have been able to make an accurate diagnosis if the patient had not brought the bedbugs to the hospital.

In summary, clinical presentation due to long-term bedbug bites can feature purpura. Evaluating the distribution of eruptions and detailed medical history-taking, including mental health disorders, are vital in making a correct diagnosis.

ACKNOWLEDGEMENTS

The patient in this manuscript provided written informed consent to publication of this case details. We are most grateful to Dr Shunji Miyachi for his support and insights on bedbugs and their data acquisition.

The authors have no conflicts of interest to declare.

REFERENCES

1. Doggett SL, Dwyer DE, Peñas PF, Russell RC. Bed bugs: clinical relevance and control options. *Clin Microbiol Rev* 2012; 25: 164–192.
2. Goddard J, DeShazo R. Bed bugs (*Cimex lectularius*) and clinical consequences of their bites. *JAMA* 2009; 301: 1358–1366.
3. Ibrahim O, Syed UM, Tomecki KJ. Bedbugs: helping your patient through an infestation. *Cleve Clin J Med* 2017; 84: 207–211.
4. Parola P, Izri A. Bedbugs. *N Engl J Med* 2020; 382: 2230–2237.
5. Lundin MS, Messenger GG. Petechial cimicosis in a patient on aspirin 81 mg, clopidogrel and warfarin. *BMJ Case Rep* 2019; 12: e231266.
6. Usinger RL. Reaction of the host. In: Monograph of Cimicidae (Hemiptera-Heteroptera) Stone A, Williams RW, Arnett Jr RH, et al., editors), volume 7. College Park: Entomological Society of America, 1966; 37–39.
7. Sheele JM. Associations Between bed bugs and mental illness among emergency department patients. *Cureus* 2021; 13: e15024.
8. Alexander JO. Feeding habits. In: *Arthropods and human skin*, 1st edition. London: Springer London; 1984: p. 66–67.
9. Peres G, Yugar LBT, Haddad Junior V. Breakfast, lunch, and dinner sign: a hallmark of flea and bedbug bites. *An Bras Dermatol* 2018; 93: 759–760.