

# Laparoscopic Removal of Migrated Intrauterine Device Embedded in Intestine

Amir A. Rahnemai-Azar, MD, Tehilla Apfel, BA, Rozhin Naghshizadian, MA,  
John Morgan Cosgrove, MD, Daniel T. Farkas, MD

## ABSTRACT

**Introduction:** The intrauterine device (IUD) is a popular family planning method worldwide. Some of the complications associated with insertion of an IUD are well described in the literature. The frequency of IUD perforation is estimated to be between 0.05 and 13 per 1000 insertions. There are many reports of migrated intrauterine devices, but far fewer reports of IUDs which have penetrated into the small intestine.

**Case Description:** Herein we report a case of perforated intrauterine device embedded in the small intestine. By using a wound protector retraction device, and fashioning the anastomosis extra-corporeally, we were able to more easily perform this laparoscopically. This left the patient with a quicker recovery, and a better cosmetic result.

**Discussion:** IUD perforation into the peritoneal cavity is a known complication, and necessitates close follow-up. Most, if not all, should be removed at the time of diagnosis. In the majority of previously reported cases, removal was done through laparotomy. Even in cases where removal was attempted laparoscopically, many were later converted to laparotomy. Surgeons should be aware of different techniques, including using a wound protector retraction device, in order to facilitate laparoscopic removal.

**Key Words:** Intrauterine device, Migration, Laparoscopy, Small intestine.

## INTRODUCTION

The intrauterine device (IUD) is a long-acting reversible contraceptive device. Worldwide, it is a mainstay of family planning, but in the United States, it has only recently become more popular, with an estimated rate of use of 1.3% in 2002,<sup>1</sup> rising to 5.3% in 2006–2010.<sup>2</sup> Although IUD use offers the benefits of being low in cost, long lasting, highly effective, and reversible,<sup>3</sup> it is not risk free.

Insertion of an IUD is associated with complications such as abdominal pain, pelvic inflammatory disease, expulsion, retraction into the cervix or uterus, and uterine perforation.<sup>3,4</sup> The frequency of uterine perforation is estimated to be between 0.05 and 13 per 1000 insertions.<sup>4,5</sup> This complication appears to be associated with the type of device (higher rates occur with copper-containing IUDs), time of insertion (higher rates occur in lactating women), skill of the operator, position of the uterus (higher rates occur in retroverted uteri), and degree of follow-up.<sup>4,6,7</sup>

Most perforations occur at the time of insertion, but partial perforation with subsequent delayed complete perforation may also occur.<sup>8</sup> Patients may present with pregnancy or lost strings or may remain asymptomatic for years.<sup>4,6</sup> A common presentation, however, is one of abdominal pain, diarrhea, and fever.

Perforation is most commonly seen through the posterior wall of the uterus. Perforations may be partial, with some portion of the device remaining within the endometrial cavity, or complete, with the device passing wholly into the peritoneal cavity.<sup>5</sup> In 15% of cases, perforated IUDs may embed or invade adjacent visceral organs, with the intestine most often affected.<sup>4,6</sup> The migrated IUD can cause fibrosis, perforation and obstruction of the large and small bowel, mesenteric penetration, bowel infarction, rectal strictures, and rectouterine fistula.<sup>9</sup>

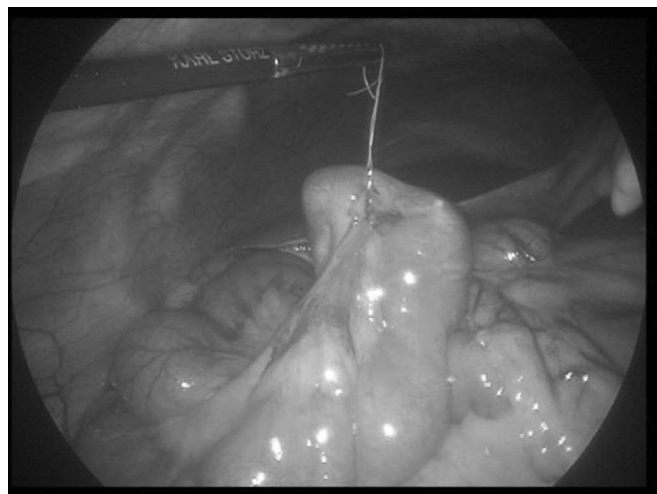
Traditionally, ectopic IUDs were not removed in asymptomatic patients; however, today, most experts advise removal of any perforated IUD.<sup>10</sup> If an IUD is found within the peritoneal cavity or deeply embedded in the myometrium, laparoscopy is indicated to allow for adequate removal.<sup>5,11</sup> In cases in which the IUD has penetrated adjacent organs, the increased complexity of the case can lead to laparoscopy not being an option, necessitating a lapa-

Department of Surgery, Bronx-Lebanon Hospital Center, Albert Einstein College of Medicine, Bronx, NY, USA (all authors).

Address correspondence to: Daniel T. Farkas, MD, Department of Surgery, Bronx-Lebanon Hospital Center, Albert Einstein College of Medicine, 1650 Selwyn Ave, Bronx, NY 10457, USA. Telephone: (718) 960-1225, E-mail: dfarkas@bronxleb.org

DOI: 10.4293/JSLS.2014.00122

© 2014 by JSLS, *Journal of the Society of Laparoendoscopic Surgeons*. Published by the Society of Laparoendoscopic Surgeons, Inc.



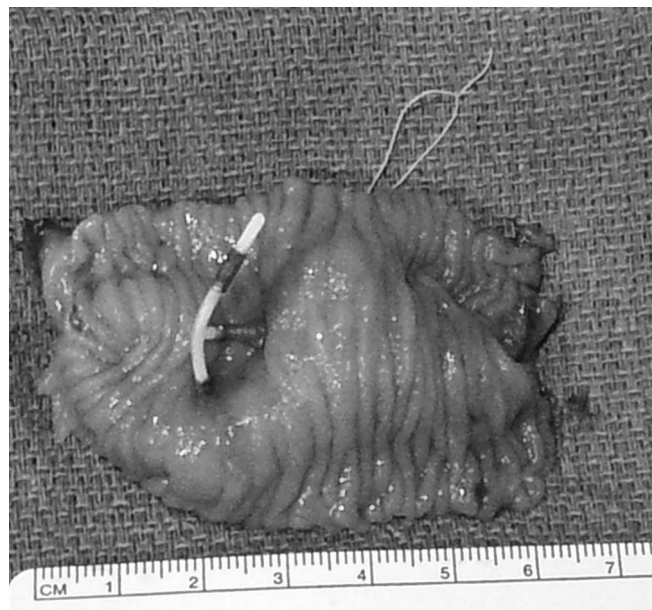
**Figure 1.** Intraoperative view of embedded migrated IUD.

rotomy for safe removal of the IUD.<sup>9,12,13</sup> We report a case of a perforated IUD embedded in the small intestine in which the IUD was successfully removed laparoscopically without the need for conversion to laparotomy.

## CASE PRESENTATION

A 33-year-old woman, gravida 5, para 4, presented to our gynecology clinic for a follow-up visit 1 month after uncomplicated IUD insertion. During vaginal examination, the strings of the IUD were not found. Transvaginal ultrasonography did not show any sign of the IUD inside the uterus, and this led to a subsequent abdominal radiograph, on which the IUD was noted in the upper pelvis, suggestive of migration.

The patient was scheduled to undergo a diagnostic laparoscopy to look for an intraperitoneal IUD. At the time of surgery, the IUD was noted to be within a loop of small bowel, with the strings coming out through the bowel wall (**Figure 1**). The uterus and adnexa were normal. There were minimal adhesions that were separated, and the small bowel was mobilized and brought toward the umbilicus. The umbilical incision was lengthened to approximately 2 cm, and a wound protector/retraction device (Applied Medical, Rancho Santa Margarita, California) was put in place. By use of the laparoscopic graspers, the affected portion of the small bowel was brought out into the wound. Because there was some inflammation around the perforation site, a limited resection and anastomosis were performed instead of an enterotomy and repair. (As can be seen on the resected segment, 1 of the limbs had embedded in the bowel wall [**Figure 2**], which was yet another reason a resection was a better choice than re-



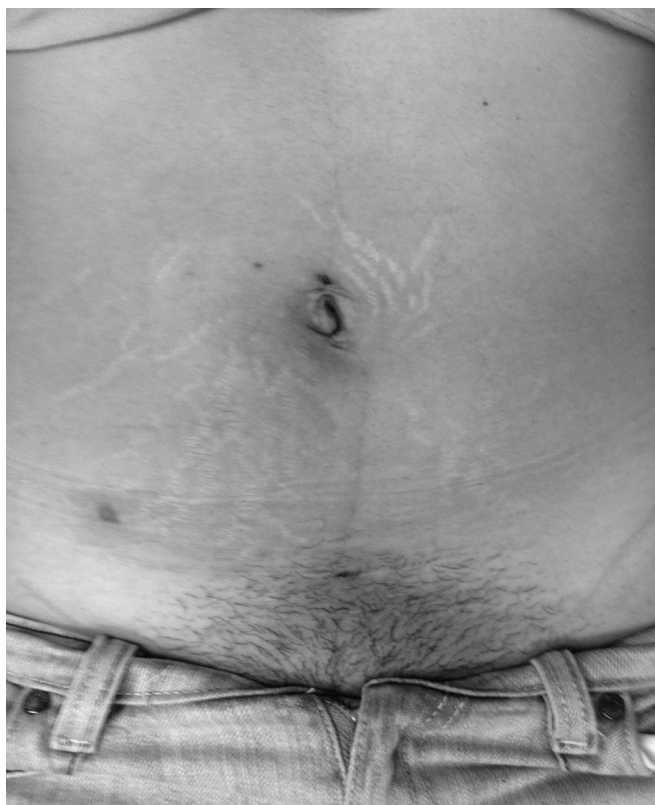**Figure 2.** Segment of resected small intestine with embedded IUD.

moval and repair.) Finally, the bowel returned to the abdomen and the fascia was closed with several polydioxanone sutures.

The postoperative recovery was uneventful. At the patient's 1-month follow-up visit in the clinic, she was doing well without any pain or problems. The incisions had healed well with a very good cosmetic result (**Figure 3**).

## DISCUSSION

Most IUD perforations occur at the time of insertion.<sup>4</sup> Most of these perforations are asymptomatic and therefore go unrecognized until follow-up examinations are performed or they become symptomatic.<sup>6,12</sup> Gastrointestinal symptoms can be observed, especially when the device migrates intraperitoneally. The combination of abdominal pain, diarrhea, and fever associated with a missing IUD is suggestive of this but can often be absent.<sup>6,12</sup> This leaves close follow-up after IUD placement as the best course of action to preemptively identify IUD perforation, as is highlighted in our case in which follow-up led to early detection. Many clinicians recommend that patients be examined 6 weeks after IUD insertion to look for signs and symptoms of perforation, such as shortening of string length.<sup>10,14</sup> When an IUD is suspected of being displaced, transvaginal ultrasonography is the test of choice, followed by radiographs in cases in which the IUD is not seen within the uterus.<sup>6,15</sup> In patients presenting with



**Figure 3.** Cosmetic result of laparoscopic approach (umbilical incision not noticeable underneath pre-existing umbilical piercing).

complications (eg, bowel perforation, bowel obstruction, abscess formation, or peritonitis), additional imaging such as computed tomography scanning or magnetic resonance imaging may be needed.<sup>15</sup>

In a literature review Gill et al<sup>12</sup> noted that perforated IUDs have been found in many locations, including in the omentum (26.7%), in the pouch of Douglas (21.5%), in the colonic lumen due to perforation (10.4%), in the myometrium (7.4%), in the broad ligament (6.7%), free within the abdomen (5.2%), in the small bowel serosa (4.4%), in the colonic serosa (3.7%), and in the mesentery (3%). The migration of IUDs to other organs including the stomach,<sup>3</sup> bladder,<sup>16,17</sup> colon,<sup>18–20</sup> and retroperitoneum<sup>10</sup> and even adjacent to the iliac vein<sup>21</sup> has been reported.

The management of intraperitoneal IUDs in asymptomatic patients is somewhat controversial. Migration into the peritoneal cavity can result in bowel obstruction, bowel perforation, bowel infarction, mesentery penetration, abscess formation, intestinal ischemia, or volvulus,<sup>10,12</sup> which makes surgery necessary even in asymptomatic patients.

The World Health Organization recommended that displaced IUDs should always be removed to prevent possible complications that can occur due to intraperitoneal adhesion formation or migration into adjacent organs.<sup>22</sup> However, some clinicians believe that open IUDs (ie, those not in a loop formation) that do not contain copper should be left in place in asymptomatic patients because the risks that may result from abdominal surgery and anesthesia are greater than the risks related to migration-associated adhesion formation.<sup>8,23</sup> Adoni and Ben Chetrit<sup>23</sup> found no adhesions in their case series of asymptomatic patients with intraperitoneal IUDs and concluded that surgical intervention is not mandatory in this group. In another study Markovitch et al<sup>8</sup> also recommended not intervening in asymptomatic patients because of the lack of adhesions in their 3 patients. In contrast, other recent studies have reported various degrees of adhesion formation in their case series and supported the World Health Organization recommendation to surgically remove all migrated IUDs.<sup>12,13</sup>

In making the decision whether to intervene in asymptomatic patients, one should also consider the other risks that the patient might face by choosing conservative treatment. These include migration to more critical locations with the resulting need for more complicated surgery,<sup>21</sup> the risk of intra-abdominal abscess formation,<sup>10,12,24</sup> psychological issues for the patient knowing about an intra-abdominal foreign body, and finally, the medicolegal repercussions of delayed treatment. All these push toward early surgical removal of intraperitoneal IUDs, even in asymptomatic patients.

For the aforementioned reasons, in our case it was decided to proceed with diagnostic laparoscopy as soon as the extrauterine position of the IUD was confirmed by ultrasonography and radiography. Laparoscopy is obviously preferable to laparotomy, but this is not always possible.<sup>12,13</sup> Mosley et al<sup>11</sup> showed in their review that surgery was attempted laparoscopically in 93% of patients, with laparotomy planned in only 7%. In their study only 22.5% of the laparoscopic cases were converted to laparotomy, primarily because of fixation to adjacent organs or adhesions. However, it must be noted that their review only included cases in which the IUD was located within the peritoneal cavity; cases with penetration into adjacent organs were excluded. In the review by Gill et al,<sup>12</sup> in which migrated IUDs in other organs were included, laparoscopy were successful in 64.2% of all cases. However, a detailed analysis of the data shows that this rate dropped to only 21% in patients with small bowel or colonic perforation by the IUD. Adhesions and severe abdominal



sepsis were the main reasons for not attempting laparoscopy or for converting to laparotomy in this case review. In our review of the English-language literature, we found 8 case reports identifying small bowel penetration by IUDs, and they were all removed by laparotomy.<sup>9,12,13,25</sup>

In our patient, although the IUD had perforated the small bowel, the removal was performed laparoscopically. Although surgeon ability is part of the equation, we believe that the use of the wound protector/retraction device was helpful in this case. Intracorporeal laparoscopic suturing is one of the more difficult skills to master.<sup>26,27</sup> Using the wound protector/retraction device allowed us to perform an extracorporeal anastomosis through a very small incision—hardly noticeable from the port site (**Figure 3**). This type of retractor has been shown in other types of surgery to help provide good visualization and keep difficult cases laparoscopic.<sup>28,29</sup> It has the additional advantage of yielding fewer wound infections because it shields the tissue from contamination.<sup>30</sup>

In summary, a migrated IUD should be removed when the diagnosis is made. This generally can be performed laparoscopically, although in cases of perforation into other organs, previously reported cases have been converted to or started as a laparotomy.<sup>9,12,13,25</sup> A wound protector can help keep the case laparoscopic, and we recommend that other surgeons consider this technique when faced with a similar situation.

## References:

1. American College of Obstetricians and Gynecologists. ACOG Practice Bulletin No. 121: Long-acting reversible contraception: implants and intrauterine devices. *Obstet Gynecol*. 2011; 118(1):184–196.
2. Jones J, Mosher W, Daniels K. Current contraceptive use in the United States, 2006–2010, and changes in patterns of use since 1995. *Natl Vital Stat Rep*. 2012;60:1–25.
3. Bozkurt M, Yumru AE, Coskun EI, Ondes B. Laparoscopic management of a translocated intrauterine device embedded in the gastric serosa. *J Pak Med Assoc*. 2011;61(10):1020–1022.
4. Zakin D, Stern WZ, Rosenblatt R. Complete and partial uterine perforation and embedding following insertion of intrauterine devices. I. Classification, complications, mechanism, incidence, and missing string. *Obstet Gynecol Surv*. 1981;36(7): 335–353.
5. Heinberg EM, McCoy TW, Pasic R. The perforated intrauterine device: endoscopic retrieval. *JSL*. 2008;12(1):97–100.
6. Zakin D, Stern WZ, Rosenblatt R. Complete and partial uterine perforation and embedding following insertion of intrauterine devices. II. Diagnostic methods, prevention, and management. *Obstet Gynecol Surv*. 1981;36(8):401–417.
7. Heartwell SF, Schlesselman S. Risk of uterine perforation among users of intrauterine devices. *Obstet Gynecol*. 1983;61(1): 31–36.
8. Markovitch O, Klein Z, Gidoni Y, Holzinger M, Beyth Y. Extrauterine mislocated IUD: is surgical removal mandatory? *Contraception*. 2002;66(2):105–108.
9. Chen CP, Hsu TC, Wang W. Ileal penetration by a multi-load-Cu 375 intrauterine contraceptive device. A case report with review of the literature. *Contraception*. 1998;58(5):295–304.
10. Ozgun MT, Batukan C, Serin IS, Ozcelik B, Basbug M, Dolanbay M. Surgical management of intra-abdominal mislocated intrauterine devices. *Contraception*. 2007;75(2):96–100.
11. Mosley FR, Shahi N, Kurer MA. Elective surgical removal of migrated intrauterine contraceptive devices from within the peritoneal cavity: a comparison between open and laparoscopic removal. *JSL*. 2012;16(2):236–241.
12. Gill RS, Mok D, Hudson M, Shi X, Birch DW, Karmali S. Laparoscopic removal of an intra-abdominal intrauterine device: case and systematic review. *Contraception*. 2012;85(1):15–18.
13. Arslan A, Kanat-Pektas M, Yesilyurt H, Bilge U. Colon penetration by a copper intrauterine device: a case report with literature review. *Arch Gynecol Obstet*. 2009;279(3):395–397.
14. Harrison-Woolrych M, Ashton J, Coulter D. Uterine perforation on intrauterine device insertion: is the incidence higher than previously reported? *Contraception*. 2003;67(1):53–56.
15. Sun CC, Chang CC, Yu MH. Far-migrated intra-abdominal intrauterine device with abdominal pain. *Taiwan J Obstet Gynecol*. 2008;47(2):244–246.
16. Sepulveda WH, Ciuffardi I, Olivari A, Gallegos O. Sonographic diagnosis of bladder perforation by an intrauterine device. A case report. *J Reprod Med*. 1993;38(11):911–913.
17. Dede FS, Dilbaz B, Sahin D, Dilbaz S. Vesical calculus formation around a migrated copper-T 380-A. *Eur J Contracept Reprod Health Care*. 2006;11(1):50–52.
18. Gungor M, Sonmezer M, Atabekoglu C, Ortac F. Laparoscopic management of a translocated intrauterine device perforating the bowel. *J Am Assoc Gynecol Laparosc*. 2003;10(4):539–541.
19. Zeino MY, Wietfeldt ED, Advani V, Ahad S, Younkin C, Hassan I. Laparoscopic removal of a copper intrauterine device from the sigmoid colon. *JSL*. 2011;15(4):568–570.
20. Mederos R, Humaran L, Minervini D. Surgical removal of an intrauterine device perforating the sigmoid colon: a case report. *Int J Surg*. 2008;6(6):e60–e62.

21. Roy KK, Banerjee N, Sinha A. Laparoscopic removal of translocated retroperitoneal IUD. *Int J Gynaecol Obstet.* 2000; 71(3):241–243.
22. Mechanism of action, safety and efficacy of intrauterine devices. Report of a WHO Scientific Group. *World Health Organ Tech Rep Ser.* 1987;753:1–91.
23. Adoni A, Ben Chetrit A. The management of intrauterine devices following uterine perforation. *Contraception.* 1991; 43(1):77–81.
24. Phupong V, Sueblinvong T, Pruksananonda K, Tanee-panichskul S, Triratanachat S. Uterine perforation with Lippes loop intrauterine device-associated actinomycosis: a case report and review of the literature. *Contraception.* 2000;61(5):347–350.
25. Ingec M, Kumtepe Y, Kadanali S, Ozdiller O. A rare case of ileal embedding by an intrauterine device. *Eur J Contracept Reprod Health Care.* 2005;10(1):29–31.
26. Bansal VK, Tamang T, Misra MC, et al. Laparoscopic suturing skills acquisition: a comparison between laparoscopy-exposed and laparoscopy-naive surgeons. *JSLS.* 2012;16(4):623–631.
27. Van Bruwaene S, De Win G, Miserez M. How much do we need experts during laparoscopic suturing training? *Surg Endosc.* 2009;23:2755–2761.
28. Tudor EC, Clark MC. Laparoscopic-assisted removal of gastric trichobezoar; a novel technique to reduce operative complications and time. *J Pediatr Surg.* 2013;48(3):e13–e15.
29. Kho KA, Shin JH, Nezhat C. Vaginal extraction of large uteri with the Alexis retractor. *J Minim Invasive Gynecol.* 2009;16(5): 616–617.
30. Horiuchi T, Tanishima H, Tamagawa K, et al. Randomized, controlled investigation of the anti-infective properties of the Alexis retractor/protector of incision sites. *J Trauma.* 2007;62(1): 212–215.