



Contents lists available at ScienceDirect

International Journal of Surgery Case Reports

journal homepage: www.casereports.com

Endoscopic-guided percutaneous nephrolithotomy (EPSL) with prone split-leg position for complex kidney stone: A case report

Soefiannagoya Soedarman^{a,b}, Nur Rasyid^{a,b}, Ponco Birowo^a, Widi Atmoko^{a,b,*}^a Department of Urology, Cipto Mangunkusumo Hospital, Faculty of Medicine, Universitas Indonesia, Jakarta, Indonesia^b Department of Urology, Universitas Indonesia Hospital, Jakarta, Indonesia

ARTICLE INFO

Article history:

Received 26 October 2020

Received in revised form 3 November 2020

Accepted 16 November 2020

Available online 26 November 2020

Keywords:

Endourology
Stones disease
Minimal-invasive
Complex stones

ABSTRACT

INTRODUCTION: The optimal patient positioning for percutaneous nephrolithotomy (PCNL) based on the complexity of stone burden is not yet defined in the literature. This report elaborated left complex kidney stones case underwent endoscopic-guided PCNL with a prone split-leg position (ePSL).

PRESENTATION OF CASE: Forty-three years old women were referred with a history of failed left open kidney surgery because of frozen kidney. A renal biopsy examination confirmed xanthogranulomatous tissue. Standard prone PCNL was performed. There were so many debris in pelvicalyceal system, so we used ultrasound guidance to puncture instead of fluoroscopy. There was residual stone in superior calyx that nephroscope couldn't reach. ePSL method was used in the second procedure. The stone was fragmented with pneumatic lithotripter. Evaluation using C-arm and nephroscope illustrated no residual stones, infundibulum laceration, and active bleeding.

DISCUSSION: This technique's main objectives are to remove urinary tract stones along the whole tract with a one-step and one-access approach with optimal utilization of full array endourologic equipment. The prone split-leg position was chosen for multiple reasons such as operator preference, the familiarity of a specific position, and inability to perform direct puncture in the upper pole. The main limitation is no long-term follow-up for patients to see the effectiveness and safety of this technique.

CONCLUSION: To conclude, ePSL with a prone split-leg position is a safe procedure with a relatively low rate of complications and can be used for complex kidney stone.

© 2020 The Authors. Published by Elsevier Ltd on behalf of IJS Publishing Group Ltd. This is an open access article under the CC BY-NC-ND license (<http://creativecommons.org/licenses/by-nc-nd/4.0/>).

1. Introduction

The optimal patient positioning for percutaneous nephrolithotomy (PCNL) based on the complexity of stone burden is not yet defined in the literature. Optimal guiding techniques also not explained fully in the literature for complex stone. Study by Batagello et al. explained that endoscopic-guided PCNL (ePSL) with a prone split-leg position are safe, with a low rate of complications. [1] Endoscopic-guided PCNL (ePSL) also produced low radiation exposure and requires less need for both multiple access and secondary procedure for complex stone management. This technique also minimizes the possibility of over-dilatation of tract due to direct visual examination from the flexible URS. Moreover, kidney tissues injury caused by too deep penetration and bleeding can also be avoided in this approach [2]. Although this procedure used many equipment and may affect the higher cost, we think that this procedure should be done in complex kidney stone. This report

elaborated one case in our centre that underwent endoscopic-guided PCNL with a prone split-leg position to achieve optimal stone free rate in the left complex kidney stones.

2. Case presentation

Forty-three years old women were referred to our hospital with a history of left open kidney surgery one year before admission to another hospital (Fig. 1). Intraoperatively during open surgery, a frozen kidney was found, and the surgery was stopped. Left DJ stent was inserted, and the xanthogranulomatous tissues was confirmed with a biopsy examination. In our hospital, the patient had a chief complaint of dull, intermittent pain in the left flank area without dysuria, hematuria, and history of passing stone. There is no history of the same diseases in the family and no certain regular drugs intake in the patient. The vital signs and general examination were within normal limits. Foley catheters with the size of 16 Fr were installed with normal urinary output. Laboratory examination showed leukocytosis ($11.66 \times 10^3/\mu\text{L}$).

Furthermore, patients were planned to undergo standard prone left PCNL by the endo-urology consultant. Retrograde pyelography (RPG) examination illustrated complete staghorn stone on the left

* Corresponding author at: Jl. Pangeran Diponegoro No.71, Kec. Senen, Central Jakarta, DKI Jakarta 10430, Indonesia.

E-mail address: dr.widiatmoko@yahoo.com (W. Atmoko).

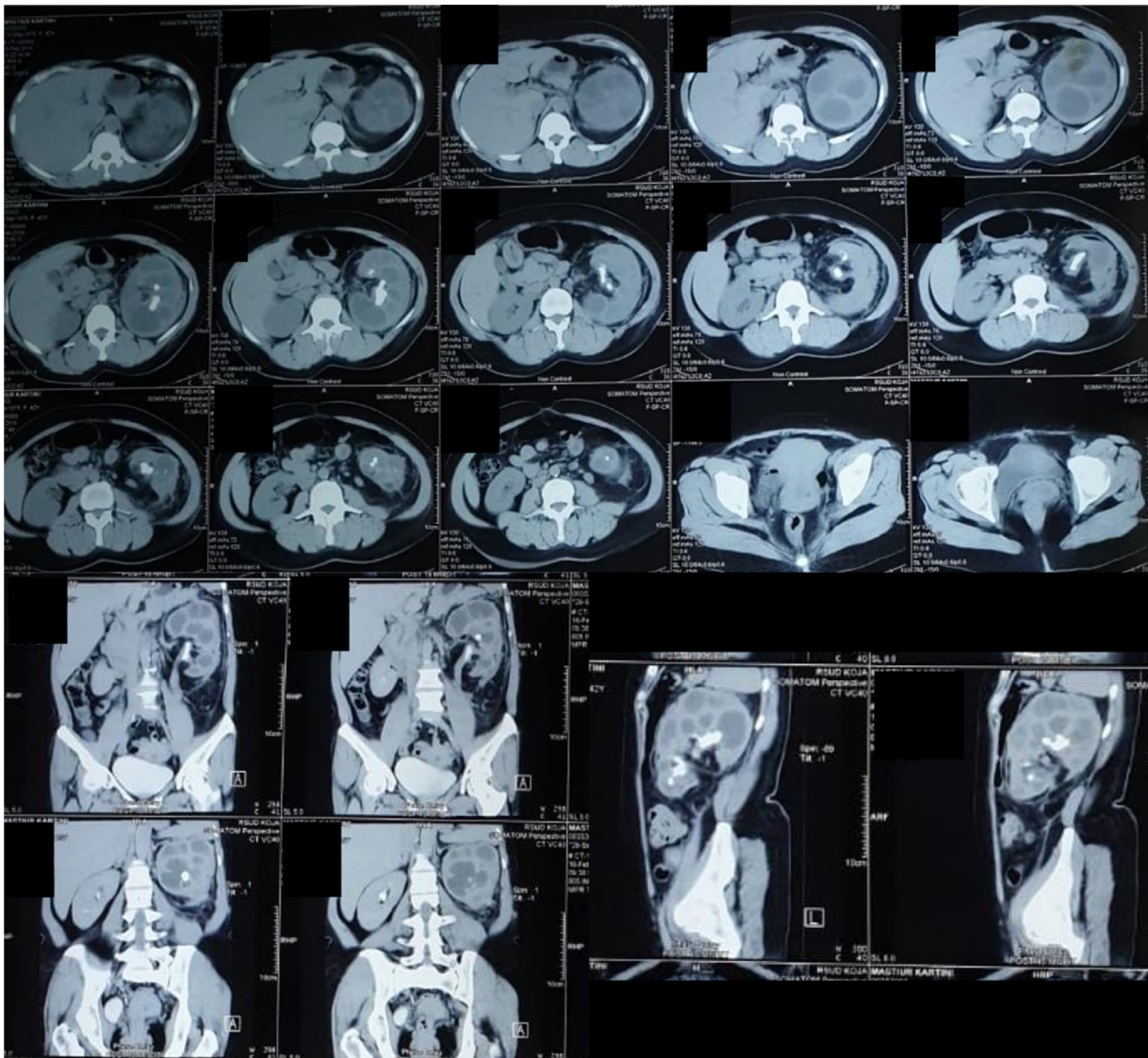


Fig. 1. The CT-scan result of the patient before open surgical procedure in the left kidney.

kidney with a lack of clarity in the dilated calyx. The operator performed several failed punctures. Therefore, we assumed that there is an accumulation of debris inside all of the calyx. The successful puncture was achieved with the addition of ultrasound guidance. However, there was a residual stone with a size of 30×20 mm in upper calyx that could not reach with nephroscope from the lower calyx approach. Uncontrolled intraoperative bleeding from the patient also strengthened the decision to stop further stone evacuation procedures.

Endoscopic-guided PCNL with a prone split-leg position with superior calyx puncture (intercostal XI–XII) was implemented by the endo-urologist two months after previous PCNL in this case. The purpose of using this technique is to obtain an optimal stone-free rate in complex kidney circumstances and also to achieve accurate puncture and dilation during the procedure. In the initial steps, the flexible URS size 9 Fr with ureteral access sheath was inserted into the left pelvicalyceal system, and a targeted stone was found. After that, a puncture in the superior right calyx with bull's eye technique with flexible URS was done. Despite the excessive amount of debris inside the pelvicalyceal system, the stone was fragmented with pneumatic lithotripter and the residual stone evacuated with stone forceps. Evaluation using C-arm and nephroscope illustrated

no residual stones, infundibulum laceration, and active bleeding. After the intervention patient was in stable condition and there is no persisted complaint the genitourinary system. There was no major complication in this patient. In contrast, a minor complaint of mild pain 1–3 days after surgery was investigated and managed by oral analgesics. Patients said the dull, intermittent pain following the intervention is significantly improved. Follow up in the outpatient clinic is performed for several weeks after the ePSL procedure (Fig. 2).

3. Discussion

In our reports, it was concluded that ePSL provided adequate and effective stone removal in complex kidney stones. Accumulation of debris increased the challenges in performing standard fluoroscopy PCNL. After undergoing this procedure, there are no residual stones found postoperatively, and there is no remaining complaint during regular follow up. Endoscopic-guided PCNL (ePSL) is one of the novel urology techniques that combines a multi-steps antero-retrograde approach to the pelvicalyceal system. The main objectives of this techniques are to obtain removal of urinary tract stones along the whole tract with one-step and one-access

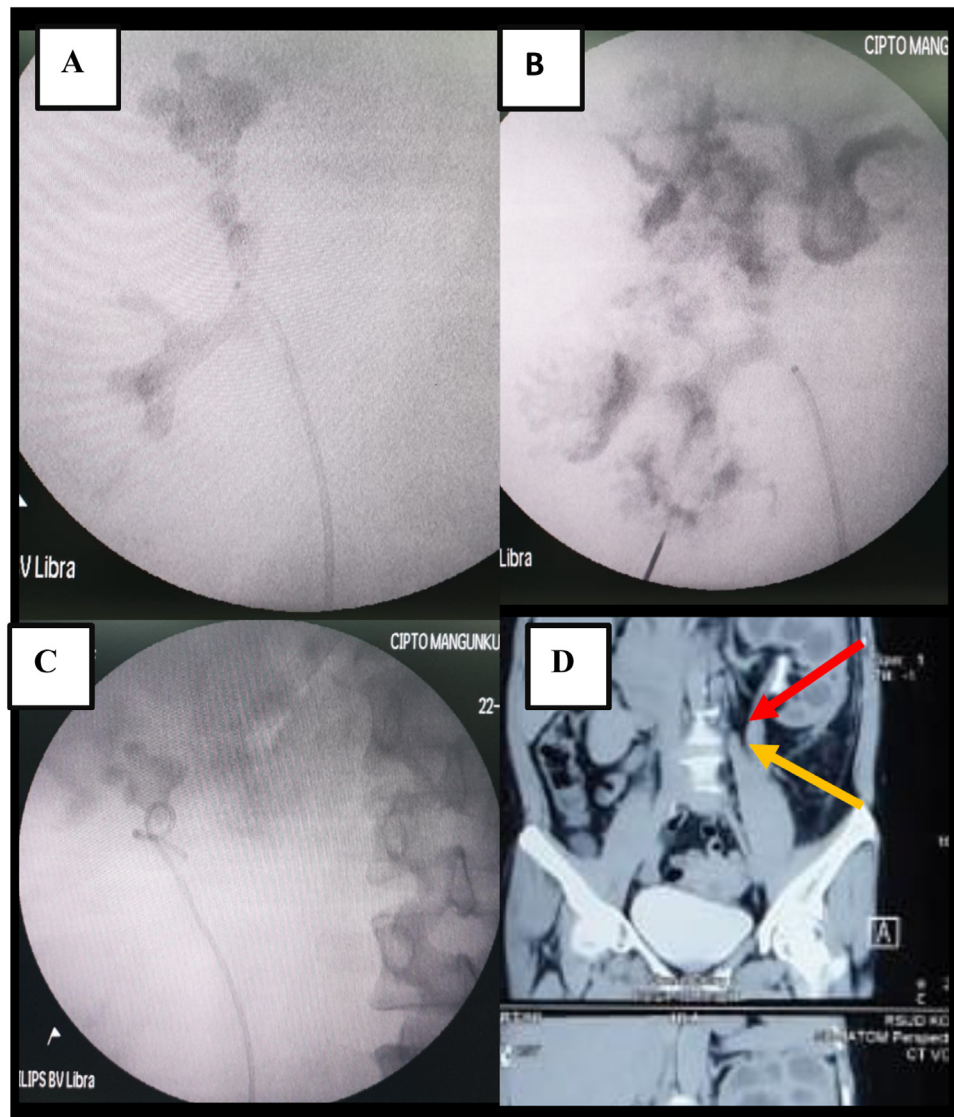


Fig. 2. (A) Fluoroscopy without contrast in the first standard prone PCNL indicated complete staghorn stone in the left kidney. (B) Retrograde pyelography contrast showed the calyx representation is not clear, several punctures were performed but failed, operator and team assumed there were so many debris inside all of the calyx. (C) There was residual stone with the size of 30×20 mm in upper left calyx that the operator couldn't reach with nephroscope from lower calyx, intraoperative bleeding influenced the decision to stop the operation. (D) pre-operative CT-scan before ePSL with prone split-leg position procedure.

approach with optimal utilization of full array endourologic equipment. Also, the combination of two types of endoscopes in the same operation has functional complementarity. For renal pelvis stone, the combination of upper and lower endoscopy increases the field of vision operation and increases the angle of operation. As a result, a better stone-free rate might be achieved. [3]

The prone position was used in our case because, the ureteral tract anatomy tends to be straight with the pressure of gravity, which provide less force for the ureteroscope to get into the upper ureter and pelvis. Under the monitor of the ureteroscope, the dilation of the percutaneous nephroscope puncture channel can avoid renal injury. In general circumstances, the endoscopic guided PCNL was performed in Galdakao-modified supine Valdivia position. [4] However, in our case, the prone split-leg position was chosen for multiple reasons such as the precarious debris accumulation in the renal that complicates the calyx puncture with standard fluoroscopy guidance. The other reason is the incapability to perform direct puncture in the upper pole due to multiple punctured needed (Lezrek technique), which increased the possibility of renal anatomy disruption and blood loss. Operator preference

and familiarity with a particular position also might influence the position approach. Cracco et al. in his study also explained several reason and/or advantages of prone-split leg position. First, the space provides for the percutaneous nephroscopy is wider and more extensive, and the probability of visceral injury is smaller compare to Galdakao-modified supine Valdivia position. Second, the absence of obesity and cardiovascular problems in patient characteristics (which are also applicable in our case). Third, preventing the compression to lower limb blood vessels due to prolong limbs elevation [3]. Furthermore, the bull's eye technique were essentials due to its ability to target the tip of f-URS directly. Unlike the supine position, the prone-leg split position accommodated the bull's eye puncture approach. Therefore, ePSL is more favorable compare to ECIRS in this case (Fig. 3).

Wen J et al. in his study compared the efficacy and complication between minimal invasive PCNL with Endoscopic Combined Intra-Renal Surgery (ECIRS) in partial staghorn calculi. It was found that there is no statistical difference in terms the clinical complications (spleen injury, fever, urinary leakage, urosepsis, haemorrhage, transfusion, nephrectomy, and embolisation) between the two

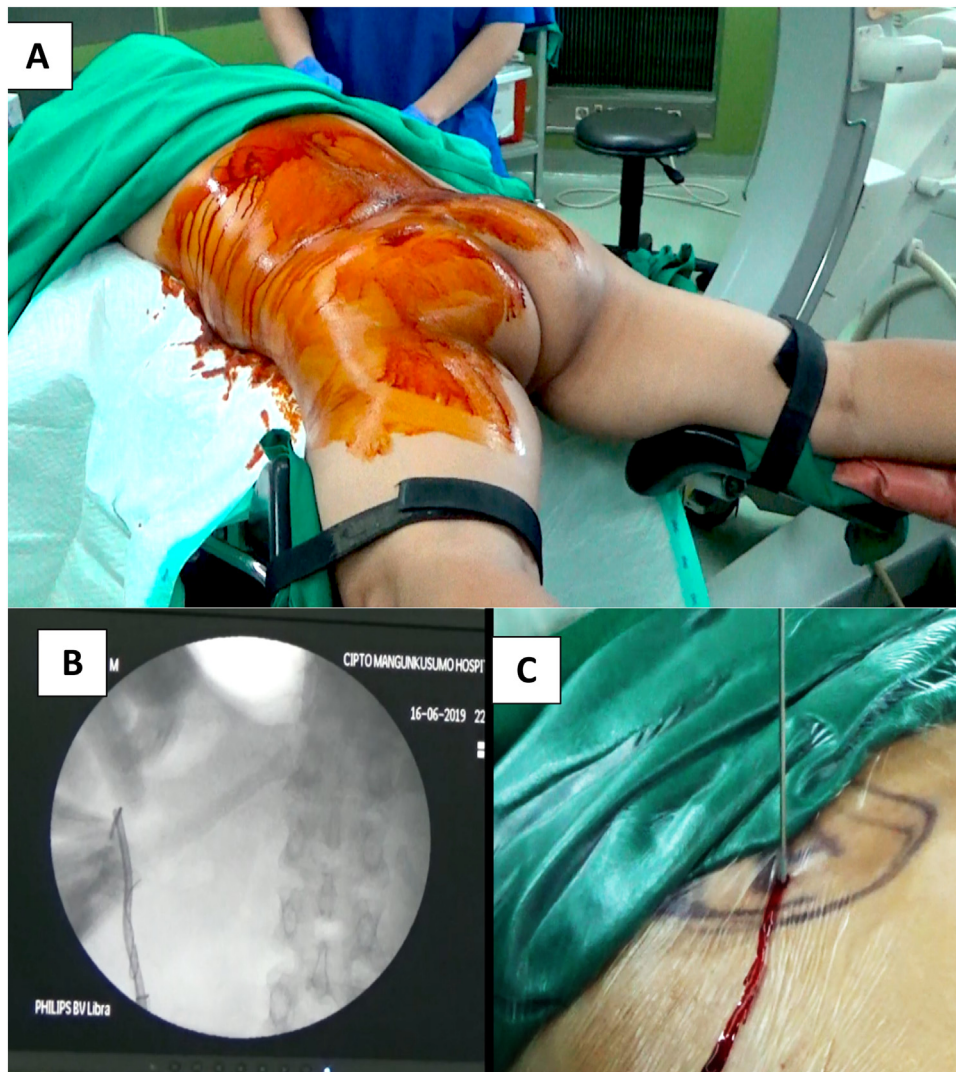


Fig. 3. (A) Prone-split leg position for ePSL. (B) C-arm during the bull's eye technique showed the tip of puncture needle. (C) Bulls eye technique for the puncture.

groups. [5] That theory also examined in this case, there is minimal bleeding, and the patient was maintained in stable condition postoperatively.

In our study, there is no long-term follow-up for patients to see the effectiveness and safety of this technique. This procedure in our centre still considered as a scarce technique since it used many endourology equipments. There is not much evidence or information that can be collected from multiple patients. Therefore, to establish ePSL's adequacy with a prone split-leg position, a multi-center study is recommended to obtain a more extensive database providing more statistically relevant data to conclude the efficacy of this particular approach.

4. Conclusion

Endoscopic-guided PCNL (ePSL) with a prone split-leg position is a safe procedure with relatively low rate of complications. It is also provided urinary tract stones removal with optimal utilization of full array endourology equipment.

Scare criteria

We confirmed that our work has been reported in line with the SCARE 2018 criteria [6].

Conflicts of interest

The authors declare no conflict of interest.

Funding

Private funds form the Department of Urology Ciptoman-gunkusumo hospital, Faculty Medicine University Indonesia. There are no study sponsors.

Ethical approval

The authors declare that we obtained permission from ethics committee in our institution.

Consent

Written informed consent was obtained from the patient for publication of this case report and accompanying images. A copy of the written consent is available for review by the Editor-in-Chief of this journal on request

Author contribution

- Soefiannagoya Soedarman MD., MRes. : Conceptualization, Methodology, Writing - Original Draft, Writing - Review & Editing, Visualization, Formal analysis, Investigation
- Nur Rasyid MD., PhD.: Data curation, Writing - Review & Editing, Project administration, Conceptualization, Methodology, Resources, Funding acquisition, Supervision
- Ponco Birowo MD., PhD. : Data curation, Writing - Review & Editing, Methodology, Resources, Supervision
- Widi Atmoko MD. : Data curation, Writing - Review & Editing, Methodology, Resources, Supervision

Registration of research studies

Our study design is case report, therefore we did not submit our report into any registry

Guarantor

Soefiannagoya Soedarman MD., MRes.
Widi Atmoko MD.

Provenance and peer review

Not commissioned, externally peer-reviewed

Acknowledgement

The contributors would like to thank Cipto Mangunkusumo Hospital team for supporting this report

References

- [1] C.A. Batagello, H.D. Barone Dos Santos, A.H. Nguyen, et al., Endoscopic guided PCNL in the prone split-leg position versus supine PCNL: a comparative analysis stratified by Guy's stone score, *Can. J. Urol.* 26 (1) (2019) 9664–9674.
- [2] D. Wang, H. Sun, L. Chen, Z. Liu, et al., Endoscopic combined intrarenal surgery in the prone-split leg position for successful single session removal of an encrusted ureteral stent: a case report, *BMC Urol.* 20 (2020) 37.
- [3] C.M. Cracco, C.M. Scoffone, ECIRS (Endoscopic Combined Intrarenal Surgery) in the Galdakao-modified supine Valdivia position: a new life for percutaneous surgery? *World J. Urol.* 29 (6) (2011) 821–827.
- [4] G. Ibarluzea, C.M. Scoffone, C.M. Cracco, et al., Supine Valdivia and modified lithotomy position for simultaneous anterograde and retrograde endourological access, *BJU Int.* 100 (2007) 233–236.
- [5] J. Wen, G. Xu, C. Du, Wang B. Minimally invasive percutaneous nephrolithotomy versus endoscopic combined intrarenal surgery with a flexible ureteroscope for partial staghorn calculi: a randomised controlled trial, *Int. J. Surg.* 28 (2011) 22–27.
- [6] R.A. Agha, M.R. Borrelli, R. Farwana, K. Koshy, A. Fowler, D.P. Orgill, For the SCARE Group, The SCARE, Statement: updating consensus surgical CAse REport (SCARE) guidelines, *Int. J. Surg.* 2018 (60) (2018) 132–136.

Open Access

This article is published Open Access at [sciencedirect.com](https://www.sciencedirect.com). It is distributed under the [IJSCR Supplemental terms and conditions](#), which permits unrestricted non commercial use, distribution, and reproduction in any medium, provided the original authors and source are credited.