





ORIGINAL ARTICLE

A Nationwide Survey on Digestive Reconstruction Following Pharyngolaryngectomy With Total Esophagectomy: A Multicenter Retrospective Study in Japan

Akihiko Okamura¹  | Masayuki Watanabe¹  | Nobuaki Mukoyama² | Yoshihiro Ota³ | Osamu Shiraishi⁴ | Wataru Shimbashi⁵ | Yoshifumi Baba⁶  | Hidetoshi Matsui⁷ | Hirotaka Shinomiya⁸ | Keijiro Sugimura⁹  | Masaru Morita¹⁰ | Makoto Sakai¹¹ | Hiroshi Sato¹² | Tomotaka Shibata¹³ | Motomi Nasu¹⁴ | Shuichi Matsumoto¹⁵ | Yasushi Toh^{10,16} | Akihiro Shiotani^{16,17} |

the Japan Broncho-Esophagological Society, Pharyngolaryngectomy with Total Esophagectomy (JBES-PLTE) Study Group

¹Department of Esophageal Surgery, Gastroenterology Center, Cancer Institute Hospital of Japanese Foundation for Cancer Research, Tokyo, Japan

²Department of Otolaryngology, Graduate School of Medicine, Nagoya University, Nagoya, Japan

³Department of Gastrointestinal and Pediatric Surgery, Tokyo Medical University, Tokyo, Japan

⁴Department of Surgery, Faculty of Medicine, Kindai University, Osaka, Japan

⁵Department of Head and Neck Surgery, Cancer Institute Hospital of Japanese Foundation for Cancer Research, Tokyo, Japan

⁶Department of Gastroenterological Surgery, Graduate School of Medical Sciences, Kumamoto University, Kumamoto, Japan

⁷Department of Head and Neck Surgery, Hyogo Cancer Center, Hyogo, Japan

⁸Department of Otolaryngology-Head and Neck Surgery, Kobe University Graduate School of Medicine, Hyogo, Japan

⁹Department of Digestive Surgery, Osaka International Cancer Institute, Osaka, Japan

¹⁰Department of Gastroenterological Surgery, National Hospital Organization Kyushu Cancer Center, Fukuoka, Japan

¹¹Department of General Surgical Science, Gunma University Graduate School of Medicine, Gunma, Japan

¹²Department of Gastroenterological Surgery, Saitama Medical University International Medical Center, Saitama, Japan

¹³Department of Gastroenterological and Pediatric Surgery, Oita University Faculty of Medicine, Oita, Japan

¹⁴Department of Esophageal and Gastroenterological Surgery, Juntendo University School of Medicine, Tokyo, Japan

¹⁵Department of Otolaryngology-Head and Neck Surgery, Kochi University, Kochi, Japan

¹⁶The Japan Broncho-Esophagological Society, Japan

¹⁷Department of Otolaryngology-Head and Neck Surgery, National Defense Medical College, Saitama, Japan

Correspondence

Masayuki Watanabe, Department of Gastroenterological Surgery, Cancer Institute Hospital of Japanese Foundation for Cancer Research, 3-8-31 Ariake, Koto-ku, Tokyo 135-8550, Japan.
Email: masayuki.watanabe@jfc.or.jp

Abstract

Aim: Digestive reconstruction after pharyngolaryngectomy with total esophagectomy (PLTE) remains challenging, with the optimal method remaining unclear. The current study aimed to clarify the short-term outcomes after PLTE and determine the optimal digestive reconstruction method.

Methods: Based on a nationwide survey of 151 patients who underwent PLTE, outcomes of digestive reconstruction methods are described.

This is an open access article under the terms of the Creative Commons Attribution-NonCommercial-NoDerivs License, which permits use and distribution in any medium, provided the original work is properly cited, the use is non-commercial and no modifications or adaptations are made.

© 2021 The Authors. *Annals of Gastroenterological Surgery* published by John Wiley & Sons Australia, Ltd on behalf of The Japanese Society of Gastroenterology.

Results: Among digestive reconstruction methods, a simple gastric tube was most frequently used (37.1%), followed by gastric tube combined with free graft transfer (FGT) (35.1%), gastric tube with microvascular anastomosis (22.5%), and other procedures (5.3%). Intraoperative evaluation of microcirculation (IOEM) was utilized in 29 patients (19.2%). Among the included patients, 66.9% developed any-grade complications, 41.0% developed severe complications, and 23.8% developed digestive reconstruction-related complications (DRRCs; leakage or necrosis). Reoperation within 30 days for any complications and DRRCs was required in 13.9% and 8.6% of the patients, respectively. Mortality within 90 days was observed in 4.6%. Among the three major methods, gastric tube combined with FGT promoted the least DRRCs in the gastric tube ($P = .005$), although the overall incidence of DRRCs was comparable. The use of IOEM was significantly associated with a reduction of severe DRRCs ($P = .005$).

Conclusions: Pharyngolaryngectomy with total esophagectomy is a high-risk surgery significantly associated with the occurrence of postoperative morbidity and mortality. Nonetheless, the addition of FGT can help prevent gastric tip complications, while IOEM can be an effective method for improving outcomes.

KEYWORDS

esophagectomy, laryngectomy, pharyngectomy, postoperative complications, reconstructive surgery

1 | INTRODUCTION

Pharyngolaryngectomy with total esophagectomy (PLTE) is a radical surgical procedure for patients with synchronous head and neck (HN) and esophageal cancers or single cervicothoracic esophageal cancer in which laryngeal preservation could not be accomplished. During PLTE, nearly all of the upper digestive tract is resected without preserving vocal function. Therefore, this procedure is highly invasive, with studies reporting high morbidity and mortality rates up to 63.1% and 4.8%, respectively.¹⁻⁴ Given that upper aero digestive tract cancers share common risk factors,⁵ esophageal and HN cancers occasionally occur simultaneously. However, given the complexity of PLTE clinical outcomes following the same have yet to be fully elucidated in a large-scale study.

During PLTE, sufficient conduit length is required for digestive reconstruction, given the considerably long defect along the digestive tract. Based on several previous studies, the gastric tube has been the most frequently used conduit in such circumstances. However, blood flow at the conduit tip may occasionally be insufficient, which increases the difficulty of reconstructive surgery after PLTE. To improve outcomes, some modifications, such as an additional microvascular anastomosis (MVA), an additional free graft transfer (FGT), and elongation of the gastric tube, have been proposed.^{1-4,6-15} However, only a few studies have elucidated the optimal reconstruction method.

Therefore, the current study aimed to clarify the current clinical situation and outcomes of reconstruction after PLTE in Japan by conducting a nationwide survey spearheaded by the Japan Bronchoesophagological Society (JBES).

2 | PATIENTS AND METHODS

2.1 | Study design and patients

We conducted a nationwide survey targeting JBES-authorized training facilities (ATFs) for board-certified bronchoesophagologists. The ATFs included those for esophageal surgery, otorhinolaryngology, HN surgery, thoracic surgery, and respiratory medicine departments. The survey initially invited all 239 ATFs, and 48 responded to participate, whereas 45 responded not to participate because of no experience of PLTE during the study period. Ultimately, 31 facilities returned their electronic questionnaire forms. Patients who underwent PLTE with immediate digestive reconstruction were eligible. Those who refused registration and had missing data were excluded from the study. The present study included 151 patients who underwent PLTE at the ATFs between January 1, 2015 and December 31, 2019. The study protocol was approved by the JBES (approval number 2020-01) and the Institutional Review Board of the Japanese Foundation for Cancer Research (approval number 2020-1147).

2.2 | Data collection and outcome measures

The questionnaire form obtained information regarding age, sex, body mass index, the American Society of Anesthesiologists-physical status (ASA-PS),¹⁶ diagnosis, preoperative treatment, operation date, surgical approach, operative time, operative blood loss, details regarding digestive reconstruction, use of intraoperative evaluation of microcirculation (IOEM), postoperative complications, reoperation within 30 days, and mortality within 90 days. As far as complications are concerned, we collected the details of frequently observed events after PLTE, including anastomotic leakage, graft necrosis, tracheal necrosis, surgical site infection, pneumonia, hemorrhage, and sepsis. In addition, we collected the information on the highest grade of any complications by Clavien–Dindo classification.¹⁷ The Union for International Cancer Control TNM staging version 8 was adopted to classify tumor stage.

The current study described the clinical outcomes after PLTE and compared the incidence of all digestive reconstruction-related complications (DRRCs), including anastomotic leakage and graft necrosis, DRRCs that developed in the gastric tube, severe DRRCs (grade \geq III), and reoperation for DRRCs within 30 days, according to the reconstructive methods.

2.3 | Digestive reconstructions

In this survey, a gastric tube, the small intestine, and an ileocolic graft were utilized after PLTE. The gastric tube was used alone or

with some modifications, such as MVA (Figure 1A), an additional FGT (Figure 1B), elongation with the supercharged reversed lesser curvature (Figure 1C), and elongation with the pedicled gastric tube (Figure 1D).

In the gastric tube with MVA, vascular anastomosis was added between the short gastric or left gastroepiploic vessels and the appropriate cervical vessels. In the gastric tube with FGT, a free graft (eg, jejunum or colon) was harvested and interposed between the pharynx and the gastric tube. During elongation with the supercharged reversed lesser curvature, the lesser curvature side of the stomach was turned over, after which the left gastric vessels were anastomosed with the appropriate cervical vessels. During elongation with the pedicled gastric tube, the gastric antrum was resected while preserving the right gastroepiploic vessels, after which the distal end of the stomach was reconstructed using the pedicled jejunum with the Roux-en-Y technique.

2.4 | Statistical analysis

Data are presented as medians (range) or numbers (%). Statistical comparisons among groups were performed using the chi-squared test. Univariate logistic regression analysis was utilized to calculate the odds ratio (OR) and 95% confidence interval (CI). All statistical analyses were performed using the software package SPSS v. 25.0 (IBM-SPSS, Armonk, NY), with a two-sided probability level \leq 0.05 indicating statistical significance.

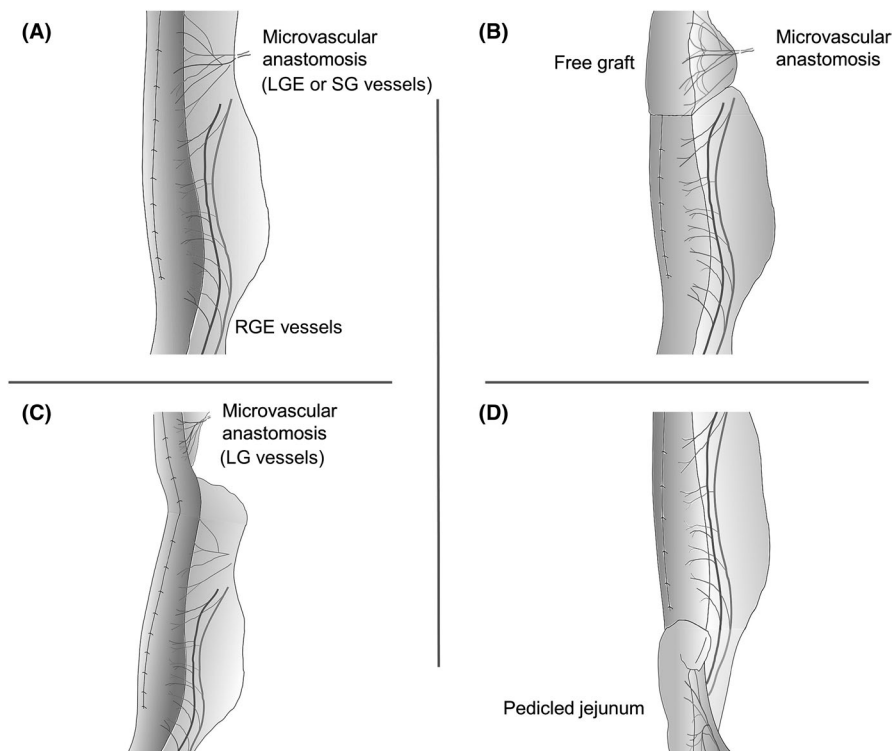


FIGURE 1 Reconstructive modifications using a gastric tube. (A) Gastric tube with MVA. (B) Gastric tube combined with FGT. (C) Elongation with the supercharged reversed lesser curvature. (D) Elongation with pedicled gastric tube. LG, left gastric; LGE, left gastroepiploic; RGE, right gastroepiploic; SG, short gastric

3 | RESULTS

3.1 | Patient characteristics and surgical procedures

Patient characteristics are summarized in Table 1. Among the 151 patients with a median age of 67 (range, 30–79 years), 132 (87.4%) were male, 74 (49.0%) had synchronous HN and esophageal cancers, and 77 (51.0%) had single cervicothoracic cancer. Preoperative chemotherapy and/or radiotherapy were administered in 100 patients (66.2%).

Regarding the surgical approach, 104 (68.9%) and 47 (31.1%) underwent surgery via the transthoracic and transhiatal approach, respectively. Open abdominal and laparoscopic procedures were used in 95 (62.9%) and 56 patients (37.1%), respectively, whereas IOEM was utilized in 29 patients (19.2%). For digestive reconstruction, a simple gastric tube was most frequently used ($n = 56$, 37.1%), followed by gastric tube with FGT ($n = 53$, 35.1%), gastric tube with MVA ($n = 34$, 22.5%), and other procedures ($n = 8$, 5.3%), including elongation with the pedicled gastric tube ($n = 4$, 2.6%), reconstruction using the small intestine ($n = 2$, 1.3%), colonic interposition ($n = 1$, 0.7%), and elongation with the supercharged reversed lesser curvature ($n = 1$, 0.7%). Of 91.4%, the reconstruction was made through the posterior mediastinal route.

3.2 | Surgical outcomes

Surgical outcomes are summarized in Table 2. The median operative time and blood loss were 732 min (range, 357–1305 min) and 545 mL (range 60–2366 mL), respectively. Postoperatively, 101 (66.9%) and 62 patients (41.0%) developed any-grade and severe complications (CD grade \geq III), respectively. The DRRC rate was 23.8%, including necrosis of the gastric tube ($n = 4$, 2.6%) and free jejunum ($n = 3$, 2.0%). Incidences of tracheal necrosis, surgical site infections, pneumonia, hemorrhage, and sepsis were 12.6%, 11.9%, 10.6%, 4.6%, and 4.0%, respectively. Additionally, reoperation within 30 days for any cause and DRRCs were 13.9% and 8.6%, respectively. Mortality within 90 days was observed in seven patients (4.6%). The median postoperative hospital stay was 44 days (range, 3–1595 days).

3.3 | Outcome comparisons according to the three major reconstructive methods

We compared the incidence of overall DRRCs (Figure 2A), DRRCs in the gastric tube (Figure 2B), severe DRRCs (CD grade \geq III) (Figure 2C), and reoperation for DRRCs within 30 days (Figure 2D) according to three major reconstructive methods, namely, a simple gastric tube, gastric tube with FGT, and gastric tube with MVA. Overall DRRCs in a simple gastric tube, gastric tube with FGT, and gastric tube with MVA were observed in 28.6%, 17.0%, and 26.5%, respectively.

DRRCs in the gastric tube developed in 28.6%, 5.7%, and 26.5%, respectively. Although DRRCs in the gastric tube occurred less frequently in patients who underwent reconstruction using a gastric tube with FGT ($P = .005$), overall and severe DRRCs were comparable among the methods ($P = .333$ and $.910$, respectively). The frequency of reoperation for DRRCs was also similar among the groups ($P = .280$). Additional MVA to a simple gastric tube promoted no reduction in the DRRCs compared to the simple gastric tube alone. The ORs of each reconstructive method for each outcome are also described in Table 3.

3.4 | Intraoperative evaluation of microcirculation

For IOEM, indocyanine green (ICG) angiography and pulse oximetry were used in 28 and 1 patients, respectively. Except for one case in which reconstruction was done using the small intestine, IOEM was used for the three major methods of reconstruction. Accordingly, outcomes among patients who underwent the three major reconstructions were compared according to whether or not they received IOEM (Figure 3A–D). The prevalence of IOEM use did not differ among the methods ($P = .477$). Patients who received IOEM tended to have fewer overall DRRCs and reoperations for DRRCs ($P = .070$ and $.074$, respectively) compared to those who did not. Moreover, none of the patients who received IOEM developed severe DRRCs, whereas 22.6% of the patients who did not receive IOEM experienced severe DRRCs ($P = .005$). The ORs of IOEM use for each outcome are also described in Table 3.

4 | DISCUSSION

By conducting a Japanese nationwide survey, the present study clarified the current clinical outcomes following PLTE. As previously reported, PLTE is a high-risk procedure that has been significantly associated with postoperative morbidity and mortality. Regarding digestive reconstruction, additional MVA to a simple gastric tube failed to decrease anastomotic leakage or necrosis. Meanwhile, gastric tube with FGT was significantly associated with reduced rates of anastomotic leakage or necrosis in the gastric tube, although it did not decrease overall complications associated with digestive reconstruction. Interestingly, our findings showed that IOEM may help improve outcomes. This has been the first study to evaluate the clinical results of several digestive reconstructions after PLTE using a multicenter cohort.

In 1960, Ong and Lee had been the first to report rereading PLTE for HN cancer with digestive reconstruction using a gastric tube.⁶ Thereafter, Wei et al published their findings regarding the outcomes of 317 PLTEs with gastric tube reconstruction over their 30 years of experience. Accordingly, they reported decreased postoperative morbidities and mortality during the study period, with

TABLE 1 Patient characteristics and surgical procedures

Variables	Value
Sex	
Male	132 (87.4%)
Female	19 (12.6%)
Age, years	67 (30–79)
BMI, kg/m ²	19.6 (14.3–27.2)
ASA-PS	
1	63 (41.7%)
2	78 (51.7%)
3	10 (6.6%)
PLTE indication	
Double cancers	74 (49.0%)
Single cancer	77 (51.0%)
cStage (Double cancers)	
HN cancer	
cStage I–II	11 (14.9%)
cStage III	13 (15.6%)
cStage IV	50 (67.6%)
Esophageal cancer	
cStage I–II	53 (71.6%)
cStage III	14 (18.9%)
cStage IV	6 (8.1%)
Not available	1
cStage (Single cancer)	
cStage I–II	14 (18.2%)
cStage III	24 (31.2%)
cStage IV	37 (48.1%)
Not available	2
Preoperative treatment	
None	51 (33.8%)
Chemotherapy	53 (35.1%)
CRT/RT	47 (31.1%)
Mediastinal approach	
Open transthoracic	39 (25.8%)
Thoracoscopic	65 (43.0%)
Transhiatal	47 (31.1%)
Abdominal approach	
Open	95 (62.9%)
Laparoscopic	56 (37.1%)
IOEM	29 (19.2%)
Digestive reconstruction	
Simple gastric tube	56 (37.1%)
Gastric tube combined with FGT	53 (35.1%)
Gastric tube with MVA	34 (22.5%)
Elongation with pedicled gastric tube and jejunum	4 (2.6%)

(Continues)

TABLE 1 (Continued)

Variables	Value
Small intestine	2 (1.3%)
Ileocolic graft	1 (0.7%)
Elongation with the lesser curvature side of the stomach	1 (0.7%)
Route of reconstruction	
Posterior mediastinal	138 (91.4%)
Retrosternal	9 (6.0%)
Subcutaneous	4 (2.6%)

Note: All data are presented as medians (range) or numbers (%).

Abbreviations: ASA, American Society of Anesthesiologists; BMI, body mass index; CRT, chemoradiotherapy; FGT, free graft transfer; HN, head and neck; IOEM, intraoperative evaluation of microcirculation; MVA, microvascular anastomosis; PLTE, pharyngolaryngectomy with total esophagectomy; PS, physical status; RT, radiotherapy.

TABLE 2 Surgical outcomes

Variables	Value
Operative time, min	732 (357–1305)
Operative blood loss, mL	545 (60–2366)
Highest grade of any complications	
0	50 (33.1%)
I	22 (14.6%)
II	17 (11.3%)
IIIa	31 (20.5%)
IIIb	18 (11.9%)
IV	6 (4.0%)
V	7 (4.6%)
Major complications	
DRRCs	36 (23.8%)
Tracheal necrosis	19 (12.6%)
Surgical site infection	18 (11.9%)
Pneumonia	16 (10.6%)
Hemorrhage	7 (4.6%)
Sepsis	6 (4.0%)
Reoperation within 30 days	21 (13.9%)
Reoperation for DRRCs within 30 days	13 (8.6%)
Mortality within 90 days	7 (4.6%)
Postoperative hospital stay, days	44 (3–1595)

Note: All data are presented as medians (range) or numbers (%).

Abbreviation: DRRCs, digestive reconstruction-related complications.

improvement in patient management, including preoperative nutritional support and a tension-free pharyngogastric anastomosis. However, given that the current nationwide study still demonstrated high postoperative morbidity and mortality rates, it may be necessary to determine the optimal digestive reconstruction method following PLTE to further improve outcomes.

FIGURE 2 Comparison of outcomes among the three major reconstruction methods. Incidence rates for overall DRRCs (A), DRRCs in the gastric tube (B), severe DRRCs (grade \geq III) (C), and reoperation for DRRCs within 30 days (D) among the three major reconstructive methods. DRRC, digestive reconstruction-related complications; G + FGT, gastric tube with free graft transfer; G + MVA, gastric tube with microvascular anastomosis; G, simple gastric tube

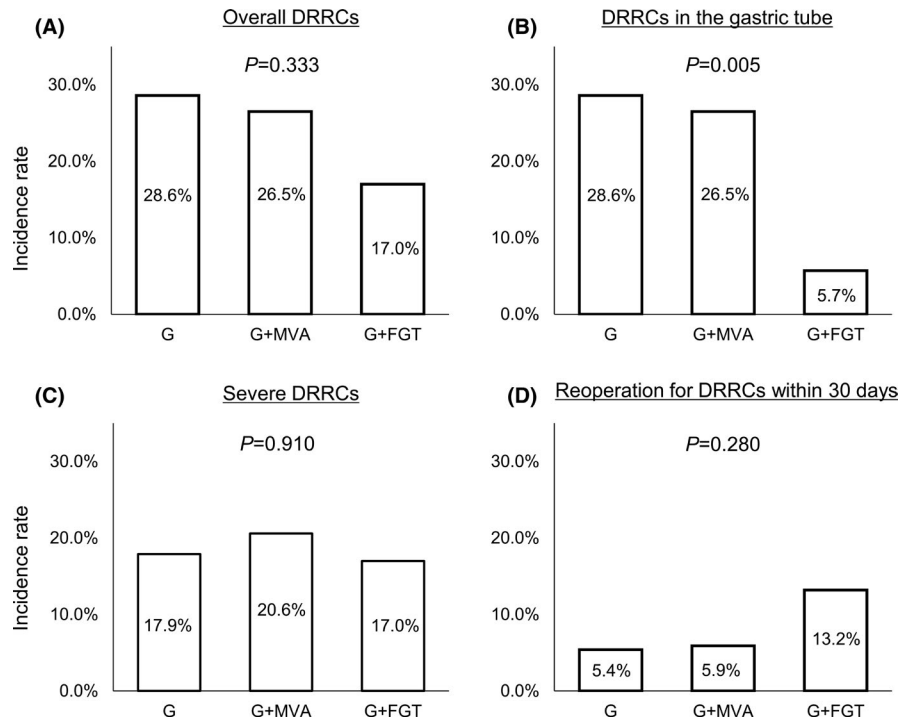


TABLE 3 Significance of reconstructive methods and IOEM for DRRCs

Outcomes	Variables	Reference	OR (95% CI)	P value
Overall DRRCs	Gastric tube with MVA	Simple gastric tube	0.829 (0.346–2.344)	.829
	Gastric tube combined with FGT		0.511 (0.203–1.286)	.154
	IOEM (+)	IOEM (-)	0.325 (0.092–1.154)	.082
DRRCs in the gastric tube	Gastric tube with MVA	Simple gastric tube	0.900 (0.346–2.344)	.829
	Gastric tube combined with FGT		0.150 (0.041–0.551)	.004
	IOEM (+)	IOEM (-)	0.432 (0.120–1.549)	.198
Severe DRRCs	Gastric tube with MVA	Simple gastric tube	1.193 (0.406–3.499)	.748
	Gastric tube combined with FGT		0.941 (0.349–2.534)	.904
	IOEM (+)	IOEM (-)	0.061 (0.008–0.463)	<.001
Reoperation for DRRCs within 30 days	Gastric tube with MVA	Simple gastric tube	1.104 (0.175–6.968)	.916
	Gastric tube combined with FGT		2.688 (0.657–11.00)	.169
	IOEM (+)	IOEM (-)	0.153 (0.019–1.210)	.063

Abbreviations: CI, confidence interval; DRRCs, digestive reconstruction-related complications; FGT, free graft transfer; IOEM, intraoperative evaluation of microcirculation; MVA, microvascular anastomosis; OR, odds ratio.

Studies have shown that a gastric tube had been most commonly used method for digestive reconstruction after PLTE. In fact, studies have shown that among patients who underwent gastric tube reconstruction, 3.3%–25.0% and 0%–16.7% developed anastomotic leakage and gastric necrosis, respectively.^{1–4,9,10,12,14} In the present study, overall DRRCs in a simple gastric tube and gastric tube with MVA were observed in 28.6% and 26.5%, respectively. Previous studies have reported that additional MVA to a simple gastric tube could promote better outcomes compared to simple gastric tube reconstruction alone.⁴ However, our findings showed that additional MVA to a simple gastric tube promoted no superior outcomes. One

possible explanation is that revascularization was not successful because of too narrow vessels to perform MVA and/or less intramural vascular communications in the gastric tip. Meanwhile, given that MVA is usually utilized only in cases where gastric tip perfusion was insufficient, it could help improve conduit microcirculation. Nonetheless, problems associated with tension in the pharyngogastric anastomosis remain.

In contrast, studies have shown that the gastric tube with FGT method promoted relatively favorable outcomes, with anastomotic leakage and graft necrosis incidence rates of 0% and 0%–4%, respectively.^{4,15} Similarly, the current study also revealed that this method

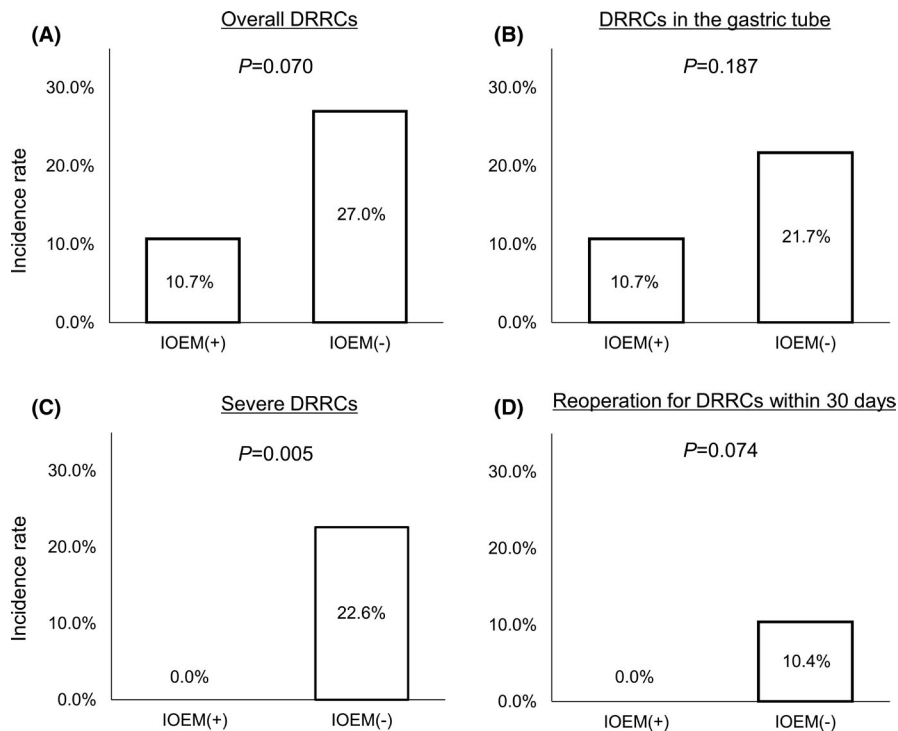


FIGURE 3 Comparison of outcomes according to the presence or absence of IOEM. Incidence rates for overall DRRCs (A), DRRCs in the gastric tube (B), severe DRRCs (grade \geq III) (C), and reoperation for DRRCs within 30 days (D) with or without IOEM in patients who underwent the three major reconstructive methods. DRRC, digestive reconstruction-related complications; IOEM, intraoperative evaluation of microcirculation

was significantly associated with decreased anastomotic leakage or necrosis rates in the gastric tube. However, it was not associated with a decrease in the overall occurrence of complications related to digestive reconstruction. Approximately 10% of patients could develop complications associated with FGT, among whom reoperation within 30 days was relatively frequent. Although FGT could resolve blood perfusion problems in the gastric tube and tension in the anastomotic site, additional digestive anastomosis and MVA could cause other complications. Indeed, our results showed that two patients developed free graft necrosis (3.8%).

Another noteworthy finding of the present study is that IOEM could help improve outcomes. Indeed, several previous studies have demonstrated the efficacy of real-time IOEM using ICG, thermal imaging, or laser Doppler flowmetry in gastric tube reconstruction after esophagectomy.¹⁸⁻²² Given that the macroscopic appearance of the graft is unreliable for indicating viability, the introduction of IOEM may improve the safety of digestive reconstruction after PLTE. Nonetheless, further studies investigating the efficacy of IOEM on improving clinical outcomes in patients undergoing PLTE are required.

Several limitations of the present study should be addressed. First, this was a relatively small retrospective observational study. However, there were few multi-institutional studies on the infrequent PLTE procedures, and thus it is meaningful to acquire data through a nationwide survey. Second, this study was based on a questionnaire survey targeting ATFs for board-certificated bronchoesophagologists and therefore may not reflect outcomes of all PLTE cases in Japan. Third, examining the details of each case was difficult due to the limited information obtained through the questionnaire survey, although the case volume of the surgeon or

hospital in charge, the specialty of the surgeon, and the proficiency in microvascular surgery techniques could affect the outcomes. Nonetheless, this study has been the first to analyze such a large number of patients and provide novel information regarding digestive reconstruction after PLTE. Ideally, a large-scale prospective interventional study is required to verify our findings, despite being impractical. Thus far, at least, a prospective registration system for this rare surgical procedure is required to further clarify the clinical outcomes and determine the optimal digestive reconstruction methods.

In conclusion, PLTE is a high-risk surgical procedure significantly associated with postoperative morbidity and mortality. Our findings showed that reconstruction using a gastric tube with FGT was significantly associated with reduced rates of anastomotic leakage or necrosis in the gastric tube, although it did not decrease overall and severe complications associated with digestive reconstruction. Additionally, we identified IOEM as a valuable method for improving outcomes.

ACKNOWLEDGMENTS

The authors sincerely appreciate all participating investigators for their valuable assistance with data collection: Ryo Kawata (Department of Otorhinolaryngology-Head and Neck Surgery, Osaka Medical and Pharmaceutical University, Osaka, Japan); Yo Kishimoto (Department of Otolaryngology, Head and Neck Surgery, Graduate School of Medicine, Kyoto University, Kyoto, Japan); Jun Sakuma (Department of Surgery, NTT Medical Center Tokyo, Tokyo, Japan); Akira Okoshi (Department of Otolaryngology-Head and Neck Surgery, Tohoku University Graduate School of Medicine, Miyagi, Japan); Hisayuki Kato (Department of Otolaryngology-Head

and Neck Surgery School of Medicine, Fujita Health University, Aichi, Japan); Shogo Shinohara (Department of Otolaryngology-Head & Neck Surgery, Kobe City Medical Center General Hospital, Hyogo, Japan); Mikio Suzuki (Department of Otorhinolaryngology, Head and Neck Surgery, University of the Ryukyus Faculty of Medicine, Okinawa, Japan); Shinsuke Takeno (Division of Gastrointestinal, Endocrine and Pediatric Surgery, Faculty of Medicine, University of Miyazaki, Miyazaki, Japan); Kuniaki Chida (Department of Otolaryngology, Head and Neck Surgery, Yamagata University Faculty of Medicine, Yamagata, Japan); Masahiko Higashikawa (Department of Otorhinolaryngology-Head and Neck Surgery, Osaka Saiseikai Nakatsu Hospital, Osaka, Japan); Shunsuke Miyamoto (Department of Otolaryngology, Head and Neck Surgery, Kitasato University, Kanagawa, Japan); Hajime Ishinaga (Department of Otorhinolaryngology-Head and Neck Surgery, Mie University Graduate School of Medicine, Mie, Japan); Kosuke Uno (Department of Otolaryngology-Head and Neck Surgery, National Defense Medical College, Saitama, Japan); Jun Okamura (Department of Otorhinolaryngology, Seirei Hamamatsu General Hospital, Shizuoka, Japan); Koji Sakamoto (Department of Otorhinolaryngology, Nippon Medical School, Tokyo, Japan); Yujiro Fukuda (Department of Otolaryngology, Kawasaki Medical School, Okayama, Japan); and Sohei Mitani (Department of Otolaryngology-Head and Neck Surgery, Ehime University Graduate School of Medicine, Ehime, Japan).

DISCLOSURE

Funding: Author Y.B. has an endowed chair funded by Ono Pharmaceutical Co. Ltd.

Conflict of Interest: The authors have no conflicts of interest related to this research and have received no grant support for this work.

Ethical Statements: This retrospective study was performed in accordance with the ethical standards of each institution's committee on human experimentation and with the Helsinki Declaration of 1964 and its later versions. Patients were given an opportunity to optout of this study through public announcements published by each institution. The study protocol was approved by the JBES (approval number 2020-01) and the Institutional Review Board of the Japanese Foundation for Cancer Research (approval number 2020-1147). All institutions applied for and obtained study approval from their respective institutional review boards.

ORCID

Akihiko Okamura  <https://orcid.org/0000-0002-3217-8888>

Masayuki Watanabe  <https://orcid.org/0000-0003-0298-1597>

Yoshifumi Baba  <https://orcid.org/0000-0003-3657-2388>

Keijiro Sugimura  <https://orcid.org/0000-0002-5100-9377>

REFERENCES

1. Triboulet JP, Mariette C, Chevalier D, Amrouni H. Surgical management of carcinoma of the hypopharynx and cervical esophagus: analysis of 209 cases. *Arch Surg*. 2001;136:1164–70.
2. Shuangba H, Jingwu S, Yinfeng W, Yanming H, Qiuping L, Xianguang L, et al. Complication following gastric pull-up reconstruction for advanced hypopharyngeal or cervical esophageal carcinoma: a 20-year review in a Chinese institute. *Am J Otolaryngol*. 2011;32:275–8.
3. Dai Z, He Q, Pan B, Liu L, Zhou D. Postoperative complication assessments of different reconstruction procedures after total pharyngolaryngoesophagectomy: tubular gastric pull-up versus whole gastric pull-up. *Am Surg*. 2018;84:1927–31.
4. Okamura A, Watanabe M, Kanamori J, Imamura Y, Takahashi K, Ushida Y, et al. Digestive reconstruction after pharyngolaryngectomy with total esophagectomy. *Ann Surg Oncol*. 2021;28:695–701.
5. Slaughter DP, Southwick HW, Smejkal W. Field cancerization in oral stratified squamous epithelium; clinical implications of multicentric origin. *Cancer*. 1953;6:963–8.
6. Ong GB, Lee TC. Pharyngogastric anastomosis after oesophago-pharyngectomy for carcinoma of the hypopharynx and cervical oesophagus. *Br J Surg*. 1960;48:193–200.
7. Matsubara T, Ueda M, Nakajima T, Kamata S, Kawabata K. Elongated stomach roll with vascular microanastomosis for reconstruction of the esophagus after pharyngolaryngoesophagectomy. *J Am Coll Surg*. 1995;180:613–5.
8. Wei WI, Lam LK, Yuen PW, Wong J. Current status of pharyngolaryngo-esophagectomy and pharyngogastric anastomosis. *Head Neck*. 1998;20:240–4.
9. Law SY, Fok M, Wei WI, Lam LK, Tung PHM, Chu KM, et al. Thoracoscopic esophageal mobilization for pharyngolaryngoesophagectomy. *Ann Thorac Surg*. 2000;70:418–22.
10. Sagawa N, Okushiba S, Ono K, Ito K, Katoh H, Kondo S, et al. Reconstruction after total pharyngolaryngoesophagectomy. Comparison of elongated stomach roll with microvascular anastomosis with gastric pull up reconstruction or something like that. *Langenbecks Arch Surg*. 2000;385:34–8.
11. Ferahkose Z, Bedirli A, Kerem M, Azili C, Sozuer EM, Akin M. Comparison of free jejunal graft with gastric pull-up reconstruction after resection of hypopharyngeal and cervical esophageal carcinoma. *Dis Esophagus*. 2008;21:340–5.
12. Morita M, Saeki H, Ito S, Ikeda K, Yamashita N, Ando K, et al. Technical improvement of total pharyngo-laryngo-esophagectomy for esophageal cancer and head and neck cancer. *Ann Surg Oncol*. 2014;21:1671–7.
13. Watanabe M, Baba Y, Yoshida N, Ishimoto T, Sakaguchi H, Kawasuji M, et al. Modified gastric pull-up reconstructions following pharyngolaryngectomy with total esophagectomy. *Dis Esophagus*. 2014;27:255–61.
14. Liu J, Deng T, Li C, Peng L, Li Q, Zhu G, et al. Reconstruction of hypopharyngeal and esophageal defects using a gastric tube after total esophagectomy and pharyngolaryngectomy. *ORL J Otorhinolaryngol Relat Spec*. 2016;78:208–15.
15. Miyata H, Sugimura K, Motoori M, Fujiwara Y, Omori T, Mun M, et al. Clinical assessment of reconstruction involving gastric pull-up combined with free jejunal graft after total pharyngolaryngoesophagectomy. *World J Surg*. 2017;41:2329–36.
16. ASA Physical Status Classification System. <https://www.asahq.org/standards-and-guidelines/asa-physical-status-classification-system>. Accessed May 3, 2021
17. Dindo D, Demartines N, Clavien PA. Classification of surgical complications: a new proposal with evaluation in a cohort of 6336 patients and results of a survey. *Ann Surg*. 2004;240:205–13.
18. Schilling MK, Redaelli C, Maurer C, Friess H, Büchler MW. Gastric microcirculatory changes during gastric tube formation: assessment with laser Doppler flowmetry. *J Surg Res*. 1996;62:125–9.

19. Linder G, Hedberg J, Bjorck M, Sundbom M. Perfusion of the gastric conduit during esophagectomy. *Dis Esophagus*. 2017;30:143–9.
20. Noma K, Shirakawa Y, Kanaya N, Okada T, Maeda N, Ninomiya T, et al. Visualized evaluation of blood flow to the gastric conduit and complications in esophageal reconstruction. *J Am Coll Surg*. 2018;226:241–51.
21. Ladak F, Dang JT, Switzer N, Mocanu V, Tian C, Birch D, et al. Indocyanine green for the prevention of anastomotic leaks following esophagectomy: a meta-analysis. *Surg Endosc*. 2019;33:384–94.
22. Nishikawa K, Fujita T, Yuda M, Tanaka Y, Matsumoto A, Tanishima Y, et al. Quantitative assessment of blood flow in the gastric conduit with thermal imaging for esophageal reconstruction. *Ann Surg*. 2020;271:1087–94.

How to cite this article: Okamura A, Watanabe M, Mukoyama N, Ota Y, Shiraishi O, Shimbashi W, et al; the Japan Broncho-Esophagological Society, Pharyngolaryngectomy with Total Esophagectomy (JBES-PLTE) Study Group. A Nationwide Survey on Digestive Reconstruction Following Pharyngolaryngectomy With Total Esophagectomy: A Multicenter Retrospective Study in Japan. *Ann Gastroenterol Surg*. 2022;6:54–62. <https://doi.org/10.1002/ags3.12509>