

Perforated duodenal ulcer: which operation?

P J Gill, C F J Russell

Accepted 7 September 1987.

SUMMARY

Between January 1968 and December 1977 a total of 230 patients with a perforated duodenal ulcer underwent emergency operation in the Royal Victoria Hospital. Simple suture closure of the perforation was carried out in 205, and in the remaining 25 a definitive ulcer procedure was performed in addition. Four patients died following operation, a mortality rate of 1.7%.

During a mean follow-up period of 10.3 years at least 107 patients (52%) who had simple suture closure of their perforation developed further ulcer symptoms. Of these, seven re-perforated and a further 56 required elective definitive ulcer surgery. A strong case can be made for a definitive ulcer operation at the time of emergency surgery for a perforated chronic duodenal ulcer.

INTRODUCTION

Simple suture of the perforated duodenal ulcer has been the standard operative treatment since its acceptance as such in the early part of this century. The principle upon which this form of management is based was well described by Graham in 1937 when he stated that 'We have no responsibility to such patients but to save their lives' and 'We have no responsibility during the surgery to carry out any procedure designed to cure the patient of his original duodenal ulcer'.¹

Since then, however, many authors have reported a high incidence of recurrent symptoms and indeed a significant incidence of life-threatening complications after simple suture of a perforated duodenal ulcer. Illingworth in 1946 reported a relapse rate of 70% and a 20% incidence of major complications in a large group of such patients followed up for five years.² Similar high relapse rates have more recently been confirmed by others^{3,4,5} and some would now consider that a definitive procedure should be combined with simple suture as the emergency operation of choice.^{6,7} It therefore seemed appropriate to review the surgical management of perforated duodenal ulcer in this hospital, to document the incidence of subsequent ulcer symptoms and, in the light of these findings, to reassess our operative strategy in these ill patients.

MATERIALS AND METHODS

During the 10-year period January 1968 to December 1977, 230 patients underwent emergency operation for perforated duodenal ulcer in the Royal Victoria Hospital. This particular time period was chosen so that, on follow-up, a minimum period of five years had elapsed since operation for each patient. The

The Royal Victoria Hospital, Belfast BT12 6BA.

P J Gill, FRCS, Surgical Registrar.

C F J Russell, BDS, FRCS, Consultant Surgeon.

Correspondence to Mr Russell.

hospital records of these patients were obtained and clinical profiles, including pre-operative radiological findings, operative procedures performed and post-operative complications were documented. Follow-up information on patients was obtained by questionnaire, telephone interview and communication with the patients' general practitioners. Complete follow-up data were not available for 19 patients who had moved overseas, nine who declined to provide the information requested and 28 who could not be traced via their last recorded address, general practitioner or the Central Services Agency. Full information was available for 174 patients including 30 who had died during the period of follow-up.

RESULTS

Of the 230 patients in the study 200 were male and 30 were female (6.7:1). The age distribution in both sexes is shown in Fig 1. Of 217 patients for whom the information is recorded, 55 (25%) had no dyspeptic symptoms prior to perforation and a further 12 had been symptomatic for less than three months. By conventional definition, therefore, 67 patients (30.9%) perforated an acute ulcer. In the remaining 150 patients with chronic ulcers the mean duration of symptoms was 98 months (range four to 420 months). The majority (64%) of the entire patient group were regular cigarette smokers. Of 191 patients with clear documentation of pre-operative abdominal radiology, 133 (69%) had free intra-peritoneal gas on the erect film.

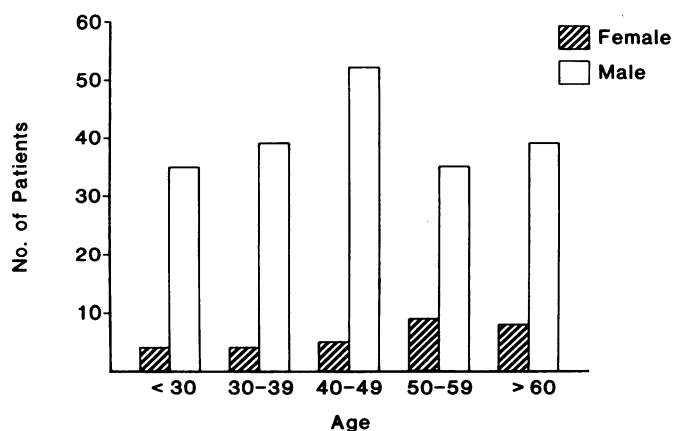


Fig 1.
Age and sex distribution of 230 patients with perforated duodenal ulcer.

The operative procedure performed in 205 patients was simple suture of the perforated duodenal ulcer, usually incorporating an omental patch. In the remaining 25, simple suture was combined with a definitive ulcer operation — truncal vagotomy and pyloroplasty in 13, truncal vagotomy and gastro-jejunostomy in 10, selective vagotomy and gastro-jejunostomy in one and truncal vagotomy without a drainage procedure in one patient.

A total of 16 patients had undergone previous peptic ulcer surgery — six had simple suture of a perforated duodenal ulcer and 10 had required definitive elective operation in the form of truncal vagotomy and gastro-jejunostomy (nine patients) and truncal vagotomy and pyloroplasty (one patient). These patients all perforated a chronic ulcer and were treated by simple suture closure with a re-vagotomy being added in one.

Post-operative complications including chest infection, wound infection, residual intra-peritoneal abscess, and thrombo-embolism were recorded for the entire patient group. The incidence of complications in the group of patients who underwent simple suture and in those who had a definitive procedure performed is recorded in the Table. Less frequent complications which arose in individual patients included bleeding per rectum (due to hypercitraemia/hypocalcaemia), haematemesis, stomal intussusception, superficial thrombophlebitis, pyloric obstruction, delirium tremens, acute urinary retention, and bacteraemia. In total 60 patients (29.3%) who had simple suture carried out and four (16.0%) of those who underwent a definitive procedure developed complications.

TABLE

	<i>Simple suture</i> (<i>n</i> = 205)	<i>Definitive surgery</i> (<i>n</i> = 25)
Chest infection	24 (11.7%)	2 (8.0%)
Wound infection	18 (8.8%)	1 (4.0%)
Wound dehiscence	9 (4.4%)	0
Subphrenic abscess	6 (2.9%)	0
Pelvic abscess	4 (1.9%)	0
Thrombo-embolism	1 (0.5%)	0
Other	19 (9.3%)	2 (8.0%)

Post-operative follow-up ranged from five to 15 years, mean 10.3 years. During the follow-up period, 107 (61%) of the 174 on whom complete information was available developed further symptoms related to their duodenal ulcers. With the exception of 13 all had had symptoms for longer than three months prior to perforation. All of these 107 patients had simple suture of their perforation at the initial operation. The symptom-free period following perforation ranged from zero to 12 years but the vast majority experienced recurrent symptoms within the first three years, mean 20.6 months (Fig 2). In seven patients (4.0%) re-perforation occurred. In a further 56 patients (32.2%) persisting or recurring dyspeptic symptoms necessitated elective definitive ulcer surgery.

Four patients died immediately following operation, a mortality rate of 1.7%. All of these patients had simple suture closure of the perforation. Of the four post-operative deaths two occurred in frail elderly men with no previous

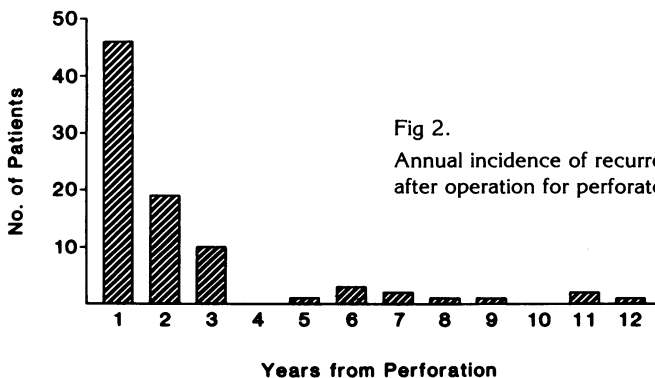


Fig 2.

Annual incidence of recurrent ulcer symptoms in patients after operation for perforated duodenal ulcer.

symptoms or precipitating factors. The third was a 64-year-old man with no previous dyspeptic history who smoked more than 30 cigarettes a day, consumed large quantities of alcohol and who developed a chest infection. The fourth was a 46-year-old woman with a dyspeptic history who was on both steroidal and non-steroidal anti-inflammatory therapy. There were no additional deaths during the follow-up period due to perforated duodenal ulcer or to related ulcer complications.

DISCUSSION

The classical presentation of perforated duodenal ulcer — sudden severe upper abdominal pain and clinical peritonitis — is well recognised. Frequently a history of peptic ulcer symptoms is given by the patient but not invariably so. Fully a quarter of our patients had no dyspeptic symptoms prior to perforation, a finding reflected in reports from other centres.^{6, 8, 9} Nineteen patients were taking steroids or non-steroidal anti-inflammatory agents at the time of perforation. The proportion of patients with perforated duodenal ulcer reported to have free gas below the diaphragm on the erect abdominal radiograph is variable.^{3, 10} In this group 69.6% of individuals X-rayed in the pre-operative period were found to have free sub-diaphragmatic gas. Whilst a definitive ulcer history and positive pre-operative radiological findings are strong corroborative factors, their absence in any individual patient should not deter the surgeon from making the diagnosis of perforated peptic ulcer and initiating treatment if the clinical picture is appropriate.

There is continuing debate in the literature regarding the preferred surgical procedure for the patient with a perforated duodenal ulcer. Simple suture closure of the perforation has much to commend it — the procedure itself is usually technically undemanding and can readily be performed by a relatively inexperienced surgeon, often operating on an ill patient. The vast majority of the patients in our series (205; 89%) had simple suture of their perforation carried out over a 10 year period by a large number of surgeons, virtually all of whom were in the training grades. The mortality rates of 2% for this group of individuals, and 1.7% for the entire group of 230 patients compare very favourably with those reported in other series,^{3, 6, 9, 10, 11} but do not quite match the remarkable 'zero' mortality achieved by A B Mitchell, operating in the Royal Victoria Hospital in the early years of this century.¹²

During the follow-up period of our study at least 107 patients (52%) who had simple suture closure of a perforation at initial operation developed further ulcer symptoms. Of these, seven re-perforated and 56 required definitive ulcer surgery. These figures are in keeping with those documented from elsewhere.^{1, 3, 4, 5, 8} It is because of this very high incidence of recurrent symptoms following simple suture of a perforated duodenal ulcer that some authors advocate the performance of a definitive operation at the time of initial surgery.^{3, 6, 7, 10, 11} Clearly such a policy can only be justified if the more demanding and time-consuming operations such as proximal gastric vagotomy or truncal vagotomy and drainage can be performed in these uniformly sick patients without any increase in morbidity and mortality. In common with others,^{3, 10, 11} our data suggest that this indeed may be the case although the number of patients in the definitive surgery group is too small for legitimate comparative purposes. However, prospective randomised studies by other authors, with careful follow-up of patients, do indicate that emergency definitive ulcer surgery is not associated with an increased complication rate.^{13, 14}

We thus feel that a strong case can be made for performing a definitive ulcer operation at the time of emergency surgery for the chronic perforated duodenal ulcer. These patients have a high risk of developing further symptoms refractory to medical treatment. However, we do not extend this argument to the treatment of perforated acute duodenal ulcers since it would appear that the risk of recurrent symptoms in such patients is significantly less — 13 of 67 individuals (19%) during the period of our study. In general we hold the view that a dogmatic approach is not appropriate and readily acknowledge that simple suture closure of the perforation by a relatively inexperienced surgeon operating on an ill patient in the small hours of the morning is a perfectly legitimate and correct treatment.

We wish to thank the consultant surgeons at the Royal Victoria Hospital, Belfast, for allowing us to study the case notes of their patients. Thanks are also extended to Miss C Rusk and Miss D McFarland for secretarial assistance and to Mr C Patterson, Department of Medical Statistics, The Queen's University of Belfast.

REFERENCES

1. Graham RR. The treatment of perforated duodenal ulcers. *Surg Gynecol Obstet* 1937; **64**: 235-8.
2. Illingworth CFW, Scott LDW, Jamieson RA. Progress after perforated peptic ulcer. *Br Med J* 1946; **1**: 787-90.
3. Coutsoftides T, Himel HS. Perforated gastroduodenal ulcers. *Am J Surg* 1976; **132**: 575-6.
4. Hennessy EJ, Chapman BL, Duggan JM. Perforated peptic ulcer long-term follow-up. *Med J Aust* 1976; **1**: 50-3.
5. Drury JK, McKay AJ, Hutchison JSF, Joffe SN. Natural history of perforated duodenal ulcers treated by suture closure. *Lancet* 1978; **2**: 749-50.
6. Skovgaard S. Late results of perforated duodenal ulcer treated by simple suture. *World J Surg* 1977; **1**: 521-6.
7. Gray JG, Roberts AK. Definitive emergency treatment of perforated duodenal ulcer. *Surg Gynecol Obstet* 1976; **143**: 890-4.
8. Cassell P. The prognosis of the perforated acute duodenal ulcer. *Gut* 1969; **10**: 572-4.
9. Playforth MJ, McMahon MJ. The indications for simple suture closure of perforated duodenal ulcers. *Br J Surg* 1978; **65**: 699-701.
10. Kirkpatrick JR, Bouman DL. A logical solution to the perforated ulcer controversy. *Surg Gynecol Obstet* 1980; **150**: 683-6.
11. Sawyers JL, Herrington JL. Perforated duodenal ulcer managed by proximal gastric vagotomy and suture plication. *Ann Surg* 1977; **185**: 656-70.
12. Mitchell AB. Duodenal ulcer: its diagnosis and treatment, with illustrative cases. *Dublin J Med Sci* 1908; **125**: 429-46.
13. Boey J, Lee NW, Koo J, Lam PH, Wong J, Ong GB. Immediate definitive surgery for perforated duodenal ulcers. *Ann Surg* 1982; **196**: 338-44.
14. Tanphiphat C, Tanprayoon T, Na Thalang A. Surgical treatment of perforated duodenal ulcer: a prospective trial between simple closure and definitive surgery. *Br J Surg* 1985; **72**: 370-2.