

# The Efficacy of Posterior Cervical Laminectomy for Multilevel Degenerative Cervical Spondylotic Myelopathy in Long Term Period

## Abstract

**Study Design:** This was a retrospective analysis. **Background:** Surgical decompression is the gold standard for preventing the progression of neurological deficit in degenerative multilevel cervical spondylotic myelopathy (CSM). The efficacy of posterior laminectomy in the surgical management of CSM has been described in the past, but long-term follow-up data are scanty. **Objective:** The aim of this study is to assess the long-term clinical-radiological outcomes following posterior cervical decompressive laminectomy in multilevel degenerative CSM. **Materials and Methods:** A retrospective analysis of 110 patients with degenerative multilevel CSM who underwent posterior cervical laminectomy alone in a single hospital by a single surgeon from 2009 to 2013 with minimum 5-year follow-up. Pre- and post-operative clinical parameters (visual analog scale [VAS], Nurick and modified Japanese orthopedic association [mJOA]), radiological parameter (Sagittal cervical Cobb's Angle), perioperative complications (time, blood loss, and hospital stay), postoperative complications (infection, C5 palsy, and neurological worsening) were evaluated. **Results:** Totally 110 patients (males – 68 and females – 42) with age varying from 46 to 80 (mean-57) years, and the mean duration of illness was 3 months were evaluated. Mean clinical parameters are VAS (preoperative =  $5 \pm 1.31$ , postoperative =  $1.49 \pm 0.687$ ), Nurick grading (preoperative =  $3.23 \pm 71$ , postoperative =  $1.924 \pm 0.75$ ), and mJOA (preoperative =  $6.32 \pm 0.87$ , postoperative =  $9.89 \pm 1.37$ ). The mean blood loss was  $93.95 \pm 19.18$  ml, and the mean time taken for surgery was  $83.65 \pm 10.18$  min. About 13% ( $n = 15$ ) patients developed cervical kyphosis and 29% ( $n = 32$ ) developed changes in cervical spine alignment and 10% ( $n = 11$ ) developed worsening of neurology at final follow-up. Two patients developed a superficial infection which was managed with antibiotics. Three patients developed C5 palsy which recovered with due time. **Conclusions:** With the proper selection of patients, posterior cervical laminectomy is effective in offering a clinical improvement to patients with degenerative multilevel CSM with a low incidence of clinically significant radiological deterioration.

**Keywords:** Cervical laminectomy, cervical spondylotic myelopathy, neurological recovery, surgical outcome

## Introduction

Cervical spondylotic myelopathy (CSM) is a progressive degenerative spine disease and the most common cause of spinal cord dysfunction in adults worldwide.<sup>[1-3]</sup> The structural changes involved in CSM includes (1) degeneration of intervertebral discs, vertebral bodies, and facet joints; (2) hypertrophy of the ligamentum flavum; and (3) ossification of posterior longitudinal ligament (OPLL).<sup>[4,5]</sup> These changes significantly narrow the spinal canal and reduce the space available for the spinal cord. As societies continue to age over coming decades, the prevalence of this common spinal disease is expected to increase among the population.<sup>[6,7]</sup>

This is an open access journal, and articles are distributed under the terms of the Creative Commons Attribution-NonCommercial-ShareAlike 4.0 License, which allows others to remix, tweak, and build upon the work non-commercially, as long as appropriate credit is given and the new creations are licensed under the identical terms.

For reprints contact: reprints@medknow.com

Surgical decompression is the gold standard procedure for preventing the progression of neurological deficits in patients with CSM.<sup>[2,8,9]</sup> However, the efficacy of posterior laminectomy in the surgical management of CSM has been described in the past but long-term follow-up data in the Indian subcontinent are scanty.

The aim of the study is to evaluate the long-term efficacy with clinical-radiological outcomes of posterior cervical decompression without fusion in patients with multilevel degenerative CSM.

## Materials and Methods

After obtaining permission from the ethical committee and hospital management, a retrospective analysis of 110 patients with degenerative multilevel CSM who underwent

**How to cite this article:** Kire N, Jain S, Merchant ZA, Kundnani V. The efficacy of posterior cervical laminectomy for multilevel degenerative cervical spondylotic myelopathy in long term period. Asian J Neurosurg 2019;14:848-52.

Neilakuo Kire,  
Sanyam Jain,  
Zahir Abbas Merchant,  
Vishal Kundnani

Spine Unit, Department of  
Orthopaedics, Bombay Hospital  
and Medical Research Centre,  
Mumbai, Maharashtra, India

### Address for correspondence:

Dr. Neilakuo Kire,  
Room 128, MRC Building,  
Bombay Hospital, Marine Lines,  
Mumbai, Maharashtra, India.  
E-mail: drneilkire@gmail.com

### Access this article online

Website: [www.asianjns.org](http://www.asianjns.org)

DOI: 10.4103/ajns.AJNS\_49\_19

### Quick Response Code:



posterior cervical laminectomy alone in a single hospital by a single surgeon from 2004 to 2013 with minimum 5-year follow-up was done. Demographic data (age, sex, duration of illness to presentation, and comorbidities), pre- and post-operative clinical parameters (neck pain score-visual analog scale [VAS], Nurick grading and modified Japanese orthopedic association [mJOA]), radiological parameter (Sagittal cervical Cobb's Angle), perioperative complications (operative time, blood loss, and hospital stay), postoperative complications (infection, C5 root palsy, and neurological worsening) were evaluated [Figures 1-3].

### Inclusion criteria

Inclusion criteria were as follows:

1. Age 45 years and above
2. Compression at level 3 or more
3. Minimum follow-up of 5 years
4. Cobb's angle  $>10^\circ$  lordotic (C2–C7) measured on standing lateral cervical spine radiography.

### Exclusion criteria

Exclusion criteria were as follows:

1. OPLL
2. Disc herniation
3. Infection
4. Neoplastic disease
5. Rheumatoid arthritis or ankylosing spondylitis
6. Patient who underwent anterior surgeries, posterior surgery with fusion, or revision surgery
7. Developmentally narrow canal (canal diameter  $<12$  mm at the base of C2).

Patients were sequentially followed up at 3 months, 6 months, 12 months, and 2 years after surgery and then annually.

### Surgical procedure

Under general anesthesia, the patient is positioned prone on padded bolsters. The neck is placed in neutral or in mild flexion. The arms are strapped by the side. A standard midline posterior exposure from C3 to C6 is carried out up to the lamina-facet junction taking care to preserve the attachments to C2 and C7. The dissection is restricted just lateral to the lamina-facet junction and the soft tissues attachments over the facet joints are preserved. The furrow at the junction of the lamina and the facet joints is marked at all levels requiring laminectomy. The gutters were created on both sides using a high-speed cutting burr till the inner cortex were reached. 1-mm Kerrison rongeur was used to remove the flavum up to the lateral gutters created. The rongeur was used to complete the furrows on either side all the way up to the C2–C3 interlaminar space. The laminectomy was completed by lifting the laminae *en bloc* from the caudal end, and gentle dissection was performed for any adhesion between the ligamentum flavum and dura.

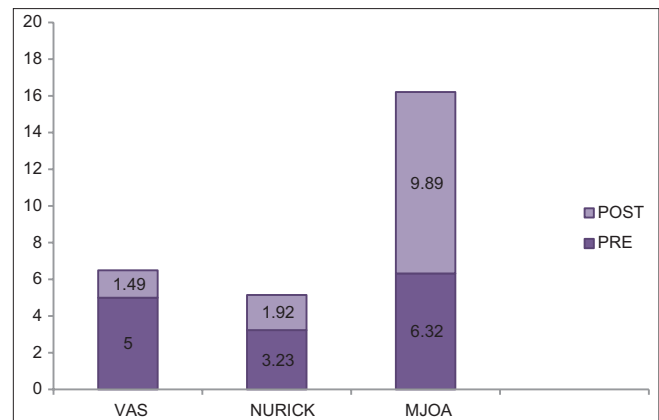


Figure 1: Graphical diagram neurology (pre and postoperative)

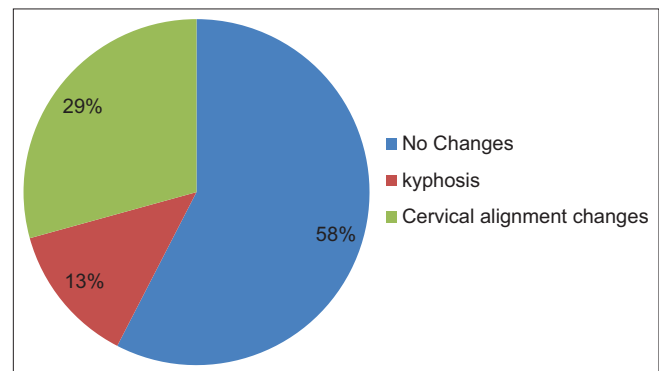


Figure 2: Postoperative cervical Cobb's angle changes

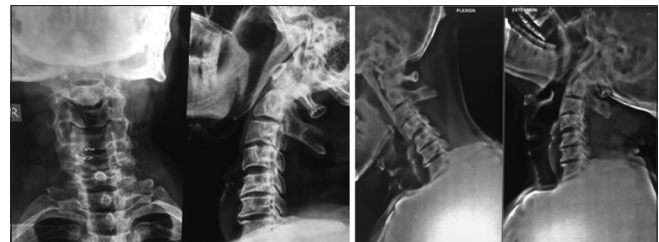

Figure 3: A 53-year-old male immediate and postoperative images at 5-year follow-up

Undercutting of C2 and C7 laminae with foraminotomy of C5 was done to provide adequate decompression.

Postoperative patients are encouraged to sit up in bed 24 h after the surgery. Patients are mobilized out of bed on the 2<sup>nd</sup> postoperative day using a soft cervical collar which was discontinued after suture removal.

The statistical analysis was carried out using a paired student *t*-test. Differences were considered statistically significant at  $P < 0.05$ . Statistical analysis was done using SPSS software 20.0 (SPSS Inc., Chicago, IL, USA).

### Results

The mean age of patients was 57.71 years (varying from 46 to 80) with male-to-female ratio 68:42. The mean duration of presentation of illness was 3 months,

**Table 1: Demography**

Variables	Mean
Age	57.71±6.82
Gender	68 male:42 female
Duration of presenting illness (in months)	3.12±1.82

**Table 2: Comorbidity**

Comorbidity	n (%)
DM	17 (14.28)
HTN	31 (26.05)
BA	2 (1.68)
HIV	1 (0.84)

HTN – Hypertension; DM – Diabetes mellitus; BA – Bronchial asthma

**Table 3: Neurological comparison (pre- and post-operative) (n=110)**

	Pre	Post	P
VAS	5±1.31	1.49±0.687	<0.05 (S)
Nurick	3.23±0.71	1.924±0.75	<0.05 (S)
mJOA	6.32±0.87	9.89±1.37	<0.05 (S)
Cobb's angle	16.38±2.66	15.53±2.86	<0.05 (S)

VAS – Visual analog scale; S – Significant; mJOA – Modified Japanese orthopedic association

**Table 4: Intraoperative duration (n=119)**

	Mean±SD
Surgical time	83.65±10.18
Blood loss	93.95±19.27

SD – Standard deviation

the mean duration of follow-up period was 8.1 years (5-15). VAS demonstrated significant improvement from pre-operative value of mean  $5 \pm 1.31$  to post-operative mean of  $1.49 \pm 0.687$ . mJOA scores improved to mean value  $9.89 \pm 1.37$  from pre-operative mean value of  $6.32 \pm 0.87$ . There is significant difference in nurick grading between pre-op value ( $3.23 \pm 71$ ) as compared to post-op ( $1.924 \pm 0.75$ ). About 13% (15 patients) developed cervical kyphosis and 29% (32 patients) developed changes in cervical spine alignment and 10% (11 patients) developed deterioration of neurology at final follow-up. The mean blood loss was  $93.95 \pm 19.18$  ml and the mean operative time was  $83.65 \pm 10.18$  min with mean hospital stay of 4.3 days. Two patients developed a superficial infection which was managed with injectable antibiotics with 2 weeks. Three patients developed C5 palsy which recovered within 6 months–1-year follow-up [Tables 1-4].

## Discussion

Surgical decompression is the gold standard procedure for preventing the progression of neurological deficits in patients with CSM,<sup>[2,8,9]</sup> and among the available techniques, laminoplasty is generally as most effective surgical option

with lowest risk of perioperative complication.<sup>[10-12]</sup> However, surgical results for laminoplasty remain unclear in elderly patients. Several reports have revealed a comparable degree of neurological recovery between elderly and younger patients.<sup>[13-18]</sup>

In multilevel degenerative CSM, anterior approach carries more morbidities following multilevel corpectomies and reconstructions, increased blood loss and surgical time, fusion-related complications, and subsidence. Research in the fusion surgery has shown that elderly patients have higher mortality, postoperative complications, and bony nonunion rates than younger patients.<sup>[19,20]</sup> Puvanesarajah *et al.*<sup>[21]</sup> also demonstrate significantly increased rates of surgical complications and mortality after anterior cervical fusion.

Posterior cervical laminectomy has assumed an irreplaceable role in preventing symptomatic progression of CSM, but emerging alternative procedure filed controversy among surgeons.<sup>[22,23]</sup>

Several comparative studies between procedures have already been done; like Hamanishi and Tanaka reported on their experience in patients with CSM who underwent laminectomy and fusion; and patients who underwent laminectomy alone, they did not observe any significant difference in functional status between the groups.<sup>[24]</sup> Lad *et al.* retrospectively reviewed a total of 2385 patients with decompression only and 620 patients with fusion and found that complication rates of the initial procedure hospitalization, and at 90 days were significantly higher for those who underwent laminectomy with fusion comparing with those who underwent laminectomy alone.<sup>[25]</sup>

The most described drawback regarding posterior cervical decompression by laminectomy involves the induction of kyphotic changes in postoperative cervical sagittal balance with increased risk of long-term instability; therefore, some authors recommended complimentary fusion as a preventive strategy significantly increasing the cost of the procedure, operative time, blood loss, and adds specific risk for complications.<sup>[24-26]</sup>

Ryken *et al.* mentioned clinical improvement after cervical laminectomy ranges from 42%–90% and also mentioned the duration of symptoms was identified as a predisposing variable since patients with asymptomatic period over 12 months reached lower long-term mean score values. However, there is no significant difference in the functional status variation and surgery enables a functional improvement concerning myelopathy regardless of disease progression time.<sup>[27,28]</sup>

Kaptain *et al.* reported on 46 patients undergoing laminectomy who had pre- and post-operative radiographic and concluded that the development of a postoperative deformity (kyphosis) was more than twice as likely in

patients with a “straight” preoperative spine (loss of lordosis) than in those with a normal lordosis.<sup>[28]</sup>

Regarding complications, van Geest *et al.* identified a rate of 9% comprising postoperative C5 radiculopathy and superficial wound infection that is, consistent with the literature;<sup>[29]</sup> these rates strengthen the role of cervical laminectomy as a safe procedure with low morbidity.

Bartels *et al.*, published a small clinical randomized trial comparing nine patients underwent laminectomy and nine patients underwent laminectomy and fusion. They did not find a difference in the neurologic outcome or quality of life between the groups at an average follow-up of 18.3 months. These results suggest that laminectomy alone may be safe and effective in patients with preserved cervical lordosis and a stable cervical spine, without preoperative spinal instability, in whose decompression would not involve the facet joints, C2 lamina or the cervicothoracic junction.<sup>[30]</sup>

According to Du *et al.* study, 30 patients underwent laminectomy alone and 30 patients for laminectomy and fusion and reported that loss of curvature index with a high incidence of axial neck symptoms in laminectomy group.<sup>[31]</sup>

Heller *et al.* performed a matched cohort study in 26 patients with CSM who underwent either by laminoplasty or laminectomy with lateral mass fixation and grafting. The author reported no significant difference in neurological recovery, postoperative axial neck pain, and complication rate between two groups. Radiologically also, no difference in cervical alignment postoperative, although severe kyphosis developed in one patient who underwent fusion.<sup>[32]</sup>

With Woods *et al.*, 82 patients underwent decompression with fusion surgery and 39 patients underwent decompression alone and reported that similar functional improvement in both groups. However, 7 (9%) patient had complications in decompression and fusion with 2 (2%) patients required revision surgery as compared to 5 (13%) patient had complications in decompression alone with 2 (5%) patients required revision surgery.<sup>[33]</sup>

Therefore, our study shows that posterior cervical decompression without fusion in multilevel degenerative CSM patients yields a significant improvement in clinical status even in long-term follow-up period. Fifteen patients who developed cervical kyphosis and 32 patients who developed straightening of the cervical spine at final follow-up which may be contributed to lesser preoperative lordotic Cobb’s angle. Furthermore, over 85% of patients was satisfied with the outcome that favors the effect of surgery in their daily lives.

Limitation of this study is the retrospective nature of the data collected which can lead to some bias in the results.

## Conclusions

With proper selection of patients, posterior cervical laminectomy is effective in offering a clinical improvement to patients with multilevel degenerative CSM in long term even though there are changes in cervical alignment.

## Financial support and sponsorship

Nil.

## Conflicts of interest

There are no conflicts of interest.

## References

1. Fehlings MG, Tetreault LA, Riew KD, Middleton JW, Wang JC. A clinical practice guideline for the management of degenerative cervical myelopathy: Introduction, rationale, and scope. *Global Spine J* 2017;7:21S-27S.
2. Kalsi-Ryan S, Karadimas SK, Fehlings MG. Cervical spondylotic myelopathy: The clinical phenomenon and the current pathobiology of an increasingly prevalent and devastating disorder. *Neuroscientist* 2013;19:409-21.
3. Fehlings MG, Tetreault LA, Wilson JR, Skelly AC. Cervical spondylotic myelopathy: Current state of the art and future directions. *Spine (Phila Pa 1976)* 2013;38:S1-8.
4. Shamji MF, Ames CP, Smith JS, Rhee JM, Chapman JR, Fehlings MG, *et al.* Myelopathy and spinal deformity: Relevance of spinal alignment in planning surgical intervention for degenerative cervical myelopathy. *Spine (Phila Pa 1976)* 2013;38:S147-8.
5. Nouri A, Tetreault L, Singh A, Karadimas SK, Fehlings MG. Degenerative cervical myelopathy: Epidemiology, genetics, and pathogenesis. *Spine (Phila Pa 1976)* 2015;40:E675-93.
6. Harris N, Grootjans J, Wenham K. Ecological aging: The settings approach in aged living and care accommodation. *Ecohealth* 2008;5:196-204.
7. Nakashima H, Tetreault LA, Nagoshi N, Nouri A, Kopjar B, Arnold PM, *et al.* Does age affect surgical outcomes in patients with degenerative cervical myelopathy? Results from the prospective multicenter AOSpine international study on 479 patients. *J Neurol Neurosurg Psychiatry* 2016;87:734-40.
8. Isogai N, Nagoshi N, Iwanami A, Kono H, Kobayashi Y, Tsuji T, *et al.* Surgical treatment of cervical spondylotic myelopathy in the elderly: Outcomes in patients aged 80 years or older. *Spine (Phila Pa 1976)* 2018;43:E1430-6.
9. Fehlings MG, Wilson JR, Kopjar B, Yoon ST, Arnold PM, Massicotte EM, *et al.* Efficacy and safety of surgical decompression in patients with cervical spondylotic myelopathy: Results of the AOSpine North America prospective multi-center study. *J Bone Joint Surg Am* 2013;95:1651-8.
10. Hirabayashi K, Miyakawa J, Satomi K, Maruyama T, Wakano K. Operative results and postoperative progression of ossification among patients with ossification of cervical posterior longitudinal ligament. *Spine (Phila Pa 1976)* 1981;6:354-64.
11. Shiraishi T, Kato M, Yato Y, Ueda S, Aoyama R, Yamane J, *et al.* New techniques for exposure of posterior cervical spine through intermuscular planes and their surgical application. *Spine (Phila Pa 1976)* 2012;37:E286-96.
12. Seichi A, Takeshita K, Ohishi I, Kawaguchi H, Akune T, Anamizu Y, *et al.* Long-term results of double-door laminoplasty for cervical stenotic myelopathy. *Spine (Phila Pa 1976)* 2001;26:479-87.

13. Chen J, Liu Z, Zhong G, Qian L, Li Z, Chen B, *et al.* Surgical treatment for cervical spondylotic myelopathy in elderly patients: A retrospective study. *Clin Neurol Neurosurg* 2015;132:47-51.
14. Handa Y, Kubota T, Ishii H, Sato K, Tsuchida A, Arai Y, *et al.* Evaluation of prognostic factors and clinical outcome in elderly patients in whom expansive laminoplasty is performed for cervical myelopathy due to multisegmental spondylotic canal stenosis. A retrospective comparison with younger patients. *J Neurosurg* 2002;96:173-9.
15. Kawaguchi Y, Kanamori M, Ishihara H, Ohmori K, Abe Y, Kimura T, *et al.* Pathomechanism of myelopathy and surgical results of laminoplasty in elderly patients with cervical spondylosis. *Spine (Phila Pa 1976)* 2003;28:2209-14.
16. Machino M, Yukawa Y, Imagama S, Ito K, Katayama Y, Matsumoto T, *et al.* Surgical treatment assessment of cervical laminoplasty using quantitative performance evaluation in elderly patients: A prospective comparative study in 505 patients with cervical spondylotic myelopathy. *Spine (Phila Pa 1976)* 2016;41:757-63.
17. Son DK, Son DW, Song GS, Lee SW. Effectiveness of the laminoplasty in the elderly patients with cervical spondylotic myelopathy. *Korean J Spine* 2014;11:39-44.
18. Tanaka J, Seki N, Tokimura F, Doi K, Inoue S. Operative results of canal-expansive laminoplasty for cervical spondylotic myelopathy in elderly patients. *Spine (Phila Pa 1976)* 1999;24:2308-12.
19. Puvanesarajah V, Jain A, Shimer AL, Li X, Singla A, Shen F, *et al.* Complications and mortality following 1 to 2 level lumbar fusion surgery in patients above 80 years of age. *Spine (Phila Pa 1976)* 2017;42:437-41.
20. Hayashi K, Matsumura A, Konishi S, Kato M, Namikawa T, Nakamura H, *et al.* Clinical outcomes of posterior lumbar interbody fusion for patients 80 years of age and older with lumbar degenerative disease: Minimum 2 years' follow-up. *Global Spine J* 2016;6:665-72.
21. Puvanesarajah V, Jain A, Shimer AL, Singla A, Shen F, Hassanzadeh H, *et al.* Complications and mortality following one to two-level anterior cervical fusion for cervical spondylosis in patients above 80 years of age. *Spine (Phila Pa 1976)* 2017;42:E509-14.
22. Guidetti B, Fortuna A. Long-term results of surgical treatment of myelopathy due to cervical spondylosis. *J Neurosurg* 1969;30:714-21.
23. Hsu L. Cervical myelopathy: Overview and management. *J Pain Palliat Care Pharmacother* 2012;26:371-2.
24. Hamanishi C, Tanaka S. Bilateral multilevel laminectomy with or without posterolateral fusion for cervical spondylotic myelopathy: Relationship to type of onset and time until operation. *J Neurosurg* 1996;85:447-51.
25. Lad SP, Babu R, Ugiliweneza B, Patil CG, Boakye M. Surgery for spinal stenosis: Long-term reoperation rates, health care cost, and impact of instrumentation. *Spine (Phila Pa 1976)* 2014;39:978-87.
26. McAllister BD, Rebholz BJ, Wang JC. Is posterior fusion necessary with laminectomy in the cervical spine? *Surg Neurol Int* 2012;3:S225-31.
27. Ryken TC, Heary RF, Matz PG, Anderson PA, Groff MW, Holly LT. Cervical laminectomy for the treatment of cervical degenerative myelopathy. *J Neurosurg Spine* 2009;11:142-9.
28. Kaptain GJ, Simmons NE, Replogle RE, Pobereskin L. Incidence and outcome of kyphotic deformity following laminectomy for cervical spondylotic myelopathy. *J Neurosurg* 2000;93:199-204.
29. van Geest S, de Vormer AM, Arts MP, Peul WC, Vleggeert-Lankamp CL. Long-term follow-up of clinical and radiological outcome after cervical laminectomy. *Eur Spine J* 2015;24 Suppl 2:229-35.
30. Bartels RH, Groenewoud H, Peul WC, Arts MP. Lamifuse: Results of a randomized controlled trial comparing laminectomy with and without fusion for cervical spondylotic myelopathy. *J Neurosurg Sci* 2017;61:134-9.
31. Du W, Wang L, Shen Y, Zhang Y, Ding W, Ren L, *et al.* Long-term impacts of different posterior operations on curvature, neurological recovery and axial symptoms for multilevel cervical degenerative myelopathy. *Eur Spine J* 2013;22:1594-602.
32. Heller JG, Edwards CC 2<sup>nd</sup>, Murakami H, Rodts GE. Laminoplasty versus laminectomy and fusion for multilevel cervical myelopathy: An independent matched cohort analysis. *Spine (Phila Pa 1976)* 2001;26:1330-6.
33. Woods BI, Hohl J, Lee J, Donaldson W 3<sup>rd</sup>, Kang J. Laminoplasty versus laminectomy and fusion for multilevel cervical spondylotic myelopathy. *Clin Orthop Relat Res* 2011;469:688-95.